

CT Guided Free-Hand Evacuation of an Intracerebral Haemorrhage Following Thrombolytic Therapy For Myocardial Infarction: A Case Report

ÖZCAN BİNATLI, NEZİH OKTAR, YUSUF ERŞAHİN, İZZET ÖVÜL

Ege University, School of Medicine, Department of Neurosurgery, Bornova - İzmir / Türkiye

Abstract : Intracerebral haemorrhage as a complication of thrombolytic therapy for myocardial infarction is infrequent, but it is associated with grave prognosis. We report on a patient who had an intracerebral haemorrhage as a complication of thrombolytic treatment and advocate the CT guided free-hand removal of

the haematoma rather than craniotomy in these kinds of complicated cases.

Key words: Cerebral haemorrhage, Myocardial infarction, Plasminogen, Streptokinase, Thrombolytic therapy, Urokinase

INTRODUCTION

During the past decade, the management of myocardial infarction (MI) has shifted from bed rest and sedation and treating only complications such as arrhythmia or congestive heart failure to a more active approach including coronary angioplasty and thrombolytic therapy. Thrombolytic therapy for acute MI with the use of tissue plasminogen activators such as streptokinase and urokinase has been employed in many clinical trials. However, intracranial haemorrhage is an infrequent but devastating complication of this treatment (6,9). The intravenous administration of thrombolytic agents is currently recommended for the majority of patients admitted within 3-6 hours after onset of symptoms (2,9). Although haemorrhage is the major adverse effect of thrombolytic therapy, its incidence can be reduced by careful selection of patients and avoidance of unnecessary invasive procedures (2,10). We report on a patient with intracerebral haemorrhage following thrombolytic therapy for acute MI.

CASE REPORT

A 55-year-old man without a history of angina or hypertension sustained an acute MI on June 17 1989. At the time of admission to hospital, he was distressed by chest pain radiating to the left arm. On physical examination, blood pressure was 110/90 mmHg and pulse rate was 108 per minute. There was no sign of heart failure. After establishment of the diagnosis of acute inferior MI, intravenous streptokinase infusion was initiated. Loading dose was 750,000 U followed by a maintenance dose of 100,000 U per hour.

The following day, the patient started to complain about a severe headache, and then he vomited, followed by a decreased level of consciousness and a left-sided weakness within 12 hours. After the detection of intracerebral haematoma in the right fronto-parieto-temporal region on computed tomographic (CT) scans (Fig. 1), he was transferred to the intensive care unit in the department of

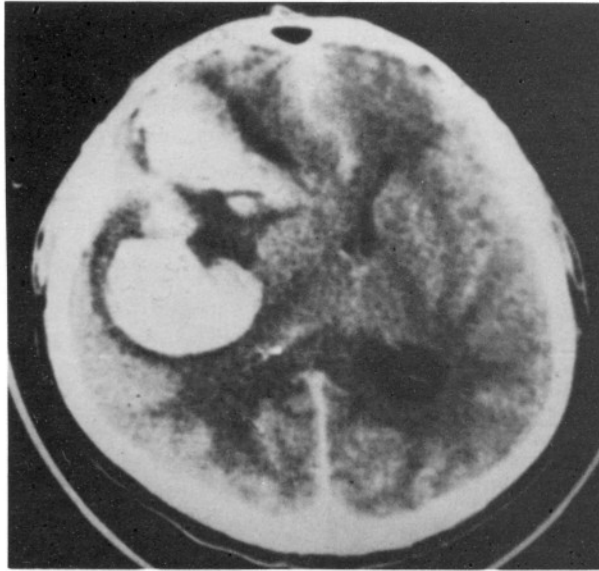


Fig. 1: Preoperative CT of the case showing a right-sided frontoparieto-temporal haematoma following thrombolytic therapy for acute MI.

neurology and put on mannitol, furosemide, dexamethasone and nimodipine. He was comatose (Glasgow Coma Scale; 1:5:2), and hemiplegic on the left side. Both pupils were miotic and nuchal rigidity was present. Bleeding, coagulation and prothrombine times were within normal limits. The patient was consulted and transferred to the department of neurosurgery. The same day, he was operated within 4 hours of the detection of ICH on CT scanning.

The haematoma was cannulated through a right temporal burr-hole under local anaesthesia. Thirty ml of liquefied haematoma were aspirated. Postoperative CT scans showed a marked reduction in the haematoma volume (Fig. 2). The catheter in the haematoma was kept in place for 5 days and the haematoma was aspirated every 12 hours. The catheter was removed on the 5th day. A small amount of haematoma was seen on CT scans (Fig. 3). Forty-one ml. haematoma in total had been evacuated by multiple aspirations. The patient was conscious and started to feed himself and move his left extremities. When he was discharged from hospital 2 weeks after surgery, he was able to walk

on his own. The hemiparesis improved almost completely one month later. His physical and neurological examinations were unremarkable for 3 years after the surgery. He had no complaints, except for forgetfulness. A hypodense area was noted at the site of the haematoma on CT scans (Fig. 4).

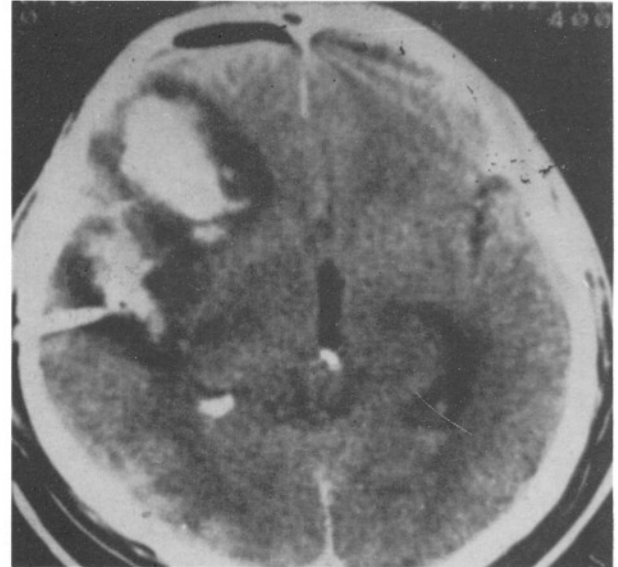


Fig. 2: Post-operative CT, twelve hours after the operation, showing the catheter in the haematoma

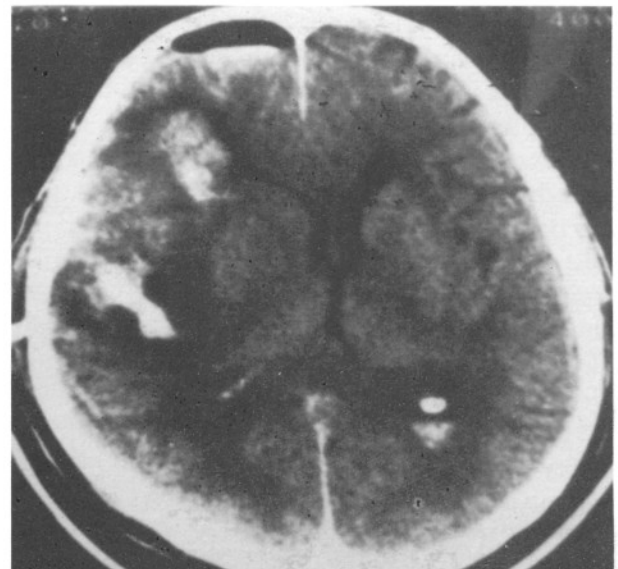


Fig. 3: CT appearance of the lesion on the fifth day post-operatively

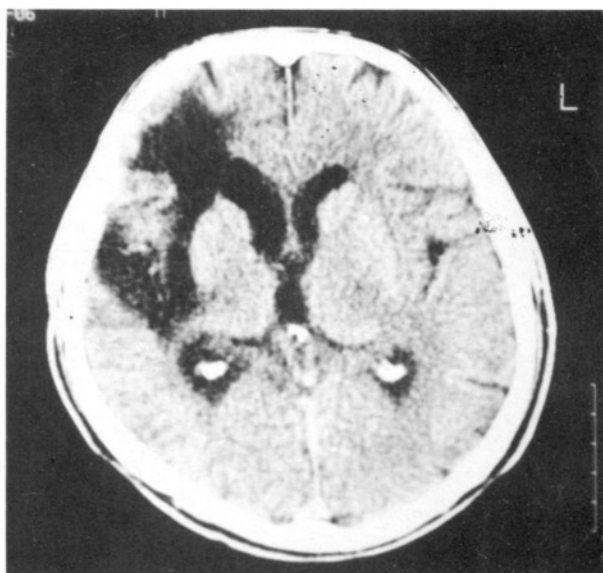


Fig. 4: Hypodense areas and encephalomalacic sequel of the haematoma in the CT taken three years later. He is back at work as a salesman without any assistance.

DISCUSSION

When one considers the occurrence of bleeding in the brain, within the context of thrombolytic therapy for MI, it appears that the premorbid condition of the brain vessels and the therapeutic perturbation introduced must have come into some kind of interplay, resulting in the extravasation of blood from vessels with the production of a clot in the parenchyma. The current recommendations for the selection of MI patients for thrombolytic therapy most probably exclude the great majority of the population with abnormal brain vessels. Initially, when the implications of this fact had not yet been fully realised, the thrombolysis in the Myocardial Infarction II Study Group found a sevenfold increased risk of intracranial haemorrhage in patients with a history of neurological disease versus patients without such a history (4). The present patient's history was unremarkable, except for smoking cigarettes for 30 years.

There are many thrombolytic agents for clinical use. Streptokinase, a bacterial product and urokinase, a product synthesized in liver and present in human urine are examples of first generation thrombolytic agents. Tissue plasminogen activator (tPA), a cloned

natural product, is one of the second generation thrombolytic agents. All thrombolytic agents convert plasminogen to plasmin, capable of lysing fibrinogen. Once the thrombus is formed, plasminogen accumulates where it contacts with fibrin. Products such as tPA are called "fibrin-specific", since they generate plasmin on the fibrin surface and do not affect the fibrinogen in circulation. Streptokinase is not fibrin-specific (2,6). Streptokinase was used in our patient. It has been known that the risk of intracerebral haemorrhage is 0.2 to 0.6% in both fibrin-specific and nonfibrin-specific agents (2,6).

It has been reported in different studies that most haemorrhages are in the lobar location (2,4,6), but epidural, subdural haematomas and intraventricular haemorrhage have also been reported after thrombolytic therapy (3,9). The haematoma was located in the fronto-parieto-temporal region in our case (Fig. 1).

Thrombolytic agent and heparin, if administered, should be stopped immediately, when haemorrhage occurs following thrombolytic therapy for acute MI. Administrations of 1mg protamine for 100 U heparin, 10 U cryoprecipitate, 2 units of fresh frozen plasma, platelet solution and an antifibrinolytic agent are advocated (4,6,9).

The aim of neurosurgical therapy is to save the patient's life and improve the chance of recovery from neurological deficits. Some authors advocate urgent craniotomy and haematoma evacuation after the neurological diagnosis is established (2,3). Coagulation disorders have to be corrected prior to craniotomy. Eleff et al. and Da Silva et al. operated on their cases with intracranial haematomas that had developed after thrombolytic therapy (2,3). Stereotactic aspiration of haematoma has been recently used particularly in the management of hypertensive intracerebral haematomas (5,7,8). We have already reported the results of 55 patients whose putaminal, thalamic, subcortical and cerebellar haematomas had been evacuated by this method using a thrombolytic agent of urakinase (1). More recent similar studies that report the use of recombinant-tissue-plasminogen activator in 14 patients with spontaneous ICH also encourage this method (9). The same technique was used in the present case who sustained a right fronto-parieto-temporal haematoma after thrombolytic therapy for acute MI. He was able to walk on his own on the 12th day after operation.

The number of neurosurgeons who use stereotactic evacuation of spontaneous intracerebral haematomas has been increasing, because it is less invasive than craniotomy and postoperative complications are minimal. We advocate the CT-guided free-hand or stereotactic removal of the haematoma especially in this rare form of complicated case.

Correspondence : Nezih Oktar M.D.

Ege niversitesi, Tıp Fakültesi Hast.,
Nöroşirürji A.D, Bornova-35100
İzmir, Türkiye
Telephone 232 388 30 42 / 3381

REFERENCES

1. Binatlı Ö, Övül İ, Oktar N, Öner K, Demirtaş E. CT-guided stereotactic aspiration and lysis of spontaneous intracerebral hematomas (Spontan intraserebral hematomların beyin tomografisi rehberliğinde stereotaksik yöntemle boşaltımı ve lizisi). J.Neurological Sciences (in Turkish) Nörol.Bil.D. 7:85-96, 1990.
2. Da Silva VF, Bormanis J. Intracerebral hemorrhage after combined anticoagulant-thrombolytic therapy for myocardial infarction: Two case reports and a short review. Neurosurgery 30:943-945, 1992.
3. Eleff SM, Borel C, Bell WR, Long DM: Acute management of intracranial hemorrhage in patients receiving thrombolytic therapy: Case reports. Neurosurgery 26:867-869, 1990.
4. Gore JM, Sloan M, Price TR, Randall AMY, Bovill E, Collen D, Forman S, Knatterud GL, Sopko G, Terrin ML, TIMI Investigators. Intracerebral hemorrhage, cerebral infarction, and subdural hematoma after acute myocardial infarction and thrombolytic therapy in the thrombolysis in myocardial infarction study. Circulation 83:448-459, 1991.
5. Itakura T, Komai N, Nakai E, Doi E. Stereotactic evacuation of hypertensive intracerebral hematoma using plasminogen activator. Surgical technique and long-term results. In: Suzuki J. Ed. Advances in Surgery for Cerebral Stroke Springer-Verlag, Tokyo, 1988: 443-448.
6. Kase CS, O'Neal AM, Fisher M, Girgis GN, Ordia JJ. Intracranial hemorrhage after use of tissue plasminogen activator for coronary thrombolysis. Annals of Internal Medicine 112:17-21, 1990.
7. Matsumoto K, Hondo H, Tomida K. Aspiration surgery for hypertensive brain hemorrhage in the acute stage. In: Suzuki J. Ed. Advances in Surgery for Cerebral Stroke Springer-Verlag, Tokyo, 1988: 433-441.
8. Niizuma H. Results of stereotactic aspiration in 175 cases of putaminal hemorrhage. Neurosurgery 24:814-819, 1989.
9. Schaller C, Rohde V, Meyer B, Hassler W: Stereotactic puncture and lysis of spontaneous intracerebral hemorrhage using recombinant tissue-plasminogen activator. Neurosurgery 36:328-335, 1995.
10. Sane DC, Califf RM, Topol EJ, Stump DC, Mark DB, Greenberg CS. Bleeding during thrombolytic therapy for acute myocardial infarction: Mechanisms and management. Annals of Internal Medicine 111:1010-1022, 1989.