



# Unusual Locations of Gangliogliomas: Intraventricular and Posterior Fossa

Adrian Mircea FURTOS<sup>1,2,3</sup>, Aurelia Mihaela SANDU<sup>2</sup>, Vasile Gheorghe CIUBOTARU<sup>2</sup>, Radu Mircea GORGAN<sup>1,2</sup>, Ligia Gabriela TĂȚĂRANU<sup>1,2</sup>

<sup>1</sup>University of Medicine and Pharmacy "Carol Davila" Bucharest, Romania

<sup>2</sup>Clinic of Neurosurgery, Emergency Clinical Hospital Bagdasar-Arseni, Bucharest, Romania

<sup>3</sup>Clinic of Neurosurgery, University Emergency Hospital Bucharest, Romania

**Corresponding author:** Aurelia Mihaela SANDU ✉ aurasandu@gmail.com

## ABSTRACT

**AIM:** To report a series of patients diagnosed with gangliogliomas (GG) in unusual locations; and to review the clinical and imaging features as well as surgical treatment and outcomes.

**MATERIAL and METHODS:** A series of consecutive patients who underwent surgery for GGs at unusual locations, such as intraventricular region and posterior fossa, from 2010 to 2022 were included in the study.

**RESULTS:** Nine patients with GGs located in unusual areas, one in the intraventricular region and 8 in the posterior fossa, were included. There were 5 males and 4 females, with a mean age  $31 \pm 8.5$  years. We performed GTR in 6 cases and STR in 3 cases. Seven tumors were grade I WHO while the remaining two were anaplastic. Five patients also had preoperative hydrocephalus. We found a positive correlation between midline GG of the posterior fossa and solid aspect of the tumor ( $p=0.05$ ). Univariate analysis found no other statistically significant associations, but this was due to the small patient sample. Recurrence was seen in 2 cases with STR, after 1 and 10 years, respectively.

**CONCLUSION:** GG should be considered in the differential diagnosis of patients with tumors in the intraventricular region or posterior fossa. Maximal tumor resection and restoration of CSF flow pathways ensure a good outcome. Growth patterns correlate with resection and can help choose the best candidates for surgery. However, further studies on large patient samples are needed.

**KEYWORDS:** Brain tumors, Ganglioglioma, Intraventricular, Posterior fossa

**ABBREVIATIONS:** CPA: Cerebellopontine angle, CSF: Cerebrospinal fluid, GG: Ganglioglioma, GTR: Gross total resection, LV: lateral ventricle, N/S: Not specified, STR: Subtotal resection, V3: Third ventricle, V4: Fourth ventricle, WHO: World Health Organization

## INTRODUCTION

Gangliogliomas (GGs) are rare primary brain malignancies, accounting for 0.4% of all central nervous system tumors (3,4,35,41). The majority of GGs are low-grade, well-defined, slow-growing neuroepithelial tumors, but aggressive types of anaplastic GGs can also occur. The first reports of GG in the literature were made by Perkins in 1926

(54), and Courville in 1930 (14). However, brainstem tumors with histopathological features suggestive of GG at autopsy were first described by Bielschowsky and Pick in 1911 (23,62).

GGs have a mixed histologic pattern, consisting of two cellular populations: neoplastic ganglion cells and neoplastic glial cells. Tumor growth is due to proliferation of glial cells. In low-grade GG the glial component is astrocytic,

Adrian Mircea FURTOS  : 0000-0002-5248-4743  
Aurelia Mihaela SANDU  : 0000-0002-0287-5201  
Vasile Gheorghe CIUBOTARU  : 0000-0002-7559-8241

Radu Mircea GORGAN  : 0000-0002-3246-9159  
Ligia Gabriela TĂȚĂRANU  : 0000-0002-3339-5817

pilocytic or fibrillary, with rare mitosis, and stigmas of slow growth, like Rosenthal fibers, eosinophilic granular bodies, microcysts, calcifications, reticulin network, perivascular lymphoid infiltrates and prominent glomeruloid capillary network. In anaplastic GG, the glial part presents mitosis, vascular proliferation, dense capillary network, and necrosis. Ganglionic cells are dysplastic with anaplastic changes being scarce. According to the 2016 WHO classification of tumors of the central nervous system, GGs are mixed neuro-glial tumors, divided into two categories: grade I and anaplastic grade III (39), but the latest 2021 WHO classification acknowledges only one entity of GGs (40). Nevertheless, new classifications have been proposed, dividing them into three histopathological entities: grade I, atypical and anaplastic (38).

Sex distribution for GGs is even (37) or with minimal preference for males (41). GGs occur in children and young adults, at a mean age of 26-36 years. (37,41) Classically, most patients present with long-term seizures (41), and symptoms that are indicative of the tumor's location. Imaging of GG is not definitive. A typical imaging result shows a well-circumscribed cystic lesion with a mural nodule. The solid part enhances contrast. No surrounding edema is usually observed but calcifications can sometimes be seen. Hemorrhagic transformation is unusual. Meanwhile, anaplastic GGs have a heterogeneous pattern, have strong contrast enhancement and are associated with surrounding edema.

Differential diagnosis is made in the case of pilocytic astrocytomas, oligodendrogliomas, dysembryoplastic neuroepithelial tumors, pleomorphic xanthoastrocytomas, desmoplastic infantile astrocytomas, gangliocytomas, astrocytomas, ependymomas, cortical dysplasias and hemangioblastomas.

GGs are usually found in the cerebral parenchyma, with the temporal lobe being the most common location (37,41,58). Unusual locations, such as the ventricular system, the cerebellum and the brainstem account for 4.3%, 7.7%, and 3% of all GG cases, respectively (37).

The treatment of choice is surgery, with the goal of complete tumor resection. Adjuvant therapies, like radiotherapy and chemotherapy, have been shown to be ineffective (58).

The aim of this study is to report a series of cases of GG with unusual locations, such as the intraventricular region and posterior fossa, and to review clinical and imaging features, surgical treatment and outcomes.

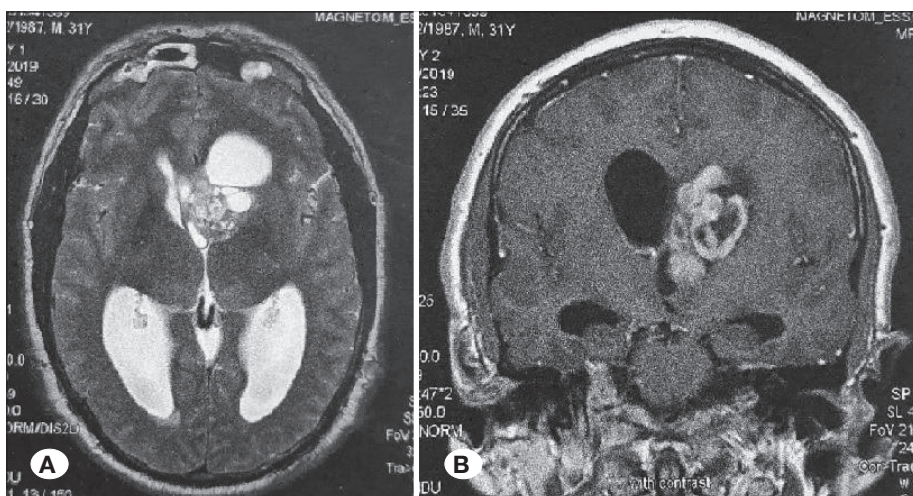
## MATERIAL and METHODS

We report a series of consecutive patients who underwent surgery for GGs at unusual locations, such as intraventricular region and posterior fossa. We included cases with positive histopathological exams for GG (histology codes M9505/1, and M9505/3 – ICD-O-3 International Classification of Diseases for Oncology, 3rd edition), from 2010 to 2022. Cases with GG arising from the parenchyma and extending into the intraventricular region and patients who underwent surgery solely for hydrocephalus were excluded. Patients with dysplastic gangliocytoma of the cerebellum Lhermitte-Duclos were also excluded. The study was approved by the hospital Ethics Committee of Spitalul Clinic de Urgenta “Bagdasar-Arseni” (No: 42914, Date: December 2022). Statistical analysis was done using SPSS IBM®.

## RESULTS

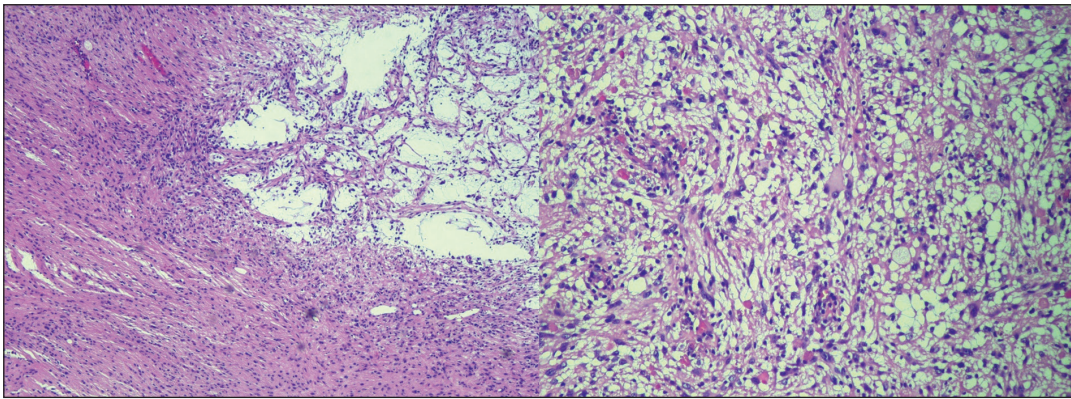
Nine patients with unusual GG locations were identified. Specifically, we found one case of intraventricular GG (Case 1, Figures 1-3) and 8 cases of GG in the posterior fossa (Cases 2-9, Figures 4-6). The main features of these patients are summarized in Table I. There were 5 males and 4 females and the mean age was  $31 \pm 8.5$  years (ranging from 20 - 46 years of age). Mean hospital stay was  $16.89 \pm 6.214$  months. Timing from onset to positive diagnosis varied from one month to 24 years.

According to tumor location, we divided patients with posterior fossa GGs into three categories: cerebellar midline (vermian and paravermian), brainstem (brainstem and V4), and lateral posterior fossa (cerebellar hemisphere and CPA). We found a correlation between location and imaging features: solid vs. solid-cystic ( $U=1.5$ ,  $p=0.05$ ), solid GG being more likely found in the midline (brainstem and cerebellar midline), while solid-cystic tumors were found in lateral locations. All GGs displayed

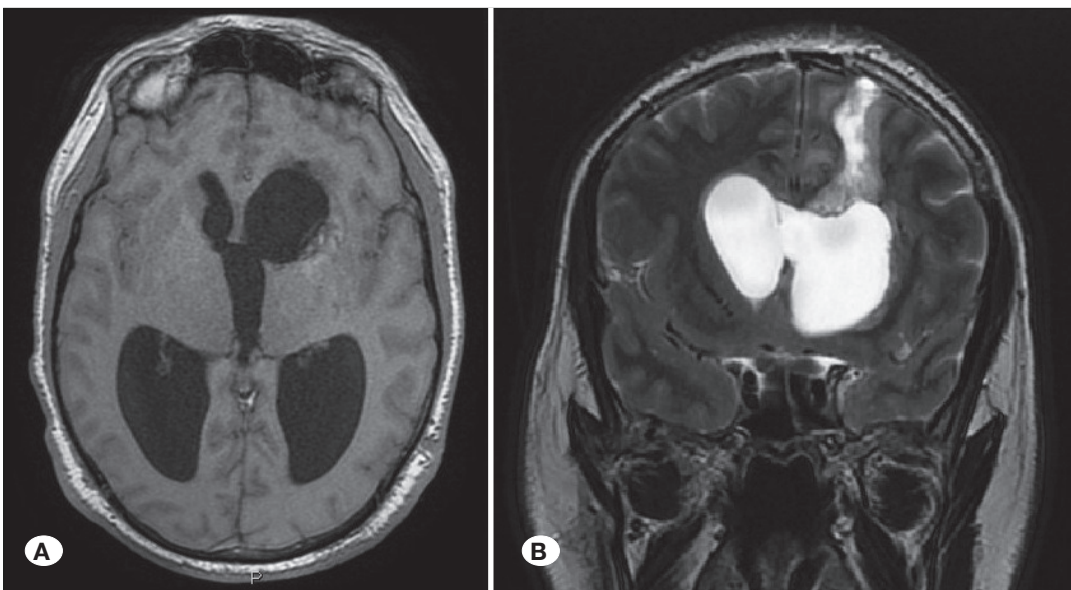


**Figure 1:** Case 1 - intraventricular ganglioglioma. Preoperative axial T2W (A) and coronal T1W contrast enhanced (B) MRI scans: left LV tumor, extending into V3, ventriculomegaly.

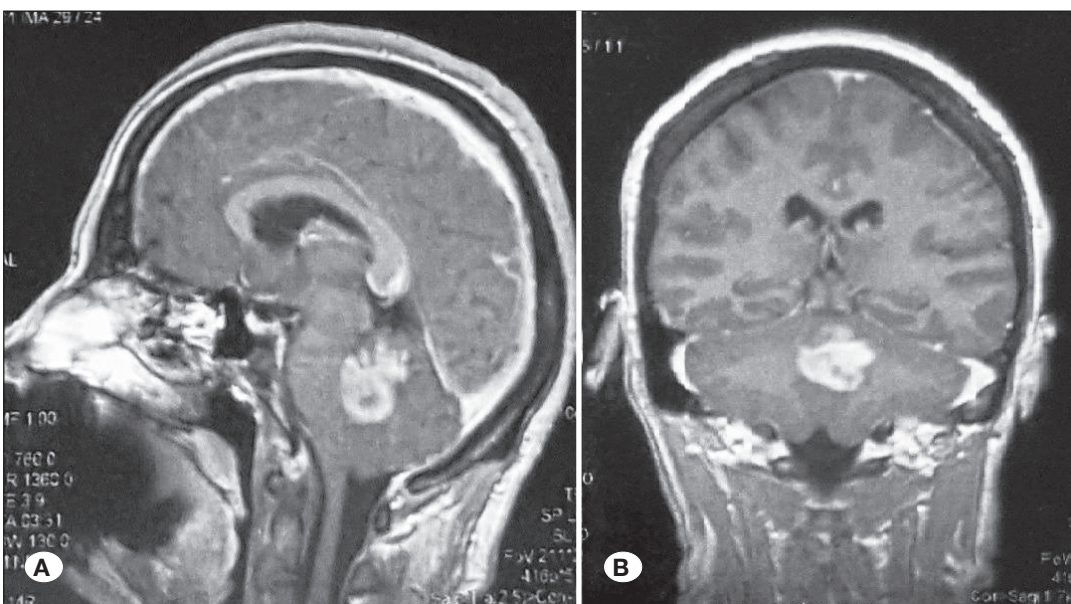




**Figure 2:** Case 1 - intraventricular ganglioglioma. Histopathological examination revealed anaplastic GG WHO Grade III. Biphasic aspect, large, multinucleate tumor cells.

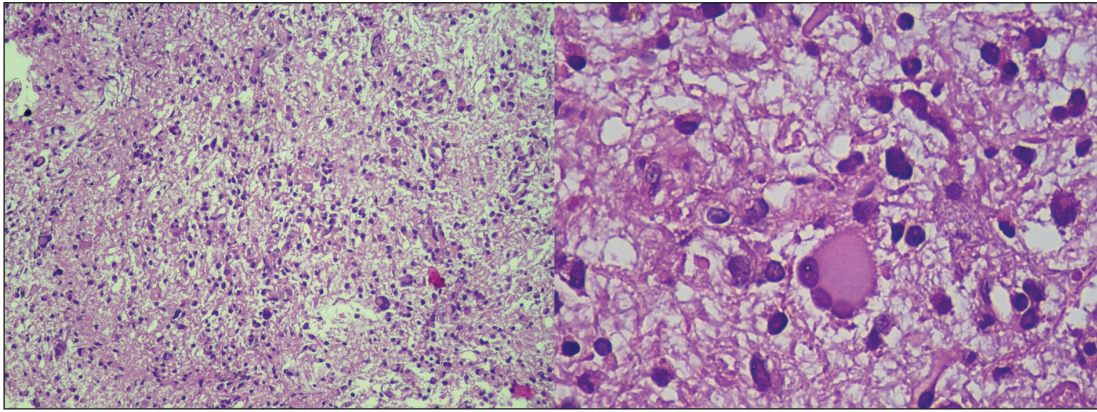


**Figure 3:** Case 1 - intraventricular ganglioglioma. Postoperative T1W axial (A) and T2W coronal (B) MRI scans showing: complete resection via transcortical approach.

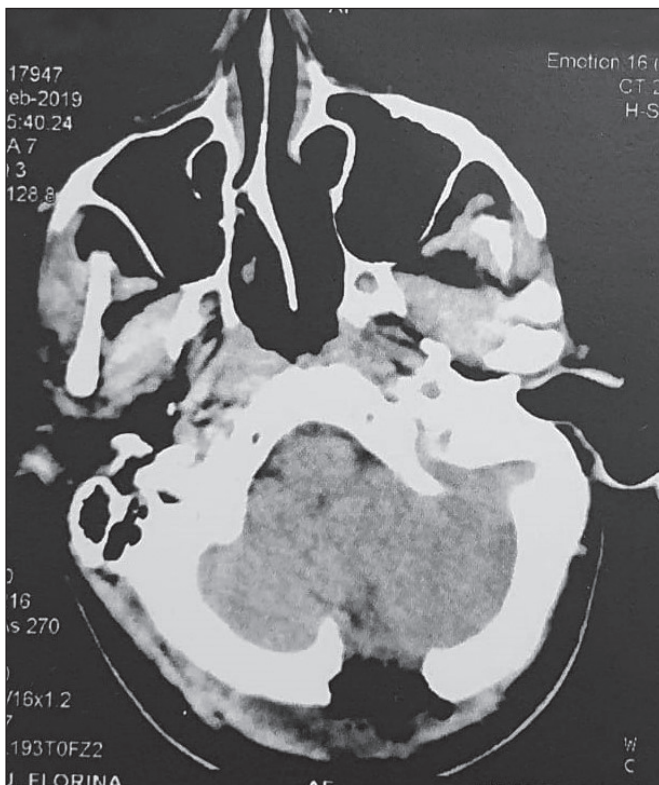

**Figure 4:** Case 7 - posterior fossa ganglioglioma. Preoperative sagittal (A) and coronal (B) T1W contrast enhanced MRI scans. Midline contrast enhancing vermian tumor.





**Figure 5:** Case 7 - posterior fossa ganglioglioma. Histopathological examination revealed GG WHO Grade I. Ganglionic cells in glial stroma, ganglionic multinucleate tumor cell (detail).



**Figure 6:** Case 7 - posterior fossa ganglioglioma. Postoperative axial CT scan showed complete resection via suboccipital craniectomy.

enhanced contrast, either homogenous or inhomogeneous. There was no correlation between tumor location and the pattern of contrast enhancement ( $U=2$ ,  $p=0.061$ ). We found no associations between tumor volume and imaging aspect ( $U=3$ ,  $p=0.180$ ) or contrast enhancement ( $U=3$ ,  $p=0.149$ ). None of the tumors presented with surrounding edema.

Extent of resection was defined as GTR (complete resection of the whole tumor as detected on postoperative MRI) or STR (resection of  $> 50\%$  of tumor). The resection grade was not associated with tumor size ( $U=8$ ,  $p=0.796$ ), but rather with the tumor location. GTR was achieved in all patients with cerebellar tumors while STR was done in challenging

locations such as the brainstem, and in a very large tumor from the CPA. Further, tumor size was not associated with hydrocephalus ( $U=4$ ,  $p=0.142$ ), histopathological grade ( $U=2$ ,  $p=0.143$ ) or postoperative complications ( $U=8$ ,  $p=0.796$ ). Five patients had enlarged ventricles at diagnosis; one required ventriculoperitoneal shunt before tumor surgery due to acute hydrocephalus, and in another one it was done after tumor surgery due to the persistence of symptoms of intracranial hypertension. Two patients developed early complications. One patient developed a CSF fistula, which resolved in a few days with CSF drainage. Another patient with brainstem GG had a less favorable outcome. Immediately after surgery the patient was fully awake, without any motor deficits, but with transient respiratory failure, which required mechanical ventilation. After a few days she was extubated, with no signs of respiratory failure, but on the 13<sup>th</sup> day of hospitalization she suffered a sudden and irreversible cardiac arrest. Finally, another patient developed late hydrocephalus 4 months after surgery, which required a ventriculoperitoneal shunt, with good outcome. The follow-up period varied from 2 to 11 years. During this period of time, tumor recurrence was noticed in two patients with STR. Recurrence timing was 1 year in grade III GG and 10 years in grade I GG.

## DISCUSSION

In the literature there are few large cohort studies on GGs. So far, the largest study included 703 adult patients with low-grade GG, from the Surveillance, Epidemiology, and End Results (SEER) database from 2004 to 2016 (37). Another large study reviewed all reports published from 1978 to 2007 and included 402 patients, both children and adults, harboring both low and high grade tumors (58). Other large studies gathering information on hundreds of cases were published by Blümcke and Wiestler (6), Luyken et al. (41), Dudley et al. (21), and Varshneya et al. (73), among others.

GGs are intriguing tumors with a histopathological hallmark of dual cellularity, consisting of both glial and neuronal cells. The tumor may exhibit either mainly neuronal or glial phenotype. The latest theory regarding the origin of GGs is that they arise from prior malformative or dysplastic lesions, in which neoplastic transformation of the glial component occurs (6). This theory is supported by a low-malignancy,

Table I: Patients with GG with Unusual Locations

No	Sex, age	Location	Signs & symptoms	Tumor size (mm)	Imaging	Hydro-cephalus	Resection type	HP grade	Postoperative complications	Recurrence
1	M, 31 y	LV + V3	Headache, gait disturbances, brachial paresthesia, memory loss, singultus	40/40/20	Solid-cystic, inhomogeneous, contrast enhancing	+	GTR	III	-	-
2	M, 22 y	cerebellum paravermian	Headache, vertigo, gait ataxia	28/24/23	Solid, homogenous, contrast enhancing	-	GTR	I	-	-
3	M, 22 y	cerebellum, vermis	Headache, nausea, vomiting, gait ataxia	20/20/25	Solid, homogenous, contrast enhancing	+	GTR	I	-	-
4	F, 34 y	brainstem, V4	Headache, nausea, tinnitus, otalgia, visual loss	24/22/20	Solid, homogenous, contrast enhancing	-	STR	I	death	n/a
5	M, 31 y	cerebellum	Headache, limb ataxia, dysmetria, dysfonia	30/25/20	Solid-cystic, inhomogeneous, contrast enhancing	-	GTR	I	-	-
6	M, 36 y	cerebellum paravermian	Headache, vomiting, truncal and limb ataxia, gait disturbance, dysmetria, hypotonia, hypokinesia, urinary incontinence, memory loss	47/45/43	Solid-cystic, inhomogeneous, contrast enhancing	+	GTR	I	CSF fistula	-
7	F, 46 y	vermis	Headache, dizziness, gait disturbance, truncal ataxia	33/30/26	Solid, inhomogeneous, contrast enhancing	-	GTR	I	hydrocephalus	-
8	F, 20 y	CPA	Headache, vomiting, facial palsy, dysmetria	57/40/26	Solid-cystic, inhomogeneous, contrast enhancing	+	STR	III	-	+
9	F, 37 y	brainstem, V4	Headache, dizziness, nausea, vomiting, memory loss, Parinauld syndrome	33/30/26	Solid, homogeneous, contrast enhancing	+	STR	I	-	+

**M:** Male, **F:** Female, **y:** years.

well-differentiated glioneuronal phenotype, immunoreactivity for stem cell epitope CD34, a slow-growing pattern, and a long-term, benign history (6). GGs exhibit a broad variety of morphological changes, with three types of histological growth patterns: relatively well-circumscribed, infiltrative and combined model (1). Most GGs express the stem cell epitope CD34 (6). Further, molecular analyses have shown that GG harbor genetic mutations that activate the MAP kinase pathway (53). BRAF p.V600E mutations are often encountered and are associated with tumor regrowth (13,26). In addition, genetic studies using trypsin-Giemsa staining and spectral karyotyping, found deletions on chromosomes 10, 13 and 22, gains in chromosomes 5, 7, 8 and 12, the unbalanced non-reciprocal translocation t(1;18)(q21;q21) and a ring chromosome 1 (75).

In addition to their typical temporal lobe location, GG can occur less frequently in other parts of the brain, such as parietal or frontal lobes, thalamus and hypothalamus, ventricular system, pituitary stalk, optic pathways, pineal gland, cerebellum, brainstem and spinal cord (52,53,59,62). Regarding unusual locations, current knowledge is limited to case reports or very small series of patients. Hence, reports on the correlation of GG and unusual locations provide better understanding of tumor behavior. GGs with unusual locations also present a specific clinical pattern, characterized by the absence of long-term epilepsy, and the presence of symptoms that mirror tumor locations. In our series of cases, age, sex ratio and imaging features are consistent with the literature.

### Intraventricular GGs

Supratentorial pure intraventricular GGs are very rare. They can be located in one or both LV and/or in V3. A literature review found only 40 cases published so far, with our case being the 41<sup>st</sup> (Table II). This is the most comprehensive literature review so far.

The origin of pure intraventricular GG is believed to be from the ventricular walls or choroid plexus (32). The clinical pattern of intraventricular GGs is primarily dominated by obstruction of CSF pathways and resulting intracranial hypertension. Other clinical features are memory loss, fatigue, loss of vision, pituitary failure, and diabetes insipidus. Rarely intraventricular GGs may present with sudden onset due to acute spontaneous intratumoral bleeding (5,9,74). Dissemination along the CSF pathways is unusual. Few and far between case reports with synchronous GG, such as LV and optic chiasm (18), or LV and sacral drop metastases(69), have been published.

Technical challenges include a long and narrow surgical corridor. We recommend maximal tumor resection with restoration of CSF flow as the first stage of surgery, as in most cases hydrocephalus resolves on its own. The persistence of acute hydrocephalus after tumor surgery is caused by intraventricular bleeding, remaining tumor tissue or infection. Treatment for secondary hydrocephalus can be carried out as a first step surgery in patients with acute symptoms, but it carries risks such as cerebral herniation, tumor bleeding, and tumor swelling, among others.

### Posterior Fossa GGs

Posterior fossa GGs are also rare, with most findings being case reports. However, many authors have conducted comprehensive literature reviews. In 2007, Safavi-Abbasi et al. reported one case and found another 70 patients with posterior fossa GGs, from 1911 to 2007 (62). In 2013, Gopalakrishnan et al. reported one case of brainstem GG in a child and found another 33 previously reported cases of brainstem GGs in children, from 1932 to 2009 (25). Puget et al. performed a comprehensive review of the literature and found 100 brainstem GGs and 80 cerebellar GGs in children (56). In 2014, Gupta et al. reported a histologic study in 22 patients with posterior fossa GGs (26). Janjua et al. performed a systematic review over 50 years, and found 142 brainstem GGs across 46 studies (33). Posterior fossa GGs are more frequent among the pediatric population (27,57).

Posterior fossa GGs may originate in the cerebellar hemispheres, vermis, cerebellar peduncles, CPA, brainstem, fourth ventricle, and cervicomedullary junction. Clinical presentation depends on the location of the tumor, and includes cerebellar syndrome, ataxia, gait disturbances, incoordination, cranial nerves deficits, long tract dysfunctions, nystagmus, and intracranial hyperpressure. As in intraventricular GG, classic symptoms, such as long-term epilepsy are not found. A few cases of epilepsy have been reported in the literature with a particular seizure (11,28,46,47,49). Development of cerebellar seizures is still debatable, but EEG monitoring shows seizure discharges arising from cerebellum (11,28,47). Intratumoral hemorrhage is rare (34).

Regarding location and tumor type, we found correlation between tumor site and imagistic appearance. However, while we observed a higher prevalence of solid tumors in the midline, other authors have reported a positive association between midline tumors and a cystic appearance (26). Nevertheless, midline tumors were associated with glial matrix composed by neoplastic astrocytes and presence of BRAF p.V600E mutation (26,53). Immunoreactivity for stem cell epitope CD34 also varies with location; most CD34 positive tumors have been found in the temporal lobe, whereas GGs in other brain regions were CD34 negative (6).

As a grade I, slow-growing tumor, GGs have good survival outcomes. Optimal treatment should be the top priority, with the goal of achieving maximal resection and restoring normal CSF flow, gold standard objectives, which ensure a good outcome. While cerebellar GGs are easily accessible for surgery, GTR of brainstem lesions is challenging. Our study found that tumor size was not a factor in determining the extent of resection. The ability to achieve complete resection was related to the tumor's location and the difficulty of the surgery. Locations that are more accessible, such as the cerebellum, do not pose significant challenges for GTR, while resection of brainstem GGs may be hindered by the vicinity of eloquent cortex. In our study, in both patients with brainstem GGs, the tumors had a dorsal exophytic component protruding into the V4. Surgery was possible through a transvermian approach, for resecting only the exophytic component occupying the V4. This provided a tissue sample for histopathological examination



**Table II:** Supratentorial Intraventricular GG – Review of the Literature

No.	Author	Year	No. of cases	Patients' features	Location	Surgery
1	Doyle and Kernohan (20)	1931	1	F, 13 y	V3	N/S
2	Anderson ve Adelstein (2)	1942	1	-	V3	N/S
3	Russell and Rubinstein (61)	1962	1	F, 26 y	LV	N/S
4	Silver et al. (68)	1991	1	M, 33 y	LV	STR
5	Majós et al. (43)	1998	1	M, 71 y	LV	GTR
6	Matsumoto et al. (45)	1999	2	M, 10 y	LV	STR
7				F, 31 y	LV	STR
8	Yin Foo Lee et al. (76)	2001	1	F, 25 y	LV	GTR
9	Jaeger et al. (32)	2001	1	F, 20 y	LV	GTR
10	Nair et al. (51)	2004	1	F, 65 y	LV	N/S
11	Shono et al. (67)	2007	2	F, 34 y	V3	GTR
12				M, 52 y	V3	GTR
13	Hauck et al. (29)	2008	1	F, 20 y	V3	GTR
14	Samdani et al. (64)	2009	1	M, 18 y	LV	GTR
15	Bhat et al. (5)	2010	1	M, 27 y	LV	GTR
16	d'Andrea et al. (15)	2011	1	M, 22 y	LV	GTR
17	Deling et al. (19)	2013	7	M, 28 y	LV	GTR
18				M, 15 y	V3	GTR
19				F, 15 y	LV	GTR
20				M, 54 y	LV	GTR
21				F, 13 y	LV	GTR
22				M, 27 y	V3	GTR
23				M, 13 y	LV	GTR
24	Gonçalves et al. (24)	2014	2	M, 38 y	V3	N/S
25				F, 10 y	LV	N/S
26	de Castro et al. (18)	2014	1	F, 10 y	LV	N/S
27	Zhao et al. (77)	2015	1	M, 12 y	V3+LV	STR
28	Prasad et al. (55)	2016	1	F, 15 y	V3	STR
29	Higa et al. (31)	2016	1	F, 38 y	V3	STR
30	Syed et al. (69)	2016	1	M, 49 y	LV	GTR
31	Maiti et al. (42)	2016	1	M, 20 y	V3	GTR
32	Warnica and Provias (74)	2017	1	F, 23 y	LV	STR
33	Miyake et al. (50)	2017	1	M, 21 y	V3	STR
34	de Abreu et al. (17)	2018	1	F, 26 y	V3+LV	N/S
35	Campos et al. (9)	2018	1	M, 33 y	LV	GTR
36	Chatrath et al. (12)	2019	1	F, 13 y	LV	STR
37				F, 10 y	V3+LV	STR
38	Timble et al. (71)	2020	1	F, 67 y	LV	GTR
39	Salge-Arrieta et al. (63)	2021	3	M, 41 y	LV	STR
40				M, 25 y	V3	STR
41	Our case	2022	1	M, 31 y	V3+LV	GTR

**M:** Male, **F:** Female, **y:** year.

and prevented the development of hydrocephalus. Resection of the focal endophytic or diffuse infiltrative tumors can be done but with high risks due to the long surgical corridor, vicinity of eloquent brain and lack of a clear boundary around the tumor. Grade I GGs and GTR are associated with a low risk of recurrence (41). Even if complete resection is not possible, prognosis remains good for grade I gliomas. Moreover, GTR has no impact on survival in these cases (41). Considering the slow-growing nature of the tumor, in patients with incomplete resection, we recommend a wait-and-watch approach for diffuse infiltrative or endophytic brainstem GG. Radiotherapy is not recommended. The seizure-free period, a common indicator for quality of life after surgery in classic GG (7), does not apply to these locations.

Anaplastic GG can appear *de novo* or through dedifferentiation of the glial part of a preexisting tumor. Neuroblastomatous malignant transformation is exceptionally rare (16,70). In 2018, Bouali et al. reported a malignant posterior fossa GG and found another 11 patients with the same histological features in the literature, from 1992 to 2012 (8). Grade III anaplastic gliomas exhibit a more aggressive behavior compared to other types of gliomas. However, they have a better prognosis than other high-grade brain gliomas (22). Anaplastic GGs have a tendency to recur after STR (36). After STR, adjuvant treatment should be tailored according to histological grade and growth kinetics studies (36). In our series of cases, one of the two patients with grade III GG had 1-year recurrence and the second had a short follow-up period of only 2 years, so we cannot conclude whether he will be a long-term survivor.

However, if the role of surgery is undebatable, the efficiency of other therapeutical options is inconclusive. Initially, radiotherapy was proposed for brainstem GG, but nowadays its use has been limited because of its poor radiosensitivity and the long-term deleterious side-effects of irradiation in young patients. Some authors even describe malignant dedifferentiation of the glial (30,60,66), or neuronal components (70) after radiotherapy. Radiotherapy has a negative impact on prognosis and survival (10,37). It is limited only to patients with unresectable progressive disease or anaplastic GG (56,65). Stereotactic radiosurgery seems to improve results in residual, recurrent or inaccessible GG (44,72). Genetic studies may be useful for developing target therapies. Lately, targeted therapies against BRAF p.V600E mutation seem to be promising (48), and they may be used in selected patients with a high surgical risk or to prolong recurrence-free survival.

The main limitation of this study is the small patient sample size without a comparison group, making it prone to bias which results in a lack of statistical significance. Our study has level IV evidence. However, the paucity of intraventricular or posterior fossa GG limits the possibility of conducting large studies. To gain a better understanding, systematic reviews that include case reports or series of cases may be useful.

## CONCLUSION

GG should be considered in the differential diagnosis of patients with intraventricular tumors or in the posterior fossa.

Patients with GGs in these unusual locations have a different clinical pattern, such as the fact that a solid aspect is common in midline GGs of the posterior fossa. Regarding treatment, successful outcomes are more likely with maximal tumor resection and restoration of CSF flow pathways. The growth pattern of the tumor is related to the extent of resection and can aid in selecting the best candidates for surgery. Cerebellar GGs are suitable for complete resection. Further, surgery may also be beneficial for exophytic brainstem GGs growing through the floor of the V4. However, further studies on larger samples are needed.

## ACKNOWLEDGMENTS

Adrian Mircea Fürtös is a PhD student at University of Medicine and Pharmacy “Carol Davila” Bucharest, Romania.

### AUTHORSHIP CONTRIBUTION

Study conception and design: AMF, AMS, LGT

Data collection: AMF, AMS

Analysis and interpretation of results: AMF, AMS

Draft manuscript preparation: AMF, AMS

Critical revision of the article: AMF, AMS, VGC, RMG

Other (study supervision, fundings, materials, etc.): VGC, RMG, LGT

All authors (AMF, AMS, VGC, RMG, LGT) reviewed the results and approved the final version of the manuscript.

## REFERENCES

- Alturkustani M: Classification of pediatric gangliogliomas based on the histological infiltration. *Curr Oncol* 29:6764-6775, 2022
- Anderson F, Adelstein LJ: Ganglion cell tumor (ganglioglioma) in the third ventricle: operative removal with clinical recovery. *Arch Surg* 45:129-139, 1942
- Becker A, Wiestler O, Figarella-Branger D, Blümcke I, Capper D: Anaplastic ganglioglioma. In: Louis D, Ohgaki H, Wiestler O, Cavenee W (eds), *WHO Classification of Tumours of the Central Nervous System*. IARC Lyon, 2016:141
- Becker A, Wiestler O, Figarella-Branger D, Blümcke I, Capper D: Ganglioglioma. In: Louis D, Ohgaki H, Wiestler O, Cavenee W (eds), *WHO Classification of Tumours of the Central Nervous System*. IARC Lyon, 2016:138-141.
- Bhat D, Mahadevan A, Manish R, Sampath S, Chandramouli B, Shankar SK: Intraventricular ganglioglioma with bleed: A rare case report. *Neurol India* 58:477-480, 2010
- Blümcke I, Wiestler O: Gangliogliomas: An intriguing tumor entity associated with focal epilepsies. *J Neuropathol Exp Neurol* 61:575-584, 2002
- Bonney P, Glenn C, Ebeling P, Conner A, Boettcher L, Cameron D, Battiste J, Sughrue M: Seizure freedom rates and prognostic indicators after resection of gangliogliomas: A review. *World Neurosurg* 84:1988-1996, 2015
- Bouali S, Maatar N, Zehani A, Mahmoud M, Kallel J, Jemel H: A case of adult anaplastic cerebellar ganglioglioma. *Surg Neurol Int* 9:31-31, 2018



9. Campos A, Biscoito L, Gasparinho M: Intraventricular ganglioglioma presenting with spontaneous hemorrhage. *Acta Med Port* 31:170-175, 2018
10. Celli P, Scarpinati M, Nardacci B, Cervoni L, Cantore G: Gangliogliomas of the cerebral hemispheres. Report of 14 cases with long-term follow-up and review of the literature. *Acta Neurochir (Wien)* 125:52-57, 1993
11. Chae J, Kim S, Wang K, Kim K, Hwang Y, Cho B: Hemifacial seizure of cerebellar ganglioglioma origin: Seizure control by tumor resection. *Epilepsia* 42:1204-1207, 2001
12. Chatrath A, Mastorakos P, Mehta G, Wildeman M, Moosa S, Jane Jr J: Ganglioglioma arising from the septum pellucidum: Case report and review of the literature. *Pediatr Neurosurg* 54:36-45, 2019
13. Chen X, Pan C, Zhang P, Xu C, Sun Y, Yu H, Wu Y, Geng Y, Zuo P, Wu Z, Zhang J, Zhang L: BRAF V600E mutation is a significant prognosticator of the tumour regrowth rate in brainstem gangliogliomas. *J Clin Neurosci* 46:50-57, 2017
14. Courville C: Ganglioglioma tumor of the central nervous system: Review of the literature and report of two cases. *Arch Neurol Psych* 24:439-491, 1930
15. d'Andrea G, Sessa G, Ferrante L: Ganglioglioma of the right lateral ventricle approached with neuronavigation and intraoperative DTI. Case report and literature review. *Cent Eur Neurosurg* 72:196-200, 2011
16. David K, de Sanctis S, Lewis P, Noury A, Edwards J: Neuroblastomatous recurrence of ganglioglioma. Case report. *J Neurosurg* 93:698-700, 2000
17. de Abreu P, Muniz B, Ventura N, Gasparetto E, Marchiori E: Intraventricular ganglioglioma with dissemination of cerebrospinal fluid. *Radiol Bras* 51:272-273, 2018
18. de Castro F, Reis F, Guerra J: Intraventricular mass lesions at magnetic resonance imaging: Iconographic essay - part 1. 47:176-181, 2014
19. Deling L, Nan J, Yongji T, Shuqing Y, Zhixian G, Jisheng W, Liwei Z: Intraventricular ganglioglioma prognosis and hydrocephalus: The largest case series and systematic literature review. *Acta Neurochir (Wien)* 155(7):1253-1260, 2013
20. Doyle J, Kernohan J: Ganglioneuroma of the third ventricle with diabetes insipidus and hypopituitarism. *J Nerv Ment Dis* 73:55-61, 1931
21. Dudley R, Torok M, Gallegos D, Mulcahy-Levy J, Hoffman L, Liu A, Handler M, Hankinson T: Pediatric low-grade ganglioglioma: epidemiology, treatments, and outcome analysis on 348 children from the surveillance, epidemiology, and end results database. *Neurosurgery* 76:313-319, 2015
22. Erguvan-Onal R, Onal C, Aydin N: Anaplastic gangliogliomas: Is it a sign of better prognosis? *Sinir Sistemi Cerrahisi Derg* 2:72-78, 2009
23. Garcia C, McGarry P, Collada M: Ganglioglioma of the brain stem. Case report. *J Neurosurg* 60:431-434, 1984
24. Gonçalves V, Reis F, Bertanha R, Queiroz L, Rogério F, França Junior M: Intraventricular gangliogliomas: Two case reports-two distinct patterns of intraventricular gangliogliomas. *Int J Radiol Radiant Oncol* 1:651, 2014
25. Gopalakrishnan C, Shrivastava A, Nair S, Radhakrishnan N: Brainstem ganglioglioma in an infant: Case report and review of literature. *J Pediatr Neurosci* 8:41-45, 2013
26. Gupta K, Orisme W, Harreld J, Qaddoumi I, Dalton J, Punchihewa C, Collins-Underwood R, Robertson T, Tatevossian R, Ellison D: Posterior fossa and spinal gangliogliomas form two distinct clinicopathologic and molecular subgroups. *Acta Neuropathol Commun* 2:18-18, 2014
27. Harrison W, Elsamadicy A, McMahon J, Chagoya G, Sobel R, McLendon R, Adamson C: Glioneuronal tumor with features of ganglioglioma and neurocytoma arising in the fourth ventricle: a report of 2 unusual cases and a review of infratentorial gangliogliomas. *J Neuropathol Exp Neurol* 78:780-787, 2019
28. Harvey A, Jayakar P, Duchowny M, Resnick T, Prats A, Altman N, Renfro J: Hemifacial seizures and cerebellar ganglioglioma: An epilepsy syndrome of infancy with seizures of cerebellar origin. *Ann Neurol* 40:91-98, 1996
29. Hauck E, Vu L, Campbell G, Nauta H: Intraventricular ganglioglioma. *J Clin Neurosci* 15:1291-1293, 2008
30. Hayashi Y, Iwato M, Hasegawa M, Tachibana O, von Deimling A, Yamashita J: Malignant transformation of a gangliocytoma/ganglioglioma into a glioblastoma multiforme: A molecular genetic analysis. Case report. *J Neurosurg* 95:138-142, 2001
31. Higa N, Yonezawa H, Oyoshi T, Hiraki T, Hirano H, Arita K: Ganglioglioma in the third ventricle: a case report and literature review. *NMC Case Rep J* 3:97-101, 2016
32. Jaeger M, Hussein S, Schuhmann M, Brandis A, Samii M, UB: Trigonal ganglioglioma arising from the choroid plexus. *Acta Neurochir (Wien)* 143:953-955, 2001
33. Janjua M, Ivasyk I, Pisapia D, Souweidane M: Ganglioglioma of brain stem and cervicomedullary junction: A 50years review of literature. *J Clin Neurosci* 44:34-46, 2017
34. Jeevan DS, Neil JA, Mohan A, Tobias M: Hemorrhagic ganglioglioma of the posterior fossa: case report. *Pediatr Neurosurg* 49:33-37, 2013
35. Kalyan-Raman U, Olivero W: Ganglioglioma: A correlative clinicopathological and radiological study of ten surgically treated cases with follow-up. *Neurosurgery* 20:428-433, 1987
36. Krouwer H, Davis R, McDermott M, Hoshino T, Prados M: Gangliogliomas: A clinicopathological study of 25 cases and review of the literature. *J Neurooncol* 17:139-154, 1993
37. Lin X, Huang R, Zhang P, Sun J, Dong G, Huang Y, Tian X: Low-grade gangliogliomas in adults: A population-based study. *Cancer Med* 10:416-423, 2021
38. Lisievici A, Pasov D, Georgescu T, Lisievici M, Sajin M: A novel histopathological grading system for ganglioglioma. *J Med Life* 14:170-175, 2021
39. Louis D, Perry A, Reifenberger G, von Deimling A, Figarella-Branger D, Cavenee W, Ohgaki H, Wiestler O, Kleihues P, Ellison D: The 2016 World Health Organization Classification of tumors of the central nervous system: A summary. *Acta Neuropathologica* 131:803-820, 2016
40. Louis D, Perry A, Wesseling P, Brat D, Cree I, Figarella-Branger D, Hawkins C, Ng H, Pfister S, Reifenberger G, Soffietti R, von Deimling A, Ellison D: The 2021 WHO Classification of Tumors of the central nervous system: A summary. *Neuro-Oncol* 23:1231-1251, 2021

41. Luyken C, Blümcke I, Fimmers R, Urbach H, Wiestler O, Schramm J: Supratentorial gangliogliomas: Histopathologic grading and tumor recurrence in 184 patients with a median follow-up of 8 years. *Cancer* 101:146-155, 2004
42. Maiti T, Arimappamagan A, Mahadevan A, Pandey P: Ganglioglioma of the posterior third ventricle region: An unusual pathology in an uncommon location. *Neurol India* 64:349-351, 2016
43. Majós C, Aguilera C, Ferrer I, López L, Pons L: Intraventricular ganglioglioma: Case report *Neuroradiology* 40:377-379, 1998
44. Mantziaris G, Diamond J, Pikis S, El Hefnawi F, Al Sideiri G, Coupé F, Mathieu D, Lee C, May J, Liščák R, Peker S, Samanci Y, Niranjana A, Lunsford L, Sheehan J: Radiological and clinical outcomes of stereotactic radiosurgery for gangliogliomas: An international multicenter study. *J Neurosurg* 25:1-6, 2022
45. Matsumoto K, Tamiya T, Ono Y, Furuta T, Asari S, Ohmoto T: Cerebral gangliogliomas: Clinical characteristics, CT and MRI. *Acta Neurochir (Wien)* 141:135-141, 1999
46. McLone D, Stieg P, Scott R, Barnett F, Barnes P, Folkherth R: Cerebellar epilepsy. *Neurosurgery* 42:1106-1111, 1998
47. Mesiwala A, Kuratani J, Avellino A, Roberts T, Sotero M, Ellenbogen R: Focal motor seizures with secondary generalization arising in the cerebellum. Case report and review of the literature. *J Neurosurg* 97:190-196, 2002
48. Miller K, Schieffer K, Grischow O, Rodriguez D, Cottrell C, Leonard J, Finlay J, Mardis E: Clinical response to dabrafenib plus trametinib in a pediatric ganglioglioma with BRAF p.T599dup mutation. *Cold Spring Harb Mol Case Stud* 7:a006023, 2021
49. Mink J, Caruso P, Pomeroy S: Progressive myoclonus in a child with a deep cerebellar mass. *Neurology* 61:829-831, 2003
50. Miyake Y, Mishima K, Suzuki T, Adachi J, Nishikawa R: Hemorrhagic ganglioglioma of the third ventricle with atypical pathological findings. *Brain Tumor Pathol* 34:135-137, 2017
51. Nair V, Suri V, Tatke M, Saran R, Malhotra V, Singh D: Gangliogliomas: A report of five cases. *Indian J Cancer* 41:41-46, 2004
52. Omofoye O, Lechpammer M, Steele T, Harsh Gt: Pituitary stalk gangliogliomas: Case report and literature review. *Clin Neurol Neurosurg* 201:106405, 2021
53. Pekmezci M, Villanueva-Meyer J, Goode B, Van Ziffle J, Onodera C, Grenert J, Bastian B, Chamyang G, Maher O, Khatib Z, Kleinschmidt-DeMasters B, Samuel D, Mueller S, Banerjee A, Clarke J, Cooney T, Torkildson J, Gupta N, Theodosopoulos P, Chang E, Berger M, Bollen A, Perry A, Tihan T, Solomon D: The genetic landscape of ganglioglioma. *Acta Neuropathol Commun* 6:47, 2018
54. Perkins O: Gangliogliomas. *Arch Pathol Lab Med* 2:11-17, 1926
55. Prasad G, Kumar R, Kurwale N, Suri V: Intraventricular gangliogliomas: A review. *World Neurosurg* 87:39-44, 2016
56. Puget S, Alshehri A, Beccaria K, Blauwblomme T, Paternoster G, James S, Dirocco F, Dufour C, Zerah M, Varlet P, Sainte-Rose C: Pediatric infratentorial ganglioglioma. *Childs Nerv Syst* 31:1707-1716, 2015
57. Quiroz Tejada A, Miranda-Lloret P, Llavador Ros M, Plaza Ramirez E, Pancucci G, Roca Barber A, Simal-Julián J, Botella-Asunción C: Gangliogliomas in the pediatric population. *Childs Nerv Syst* 37:831-837, 2021
58. Rades D, Zwick L, Leppert J, Bansanto M, Tronnier V, Dunst J, Schild S: The role of postoperative radiotherapy for the treatment of gangliogliomas. *Cancer* 115:432-442, 2010
59. Rolston J, Han S, Cotter J, El-Sayed I, Aghi M: Gangliogliomas of the optic pathway. *J Clin Neurosci* 21:2244-2249, 2014
60. Rumana C, Valadka A: Radiation therapy and malignant degeneration of benign supratentorial gangliogliomas. *Neurosurgery* 42:1038-1043, 1998
61. Russell D, Rubinstein L: Ganglioglioma: A case with long history and malignant evolution. *J Neuropathol Exp Neurol* 21:185-193, 1962
62. Safavi-Abbasi S, Di Rocco F, Chandra K, Feigl G, El-Shawarby A, Samii A, Samii M: Posterior cranial fossa gangliogliomas. *Skull Base* 17:253-264, 2007
63. Salge-Arrieta F, Carrasco-Moro R, Rodriguez-Berrocá V, Vior-Fernandez C, Lee P, Pian H, Martinez-San Millán J, Ley-Urzaiz L: Diagnosis and therapeutic management of ventricular gangliogliomas: An illustrated review. *World Neurosurg* 149:e651-e663, 2021
64. Samdani A, Torre-Healy A, Khalessi A, McGirt M, Jallo G, Carson B: Intraventricular ganglioglioma: A short illustrated review. *Acta Neurochir (Wien)* 151:635-640, 2009
65. Selch M, Goy B, Lee S, El-Sadin S, Kincaid P, Park S, Withers H: Gangliogliomas: Experience with 34 patients and review of the literature. *Am J Clin Oncol* 21:557-564, 1998
66. Selvanathan S, Hammouche S, Salminen H, Jenkinson M: Outcome and prognostic features in anaplastic ganglioglioma: Analysis of cases from the SEER database. *J Neurooncol* 105:539-545, 2001
67. Shono T, Tosaka M, Matsumoto K, Onaka S, Yamaguchi S, Mizoguchi M, Iwaki T, Nakazato Y, Sasaki T: Ganglioglioma in the third ventricle: Report on two cases *Neurosurg Rev* 30:253-258, 2007
68. Silver J, Rawlings Cr, Rossitch EJ, Zeidman S, Friedman A: Ganglioglioma: A clinical study with longterm follow-up. *Surg Neurol* 35:261-266, 1991
69. Syed H, Rhee J, Jha R, Felbaum D, Kalhorn C: Concurrent intraventricular and sacral spinal drop metastasis of ganglioglioma in an adult patient: A case report and review of literature. *Cureus* 8(3): e538, 2016
70. Tarnaris A, O'Brien C, Redfern R: Ganglioglioma with anaplastic recurrence of the neuronal element following radiotherapy. *Clin Neurol Neurosurg* 108:761-767, 2006
71. Timble M, Patil A, Naik A, Shivakumar S, Chaudhary B: Intraventricular ganglioglioma with unusual location and morphology - a case report. *Int J Radiol Radiat Oncol* 6:1-3, 2020
72. Tuleasca C, Peciu-Florianu I, Enora V, Reyns N: Gamma Knife radiosurgery as salvage therapy for gangliogliomas after initial microsurgical resection. *J Clin Neurosci* 92:98-102, 2021

73. Varshneya K, Sarmiento JM, Nuño M, Lagman C, Mukherjee D, Nuño K, Babu H, Patil C: A national perspective of adult gangliogliomas. *J Clin Neurosci* 30:65-70, 2016
74. Warnica W, Provias J: Intraventricular ganglioglioma with extensive hemorrhage. *Clin Neuropathol* 36:178-182, 2017
75. Xu L, Holland H, Kirsten H, Ahnert P, Krupp W, Bauer M, Schober R, Mueller W, Fritzsche D, Meixensberger J, Koschny R: Three gangliogliomas: Results of GTG-banding, SKY, genome-wide high resolution SNP-array, gene expression and review of the literature. *Neuropathology* 35:148-157, 2015
76. Yin Foo Lee G, Scott G, Blumbergs P, Patrick Brophy B, J LC: Ganglioglioma of the lateral ventricle presenting with blepharospasm - case report and review of the literature. *J Clin Sci* 8:279-282, 2001
77. Zhao R, Chu S, Zheng K, Kong L, Wang Y: Ganglioglioma in the bilateral ventricles arising from the septum and extending to the third ventricle. *Clin Neuropathol* 34:50-53, 2015