

# Electromagnetic Waves from Mobile Phones may Affect Rat Brain During Development

Dilek AKAKIN<sup>1</sup>, Olgu Enis TOK<sup>1</sup>, Damla ANIL<sup>1</sup>, Akin AKAKIN<sup>2</sup>, Serap SIRVanci<sup>1</sup>, Goksel SENER<sup>3</sup>, Feriha ERCAN<sup>1</sup>

<sup>1</sup>Marmara University, School of Medicine, Department of Histology and Embryology, Istanbul, Turkey

<sup>2</sup>Bahcesehir University, School of Medicine, Department of Neurosurgery, Istanbul, Turkey

<sup>3</sup>Marmara University, School of Pharmacy, Department of Pharmacology, Istanbul, Turkey

**Corresponding author:** Dilek AKAKIN ✉ dilekbangir@yahoo.com

## ABSTRACT

**AIM:** To investigate the effects of electromagnetic waves (EMWs) from mobile phones (MPs) on rat brains of rats by morphological and biochemical analysis.

**MATERIAL and METHODS:** EMW was applied for two hours/day until birth in stand-by fetal and EMW fetal groups and postnatal 60<sup>th</sup> day in stand-by and EMW groups. The control group was not exposed to MP. On postnatal 60<sup>th</sup> day, brain malondialdehyde (MDA) and glutathione (GSH) levels were measured, and western blot analysis was performed to determine glial fibrillary acidic protein (GFAP) content. Hematoxylin and eosin staining and GFAP immunohistochemistry were applied. Trigeminal nerves were examined using the transmission electron microscope.

**RESULTS:** In comparison to controls, rats exposed to MP in stand-by or talk modes had significantly increased neuronal damage in the cortex and hippocampus. Increased MDA levels in the EMW group and decreased GSH levels in the stand-by, EMW fetal and EMW groups were found compared with controls. Increased GFAP content in the EMW group and increased GFAP staining in the EMW fetal and EMW groups compared to controls were observed. EMW group had a significantly decreased number of myelinated axons than control animals.

**CONCLUSION:** 1800 MHz EMWs (SAR=1.79 W/kg) exposure in the prenatal and early postnatal life may lead to trigeminal nerve damage in addition to oxidative stress-induced neuronal degeneration and astroglial activation in the rat brain. Effects seem to be mode related, being more detrimental in groups exposed to MP during talk mode.

**KEYWORDS:** Cell phone, Electromagnetic wave, Trigeminal nerve, Rat, Oxidative stress

**ABBREVIATIONS:** BBB: Blood-brain barrier, CNS: Central nervous system, EMF: Electromagnetic field, EMR: Electromagnetic radiation, EMW: Electromagnetic wave, GFAP: Glial fibrillary acidic protein, GSH: Glutathione, MDA: Malondialdehyde, MP: Mobile phones, RF: Radiofrequency, ROS: Reactive oxygen species

## INTRODUCTION

Widespread access to mobile phones (MPs) is an area of concern due to its effects on health. Harmful effects of radiofrequency (RF) radiation have been reported on various body parts, including the central nervous

system (CNS) (3,8,29,30,38). Electromagnetic waves (EMWs) emitted from MPs increase the brain activity, and EEG pattern alterations have been reported (25). Brain functions like sleep, attention, cognitive performance, learning and memory are also affected by MP emitted electromagnetic radiation (EMR) (31,39,40).

Dilek AKAKIN  : 0000-0002-1781-3708  
Olgu Enis TOK  : 0000-0002-4899-9146  
Damla ANIL  : 0000-0003-4103-8913

Akin AKAKIN  : 0000-0002-3881-5913  
Serap SIRVanci  : 0000-0001-7683-4587  
Goksel SENER  : 0000-0001-7444-6193

Ferihan ERCAN  : 0000-0003-2339-5669

Potential carcinogenic effects, particularly increased risk for brain tumors due to MP-emitted EMW exposure, have also been pointed, and increased glioma and pituitary tumor risk was suggested (24,34,53).

Despite many experimental studies, the mechanism of MP effects is still not fully known. Thermal and non-thermal effects are considered to be the possible reasons that may disturb the cell function. As suggested for many diseases, reactive oxygen species (ROS) are also considered here to cause harmful effects (30). In furtherance, rats that had intrauterine microwave radiation exposure showed decreased superoxide dismutase and glutathione peroxidase with increased malondialdehyde (MDA) contents compared to controls indicating certain harmful effects on fetal rat brains (28).

Normally, astrocytes are involved in neuronal electrical activity, synaptic transmission and plasticity regulation (16). Mental functions and adaptive behaviors generated by cortical and subcortical structures, such as the hippocampus, could be affected by astrocyte-released pro-inflammatory molecules (45). Increased glial fibrillary acidic protein (GFAP) staining indicates reactive astrogliosis (49). Intermediate filament network reorganization leads to expressional changes in the GFAP, reflecting functional activity modifications of astrocytes related to nervous tissue damage, metabolic abnormalities or development of neurodegenerative states (19,21,33). Neuronal degeneration due to MP-emitted radiation exposure was reported in several studies (29,46,52). In addition, increased GFAP immunoexpression was also shown in the brains of RF-exposed rodents (3,5,37).

In addition to many other different regions of the nervous system, thermal and electromagnetic effects of MPs have also been reported on the cranial nerves, especially the adverse effects on facial and cochlear nerves have been shown in recent studies (1,14). Using wireless phones, including MPs, associated with increased glioma and acoustic neuroma, has also been reported (24). However, their effects on the trigeminal nerve have not yet been indicated.

Eventually, despite the presence of many reports about the effects of EMWs, still unclear points need to be examined, particularly while the use of MPs is increasing at the early period of life. Therefore, we designed the experiment in this study to investigate whether EMWs emitted from 1800 MHz MP (talk/stand-by mode) starting from the intrauterine life affect the brain as assessed by lipid peroxidation, antioxidant mechanisms, neuronal injury, gliosis, and cranial nerve involvement.

## ■ MATERIAL and METHODS

### Animals and Experimental Design

Rats (Wistar, 250–350 g) and their male pups were used in this study. Animals were held at a steady temperature ( $22 \pm 1^\circ\text{C}$ ) and 12 hours /12 hours light/dark cycles, with standard rat feed and free access to water. The experiment was performed according to the national guidelines on animal experimentation and was approved by the Marmara University Local Ethical Committee for Experimental Animals (56.2010.mar).

In the beginning, each female rat ( $n=10$ ) was placed in a cage for 24 hours with a male rat ( $n=10$ ), and on the next morning, vaginal plugs were examined. The first 24 hours period following the determination of the vaginal plug was established as embryonic day 0 (E0) of pregnancy. Male rats were removed from the cage after mating, female pregnant rats were taken in one cage and starting from the 14<sup>th</sup> day of pregnancy until birth, they were exposed to a cell phone (1800 MHz, 1.79 W/kg, 2 hours/day) placed 1 cm above the cage. The MP was on-call mode to another MP with a similar specific absorption rate (SAR) value or stand-by mode. Male rats born were randomly allocated to five experimental groups ( $n=6$ , in each): control, stand-by fetal, stand-by, EMW fetal and EMW. Animals in the prenatal groups were not exposed to a cell phone after birth; however, other rats continued to have EMW until postnatal 60th day. Control group animals were not exposed to cell phone pre- or post-natally. Rats were sacrificed at the end of the second month. Brains were removed and trigeminal nerves were dissected under a stereomicroscope. MDA and GSH levels in the brain and Western blot analysis for the GFAP protein amount in the brain tissues were biochemically analyzed. The ultrastructural morphology of trigeminal nerves was established using transmission electron microscopic techniques.

### Malondialdehyde (MDA) and Glutathione (GSH) Assays

Rats were decapitated and fresh brain tissues of rats obtained were weighed and kept in phosphate buffer at  $-80^\circ\text{C}$ . Tissues were processed for the examination of biochemical parameters MDA and GSH (2). Determination of MDA levels was assayed, as described previously (11). Modified Ellman procedure was used for GSH measurements (6). Data were represented as nmol (MDA) or  $\mu\text{mol}$  (GSH) per g tissue.

### Western Blot Analyses for Protein Expression

To measure the GFAP amount by Western blot, RIPA cell lysis buffer (Santa Cruz Biotechnology, Santa Cruz, CA, USA) was used to homogenize rat brains. After centrifugation at  $10,000 \times g$  for 15 min at  $4^\circ\text{C}$ , protein concentration measurement of supernatants was made using the bicinchoninic acid protein assay kit (Pierce, Rockford, IL, USA). The tissue lysate was heated at  $70^\circ\text{C}$  for 5 min in 1 x SDS sample buffer (50 mM Tris-HCl pH 6.8, 12.5% glycerol, 1% sodium dodecyl sulfate, 0.01% bromophenol blue) containing 5%  $\beta$ -mercaptoethanol for protein denaturation. Equal amounts of protein were subjected to SDS-PAGE electrophoresis using 4–12% NuPAGE Bis-Tris gels (Invitrogen) with NuPAGE MOPS SDS running buffer (Invitrogen) at a constant voltage of 160 V. Proteins were transferred to polyvinylidene fluoride (PVDF) membrane using the iBlot dry blotting method (Invitrogen). Protein bands were visualized using Western Breeze Chromogenic Kits (Invitrogen). GFAP primary antibody (Merck Millipore, MAB360) was used at a 1:1000 dilution. The relative densities of bands were analyzed with Image J Programme (NIH Image Version 1.61). The procedure was repeated at least three times, and signals were normalized concerning B-actin.

### Light Microscopy Preparation and Histopathologic Evaluation

To perform light microscopic investigations, an equal number

of rats was anesthetized and transcardially perfused with fixative (4% paraformaldehyde in 0.1 M PBS -phosphate buffer saline- pH 7.4). Brains were carefully dissected out from the skull and kept in the same fixative at 4°C. Tissues were processed for light microscopic investigations and 5 µm-thick paraffin sections cut by rotary microtome (Leica RM2155, Germany) were stained with hematoxylin and eosin (H&E) to observe neuronal damage in the cortex and hippocampus (dentate gyrus -DG- and CA3). Semi-quantitative scores were given (0: none, 1: mild, 2: moderate, 3: severe). Finally, photographs were taken under a photomicroscope (Olympus BX51, Tokyo, Japan) with a digital camera (Olympus DP72, Tokyo, Japan) attachment.

### GFAP Immunohistochemistry

For GFAP immunohistochemistry, after deparaffinization and rehydration, to inhibit endogenous enzyme blockage, sections were incubated in 3% hydrogen peroxide in methanol (10 min). Following washing in PBS, antigen retrieval was performed using citrate buffer (pH 6.1) for 20 min in microwave. After washed, sections were incubated in blocking solution and then with mouse anti-GFAP (1:1000, Merck Millipore, MAB360) at 4°C, overnight. According to the manufacturer's protocol, a secondary antibody (Histostain®-Plus 3rd Gen IHC Detection Kit, 85-9073, Invitrogen, CA, USA) was applied. Sections were later incubated in streptavidin-peroxidase (10 min) and 3, 3'-diaminobenzidine for 5 min. Mayer's hematoxylin was used to counterstain sections before mounting. Immunostaining was scored using a semiquantitative method on a 0–3 point scale based on the density of GFAP-immunopositive cells, where 0: baseline staining; 1: mild immunoreactivity; 2: moderate immunoreactivity; 3: widespread severe immunoreactivity. Sections were viewed under a photomicroscope and average immunostaining scores were recorded for each group before statistical analysis was performed.

### Electron Microscopy

For electron microscopic investigations, trigeminal nerves were fixed in 2.5% glutaraldehyde solution in PBS (0.1 M, pH 7.3). Tissues were then incubated in 1% OsO<sub>4</sub> in PBS (0.1 M, pH 7.3). After progressively dehydrated with ethyl alcohol and cleared in propylene oxide, samples were embedded in Epon 812 for 24 h at 60°C.

Trigeminal nerve areas and the number of myelinated axons were measured using the Image J programme in the four photographs (100x objective) captured from toluidine blue stained semi-thin sections. The average number of myelinated axons was recorded for each animal. Lead citrate (1%) and uranyl acetate were used to stain thin (60-nm) sections. Finally, sections were photographed by the SIS Morada CCD camera system attached transmission electron microscope (JEOL 1200 EXII, Tokyo, Japan).

### Statistical Analysis

Statistical analysis was performed with the use of GraphPad Prism 3.0 (GraphPad Software, San Diego, CA, USA). Data were expressed as means ± SEM. Analysis of variance (ANOVA) and Tukey's multiple comparison tests were used to

analyze biochemical and histological data. The significance value was counted as  $p < 0.05$ .

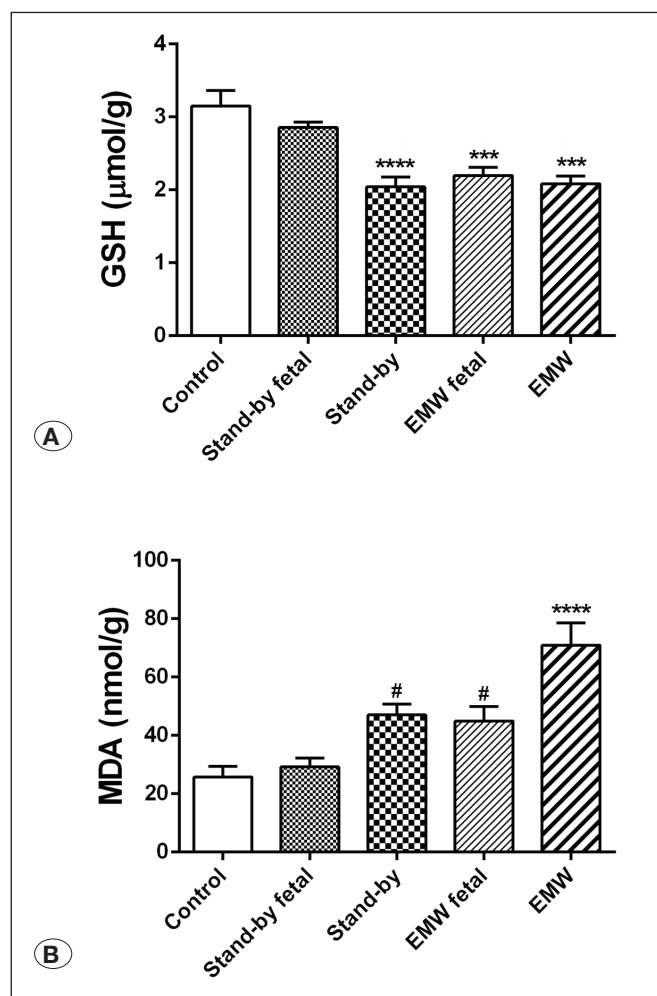
## RESULTS

### Malondialdehyde (MDA) and Glutathione (GSH) Assays

EMW exposure revealed a decrease of GSH levels of brain tissues of stand-by, EMW fetal and EMW groups compared to controls ( $p < 0.001$ – $0.0001$ ) (Figure 1A). Increased MDA levels were detected in brain tissues of the EMW group regarding controls ( $p < 0.0001$ ) (Figure 1B). Exposure to the intrauterine cell phone in the stand-by and EMW fetal groups did not significantly increase the MDA levels compared to controls, while still above control levels and statistically lower than that of the rats in the EMW group ( $p < 0.05$ ).

### Western Blot Analysis

GFAP protein expression was detected by Western blot in all experimental groups and the intensity of protein bands



**Figure 1:** Glutathione (GSH; A) and malondialdehyde (MDA; B) levels in the brain tissues of experimental groups. \*\*\*:  $p < 0.001$ , \*\*\*\*:  $p < 0.0001$  compared to the control group; #:  $p < 0.05$  compared to the EMW group.

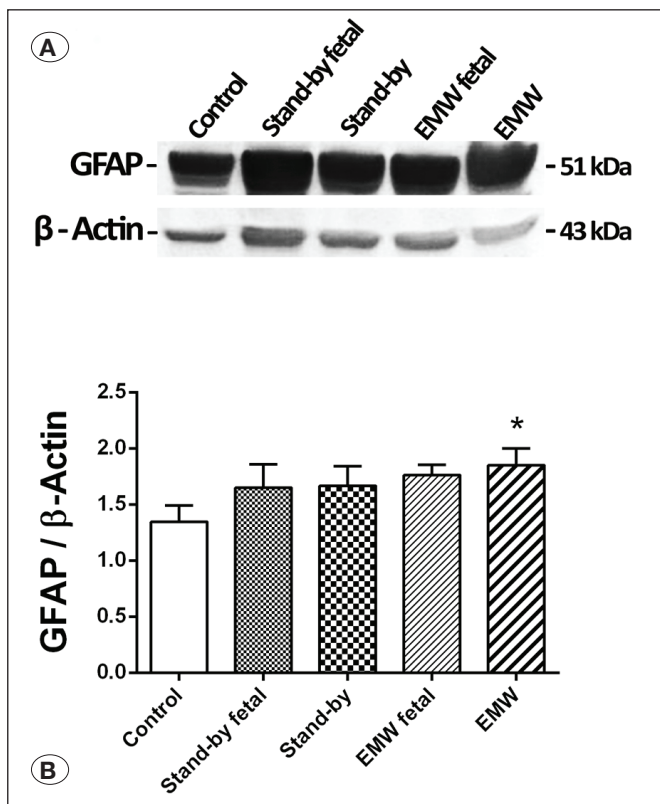
increased in the EMW group compared to controls ( $p < 0.05$ ) (Figure 2A, B).

### Histopathological Findings

Our findings revealed the regular morphology of neurons in the control group that was not exposed to any EMW (Figure 3A-F). However, marked morphological changes and increased neuronal degeneration in the cortices and hippocampal DG and CA3 regions of rats in EMW, EMW fetal and stand-by groups ( $p < 0.05$  -  $p < 0.0001$ ) and in the cortices and hippocampal DG region of the stand-by fetal group ( $p < 0.01$ ) were detected. Perineuronal edema, neuronal shrinkage and nuclear pyknosis were evident in the on-call MP-exposed rats with darkly stained neurons. Neuronal degeneration being more obvious in the EMW group was observed with many vacuoles in the neuropil of both cortex and the hippocampus.

### GFAP Immunohistochemistry

GFAP-positive staining was observed in all regions of the brain and increased GFAP-immunoreactivity (GFAP-IR) revealing higher scores were found in the cortex of rats in the EMW group and hippocampal DG and CA3 regions of EMW fetal and EMW groups, compared to control rats (Figure 4A-F) ( $p < 0.05$ ).



**Figure 2:** GFAP protein expression detected by Western blot in the experimental groups. Immunoreactive bands for proteins GFAP and  $\beta$ -actin (internal control) for control, stand-by fetal, stand-by, EMW fetal and EMW groups are shown in **A**. The graph (**B**) gives the relative densities of GFAP/ $\beta$ -actin in which (\*) indicates a statistical difference between the EMW group and controls, considering the level of significance with  $p < 0.05$ .

### Trigeminal Nerve Findings

Trigeminal nerve sections stained with toluidin blue revealed several myelinated nerve fiber transverse sections with the various diameters (Figure 5A-F). Electron microscopic examination showed myelinated nerve fibers surrounded by the Schwann cells and nonmyelinated nerve fibers embedded in the cytoplasm. Regular axonal morphology with normal appearing neurofilaments was seen in the control group. Degeneration of myelinated axons with myelin sheath disturbance, dispersion of myelin lamella in stand-by, EMW fetal and EMW groups and vacuolizations in the axoplasm in EMW group were evident. Myelinated axon number was lower in the EMW group than that of the control group ( $p < 0.05$ ); however, no statistical difference between experimental groups was detected for trigeminal nerve areas.

### DISCUSSION

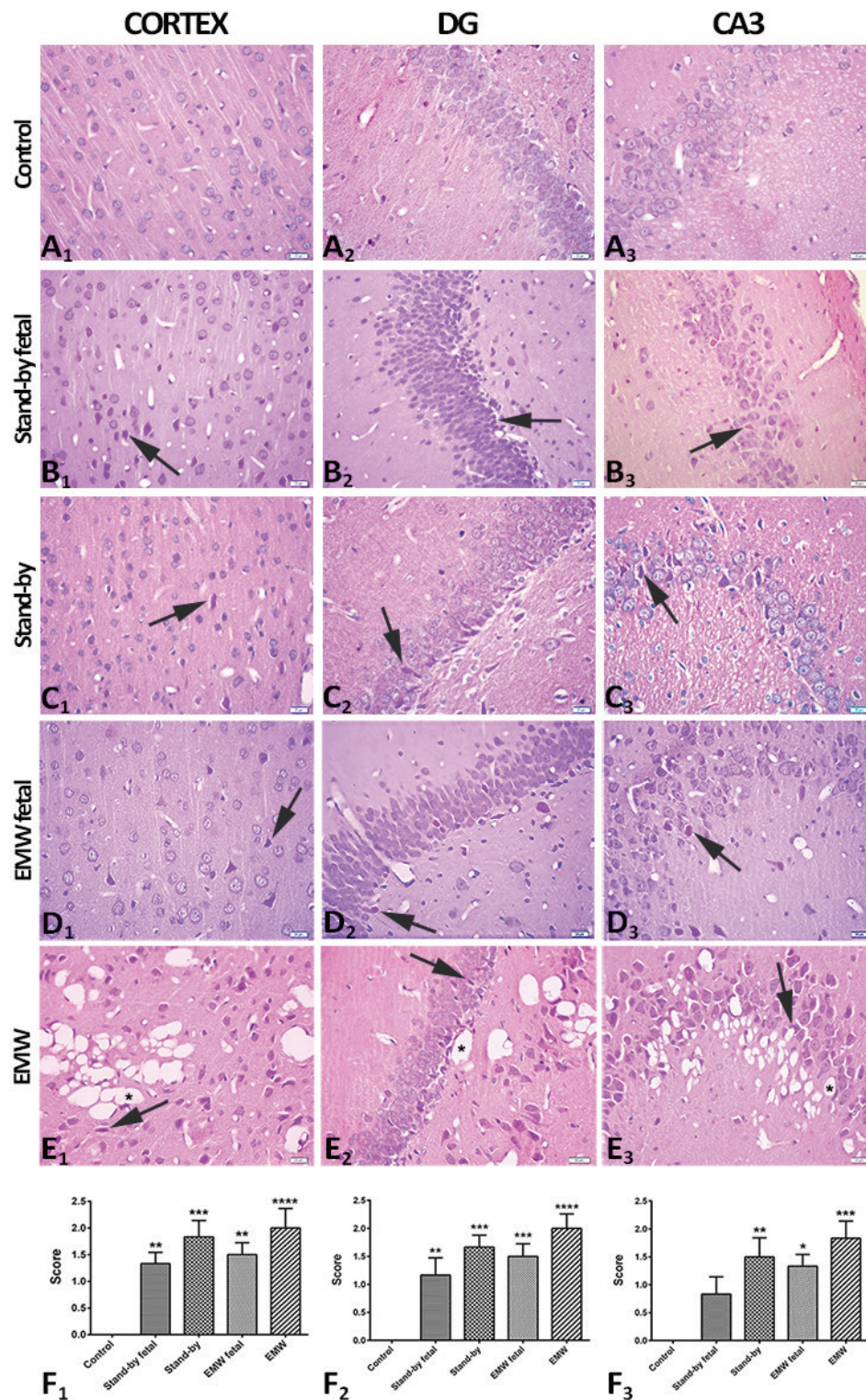
In this study, 1800 MHz electromagnetic fields (EMF) exposure from MP increased oxidative stress (MDA) in the brain tissue of rats in on-call mode and conversely decreased the level of antioxidants (GSH) either on-call or stand-by mode. In the histological investigations, the neuronal injury was noted in both cortical and hippocampal samples. GFAP protein content and expression also increased in the on-call MP EMF exposed rats. In addition, to our knowledge, this is the first study in the literature to demonstrate the effects of EMF from MPs on the trigeminal nerve ultrastructurally and decreased myelinated axons in the trigeminal nerves of EMW groups were observed.

Increasing use of MPs starting from early ages has raised attention to the potential harm of them on child and teenager health worldwide. While the average age that uses MPs decreases by the time, the time spent using them also increases. Longer lifetime exposure of children compared to today's adults is assumed and it is stated that the health status in children using MPs regularly goes worse (12). Skull thickness is lower in children than in adults and absorption of substantially higher radiation doses by young eyes and brains is revealed with a cell phone and virtual reality device modeling (20). Higher SAR values reported in children would lead to more destructive effects.

Intrauterine exposure is another issue. Behavioural difficulties and particularly increased hyperactivity/inattention problems in children with intrauterine cell phone exposure are stated (7,18). Developmental delay of the chick embryos in the early period was also reported due to EMR emitted by MPs (51). Nervous system development continues after birth and the brain is more vulnerable to environmental exposures at these important stages. Therefore, we aimed to examine how EMWs of MPs affect the brain beginning from the fetal period. Neuronal damage described here and other studies may not display their effects immediately in the brain functions; however, in the long run, intense MP use by teenagers may result in reduced brain reserve capacity and after some years of frequent daily use, adults may suffer negative effects (46).

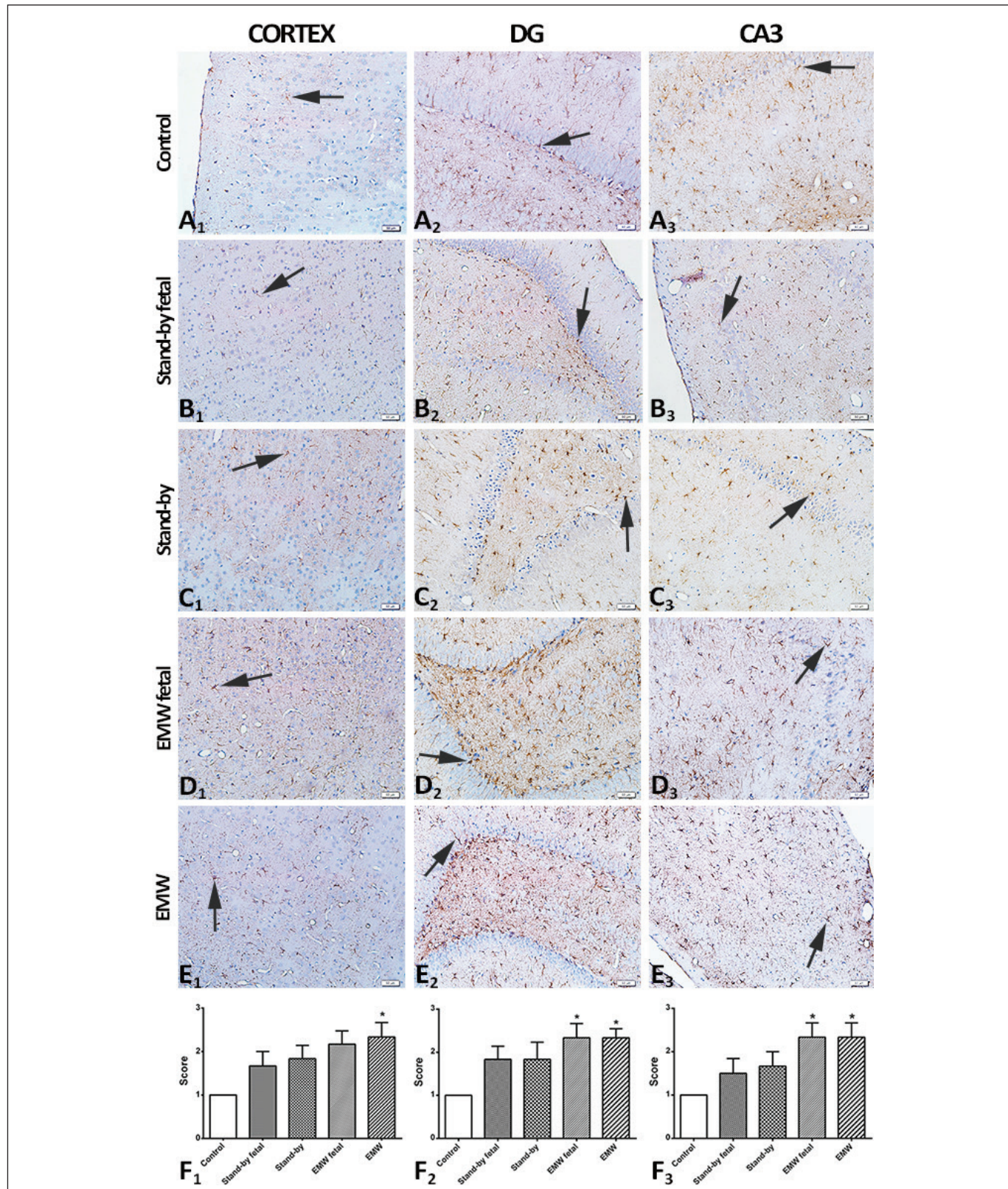
EMWs could disrupt the balance between the atom and molecules and also the electrical balance of the cells by





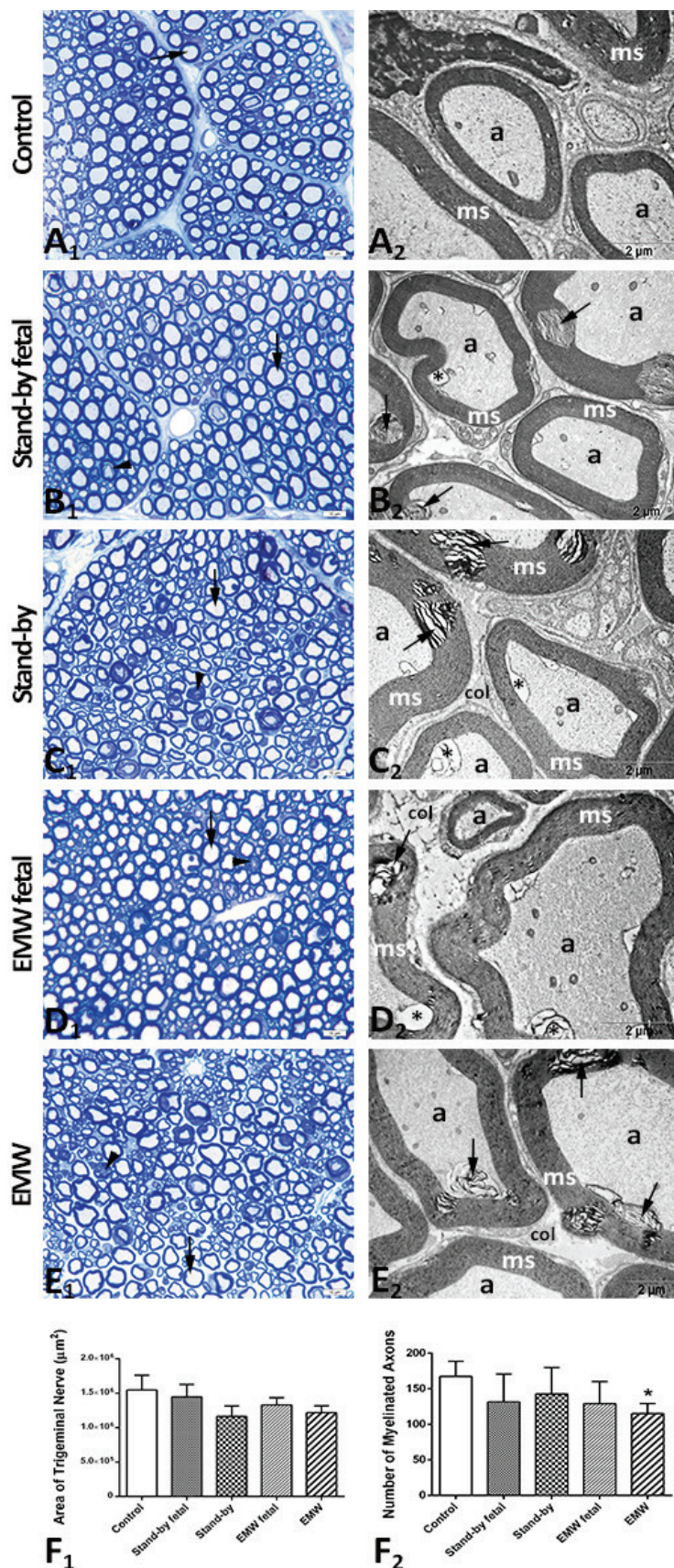
**Figure 3:** Representative photomicrographs of brain cortices and hippocampal dentate gyrus (DG) and CA3 regions in the experimental groups. Normal morphology of neurons in the cortex and hippocampus of the control rats (A<sub>1-3</sub>) is seen. Degenerated nerve cells (arrows) interspersed among the normal appearing nerve cells are observed in the stand-by fetal (B<sub>1-3</sub>), stand-by (C<sub>1-3</sub>), EMW fetal (D<sub>1-3</sub>) and EMW (E<sub>1-3</sub>) groups. Vacuoles (\*) in the cortical and hippocampal neuropil in the EMW (E<sub>1-3</sub>) group is indicated. Hematoxylin and eosin stain. Bars: 20 μm; E<sub>2</sub>, 50 μm. Microscopic damage scores in the cortex (F<sub>1</sub>) and hippocampal DG (F<sub>2</sub>) and CA3 (F<sub>3</sub>) areas. \*: p<0.05, \*\*: p<0.01, \*\*\*: p<0.001, \*\*\*\*: p<0.0001 compared to control group.





**Figure 4:** Representative photomicrographs of GFAP-immunostained cortex and hippocampal dentate gyrus (DG) and CA3 regions of control (**A<sub>1-3</sub>**), stand-by fetal (**B<sub>1-3</sub>**), stand-by (**C<sub>1-3</sub>**), EMW fetal (**D<sub>1-3</sub>**) and EMW (**E<sub>1-3</sub>**) groups. GFAP expression is shown by arrows. **Bars:** 50  $\mu$ m. GFAP immunoreactivity scores in the cortex (**F<sub>1</sub>**) and hippocampal DG (**F<sub>2</sub>**) and CA3 (**F<sub>3</sub>**) areas. \*:  $p < 0.05$  compared to the control group.





affecting the biochemical activities. These effects have been reported in the brain in which the electrical balance is particularly important (9). Studies investigating the electromagnetic and thermal effects of EMWs emitted from MPs have especially focused on the brain because of its close proximity when on use. Studies on cognitive functions and learning in children are especially significant. RF radiation exposure to the hippocampus of the young brain may cause considerable effects and the correlation between MP exposure and memory impairment is propounded (3,31,40,44). In relation, our histological findings expressing the neuronal injury in the hippocampus of rats both in EMW and stand-by groups are meaningful.

In addition to many other diseases, oxidative stress is defined as underlining pathology in the neurological conditions, including neurodegenerative disorders, subarachnoid haemorrhage, epileptic seizures and traumatic brain injury (17,33,43). High metabolic rate and oxygen consumption capacity, deficient oxidant defense mechanisms and diminished cellular turnover of the nervous system all cause vulnerability to the ROS (17,22,42). When the brain is exposed to oxidative stress, antioxidant enzymes are produced; however, lower antioxidant defense mechanisms are also concluded in the brain (23). Levels of GSH, as a component of cellular antioxidant defense mechanism and the level of MDA, are examined in this study.

Free radicals produced by EMFs may lead to congenital malformations and tissue damage (48). A biochemical study in Balb/C mice revealed increased MDA and decreased total thiol groups, superoxide dismutase and catalase activity in various tissues, including the hippocampus of both the dams receiving MP (900–1800 MHz) exposure and their offsprings (4). The reversing effects of antioxidants like melatonin (50) and *Lycopersicon esculentum* extract (32) on the brain tissues of animals exposed to MP also support the oxidative stress effect. Tissue damage may also be due to thermal effects, as shown with the significantly higher mean tympanic temperature during continuous exposure than during sham exposure in a study performed on healthy men (10). Decreases in brain GSH levels of stand-by, EMW-fetal and EMW groups and increased MDA levels of EMW group in this study demonstrate that MP-emitted EMWs may cause oxidative damage and decreases a major endogenous antioxidant store. Long-term exposure to EMF proceeds to even higher levels of oxidative stress, causing more adverse histological effects and that would probably explain the significant difference between MDA levels of EMW fetal and EMW groups.

Researchers have pointed out the leakage of albumin and some other smaller molecules through the blood–brain barrier (BBB) due to RF EMF exposure that could cause damage to the neurons (29,46). As another underlying mechanism, variations in excitatory and inhibitory amino acid neurotransmitters are also suggested after exposure, described in the cerebellum, midbrain and medulla (41). Recently, inhibited expression of proliferating cell nuclear antigen and doublecortin was explained by BDNF down-regulation in DG of rat offspring exposed to long duration prenatal MP (52).

Degenerated neuron number and EMW dose (SAR) were in significant relation (46). The significant relation between the period of exposure with the instances of histopathological changes in brain tissue was also indicated in a study that revealed increased permeability of BBB in the exposed groups (29). Similarly, we found in this study that the EMW groups revealed severe neuronal degeneration and vacuolizations observed mainly in the cortex of the EMW group was compatible with a previous study that revealed vacuoles in the brain cortex of MP RF-exposed adult rats (6 hours/day) in which the number and size of the vacuoles were larger in animals exposed for longer time (47). The mechanism responsible for the severe degeneration could be explained through ROS in the MP exposed rats from intrauterine life up to two months of age, which also showed significantly increased MDA levels.

GFAP is well known to have a role in homeostasis and brain injury control in the CNS. In various conditions that cause CNS injury, reactive gliosis is observed (33,54). Jointly with the increased GFAP expression, reactive astrocytes are in parallel with cell hypertrophy and hyperplasia (27). Correlation between trauma severity and GFAP (+) astrocyte number is also concluded (13). Similarly, when we evaluated GFAP using immunohistochemistry and Western blot methods, exposure to MP at on-call mode revealed a significant increase compared to controls, particularly in the EMW group. Effects of intrauterine and both intra- and extrauterine MP exposure on stand-by mode related to GFAP were not shown previously and we presented in this study that the exposure to a cell phone on stand-by mode in either periods did not reveal a significant change of GFAP compared to controls. Based on this finding, we may suggest that the MP emitted EMWs could induce glial activation and this effect may be exposure mode dependent.

Sub-chronic MP exposure of rats showed increased brain GFAP levels regarding the sham-treated animals, proposed as a sign of potential gliosis (3). When effects of SAR values were investigated, stronger GFAP-IR was shown compared to controls, with more prominent GFAP-IR in the higher SAR group (37). Astrogliosis and its effects on memory induced by RF EMF were shown using enzyme-linked immunosorbent assay (5). With the findings in this study, we can propound that increase in both GFAP levels and immunoreactivity may mediate brain damage caused by RF exposure from cell phones.

The effects of the MPs on cranial nerves, particularly facial and the cochlear nerves, have been shown in previous studies (1,14,15,24,35). In addition to the series of symptoms associated with MP use, dysaesthesia with marked alterations in the trigeminal nerve current perception threshold testing of the affected area was also presented (26). It was also specified that the trigeminal nerves have cutaneous warmth-sensing neurons (36). However, the morphological effects of EMW emitted from MPs on the trigeminal nerve have not been reported yet. To our knowledge, this is the first study to ultrastructurally analyze this nerve, which is localized in close proximity to the cell phone when used on-call and our findings



are important to show that the EMWs associated with the exposure cell phones could affect the trigeminal nerve during developmental ages and lead to potentially severe outcomes with long-term usage.

## CONCLUSION

MPs (even on stand-by mode, which is more common in practical routine) could affect brain development from fetal to adult period. It is not possible to avoid what technology presents to humans, especially in the current COVID-19 pandemic when the children and youngsters use it for many purposes, such as education, communication, fun and social life. However, considering the results of this study, it is necessary to be aware of the health impacts caused by MPs and measures, such as exposure time reduction as a lifestyle change and efforts to mitigate harmful effects should be considered until more definitive research results are achieved.

## ACKNOWLEDGEMENT

This study was supported by the Marmara University Scientific Research Committee (SAG-A-130511-0130), Istanbul, Turkey.

## REFERENCES

1. Acar GO, Yener HM, Savrun FK, Kalkan T, Bayrak I, Enver O: Thermal effects of mobile phones on facial nerves and surrounding soft tissue. *Laryngoscope* 119(3):559-562, 2009
2. Aktas HS, Ozel Y, Ahmad S, Pence HH, Ayaz-Adakul B, Kudas I, Tetik S, Sekerler T, Canbey-Goret C, Kabasakal L, Elcioglu HK: Protective effects of resveratrol on hepatic ischemia reperfusion injury in streptozotocin-induced diabetic rats. *Mol Cell Biochem* 460(1-2):217-224, 2019
3. Ammari M, Gamez C, Lecomte A, Sakly M, Abdelmelek H, De Seze R: GFAP expression in the rat brain following sub-chronic exposure to a 900 MHz electromagnetic field signal. *Int J Radiat Biol* 86(5):367-375, 2010
4. Bahreyni Toossi MH, Sadeghnia HR, Mohammad Mahdizadeh Feyzabadi M, Hosseini M, Hedayati M, Mosallanejad R, Beheshti F, Alizadeh Rahvar Z: Exposure to mobile phone (900-1800MHz) during pregnancy: Tissue oxidative stress after childbirth. *J Matern Fetal Neonatal Med* 31(10):1298-1303, 2018
5. Barthélémy A, Mouchard A, Bouji M, Blazy K, Puigsegur R, Villégier AS: Glial markers and emotional memory in rats following acute cerebral radiofrequency exposures. *Environ Sci Pollut Res Int* 23(24):25343-25355, 2016
6. Beutler E: Glutathione. In: Beutler E (ed), *Red Cell Metabolism, A Manual of Biochemical Methods*, 2nd ed, New York: Grune and Stratton, 1975:112-114
7. Birks L, Guxens M, Papadopoulou E, Alexander J, Ballester F, Estarlich M, Gallastegi M, Ha M, Haugen M, Huss A, Kheifets L, Lim H, Olsen J, Santa-Marina L, Sudan M, Vermeulen R, Vrijotte T, Cardis E, Vrijheid M: Maternal cell phone use during pregnancy and child behavioral problems in five birth cohorts. *Environ Int* 104:122-131, 2017
8. Black DR, Heynick LN: Radiofrequency (RF) effects on blood cells, cardiac, endocrine, and immunological functions. *Bioelectromagnetics* 6:S187-195, 2003
9. Blank M: Biological effects of environmental electromagnetic fields: An overview. *Advances in Chemistry* 250:1-10, 1995
10. Bortkiewicz A, Gadzicka E, Szymczak W, Zmyslony M: Changes in tympanic temperature during the exposure to electromagnetic fields emitted by mobile phone. *Int J Occup Med Environ Health* 25(2):145-150, 2012
11. Buege JA, Aust SD: Microsomal lipid peroxidation. *Methods Enzymol* 52:302-310, 1978
12. Chiu CT, Chang YH, Chen CC, Ko MC, Li CY: Mobile phone use and health symptoms in children. *J Formos Med Assoc* 114(7):598-604, 2015
13. Cikrikler HI, Uysal O, Ekici MA, Ozbek Z, Cosan DT, Yucel M, Yurumez Y, Baydemir C: Effectiveness of GFAP in determining neuronal damage in rats with induced head trauma. *Turk Neurosurg* 26(6):878-889, 2016
14. Colletti V, Mandalà M, Manganotti P, Ramat S, Sacchetto L, Colletti L: Intraoperative observation of changes in cochlear nerve action potentials during exposure to electromagnetic fields generated by mobile phones. *J Neurol Neurosurg Psychiatry* 82(7):766-771, 2011
15. Celiker M, Ozgur A, Tumkaya L, Terzi S, Yilmaz M, Kalkan Y, Erdogan E: Effects of exposure to 2100MHz GSM-like radiofrequency electromagnetic field on auditory system of rats. *Braz J Otorhinolaryngol* 83(6):691-696, 2017
16. De Pitta M, Brunel N, Volterra A: Astrocytes: Orchestrating synaptic plasticity? *Neuroscience* 323:43-61, 2016
17. Demir D, Kuru Bektasoglu P, Koyuncuoglu T, Kandemir C, Akakin D, Yuksel M, Celikoglu E, Yegen BC, Gurer B: Neuroprotective effects of mildronate in a rat model of traumatic brain injury. *Injury* 50(10):1586-1592, 2019
18. Divan HA, Kheifets L, Obel C, Olsen J: Prenatal and postnatal exposure to cell phone use and behavioral problems in children. *Epidemiology* 19(4):523-529, 2008
19. Elahi FM, Casaletto KB, La Joie R, Walters SM, Harvey D, Wolf A, Edwards L, Rivera-Contreras W, Karydas A, Cobigo Y, Rosen HJ, DeCarli C, Miller BL, Rabinoivici GD, Kramer JH: Plasma biomarkers of astrocytic and neuronal dysfunction in early- and late-onset Alzheimer's disease. *Alzheimers Dement* 16(4):681-695, 2020
20. Fernández C, de Salles AA, Sears ME, Morris RD, Davis DL: Absorption of wireless radiation in the child versus adult brain and eye from cell phone conversation or virtual reality. *Environ Res* 167:694-699, 2018
21. Garabadu D, Singh D: Ocimum basilicum attenuates ethidium bromide-induced cognitive deficits and pre-frontal cortical neuroinflammation, astrogliosis and mitochondrial dysfunction in rats. *Metab Brain Dis* 35(3):483-495, 2020
22. Hall ED, Vaishnav RA, Mustafa AG: Antioxidant therapies for traumatic brain injury. *Neurotherapeutics* 7(1):51-61, 2010
23. Halliwell B: Oxidative stress and neurodegeneration: Where are we now? *J Neurochem* 97(6):1634-1658, 2006
24. Hardell L, Carlberg M, Hansson Mild K: Use of mobile phones and cordless phones is associated with increased risk for glioma and acoustic neuroma. *Pathophysiology* 20(2):85-110, 2013
25. Hermann DM, Hossmann KA: Neurological effects of microwave exposure related to mobile communication. *J Neurol Sci* 152:1-14, 1997

26. Hocking B, Westerman R: Neurological abnormalities associated with mobile phone use. *Occup Med (Lond)* 50(5): 366-368, 2000
27. Janeczko K: Co-expression of GFAP and vimentin in astrocytes proliferating in response to injury in the mouse cerebral hemisphere. A combined autoradiographic and double immunocytochemical study. *Int J Dev Neurosci* 11(2): 139-147, 1993
28. Jing J, Yuhua Z, Xiao-qian Y, Rongping J, Dong-mei G, Xi C: The influence of microwave radiation from cellular phone on fetal rat brain. *Electromagn Biol Med* 31(1):57-66, 2012
29. Kafaee Razavi M, Raji RA, Maleki M, Dehghani H, Hagheima A: Histopathological and immunohistochemical study of rat brain tissue after exposure to mobile phone radiation. *Comp Clin Path* 24:1271-1276, 2015
30. Kesari KK, Kumar S, Nirala J, Siddiqui MH, Behari J: Biophysical evaluation of radiofrequency electromagnetic field effects on male reproductive pattern. *Cell Biochem Biophys* 65:85-96, 2013
31. Koivisto M, Krause CM, Revonsuo A, Laine M, Hamalainen H: The effects of electromagnetic field emitted by GSM phones on working memory. *Neuroreport* 11:1641-1643, 2000
32. Kokturk S, Yardimoglu M, Celikozlu SD, Dolanbay EG, Cimbiz A: Effect of Lycopersicon esculentum extract on apoptosis in the rat cerebellum, following prenatal and postnatal exposure to an electromagnetic field. *Exp Ther Med* 6(1):52-56, 2013
33. Koyuncuoglu T, Vizdiklar C, Uren D, Yilmaz H, Yildirim C, Atal SS, Akakin D, Kervancioglu Demirci E, Yuksel M, Yegen BC: Obestatin improves oxidative brain damage and memory dysfunction in rats induced with an epileptic seizure. *Peptides* 90:37-47, 2017
34. Leng L, Zhang Y: Etiology of pituitary tumors: A case control study. *Turk Neurosurg* 26(2):195-199, 2016
35. Mandalà M, Colletti V, Sacchetto L, Manganotti P, Ramat S, Marcocci A, Colletti L: Effect of Bluetooth headset and mobile phone electromagnetic fields on the human auditory nerve. *Laryngoscope* 124(1):255-259, 2014
36. Marino AA, Kim PY, Frilot Li C: Trigeminal neurons detect cell phone radiation: Thermal or nonthermal is not the question. *Electromagn Biol Med* 36(2):123-131, 2017
37. Maskey D, Kim HJ, Kim HG, Kim MJ: Calcium-binding proteins and GFAP immunoreactivity alterations in murine hippocampus after 1 month of exposure to 835 MHz radiofrequency at SAR values of 1.6 and 4.0 W/kg. *Neurosci Lett* 506(2):292-296, 2012
38. Monfared AL, Nooraii A, Shamsi M: Histological and biochemical studies of mice kidney after exposure to mobile phone radiation. *J Bas Res Med Sci* 3:45-51, 2016
39. Munezawa T, Kaneita Y, Osaki Y, Kanda H, Minowa M, Suzuki K, Higuchi S, Mori J, Yamamoto R, Ohida T: The association between use of mobile phones after lights out and sleep disturbances among Japanese adolescents: A nation wide cross-sectional survey. *Sleep* 34:1013-1020, 2011
40. Nittby H, Grafstrom G, Tian DP, Malmgren L, Brun A, Persson BR, Salford LG, Eberhardt J: Cognitive impairment in rats after long-term exposure to GSM-900 mobile phone radiation. *Bioelectromagnetics* 29:219-232, 2008
41. Noor NA, Mohammed HS, Ahmed NA, Radwan NM: Variations in amino acid neurotransmitters in some brain areas of adult and young male albino rats due to exposure to mobile phone radiation. *Eur Rev Med Pharmacol Sci* 15(7):729-742, 2011
42. Ozdemir D, Uysal N, Gonenc S, Acikgoz O, Sonmez A, Topcu A, Ozdemir N, Duman M, Semin I, Ozkan H: Effect of melatonin on brain oxidative damage induced by traumatic brain injury in immature rats. *Physiol Res* 54(6):631-637, 2005
43. Ozsavci D, Ersahin M, Sener A, Ozakpinar OB, Toklu HZ, Akakin D, Sener G, Yegen BC: The novel function of nesfatin-1 as an anti-inflammatory and antiapoptotic peptide in subarachnoid hemorrhage-induced oxidative brain damage in rats. *Neurosurgery* 68(6):1699-1708, 2011
44. Petitdant N, Lecomte A, Robidel F, Gamez C, Blazy K, Villégier AS: Cerebral radiofrequency exposures during adolescence: Impact on astrocytes and brain functions in healthy and pathologic rat models. *Bioelectromagnetics* 37(5):338-350, 2016
45. Rothstein JD, Dykes-Hoberg M, Pardo CA, Bristol LA, Jin L, Kuncir RW, Kanai Y, Hediger MA, Wang Y, Schielke JP, Welty DF: Knockout of glutamate transporters reveals a major role for astroglial transport in excitotoxicity and clearance of glutamate. *Neuron* 16:675-686, 1996
46. Salford LG, Brun AE, Eberhardt JL, Malmgren L, Persson BR: Nerve cell damage in mammalian brain after exposure to microwaves from GSM mobile phones. *Environ Health Perspect* 111(7): 881-883; discussion A408, 2003
47. Shahabi S, Hassanzadeh Taji I, Hoseinnehzaddarzi M, Mousavi F, Shirchi S, Nazari A, Zarei H, Pourabdolhossein F: Exposure to cell phone radiofrequency changes corticotrophin hormone levels and histology of the brain and adrenal glands in male Wistar rat. *Iran J Basic Med Sci* 21(12):1269-1274, 2018
48. Shaw GM: Adverse human reproductive outcomes and electromagnetic fields: A brief summary of the epidemiologic literature. *Bioelectromagnetics* 5:S5-18, 2001
49. Sofroniew MV, Vinters HV: Astrocytes: Biology and pathology. *Acta Neuropathol* 119(1):7-35, 2010
50. Sokolovic D, Djindjic B, Nikolic J, Bjelakovic G, Pavlovic D, Kocic G, Krstic D, Cvetkovic T, Pavlovic V: Melatonin reduces oxidative stress induced by chronic exposure of microwave radiation from mobile phones in rat brain. *J Radiat Res* 49(6): 579-586, 2008
51. Umur AS, Yaldiz C, Bursali A, Umur N, Kara B, Barutcuoglu M, Vatansever S, Selcuki D, Selcuki M: Evaluation of the effects of mobile phones on the neural tube development of chick embryos. *Turk Neurosurg* 23(6):742-752, 2013
52. Wang LX, Huang HH, Lv GR: Cts of prenatal exposure of 850-1900 MHz mobile phone on the expression of PCNA and DCX in dentate gyrus of offspring rats. *Zhongguo Ying Yong Sheng Li Xue Za Zhi* 34(1):35-38, 2018
53. Yang M, Guo W, Yang C, Tang J, Huang Q, Feng S, Jiang A, Xu X, Jiang G: Mobile phone use and glioma risk: A systematic review and meta-analysis. *PLoS One* 12(5):e0175136, 2017
54. Zurek J, Fedora M: Dynamics of glial fibrillary acidic protein during traumatic brain injury in children. *J Trauma* 71(4):854-859, 2011