



Safe Cervical ICA Control for Clipping Clinoid-Ophthalmic Segment ICA Aneurysms

Parth JANI, Suresh N MATHURIYA, Sivashanmugam DHANDAPANI

Post Graduate Institute of Medical Education & Research (PGIMER), Department of Neurosurgery, Chandigarh, India

Corresponding author: Sivashanmugam DHANDAPANI ✉ ssdhandapani.neurosurg@gmail.com

Sir, surgical clipping is still the mainstay for treating aneurysmal subarachnoid hemorrhage in developing countries due to the cost involved in endovascular management (1,2). One of the mandatory pre-requisites for clipping aneurysms in clinoid and ophthalmic segments of the internal carotid artery (ICA) is to have a proximal control of cervical ICA not only to prevent or control intra-operative aneurysm rupture (IAR) but even to safely dissect the aneurysm & also to delineate the proximal neck of the aneurysm. However, few issues are challenging the conventional method of looping the cervical ICA (Figure 1).

Firstly, the handling and looping of cervical ICA may risk dislodgement of an atherosclerotic plaque or cause dissection, adding on to vasospasm leading to ischemic stroke and its morbidity, thereby increasing the socio-economic burden (4,6-8). Secondly, rare anatomical variations at the common carotid artery (CCA) bifurcation may result in inadvertent looping of the external carotid artery (ECA) instead of ICA, thereby causing failure to achieve proximal control and significant bleeding in case of IAR (3,5). There have been no methods published in the literature to prevent cervical ICA handling hazards.

We propose a modification in the proximal control technique to minimize cervical ICA handling and related complications. Following exposure of the CCA-ECA-ICA junction in the neck, instead of direct handling of the ICA, we propose to take individual control of both ECA (proximal to its first branch) and CCA (Figure 2). With temporary occlusion of direct flow in the ICA from CCA and the ECA's backflow, we achieve full proximal control for exposing the aneurysm.

In this scenario, the ICA handling is minimized to prevent atherosclerotic plaque disruption and dissection along the ICA. Additionally, in cases of anatomical variations of bifurcation, the proximal control is still secure. The authors have been using this technique for many years. It has been beneficial,

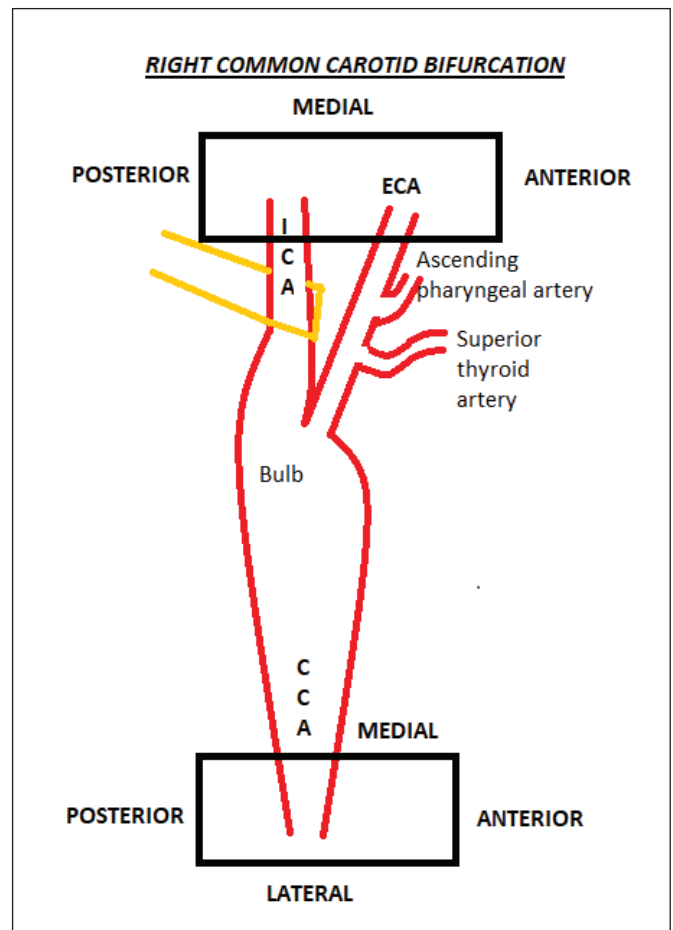


Figure 1: Conventional looping of cervical ICA for proximal control.

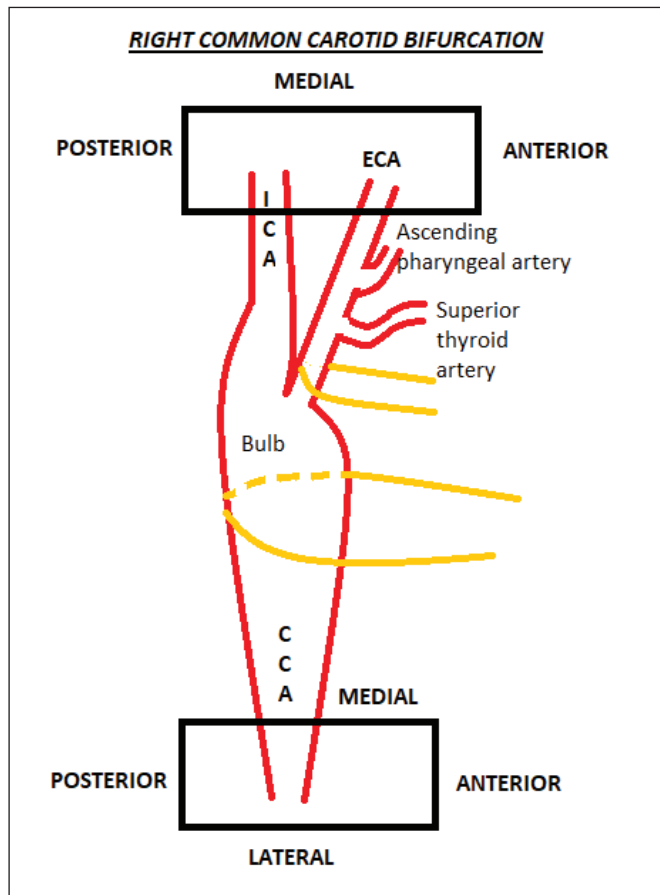


Figure 2: Our proposed technique for proximal control.

without additional technical complexities or prolongation of surgical time.

REFERENCES

1. Dhandapani S, Narayanan R, Dhandapani M, Bhagat H: How safe and effective is shifting from pterional to supraorbital keyhole approach for clipping ruptured anterior circulation aneurysms? A surgeon's transition phase comparative study. *J Neurosci Rural Pract* 2021 (Epub ahead of print)
2. Dhandapani S, Singh A, Singla N, Praneeth K, Aggarwal A, Sodhi HB, Pal SS, Goudihalli S, Salunke P, Mohindra S, Kumar A, Gupta V, Chhabra R, Mukherjee KK, Tewari MK, Khandelwal N, Mathuriya SN, Khosla VK, Gupta SK: Has outcome of subarachnoid hemorrhage changed with improvements in neurosurgical services? *Stroke* 49:2890-2895, 2018
3. Gluncic V, Petanjek Z, Marusic A, Gluncic I: High bifurcation of common carotid artery, anomalous origin of ascending pharyngeal artery and anomalous branching pattern of external carotid artery. *Surg Radiol Anat* 23:123-125, 2001
4. Kapoor A, Dhandapani S, Gaudihalli S, Dhandapani M, Singh H, Mukherjee KK: Serum albumin level in spontaneous subarachnoid haemorrhage: More than a mere nutritional marker! *Br J Neurosurg* 32:47-52, 2018
5. Kathuria S, Gregg L, Chen J, Gandhi D: Normal cerebral arterial development and variations. *Semin Ultrasound CT MR* 32:242-51, 2011
6. Mahak C, Shashi, Yashomati, Hemlata, Manisha N, Sandhya G, Dheeraj K, Dhandapani M, Dhandapani SS: Assessment of utilization of rehabilitation services among stroke survivors. *J Neurosci Rural Pract* 9:461-467, 2018
7. Rao TS, Sethi PK: Persistent proatlantal artery with carotid-vertebral anastomosis. Case report. *J Neurosurg* 43:499-501, 1975
8. Thomas LC, Rivett DA, Attia JR, Parsons M, Levi C: Risk factors and clinical features of craniocervical arterial dissection. *Man Ther* 16:351-356, 2011