



# Statistical Shape Analyses of the Brainstem in Chiari Patients

Gokhan OCAKOGLU<sup>1</sup>, Mevlut Ozgur TASKAPILIOGLU<sup>2</sup>, Oguz ALTUNYUVA<sup>2</sup>, Selcuk YILMAZLAR<sup>2</sup>

<sup>1</sup>Uludag University Faculty of Medicine, Department of Biostatistics, Bursa, Turkey

<sup>2</sup>Uludag University Faculty of Medicine, Department of Neurosurgery, Bursa, Turkey

**Corresponding author:** Gokhan OCAKOGLU ✉ gocakoglu@gmail.com

## ABSTRACT

**AIM:** To ascertain whether the brain stem's shape differs in patients with syrinx and without syrinx in cases with Chiari malformation Type I (CM-1), relative to healthy controls.

**MATERIAL and METHODS:** Data on marked brainstem regions were obtained from 2D digital image files. Generalized Procrustes analysis was used to evaluate shape differences among patients with syrinx, patients without syrinx, and healthy controls. Shape deformations among groups were examined by Thin Plate Spline (TPS) analysis.

**RESULTS:** According to the brain stem shape, there were differences between patients with syrinx and controls, and between patients without syrinx and controls. High-level deformations were also observed among the groups.

**CONCLUSION:** In the present study, the presence of shape deformations in Chiari patients' brainstem was demonstrated. This is the first study using a landmark-based geometrical morphometric method to demonstrate the shape difference in Chiari patients' brainstem.

**KEYWORDS:** Chiari malformation Type I, Brainstem, Shape, Statistical shape analysis

**ABBREVIATIONS:** **CM-I:** Chiari malformation Type I, **CSF:** Cerebrospinal Fluid Circulation, **MRI:** Magnetic resonance imaging, **TPS:** Thin Plate Spline

## INTRODUCTION

When cerebellar tonsils are placed  $\geq 5$  mm below the foramen magnum, the situation is referred to as Chiari malformation Type I (CM-I). The prevalence of CM-1 has been reported to be 0.6%–1% (1). Due to obstruction in Cerebrospinal Fluid Circulation (CSF) circulation, formation of syrinx of the spinal cord can be observed in these patients. CM-I patients are known to be generally asymptomatic. Posterior headache and/or neck pain, nausea, vomiting, vertigo, ataxia, as well as sensory and motor deficits may be the presented signs and symptoms. Lower cranial nerve involvement indicates hydrocephalus, brain stem, and cerebellar compression.

In recent years, the increase in number of studies examining the effects of a specific disease or environmental factors

in terms of organ's geometric properties or structure is remarkable (14,17-19,22). However, there is no study conducted in literature on the shape of brain stem. Studies in this area mostly focused on brain stem's functional properties (7,9,10).

With advances in imaging technology, modern geometric morphometric-based methods, such as statistical shape analysis, can use the organ's shape as input data (16). The statistical shape analysis allows the interpretation of the differences in shape, with comments on the general or localized possible deformations that occur in the structure or organ of interest.

This study aimed to evaluate the presence of any difference in the shape of brainstem in CM-I patients with syrinx and without syrinx, relative to healthy controls.

## ■ MATERIAL and METHODS

### Subjects

The cranial sagittal magnetic resonance imaging (MRI) scans of 10 (5 males, 5 females) patients with syrx (mean age:  $32.80 \pm 8.42$  years, age range: 18–50 years), 15 (2 males, 13 females) patients without syrx (mean age:  $35.73 \pm 12.05$  years, age range: 19–63 years) and 25 (9 males, 16 females) healthy controls (mean age:  $35.60 \pm 9.85$  years, age range: 18–55 years) were included in this study. T2-weighted sagittal images of CM-I patients and healthy controls admitted to Uludag University Faculty of Medicine, Department of Neurosurgery, between July 2013 and November 2017, acquired from 3 Tesla MRI imaging system (Philips Achieva 3T, Best, Netherlands) using a 32-channel head coil, were evaluated retrospectively.

The inclusion criteria for this study were as follows: All patients older than 18 years of age; patients that had been operated on in our clinic; and patients that had at least 1-year follow-up. The patients' cerebellar tonsils had to be displaced 5 mm or more from the foramen magnum and there was no significant pathology other than CM-I on their MRI.

Ethics committee approval was obtained for this retrospective study from the Ethics Committee of the Faculty of Medicine of Bursa Uludag University. All the patients and the controls gave their informed consent prior to the commencement of the study.

### Collection of Two-Dimensional Cranial Landmarks

Shape data of the brainstem regions were obtained from 2D digital images corresponding to midsagittal plane (Figure 1) by marking ten anatomical landmarks. TPSDIG version 2.04 (20) software was used to mark selected landmarks on the digital images. Identifications of these markings are shown in Table I.

### Geometric Morphometric Analysis

**Statistical Shape Analysis:** Shape difference among patients with syrx, without syrx, and healthy control was examined by conducting Generalized Procrustes analysis. Homogeneity of variance-covariance matrices was tested by Box's M approach. Hotelling  $T^2$  test procedure was used to determine the shape differences (16). To assess the study groups' overall shape variability measures, we considered the root mean square of Kendall's Riemannian distance. Shape deformations were evaluated by Thin Plate Spline (TPS) analysis (3).

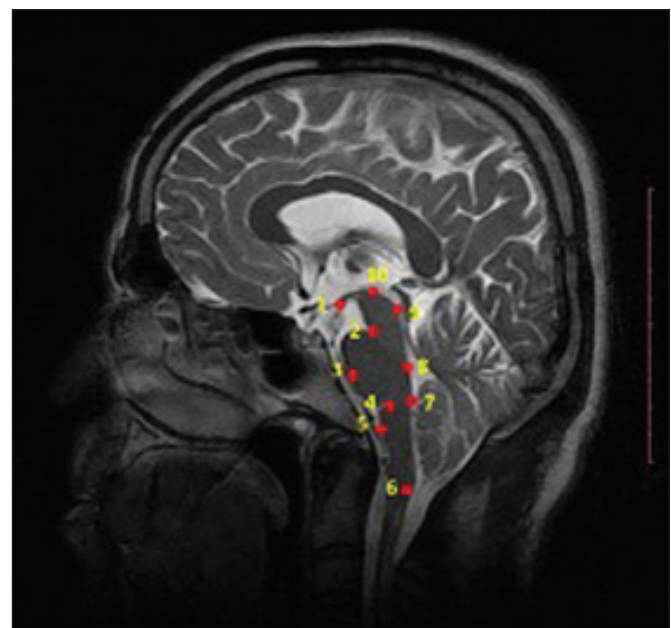
**General Statistical Analysis:** Shapiro-Wilk test was used to examine the suitability of the age data to normal distribution. One-way analysis of variance test was used to compare age difference among groups. Gender distribution was compared between groups using Fisher-Freeman-Halton test. Type I error rate was set at  $\alpha = 5\%$  for statistical significance. For pairwise comparisons, Bonferroni correction was applied and adjusted statistical significance was set at  $p < 0.017$ . SPSS (21), R 3.5.1 (23) and PAST 3.0 (6) software were used for the statistical analysis.

## ■ RESULTS

Age and sex did not differ among the groups ( $p=0.741$  and  $p=0.128$ , respectively). Differences in shape of the brainstem between groups were analyzed by statistical shape analysis. Procrustes mean shapes were computed for the groups (Figure 2). According to the brain stem shape, there was a difference between patients with syrx and controls ( $p=0.002$ ) and between patients without syrx and controls ( $p<0.001$ ). On the other hand, there was no difference between patients with a syrx and without syrx according to the brain stem's shape ( $p=0.099$ ). According to the shape variation, the brainstem evaluation showed that the highest variation occurred in patients with syrx (0.120), followed by patients without syrx (0.104) and healthy controls (0.099).

**Table I:** Definitions of Landmarks Used in the Present Study

Landmark Number	Description
Landmark 1	Mammillary body
Landmark 2	Sulcus pontocruralis
Landmark 3	Anterior line of pons
Landmark 4	Sulcus pontobulbaris
Landmark 5	Anterior median line of medulla oblangata
Landmark 6	Inferior of medulla oblangata
Landmark 7	Obex
Landmark 8	Floor of fourth ventricle
Landmark 9	Posteromedian line of tectum
Landmark 10	Superior of midbrain



**Figure 1:** Landmark markings on the brainstem.

High-level deformations from patients with syrinx to the control group for brainstem were observed in TPS graph (Figure 3). The region inferior to the medulla oblongata (landmark 6) had the highest deformation. In patients with syrinx, it was observed that there was a localized deformation in the region inferior to the medulla oblongata of the average brain stem in the direction of enlargement and elongation, according to the healthy controls.

Similarly, when Figure 4 was examined, it was observed that the most severe deformation occurred in the region inferior to the medulla oblongata in patients without syrinx and there was a localized deformation in the direction of expansion and extension.

When analyzing the deformation of the mean brainstem shape of patients with syrinx, relative to the mean shape of patients without syrinx, it is observed that there is a narrowing, especially in the lower part of the tail region and in the region where the y axis is close to 40 (Figure 5).

■ DISCUSSION

CM’s definition was first described as the herniation of the posterior brain in 1891 (13). Through the definition’s scope, cerebellum descending through foramen magnum receives all the attention. Crushing of the brainstem at the level of the foramen magnum is also present. The gold standard treatment for CM with or without syringomyelia is decompression of the posterior fossa. Generally, opening the dura is recommended for patients with syrinx.

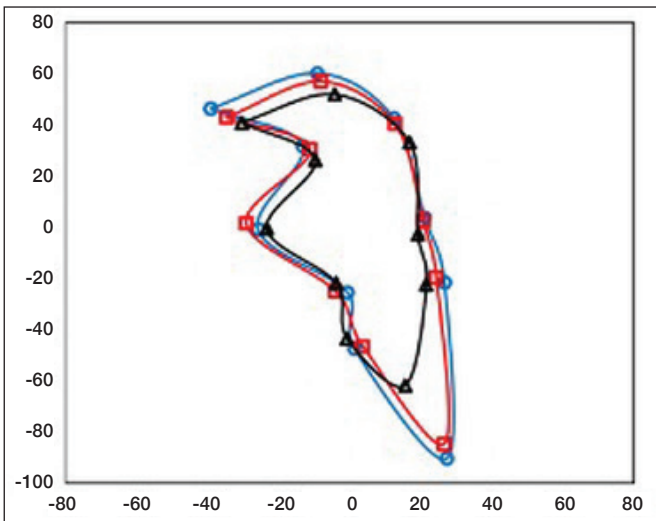


Figure 2: Procrustes mean shapes for the brainstem images of patients with syrinx (o), patients without syrinx (□) and healthy controls (Δ).

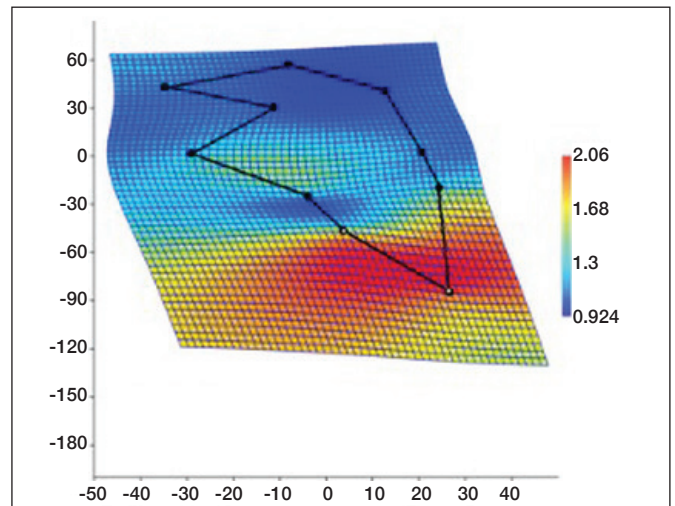


Figure 3: A thin-plate spline demonstrating the average brainstem shape deformation for patients with syrinx compared to healthy controls.

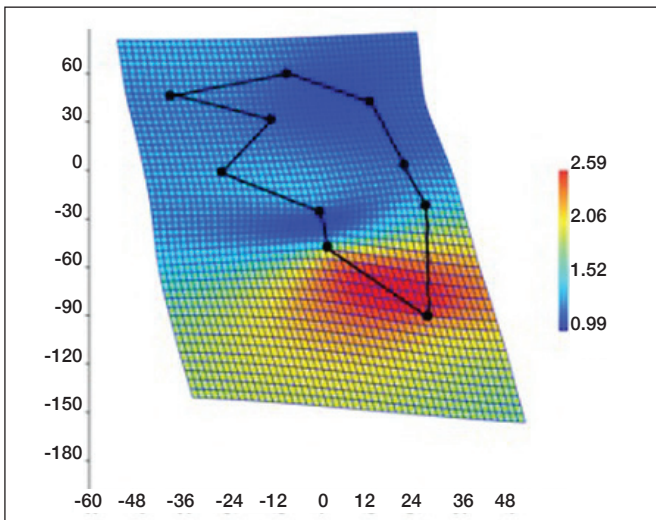


Figure 4: A thin-plate spline demonstrating the average brainstem shape deformation for patients without syrinx compared to healthy controls.

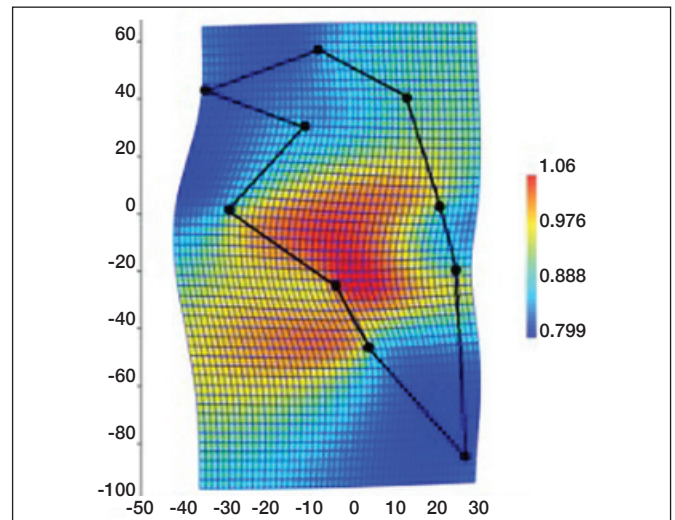


Figure 5: A thin-plate spline demonstrating the average brainstem shape deformation for patients with syrinx compared to patients without syrinx.

We performed a landmark-based shape analysis to evaluate the shape changes of the brainstem of CM-I patients. Detection of both regional and global changes was possible with this approach. In addition, differences in changes between CM-I patients and healthy controls were evaluated. Advances in imaging technology and tendency to investigate the effects of diseases and environmental factors on organs or organisms' anatomical structure are the underlying reasons for the wide use of statistical shape analysis in medicine (15).

In a morphometric study by Khalsa et al. , six 2D anatomical MRI measurements and four 3D volumetric measurements of the posterior fossa were used in the retrospective analysis of 102 CM-I patients. The authors demonstrated that no significant difference between asymptomatic and symptomatic CM-I groups were detected in either 2D morphometric or 3D volumetric measurements (8). Comparison of radiographic posterior cranial fossa parameters between CM-I patients and healthy subjects was performed in many morphometric studies in literature (2,4,5). Although several parameters were investigated, there is paucity of information regarding the brainstem morphology of CM-I patients. Comparison of shape analysis of the brainstems of CM-I patients and healthy controls brainstems were performed in the present study, resulting in a significant difference between the CM-I patients and healthy controls.

In this study, shape variability was higher in patients with or without syrinx than in healthy controls. A high degree of brainstem shape deformation was found as a result of comparison of mean shapes of the patients to that of the healthy controls. The greatest deformation was detected in the tail region of the brainstem as enlargement and elongation. According to the brainstem's mean shape, when the patients with syrinx were compared to those without syrinx, a narrowing was observed in the brainstem tail region.

The diagnosis of CM-I is based on radiological anatomical finding. Milhorat et al. reported that some patients that present symptoms don't have an apparent anatomical malformation and that some of these patients' symptoms were relieved after sub-occipital decompression (11). The failure of the traditional anatomical definition suggests the investigation of the compression of the brain stem of CM-I patients. Krishna et al. detected a difference in fractional anisotropy in the lower brain stem of CM-I patients than in the healthy controls. This anisotropy was normalized after decompression (9). Moncho et al. studied brain stem auditory evoked potentials and somatosensory evoked potential (SSEP) alterations in CM-I patients (12). In a 545-patient series, the authors detected evoked potential alterations regardless of radiological findings, which was consistent with Krishna et al.'s results, thus showing the importance of brain stem compression at CM-I.

## CONCLUSION

Shape deformations in Chiari patients' brainstem were demonstrated in the present study. This is the first study using a landmark-based geometrical morphometric method and showing the shape differences in Chiari patients' brainstems by considering the topographic distribution.

## REFERENCES

1. Aboulezz AO, Sartor K, Geyer CA, Gado MH: Position of cerebellar tonsils in the normal population and in patients with Chiari malformation: A quantitative approach with MR imaging. *J Comput Assist Tomogr* 9:1033-1036, 1985
2. Aydin S, Hanimoglu H, Tanriverdi T, Yentur E, Kaynar MY: Chiari type I malformations in adults: A morphometric analysis of the posterior cranial fossa. *Surg Neurol* 64:237-241, 2005
3. Bookstein FL: Principal warps: Thin-plate splines and the decomposition of deformations. *IEEE Trans Pattern Anal Mach Intell* 11:567-585, 1989
4. Dagtekin A, Avci E, Kara E, Uzmansel D, Dagtekin O, Koseoglu A, Talas D, Bagdatoglu C: Posterior cranial fossa morphometry in symptomatic adult Chiari I malformation patients: Comparative clinical and anatomical study. *Clin Neurol Neurosurg* 113:399-403, 2011
5. Furtado SV, Reddy K, Hegde A: Posterior fossa morphometry in symptomatic pediatric and adult Chiari I malformation. *J Clin Neurosci* 16:1449-1454, 2009
6. Hammer Ø, Harper D, Ryan P: Paleontological statistics software: Package for education and data analysis. *Palaeontologia Electronica* 1:9-18, 2001
7. Houston JR, Allen PA, Rogers JM, Lien M-C, Allen NJ, Hughes ML, Bapuraj JR, Eppelheimer MS, Loth F, Stoodley MA: Type I Chiari malformation, RBANS performance, and brain morphology: Connecting the dots on cognition and macrolevel brain structure. *Neuropsychology* 33:725, 2019
8. Khalsa SSS, Geh N, Martin BA, Allen PA, Strahle J, Loth F, Habtzghi D, Serrano AU, McQuaide D, Garton HJ: Morphometric and volumetric comparison of 102 children with symptomatic and asymptomatic Chiari malformation Type I. *J Neurosurg Pediatr* 21:65-71, 2018
9. Krishna V, Sammartino F, Yee P, Mikulis D, Walker M, Elias G, Hodaie M: Diffusion tensor imaging assessment of microstructural brainstem integrity in Chiari malformation Type I. *J Neurosurg* 125:1112-1119, 2016
10. Kurtcan S, Alkan A, Yetis H, Tuzun U, Aralasmak A, Toprak H, Ozdemir H: Diffusion tensor imaging findings of the brainstem in subjects with tonsillar ectopia. *Acta Neurol Belg* 118:39-45, 2018
11. Milhorat TH, Chou MW, Trinidad EM, Kula RW, Mandell M, Wolpert C, Speer MC: Chiari I malformation redefined: Clinical and radiographic findings for 364 symptomatic patients. *Neurosurgery* 44:1005-1017, 1999
12. Moncho D, Poca MA, Minoves T, Ferré A, Cañas V, Sahuquillo J: Are evoked potentials clinically useful in the study of patients with Chiari malformation Type 1? *J Neurosurg* 126:606-619, 2017
13. Oakes WJ, Tubbs RS: Chiari malformations. In: Youmans J (ed), *Youman's Neurological Surgery*, Philadelphia: Elsevier Saunders, 2004:3347- 3361
14. Ocakoglu G, Baykal D, Altunyuva O, Taskapilioglu MO, Yilmazlar S: Statistical shape analysis of cerebellum in patients with chiari malformation I. *J Craniofac Surg* 30:1683-1685, 2019
15. Ocakoglu G, Ercan I: Traditional and modern morphometrics. *Turkiye Klinikleri J Biostat* 5(1):37-41, 2013

16. Ocakoglu G, Ercan I: Type I error rate for two-sample tests in statistical shape analysis. *Hacet J Math Stat* 41:141-152, 2014
17. Ocakoglu G, Ozdemir ST, Ercan I, Etoz A: The shape of the external human ear: A geometric morphometric study. *Turkiye Klinikleri J Med Sci* 33:184-190, 2013
18. Ocakoglu G, Taskapilioglu MO, Ercan I, Demir AB, Hakyemez B, Bekar A, Bora I: Statistical shape analysis of temporal lobe in mesial temporal sclerosis patients. *Acta Neurochir (Wien)* 157:1897-1903, 2015
19. Ocakoglu G, Taskapilioglu MO, Kaya S, Yazici Z: Statistical shape analyses of patients with scaphocephaly after surgical remodeling. *Turk Neurosurg* 30:382-386, 2020
20. Rohlf F: TpsDig, ver. 2.04. Department of Ecology and Evolution, Stony Brook, State University of New York, 2005
21. SPSS: Statistics for Windows, version 20.0. IBM Corp., Armonk, NY, 2012
22. Taskapilioglu MO, Ocakoglu G, Kaya S, Baykal D: Statistical shape analyses of trigonocephaly patients. *Childs Nerv Syst* 36:379-384, 2020
23. Team RC: A language and environment for statistical computing. R Foundation for Statistical Computing, Vienna, 2013