

# The Preventive Effect of Systemic Honokiol and Systemic Pentoxifylline on Epidural Fibrosis

Kutsal Devrim SECINTI<sup>1</sup>, Ilke Evrim SECINTI<sup>2</sup>, Ergul BELGE KURUTAS<sup>3</sup>

<sup>1</sup>Kahramanmaraş Sutcu Imam University School of Medicine, Department of Neurosurgery, Kahramanmaraş, Turkey

<sup>2</sup>Hatay Mustafa Kemal University School of Medicine, Department of Pathology, Hatay, Turkey

<sup>3</sup>Kahramanmaraş Sutcu Imam University School of Medicine, Department of Biochemistry, Kahramanmaraş, Turkey

**Corresponding author:** Kutsal Devrim SECINTI ✉ devrimsecinti@yahoo.com

## ABSTRACT

**AIM:** To investigate the preventive effects of systemic honokiol and pentoxifylline treatments on epidural fibrosis (EF) in the experimental laminectomy model.

**MATERIAL and METHODS:** Thirty-two rats were divided into four equal groups. Laminectomy was performed in all rats except for the control group. One group was kept as the negative control group. Moreover, 10 mg/kg pentoxifylline and 10 mg/kg honokiol were administered intraperitoneally for 5 days, respectively, to the other two groups. The rats were sacrificed after 4 weeks. The samples were examined biochemically in terms of oxidative stress and inflammation induced by tissue damage. Histopathological and immunohistochemical investigations were also performed to detect EF severity.

**RESULTS:** In honokiol and pentoxifylline groups compared with the negative control group, tumor necrosis factor-beta and interleukin-10 levels (indicating inflammation); myeloperoxidase, malondialdehyde, and hydroxyproline levels (indicating oxidative stress); and intercellular adhesion molecule levels (indicating fibrosis) were decreased. Histopathologically and immunohistochemically, EF was significantly reduced in the pentoxifylline and honokiol groups. Biochemical findings were consistent with the histopathological and immunohistochemical findings.

**CONCLUSION:** Both pentoxifylline and honokiol prevent EF formation. However, this effect is more pronounced in honokiol.

**KEYWORDS:** Oxidative stress, Cytokines, Epidural fibrosis, Honokiol, Pentoxifylline

**ABBREVIATIONS:** ANOVA: Analysis of variance, ARRIVE: Animal Research: Reporting of In Vivo Experiments, DAB: 3,3'-Diaminobenzidine, DMSO: Dimethyl sulphoxide, ELISA: Enzyme-linked immunosorbent assay, EF: Epidural Fibrosis, g: gram, HNK: Honokiol, HSD: Honestly significant difference, HYP: Hydroxyproline, ICAM-1: Intercellular adhesion molecule-1, IL-10: Interleukin-10, KCl: Potassium chloride, kg: Kilogram, L1: First lumbar vertebra, L4: Fourth lumbar vertebra, max: Maximum, MDA: Malondialdehyde, min: Minimum, mg: Milligram, MPO: Myeloperoxidase, PBS: Phosphate buffered saline, PNT: Pentoxifylline, ROS: Radical oxygen species, TNF-β: Tumor necrosis factor-beta, μL: Micro liter

## INTRODUCTION

Epidural fibrosis (EF), which develops after laminectomy and is characterized by excessive scar tissue, is one of the most important factors of surgical failure (9,17). Although it is accepted to be a natural process of wound healing, it is responsible for a considerable rate of failed back

surgery syndrome (1,5). Many of the materials, including antineoplastic agents, Teflon membranes, gel foam, sodium hyaluronate, steroids, and others have been used in the literature to prevent EF (2,4,10,11,18,19,35). However, their clinical use has not yet been successful although their use has been successfully shown in animal models.

Honokiol (HNK) is a phenylpropanoid molecule obtained from *Magnolia officinalis* (39). It has antioxidative, antineoplastic, anti-inflammatory, antimigratory, and antiangiogenic properties (15,20,25,27,32,37). Due to all these features, honokiol has been thought to have the potential to have antifibrotic features. A study also exists that supports this idea and argues that it is successful in preventing renal fibrosis (7).

Pentoxifylline (PNT) is a methylxanthine derivative (28). It has anti-inflammatory effects leading to a decrease in neutrophil secretion and inhibition of the production of radical oxygen species (16). It also mediates the inhibition of thromboxane production, which is a stimulator of platelet aggregation, and also increases the collagenase activity (3). It has also been shown to reduce postoperative peritoneal fibrosis and adhesion formation (23).

The effects of systemic PNT administration on EF were examined before and was found to be successful (18). However, the effects of systemic HNK on EF have not been studied before until May 2016, which was the date that the current study was planned and commenced.

This study compared in experimental laminectomy model the effects of systemic HNK and PNT applications against EF.

## ■ MATERIAL and METHODS

### Animals, Chemicals, and Experimental Set-up

The presented study was in compliance with the Animal Research: Reporting of In Vivo Experiments guidelines and carried out following the UK Animals (Scientific Procedures) Act of 1986 and associated guidelines.

Pentoxifylline (CAS: 6493-05-6) and honokiol (CAS 35354-74-6; Sigma-Aldrich, St. Louis, MO, USA) used in the study were dissolved in dimethyl sulfoxide (DMSO). After the approval of the University's Local Ethics Committee, 32 female Wistar albino rats (mean weight, 250 g; min: 229 g, max: 265 g) were divided into four equal groups.

Group 1 was represented the control group. Thus, no surgical procedure was performed. All rats in the other three groups were anesthetized and intramuscularly administered with 10 and 30 mg/kg Rompun and Ketalar, respectively. Total laminectomy (L1–L4 levels) was performed. The surgical area was closed without any additional procedure. In groups 3 and 4, 500 µL of pentoxifylline (10 mg/kg) and 500 µL of honokiol (10 mg/kg) were intraperitoneally applied during the 5 days after surgery (When the study was planned and commenced in May 2016, no data were available for honokiol in the literature against EF. Thus, the honokiol dose was decided to be the same as the pentoxifylline dose for ease of comparison). Every injection dose contained 2.5 mg of honokiol or pentoxifylline in 500 µL because the mean weight of the rats was 250 g. In groups 1 and 2, 500 µL of DMSO was injected intraperitoneally during the 5 days after surgery to exclude both the injection-induced stress on animals and also the effect of DMSO which was used as a solvent.

One hour before surgery, 50 mg/kg of ceftriaxone (Roche, Istanbul, Turkey) were intraperitoneally administered to all rats. Group 1 rats received a saline injection to exclude the injection-induced stress which may affect the oxidative stress markers used in the study. Consequently, rats were sacrificed by pentothal overdose after 4 weeks. Vertebrae matching the laminectomy site were removed en-block. The samples were taken for biochemical, histopathological, and immunohistochemical examinations.

### Biochemical Examination

The tissue samples were removed from the freezer, brought to room temperature, then homogenized with three volumes of ice-cold 1.15% KCl. The levels of all biochemical parameters were measured in the supernatant obtained from centrifugation at 14,000 rpm. Lipid peroxidation was reflected by malondialdehyde (MDA) levels, which were measured by the method described by Ohkawa et al. (26).

The levels of cytokines [interleukin-10 (IL-10) and tumor necrosis factor-beta (TNF-β)], intercellular adhesion molecule (ICAM), hydroxyproline (HYP), and myeloperoxidase (MPO) in the tissue samples were measured in duplicate using commercially available solid-phase sandwich enzyme-linked immunosorbent assay rat kits (MyBioSource Company, San Diego, CA, USA) according to the manufacturer's protocol.

### Histopathological Examination

Samples were fixed in 10% buffered formalin for 2 days. They were then decalcified in 10% formic acid for 2 days. Three transverse sections (proximal, middle, and distal) of 2-mm thickness were taken from the laminectomy site and were placed in cassettes before washing in running water for 3 h. After routine follow-up (13 h), 4-µm thick sections were taken from the tissues embedded in paraffin blocks and routine hematoxylin and eosin and Masson trichrome stainings were performed. All samples in each group were systematically assessed using an Olympus DP20 microscope digital camera system attached to an Olympus BX51 (Olympus Corp., Tokyo, Japan) light microscope. Staging of fibrosis in the dura was performed following He et al. (13).

### Immunohistochemical Examination

For the immunohistochemical investigation, 4-µm thick sections were obtained from the tissue paraffin blocks. The prepared sections were stained using osteopontin (OPN) antibody (prediluted polyclonal antibody, 1:100 dilution; ProteinTech, Chicago, IL, USA; catalog number: 25715-1-AP) using the streptavidin–biotin–peroxidase and microwave antigen retrieval combination method. After washing with phosphate-buffered saline, the slides were stained with 3,3'-diaminobenzidine chromogen (Glostrup, Denmark) for 7 min, followed by Mayer's hematoxylin (Thermo Fisher Scientific, NY, USA) for 1 min for counterstaining. Human stomach adenocarcinoma tissue was accepted as the positive control.

Samples stained with anti-OPN antibodies were evaluated by Olympus BX51 light microscope at low magnifications (×40 and ×100) and three different areas where the microvessel

density was the highest (hot spots) were selected. At  $\times 400$  magnification, single endothelial cells stained brown or clusters of interconnected endothelial cells were considered as a countable microvessel whether they contained a lumen or not. Vessels containing muscular layers were not considered as neovasculature and were not taken into account during counting. The mean number of microvessels from the three areas was calculated and recorded as microvessel density and graded as grade 1,  $\leq 3$  microvessels; grade 2, 4–6 microvessels; and grade 3,  $\geq 7$  microvessels (34).

### Statistical Analysis

Kruskal–Wallis and post hoc multiple pairwise comparisons were performed because histopathological and immunohistochemical data were ordinal. The Levene test was applied to determine homogeneity because the biochemical parameters were in a normal distribution with the Shapiro–Wilk test.

After one-way analysis of variance analysis, Tukey's honest significance difference test was applied and that data was found to be nonhomogeneously distributed. Therefore, Tamhane's T2 test, one of the post hoc tests, was performed. Moreover,  $p < 0.05$  was considered significant.

## ■ RESULTS

### Biochemical Examination

All the examined oxidative and inflammatory parameters were significantly increased in the negative control group compared with the control group. The statistical difference between the two groups was significant for all parameters except for MPO.

All parameters were higher for the PNT group when the PNT group was compared with the control group. However, no statistically significant difference exists between groups.

All parameters were found to be lower in the PNT group when the PNT group was compared with the negative control group. Statistically, a significant difference exists in terms of HYP, MDA, and IL-10 for the PNT group, while no significant difference in terms of TNF- $\beta$ , ICAM, and MPO exists.

When the HNK group was compared with the control group, HYP, IL-10, and TNF- $\beta$  were higher in the HNK group, while ICAM, MPO, and MDA were lower. Moreover, no significant difference was found between the groups in terms of any parameters studied.

When the HNK group was compared with the negative control group, all the values of the HNK group in terms of all parameters studied were found to be lower than the negative control group. It was determined that a significant difference exists for all parameters between the groups.

All parameters for the HNK group except for HYP were lower compared with the PNT group when the HNK group was compared with the PNT group. Moreover, the statistical difference between the HNK and PNT groups was found only for MDA. No difference was found in terms of other parameters (The median, minimum, and maximum values of biochemical markers according to the groups are summarized in Table I, and statistical comparisons are shown in Table II).

The correlation assessment was performed for biochemical parameters in the negative control group. A negative correlation exists between the HYP and TNF- $\beta$  ( $p = 0.047$ ,  $\rho = -0.714$ ) while IL-10 and TN-beta were positively correlated ( $p = 0.028$ ,  $\rho = 0.762$ ).

### Histopathological Examination

Grade 0 fibrosis was detected in all rats in the control group. In the negative control group, two and six rats were scored as grades 2 and 3 fibrosis, respectively. In the PNT group, two, five, and one rat had grades 1, 2, and 3 fibrosis, respectively. In the HNK group, grades 1 2 fibrosis was detected in five and three rats, respectively (Figure 1A–D). The results are summarized in Table III.

Statistical difference was significant when the HNK and negative control groups were compared ( $p = 0.038$ ). However, no significance exists between the PNT and negative control ( $p = 1.000$ ).

The HNK group was not statistically significant ( $p = 0.202$ ) when the control group was compared with the HNK and PNT groups. However, a statistical significance exists between the PNT and control groups ( $p = 0.003$ ).

### Immunohistochemical Examination

OPN scores were determined as 1 in all rats in the control group. In the negative control group, osteopontin scores were 2 and 3 in two and six rats, respectively. In the PNT group, six and two rats scored 2 and 3, respectively. In the HNK group, three rats scored 1 for OPN staining, while four and one rats scored 2 and 3 points, respectively (Figure 2A–D). The results are summarized in Table IV.

A statistical significance exists between the control and PNT groups in terms of OPN staining ( $p = 0.006$ ). No significance was noted in terms of control and HNK groups ( $p = 0.600$ ). Moreover, no significance was noted when the HNK and PNT were compared with each other ( $p = 1.000$ ; Table V).

## ■ DISCUSSION

The mechanisms underlying EF are complicated. Excessive accumulation of extracellular matrix components (e.g., collagen, fibronectin, dermatan sulfate) and a decrease in the cell density of the tissue result in EF (21,24).

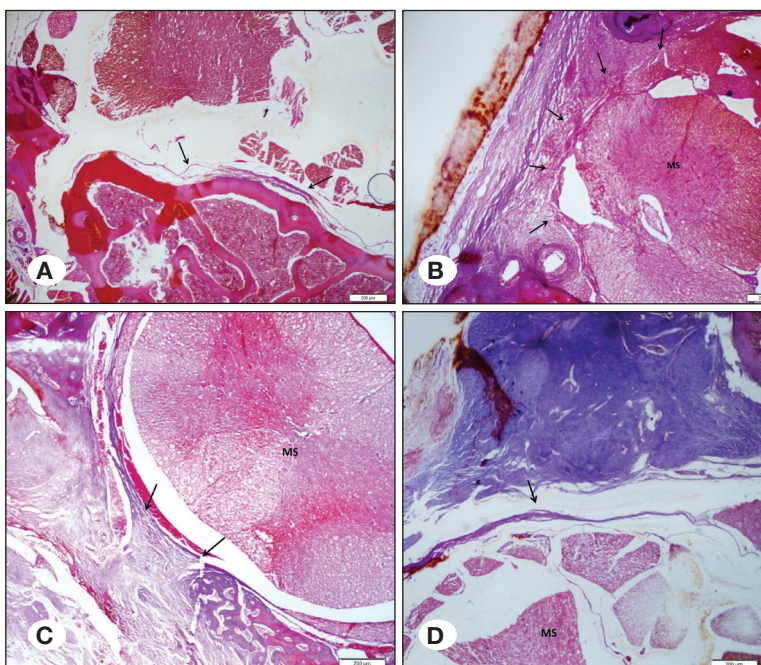
The nucleus pulposus contains a high rate of phospholipase A2 and the structure of the annulus fibrosus is destructed during discectomy and initiates the EF development by the leaking of phospholipase A2 into the epidural space (30,31).

Opinions associate the development of EF to the surgical procedure itself and bleeding in the surgical site. Accordingly, the primary cause of EF is chemotactic factors released from the fragmented erythrocytes and platelets in the surgical site after laminectomy and the migration of fibroblasts from the paraspinal muscles. Adhesions develop secondary to the hyperplasia of the fibrous connective tissue. Fibroblasts, the main actors in tissue repair, are activated by inflammatory cytokines and growth factors and tries to repair local defects

**Table I:** Comparisons of Mean Values of Biochemical Markers

	Group	Mean	Minimum	Maximum
ICAM-1	<b>Control</b>	<b>0.887</b>	<b>0.596</b>	<b>1.167</b>
	Neg Control	2.114	1.515	2.917
	PNT	1.426	0.788	2.669
	HNK	0.832	0.147	1.159
HYP	<b>Control</b>	<b>0.607</b>	<b>0.134</b>	<b>1.421</b>
	Neg Control	1.405	1.048	1.653
	PNT	0.647	0.501	0.795
	HNK	0.660	0.526	0.909
MPO	<b>Control</b>	<b>2.038</b>	<b>1.786</b>	<b>2.447</b>
	Neg Control	2.454	2.048	3.104
	PNT	2.223	1.599	2.931
	HNK	1.807	1.644	2.032
MDA	<b>Control</b>	<b>2.372</b>	<b>2.010</b>	<b>2.950</b>
	Neg Control	4.454	4.180	5.020
	PNT	2.989	2.430	3.630
	HNK	2.162	2.010	2.440
TNF-Beta	<b>Control</b>	<b>26.850</b>	<b>18.70</b>	<b>37.30</b>
	Neg Control	38.462	33.60	42.80
	PNT	28.500	16.30	41.80
	HNK	26.912	19.40	38.50
IL-10	<b>Control</b>	<b>41.55</b>	<b>31.65</b>	<b>54.08</b>
	Neg Control	76.72	45.29	94.18
	PNT	47.121	43.20	52.09
	HNK	40.829	38.06	43.54

**ICAM-1:** Intercellular adhesion molecule-1, **TNF- $\beta$ :** Tumor necrosis factor-beta, **IL-10:** Interleukin-10, **Neg Control:** Negative Control, **HNK:** Honokiol, **PNT:** Pentoxifylline, **HYP:** Hydroxyproline, **MPO:** Myeloperoxidase, **MDA:** Malondialdehyde.



**Figure 1:** Fibrosis scoring of groups by Masson trichrome staining. **A)** Group 1 (control): a thin dura mater (arrows) is seen and no fibrosis is observed. Fibrosis score = 0. **B)** Group 2 (negative control): large fibrosis and dura adhesion are seen in >2/3 of the laminectomy defect (arrows). Fibrosis score = 3. **C)** Group 3 (pentoxifylline): fibrosis constitutes less than <2/3 of laminectomy defect (arrows). Fibrosis score = 2. **D)** Group 4 (honokiol): a tiny fibrous band is seen (arrows) between the dura mater and the scar tissue. Fibrosis score = 1. MS medulla spinalis; Masson trichrome,  $\times 40$ ).



**Table II:** Statistical Comparisons of Groups in Terms of Biochemical Markers

Group	Comparisons	p	Significance (p<0.05)	Group	Comparisons	p	Significance (p<0.05)	Group	Comparisons	p	Significance (p<0.05)
<b>ICAM-1</b>				<b>Hydroxyproline</b>				<b>Myeloperoxidase</b>			
<b>Ctrl</b>	nCtrl	0.002	S	<b>Ctrl</b>	nCtrl	0.016	S	<b>Ctrl</b>	nCtrl	0.341	NS
	PNT	0.167	NS		PNT	1.000	NS		PNT	1.000	NS
	HNK	1.000	NS		HNK	1.000	NS		HNK	0.327	NS
<b>nCtrl</b>	Ctrl	0.002	S	<b>nCtrl</b>	Ctrl	0.016	S	<b>nCtrl</b>	Ctrl	0.341	NS
	PNT	0.022	S		PNT	<0.001	S		PNT	0.999	NS
	HNK	0.005	S		HNK	<0.001	S		HNK	0.032	S
<b>PNT</b>	Ctrl	0.167	NS	<b>PNT</b>	Ctrl	1.000	NS	<b>PNT</b>	Ctrl	1.000	NS
	nCtrl	0.022	S		nCtrl	<0.001	S		nCtrl	0.999	NS
	HNK	0.572	NS		HNK	1.000	NS		HNK	0.605	NS
<b>HNK</b>	Ctrl	1.000	NS	<b>HNK</b>	Ctrl	1.000	NS	<b>HNK</b>	Ctrl	0.327	NS
	nCtrl	0.005	S		nCtrl	<0.001	S		nCtrl	0.032	S
	PNT	0.572	NS		PNT	1.000	NS		PNT	0.605	NS
<b>Malondialdehyde</b>				<b>TNF-β</b>				<b>IL-10</b>			
<b>Ctrl</b>	nCtrl	<0.001	S	<b>Ctrl</b>	nCtrl	0.034	S	<b>Ctrl</b>	nCtrl	0.004	S
	PNT	0.070	NS		PNT	1.000	NS		PNT	0.815	NS
	HNK	0.975	NS		HNK	1.000	NS		HNK	1.000	NS
<b>nCtrl</b>	Ctrl	<0.001	S	<b>nCtrl</b>	Ctrl	0.034	S	<b>nCtrl</b>	Ctrl	0.004	S
	PNT	<0.001	S		PNT	0.340	NS		PNT	0.019	S
	HNK	<0.001	S		HNK	0.021	S		HNK	0.006	S
<b>PNT</b>	Ctrl	0.070	NS	<b>PNT</b>	Ctrl	1.000	NS	<b>PNT</b>	Ctrl	0.815	NS
	nCtrl	<0.001	S		nCtrl	0.340	NS		nCtrl	0.019	S
	HNK	0.002	S		HNK	1.000	NS		HNK	0.062	NS
<b>HNK</b>	Ctrl	0.975	NS	<b>HNK</b>	Ctrl	1.000	NS	<b>HNK</b>	Ctrl	1.000	NS
	nCtrl	<0.001	S		nCtrl	0.021	S		nCtrl	0.006	S
	PNT	0.002	S		PNT	1.000	NS		PNT	0.062	NS

**ICAM-1:** Intercellular adhesion molecule-1, **TNF-β:** Tumor necrosis factor-beta, **IL-10:** Interleukin-10, **nCtrl:** Negative Control, **Ctrl:** Control, **HNK:** Honokiol, **PNT:** Pentoxifylline, **S:** Significant, **NS:** Non significant.

**Table III:** Fibrosis Degrees according to Groups

Group	Definition	Fibrosis Degree by Masson trichrome			
		0	1	2	3
<b>Group-1</b>	Control	8	0	0	0
<b>Group-2</b>	Neg Control	0	0	2	6
<b>Group-3</b>	PNT	0	2	5	1
<b>Group-4</b>	HNK	0	5	3	0

**Neg Control:** Negative control, **HNK:** Honokiol, **PNT:** Pentoxifylline.

in the vertebral lamina. Fibroblasts transform into fibrocytes with the production of collagen fibrils. Thus, scar tissue is formed from the fibrous connective tissue (5).

In brief, fibroblasts and inflammatory response play an important role in wound healing. Once fibroblasts are

activated by inflammatory factors, they produce collagen fibers and spread them around as part of the healing process. However, exaggerated inflammatory response and fibrotic process cause excessive deposition of local collagen. Consequently, excessive growth of scar tissue transformed from the fibrous tissue can cause compression of the dura

**Table IV:** Comparisons of Groups in Terms of Osteopontin Scores

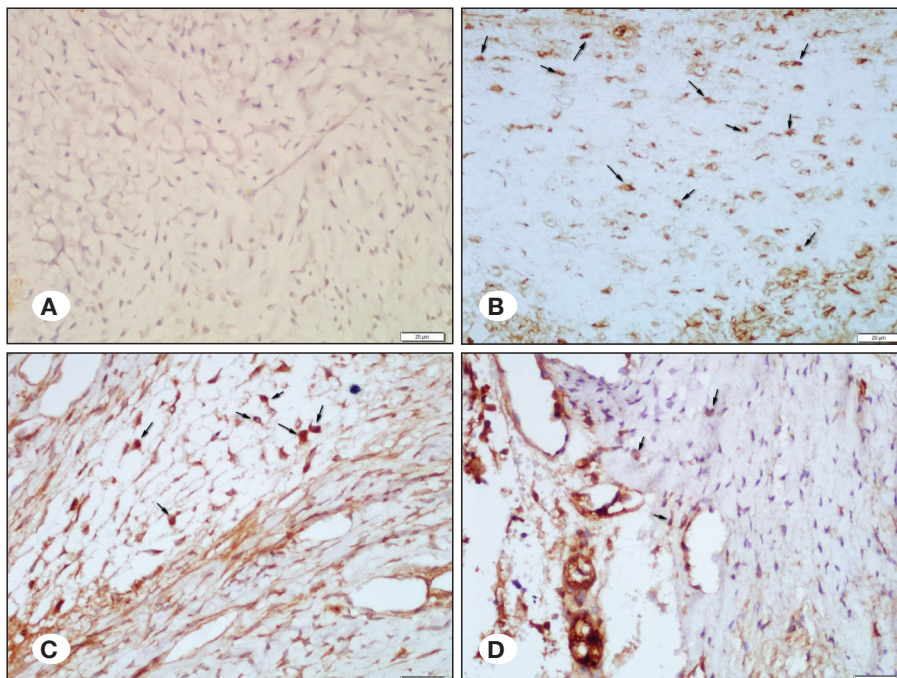
Group	Definition	Osteopontin Score		
		1	2	3
Group-1	Control	8	0	0
Group-2	Negative Control	0	2	6
Group-3	PNT	0	6	2
Group-4	HNK	3	4	1

**HNK:** Honokiol, **PNT:** Pentoxifylline.

**Table V:** Comparisons of Groups in Terms of Fibrosis Scores and Osteopontin Stainings

Compared Groups	p value for Fibrosis ( $p < 0.05$ significant)	p value for OPN staining ( $p < 0.05$ significant)
Control-HNK	0.202	0.600
Control-PNT	<b>0.003</b>	<b>0.006</b>
Control-Negative Control	<b>&lt;0.001</b>	<b>&lt;0.001</b>
HNK-Negative Control	<b>0.038</b>	0.143
PNT-Negative Control	1.000	1.000
HNK-PNT	1.000	1.000

**HNK:** Honokiol, **PNT:** Pentoxifylline. Statistically significant comparisons marked as bold.



**Figure 2:** Microvessel density of groups by osteopontin immunostaining. **A)** Group 1 (control): no microvessel was seen in osteopontin staining. Score = 1. **B)** Group 2 (negative control): numerous new vessel formation (arrows) were observed. Score = 3. **C)** Group 3 (pentoxifylline): scattered and medium-density microvessels (arrows) were observed. Score = 2. **D)** Group 4 (honokiol): a small number of microvessel formations (arrows) were seen. Score = 1. (It could not be indicated with arrows because no microvessel was seen in the control group.) For other groups, arrows are shown only in some (not all) microvessels (osteopontin  $\times 100$ ).

or nerve root, resulting in spinal stenosis, limited movement of the nerve root, and dural compression. Thus, EF develops after the accumulation of extracellular proteins and fibroblasts in the perineural area due to the deformation of normal tissue structures because of inflammation (33).

Limitation of angiogenesis, stopping or slowing the fibroblast and inflammatory cell migration to the surgical site, and suppressing the oxidative response which leads to cytokine release seems mandatory to prevent EF.

PNT greatly reduces acute cell proliferation, stimulates collagenase activity, and suppresses secretion and synthesis of fibrillar collagen, fibronectin, and proteoglycan (6,8). PNT also has an antifibrinogenic effect on the liver and reduces fibroblast proliferation and production of collagen and matrix proteins (8,12). Moreover, PNT inhibits the growth and collagen synthesis of human myofibroblasts (29).

HNK is antimigratory, antiproliferative, antimitotic, antiangiogenic, apoptotic, and antifibrotic (2,20,25,32,37,39). Moreover, studies have shown that free oxygen radicals have a positive regulatory effect on the release of cytokines. Radical oxygen species show this effect by activating nuclear factor-kappa B (NF- $\kappa$ B), which regulates the synthesis of many cytokines. Moreover, honokiol has been shown to inhibit NF- $\kappa$ B (38). This inhibition is also responsible for honokiol's antiproliferative properties (38). Thus, both substances are strong candidates against EF.

Cytokines secreted by endothelial cells and leukocytes in response to tissue damage are the most important regulators of inflammation. TNF- $\alpha$  and TNF- $\beta$  stimulate the secretion of the proinflammatory cytokines IL-6, IL-8, and IL-10. It is known that they rise together after all types of tissue damage. This is why the number of IL-10 and TNF- $\beta$  in the negative control group was higher compared with the control group. In the other two groups (PNT and HNK) where surgery was performed, these levels were observed to be lower compared with the negative control group, but still higher compared with the control group (Table I). The decrease in the level of these two cytokines (TNF- $\beta$  and IL-10) was commented as an inflammation decrease. These results show that both HNK and PNT exhibit similar anti-inflammatory properties because no statistical difference exists between the control group of these cytokines and the HNK and PNT groups (Tables I and II).

ICAM is responsible for fibrosis, which follows neutrophil infiltration and increased inflammation. Although the importance of ICAM on fibrosis has been studied in some visceral organs such as the lungs and liver (14,36), it has not been studied on EF.

ICAM and histopathologically determined EF were negatively correlated in the present study. PNT and HNK are capable of inhibiting EF because high ICAM levels are fibrosis indicators (14,36), and no significant difference exists between these two groups in terms of ICAM.

MPO, HYP, and MDA are important markers of oxidative stress (22). In the present study, oxidative stress markers were increased in the negative control group compared with the control group (Table I), and the difference (except MPO) was

statistically significant (Table II). The results were also coherent with the fibrosis degrees histopathologically detected (Tables III, IV, and V).

A significant decrease of oxidative stress markers in both the HNK and PNT groups suggested that both had antioxidant properties. However, this effect was more pronounced in HNK. The decrease in IL-10 and TNF- $\beta$  levels detected in the PNT and HNK groups compared with the negative control group indicated that both had anti-inflammatory properties. The antioxidant and anti-inflammatory properties of both chemicals may have reduced EF formation by suppressing cytokine release that will occur in the damaged tissue.

HNK and PNT have potentials in EF prevention when systematically administered. Moreover, the knowledge about PNT was previously described in the literature (18). The present study also confirmed this claim and vice versa. However, the information about systemic HNK on preventing EF is new and unique.

## ■ CONCLUSION

Systemic administration of honokiol and pentoxifylline are capable to inhibit epidural fibrosis formation, but honokiol is superior to pentoxifylline.

## ■ ACKNOWLEDGEMENTS

This project (2016/6-51 M) was financially supported by the Scientific Research Projects Unit of our university.

Preparation for publication of this article is partly supported by Turkish Neurosurgical Society.

## ■ REFERENCES

1. Alkalay RN, Kim DH, Urry DW, Xu J, Parker TM, Glazer PA: Prevention of postlaminectomy epidural fibrosis using bioelastic materials. *Spine* 28:1659-1665, 2003
2. Aydinçak O, Yilmaz MB, Emmez H, Kurt G, Sepici A, Memis L, Baykaner K: The effect of temozolomide on the prevention of epidural fibrosis developing after lumbar laminectomy in rats. *Turk Neurosurg* 22:706-711, 2012
3. Berman B, Matthew R, Duncan R: Pentoxifylline inhibits normal human dermal fibroblasts in vitro proliferation, collagen, glycosaminoglycan, and fibronectin production and increases collagenase activity. *J Invest Dermatol* 92:605-610, 1989
4. Bryant MS, Bremer AM, Nyugen TQ: Autogeneic fat transplants in the epidural space in routine lumbar spine: MR imaging assesment. *AJNR* 9:169-178, 1988
5. Cassisi JE, Sybert GW, Salamon A, Kapel L: Independent evaluation of a mul-tidisciplinary rehabilitation program for chronic low back pain. *Neurosurgery* 25:877-883, 1989
6. Chang CC, Chang TC, Kao SC, Kuo YF, Chein LF: Pentoxifylline inhibits the proliferation and glycosaminoglycan synthesis of cultured fibroblasts derived from patients with Graves'ophthalmopathy and pretibial myxoedema. *Acta Endocrinol* 129:322-327, 1993

7. Chiang CK, Sheu ML, Lin YW, Wu CT, Yang CC, Chen MW, Hung KY, Wu KD, Liu SH: Honokiol ameliorates renal fibrosis by inhibiting extracellular matrix and pro-inflammatory factors in vivo and in vitro. *Br J Pharmacol* 163:586-597, 2011
8. Duncan MR, Hasan A, Berman B: Pentoxifylline, pentifylline, and interferons decrease type I and type procollagen mRNA levels in dermal fibroblasts: Evidence for mediation by nuclear factor 1 down-regulation. *J Invest Dermatol* 104:282-286, 1995
9. Frymoyer JW, Pope MH, Costanza MC, Rosen JC, Goggin JE, Wilder DG: Epidemiologic studies of low-back pain. *Spine* 5(5):419-423, 1980
10. Geisler FH: Prevention of epidural fibrosis: Current methodologies. *Neurol Res* 21(1):9-22, 1999
11. Gorgulu A, Simsek O, Cobanoglu S, Imer M, Parsak T: The effect of epidural free fat graft on the outcome of lumbar disc surgery. *Nuerosurgical Review* 27(3):181-184, 2004
12. Gressner AM: The cell biology of liver fibrogenesis – an imbalance of proliferation, growth arrest and apoptosis of myofibroblasts. *Cell Tissue Res* 292:447-452, 1998
13. He Y, Revel M, Loty B: A quantitative model of postlaminectomy scar formation. Effects of a nonsteroidal anti-inflammatory drug. *Spine* 20:557-563, 1995
14. Hintermann E, Christen U: The Many Roles of Cell Adhesion Molecules in Hepatic Fibrosis. *Cells* 8(12):1503, 2019
15. Hwang ES, Park KK: Magnolol suppresses metastasis via inhibition of invasion, migration, and matrix metalloproteinase-2/-9 activities in PC-3 human prostate carcinoma cells. *Biosci Biotechnol Biochem* 74: 961-967, 2010
16. Ishizaka A, Wu ZH, Stephens KE, Harada H, Hogue RS, O'Hanley PT, Raffin TA: Attenuation of acute lung injury in septic guinea pigs by pentoxifylline. *Am Rev Respir Dis* 138: 376-382, 1988
17. Kelsey JL, White AA: Epidemiology and impact of low-back pain. *Spine* 5(2):133-142, 1980
18. Kelten B, Erdogan E, Antar V, Sanel S, Tuncdemir M, Kutnu M, Karaoglan A, Orki T: Pentoxifylline inhibits epidural fibrosis in post-laminectomy rats. *Med Sci Monit* 22:840-847, 2016
19. Kemaloglu S, Ozkan U, Yilmaz F, Nas K, Gur A, Acemoglu H, Karasu H, Cakmak E: Prevention of spinal epidural fibrosis by recombinant tissue plasminogen activator in rats. *Spinal Cord* 41:427-431, 2003
20. Kim KR, Park KK, Chun KS, Chung WY: Honokiol inhibits the progression of collagen-induced arthritis by reducing levels of pro-inflammatory cytokines and matrix metalloproteinases and blocking oxidative tissue damage. *J Pharmacol Sci* 114: 69-78, 2010
21. Koshiishi I, Hasegawa T, Imanari T: Quantitative and qualitative alterations of chondroitin/dermatan sulfates accompanied with development of tubulointerstitial nephritis. *Arch Biochem Biophys* 401:38-43, 2002
22. Kurutas EB: The importance of antioxidants which play the role in cellular response against oxidative/nitrosative stress: Current state. *Nutr J [serial online]* 15:71, 2016
23. Lai HS, Chu SY, Chen Y, Wu CH, Lin LT: Effect of pentoxifylline on intraperitoneal adhesions after intestinal resection in rats. *J Formos Med Assoc* 93:911-915, 1994
24. Laurent GJ, Chambers RC, Hill MR, McAnulty RJ: Regulation of matrix turnover: Fibroblasts, forces, factors and fibrosis. *Biochem Soc Trans* 35:647-651, 2007
25. Liou KT, Shen YC, Chen CF, Tsao CM, Tsai SK: The anti-inflammatory effect of honokiol on neutrophils: Mechanisms in the inhibition of reactive oxygen species production. *Eur J Pharmacol* 475:19-27, 2003
26. Ohkawa H, Ohishi N, Tagi K: Assay for lipid peroxides in animal tissues by thiobarbituric acid reaction. *Anal Biochem* 95:351-358, 1979
27. Park EJ, Zhao YZ, Kim YH, Lee BH, Sohn DH: Honokiol induces apoptosis via cytochrome c release and caspase activation in activated rat hepatic stellate cells in vitro. *Planta Med* 71:82-84, 2005
28. Porter JM, Cutler BS, Lee BY, Reich T, Rehicle FA, Scogin JT, Strandness DE: Pentoxifylline efficacy in the treatment of intermittent claudication: Multicenter controlled double-blind trial with objective assessment of chronic occlusive arterial disease patients. *Am Heart J* 104:66-72, 1982
29. Preaux AM, Mallat A, Rosenbaum J, Zafrani E, Mavrier P: Pentoxifylline inhibits growth and collagen synthesis of cultured human hepatic myofibroblast-like cells. *Hepatology* 6: 315-322, 1997
30. Robertson JT: Role of epidural fibrosis in the failed back: A review. *Eur Spine J* 5(1):2-6, 1996
31. Saal JS, Franson RC, Dobrow R, Saal JA, White AH, Goldthwaite N: High Level of inflammatory Phospholipase A2 activity in lumbar disc herniations. *Spine* 15(7):674-678, 1990
32. Son HJ, Lee HJ, Yun-Choi HS, Ryu JH: Inhibitors of nitric oxide synthesis and TNF-alpha expression from Magnolia obovata in activated macrophages. *Planta Med* 66:469-471, 2000
33. Su C, Sui T, Zhang X, Zhang H, Cao X: Effect of topical application of mitomycin-C on wound healing in a postlaminectomy rat model: An experimental study. *Eur J Pharmacol* 674:7-12, 2012
34. Tanriverdi O, Yilmaz I, Adilay H U, Gunaldi O, Erdogan U, Gungor A, Kilic M, Tanik C: Effect of cetuximab on the development of epidural fibrosis based on CD105 and osteopontin immunohistochemical staining. *Spine* 44(3): E134-E143, 2019
35. Temel SG, Ozturk C, Temiz A, Ersozlu S, Aydinli U: A new material for prevention of epidural fibrosis after laminectomy. *J Spinal Disord Tech* 19: 270-275, 2006
36. Tsoutsou PG, Gourgoulis KI, Petinaki E, Mpaka M, Efremidou S, Maniatis A, Molyvdas PA: ICAM-1, ICAM-2 and ICAM-3 in the sera of patients with idiopathic pulmonary fibrosis. *Inflammation* 28(6):359-364, 2004
37. Xu HL, Tang W, Du GH, Kokudo N: Targeting apoptosis pathways in cancer with magnolol and honokiol, bioactive constituents of the bark of Magnolia officinalis. *Drug Discov Ther* 5:202-210, 2011
38. Yang SE, Hsieh MT, Tsai TH, Hsu SL: Effector mechanism of magnolol-induced apoptosis in human lung squamous carcinoma CH27 cells. *Br J Pharmacol* 138:193-201, 2003
39. Zbidah M, Lupescu A, Herrmann T, Yang W, Foller M, Jilani K, Lang F: Effect of honokiol on erythrocytes. *Toxicol in Vitro* 27:1737-1745, 2013