



Asymmetric Cross Sectional Area Size of the Psoas Muscle Seems to be a Key Feature in Patients with L4-5 Lumbar Disc Herniations

Osman Ersegun BATCIK¹, Ayhan KANAT¹, Bulent OZDEMIR¹, Hasan GUNDOGDU²

¹Recep Tayyip Erdogan University, School of Medicine, Department of Neurosurgery, Rize, Turkey

²Recep Tayyip Erdogan University, School of Medicine, Department of Radiology, Rize, Turkey

Corresponding author: Ayhan KANAT ✉ ayhankanat@yahoo.com

ABSTRACT

AIM: To determine the relationship between the occurrence of lumbar L4-5 disc herniation (LDH) and the size of psoas muscles.

MATERIAL and METHODS: The cross-sectional areas (CSAs) of the psoas muscles were measured at the L4-5 disc level on axial MRI of patients with LDH who were admitted to the hospital between 1 January 2020 and 1 June 2020. The patients were divided into three groups according to the involvement side of LDH as the patients without disc (Group I), right side disc (Group II), and left side disc (Group III). The relationship of ipsilateral and the opposite side of the CSA of PM in the control group and the patients with LDHs was analyzed.

RESULTS: This retrospective study included 65 patients (ages between 20 and 70 years) whose mean age is 42, 12. The mean values of the right side cross-sectional area of PM were 12.09 cm² in Group I (n=18), 12.84 cm² in Group II (n=20), and 14.15 cm² in Group III (n=27). The left side values were 12.08 cm², 13.22 cm², 14.00 cm² in Group I, II, and III, respectively. The difference between right and left side CSA of PM is that values of patients with left-sided LDHs were higher than those of the control and right-sided LDH group, and the difference was statistically significant. A strong correlation was observed between the left and right side of the cross-sectional area of psoas muscle at the L4-5 level (p<0.05).

CONCLUSION: This study shows that there are reciprocal changes in the cross-sectional area of the psoas muscle in patients with L4-5 lumbar disc herniation.

KEYWORDS: Cross-sectional area, Psoas muscle, L4-5 lumbar disc herniation

ABBREVIATIONS: LBP: Low back pain, LDH: Lumbar disc herniation, PM: Psoas muscle, CSA: Cross sectional area

INTRODUCTION

Currently, low back pain (LBP) is an important public health problem (1,27), and contributes to the socioeconomic health burden worldwide. Its reported incidence is 5%–30% (33), and prevalence is nearly 84% in the lifetime (32). Today, high technology has been used in radiological modalities (12,30). This technical progress in the discipline of spinal surgery has led to many changes in our understanding

of spine anatomy (3,18,20,28). Today, it is easier to assess body composition, such as PM size, but we still have a very limited understanding of the pathophysiology of LDH. Spinal surgical operations have some features that are distinct from other operative procedures (15). The reasons why some people have this persistent pain after lumbar discectomy remain unclear, so the surgical management of lumbar intervertebral discs sometimes discourage both surgeon and patient (21).

Understanding the pathophysiology and biomechanics in lumbar disc herniations may resolve this problem. Some structural and functional alterations may be seen in a patient with LDH. In this context, the spinal musculature may have clinical importance in patients with LDH. Asymmetric mechanical load of PM may lead to hypertrophy of these muscles. The psoas major muscles are located at the top of the lateral face and the base of the transverse processes of the first four lumbar vertebrae and interposed intervertebral discs (34). The lumbar spine is stabilized by paraspinal muscles, including psoas muscles, erector spinae, and multifidus. The psoas major is the largest muscle in cross-section at the L4-5 level. There can be a relationship between lumbar disc herniation and the asymmetric nature of psoas muscle (PM). Spine surgeons have been investigating a method to understand the pathology of lumbar disc herniations, but despite the association with lumbar discs and the psoas muscle, this relationship has received little attention. A better understanding of the role of the psoas muscle and its impact on the occurring of lumbar disc herniations may improve the clinical management of patients suffering from LDHs. Asymmetric PM muscle anatomy could affect the development of LDH which has never been quantitatively studied previously. In this study, we hypothesized that the psoas muscle might have a role in occurring of L4-5 disc herniation.

■ MATERIAL and METHODS

This retrospective cross-sectional study was approved by the Recep Tayyip Erdogan University's Ethics Committee (40465587-050.01.04-176). We enrolled patients admitted and operated for lumbar disc herniations at 4-5 levels between 1 January 2020 and 1 June 2020. 18 patients with low back pain but without LDH were recruited at the time of their visit to the neurosurgery outpatient clinics as the control group. The patients were divided into three groups according to the involvement side of lumbar disc herniation as the patients without disc (Group I), right side disc (Group II), and left side disc (Group III). All participants had lumbosacral magnetic resonance imaging (MRI) as a part of their routine diagnostic workup. The inclusion criteria were single-level lumbar disc herniation at L4-5 level on MRI. Overall exclusion criteria were the patients with multilevel disc herniation, recurrent disc herniation, previous surgical histories in the PS region, or spinal deformities, spinal stenosis, spondylolisthesis, hip disorders, pregnancy within the last three years.

Magnetic Resonance and Measurement of Cross-Section Area of the Psoas Muscle

All MRI examinations were performed using a 1.5 Tesla superconducting magnet using movable surface coils. The patients were placed in a supine position. MRI scans were stored in DICOM format. All measurements were made bilaterally at the anatomic L4-5 level on T1-weighted sequences. Muscle CSA is assumed to be reflective of muscle volume (26). The CSA of paraspinal muscles has been associated to some degree with the muscle's capacity to generate force since force is proportional to the CSA of the muscle. In this study (36), the CSA of psoas muscle was calculated at the side of L4-5 disc hernia-

tion and also the opposite side. The degree of disc herniation was classified as bulging, protrusion, extrusion. A score from 1 to 4 was assigned to each patient's MR imaging findings, according to the severity of the herniation. In this MRI scoring, 1 point was given for bulging, 2 for protrusion, 3 for extruding, 4 for sequestration, and the relationship between PM asymmetry and L4-5 disc herniation was analyzed.

Statistical Analysis

For statistical analysis, the averages of the right-side and left-side measurements of PM were compared. The variables were found to be normally distributed, and differences between the right and left side CSA for PM muscle were calculated and analyzed by using the One-way Anova test. The dependent variable was the side of LDH, and the independent variables included PSA size of PM at the L4-5 vertebral level. Pearson Chi-Square test was used to detect the relationship between the involved side of the herniation and the non-involved side. All measurements were evaluated separately for men and women according to disc herniation, and age of the patients. Spearman's rho was calculated for the analysis of the correlation between the CSA of the bilateral iliopsoas and disc herniation side. The level of significance was set at 0.05 for all tests. The differences were also calculated between right and left PM CSA values (Table I).

■ RESULTS

In this study, the transverse lumbar sectional images of bilateral psoas muscle of 65 patients were examined. 18, 20, and 27 patients were included in Group I, Group II (right-sided LDH), and group III (left-sided discLDH), respectively. There were 32 males, and 33 female patients (The ages between 20 and 70 years; mean 42.12 years). The mean values of the right side cross-sectional area of PM were 12.05 cm² in Group I (n=18), 12.84 cm² in Group II (n=20), and 14.15 cm² in Group III (n=27). Figure 1 shows the graphical view of right PM CSA values. The values on the left side were 12.08 cm², 13.22 cm², 14.00 cm² in Group I, II, and III, respectively. Left PM CSA can be seen in Figure 2. Table I shows the PM CSA values and the differences between the two sides in patients with right and left LDH. The Chi-square test showed that there is no significant difference in gender (Table II). Figures 3, 4 show the axial MRI of two patients. In Figure 3, the size of the contralateral right side PM is larger than the muscle on the ipsilateral side of LDH. In Figure 4, the ipsilateral side PM size is larger than the contralateral side in a patient with a right-sided disc. A strong correlation was observed between the left and right side of the cross-sectional area of psoas muscle at the L4-5 level ($p < 0.05$) (Table III). The mean, minimum, and maximum values of CSA of PM in patients with LDHs were higher than those in the control group and the group of patients with right-sided LDH, and the differences in PS CSA values were statistically significant ($p < 0.05$). The LDHs were observed on the left side in 27 cases, and on the right side in 20 cases. Pearson Chi-Square test showed that there was a significant relationship between the disc degeneration and involvement side ($p < 0.05$), but not any significant gender difference. The effect of aging was analyzed by dividing the patients into three groups; age

Table I: The Psoas Muscle Cross Sectional Area Values and the Differences of Two Sides in Patients with Right and Left LDHs

		n	Mean (mm ²)
Age	Control group	18	33.0000
	Right sided LDH	20	48.5000
	Left sided LDH	27	43.4815
	Total	65	42.1231
Right PM CSA values	Control group	18	1205.6111
	Right sided LDH	20	1284.4000
	Left sided LDH	27	1415.3704
	Total	65	1316.9846
Left PM CSA values	Control group	18	1208.6667
	Right sided LDH	20	1322.4000
	Left sided LDH	27	1400.6667
	Total	65	1323.4154
The difference of PM CSA values of patients with right LDH	Control group	5	21.2000
	Right sided LDH	4	79.7500
	Left sided LDH	15	71.6000
	Total	24	62.4583
The difference of PM CSA values of patients with left LDH	Control group	13	12.2308
	Right sided LDH	16	76.0000
	Left sided LDH	12	78.7500
	Total	41	56.5854

PM: Psoas muscle, **LDH:** Lumbar disc herniation, **CSA:** Cross sectional area.

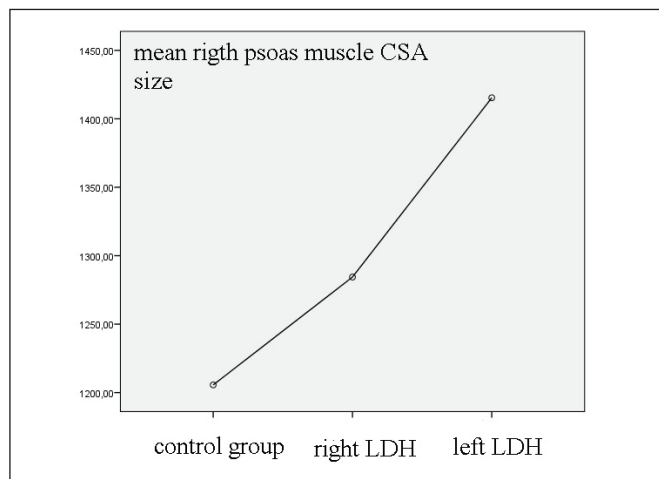


Figure 1: It shows the graphical view of right PM CSA values.

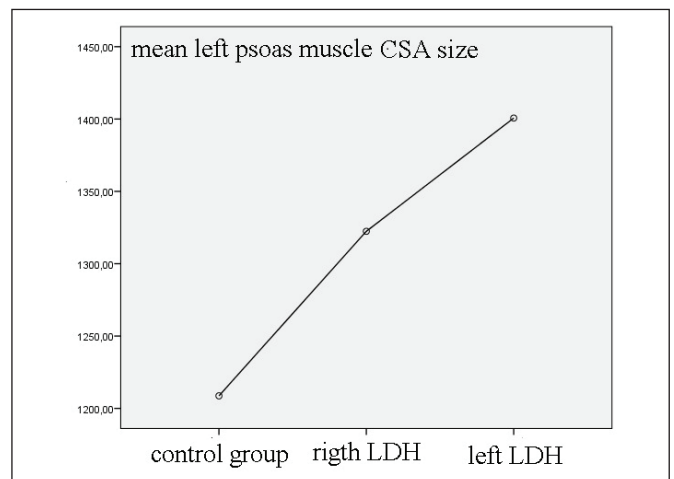


Figure 2: Left PM CSA sizes are seen.

Table II: Gender and Disc Side Cross Tabulation. Chi Square Test Showed That There Is No Significant Difference of Gender

		Groups			Total
		Control	Right LDH	Left LDH	
Gender	Male	7	9	17	33
	Female	11	11	10	32
Total		18	20	27	65

LDH: Lumbar disc herniation.

Table III: A Strong Correlation was Observed Between the Left and Right Side of the Cross-Sectional Area of Psoas Muscle at the L4-5 Level ($p < 0.05$, values for all groups)

Side of Lumbar Disc Herniation		Area		
		Right	Left	
Right	Right CSA of the psoas muscle	Pearson Correlation	1	.983**
		Sig. (2-tailed)		.000
		N	30	30
	Left CSA of the psoas muscle	Pearson Correlation	.983**	1
		Sig. (2-tailed)	.000	
		N	30	30
Left	Right CSA of the psoas muscle	Pearson Correlation	1	.984**
		Sig. (2-tailed)		.000
		N	38	38
	Left CSA of the psoas muscle	Pearson Correlation	.984**	1
		Sig. (2-tailed)	.000	
		N	38	38

***. Correlation is significant at the 0.01 level (2-tailed). CSA: Cross sectional area.*

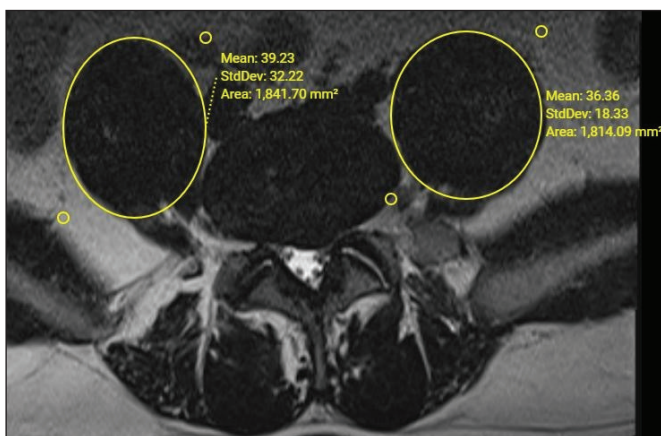


Figure 3: The size of the contralateral right side PM is larger than the muscle on the ipsilateral side of LDH.

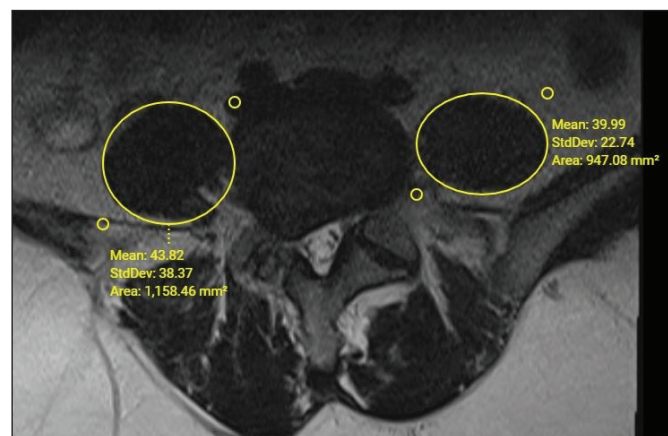


Figure 4: The ipsilateral side PM size is larger than the contralateral side in a patient with the right-sided disc.

under 30 (Group I, n=13), ages between 30 and 60 (Group II, n=47), and ages above 60 (Group III, n=5). CSA of PM was larger in Group II than Group I and Group III, but the difference was not statistically significant ($p>0.05$).

■ DISCUSSION

Key Results

1-It was found that left side CSAs of PM are generally larger than the right side in all groups. Table I shows the differences in CSA values between right and left sides, which were statistically significant ($p<0.05$). Figures 1 and 2 show mean values of right and left PMCSA .

2- Asymmetrical and reciprocal changes of the CSA psoas muscle are associated with L4-5 disc herniation. These changes can be seen in Figures 3, 4. Chi-Square test showed that there was a significant relationship between the disc severity score and the involvement side ($p<0.05$).

Conflicting reports about the relationship between Lumbar Pathology and Psoas Muscle Size

Various studies have been published about the relationship between lumbar pathology and psoas muscle size. Some researchers reported a significant reduction in the CSA of the psoas muscle in the affected side only, prominently at the level of disc herniation (4,6,7,29). The CSA decrease at the symptomatic side ranging from 2 to 62% was positively associated with the duration of symptoms (35). Yalçın et al. found that the PM measurements were larger in patients without LDH than those with LDH, but the difference was not statistically significant (37). Our study showed that the left side CSA psoas muscle at the level L4-5 is larger than other sides. Conversely, in other studies, I reported no change in psoas size in patients with low back pain (5,8).

Interpretation of the facts of larger muscle size in the non-dominant (left side) than the right side

Scientific principles are important in our clinical practice (2,19). The human body, which appears symmetrical along the midline grossly, is, in fact, asymmetrical both morphologically and physiologically (22). The spinal imbalance is important in humans; the balance of the body essentially depends on how far the head is to the midline. Previously Kanat et al. reported that occurring of LDH in human is more common on the left side than on the right side (22), later a larger muscle size was reported on the left side of PS compared to the right side, (31,35) although this increase was not statistically significant in people without back pain (35). The psoas major muscle is among the most significant muscles that overlie the vertebral column (34). It has the largest muscle in cross-section size at the lower levels of the lumbar spine (31). The psoas muscle has a biomechanical and postural function during both moving and static states (34), and is associated with all the lumbar intervertebral discs (7). In the present study, the PM CSA size in the non-dominant leg (left) side was larger than the right side in all groups (Group II, and III) and the finding of the relationship between larger psoas volume and developing disc herniation at the L4-5 level is not in agreement with that of

other studies (7,25,37). In Figure 3, the size of the contralateral right side PM is larger than the muscle on the ipsilateral side of LDH. In Figure 4, the ipsilateral side PM size is larger than the contralateral side in a patient with a right-sided disc.

We also calculated the differences between the right and left side CSA for PM muscle of the same patients (Table I), and analysis conducted by using the One-way ANOVA test showed that the difference is statistically significant at the left side, not on the right side. What can be the reason for not statistically significant results on the right side? We think that it is related to the dominance of the right side. More stress and strain on the dominant side may cause differences between the sides, often referred to as directional asymmetry (22). Wolff's law says bone formation occurs along lines of stress which the bones and muscles respond to by growing more vigorously and increasing in density on exposure to repeated high levels of mechanical loading (22). We think that the PM is a more substantial size on the dominant side than the non-dominant side in human without LDH. In patients with LDH, the asymmetry of PM cannot be increased. This subject should be studied.

Gender: Dohzono et al. reported that psoas muscle areas are significantly greater in men than in women (9). A gender-related difference can be expected in developing lumbar disc herniation. In this study, we could not find gender-related differences in CSA of PM.

Aging-related Psoas CSA changes

A whole host of gross-level neuroanatomical changes take place as we get older (17). In this study, an increased psoas volume was observed in middle-aged patients. This finding is not surprising as LBP can be caused by structural problems that are related to age (23). Aging is one of the most complex biological processes (27). Muscle atrophy may increase with age (37). Indeed, at the lumbar L4-5 disc level, for both genders, psoas muscle volume decreases with age, most likely because of atrophy of muscle. Sarcopenia of PM may occur, which is the age-related loss of PM mass. We noted there is no relationship between sarcopenia-related psoas CSA size changes at the L4-5 level and LDH ($p>0.05$), but there is a strong correlation between disc degeneration rate herniation and size or CSA of PM ($p<0.05$).

Clinical Implications of the Findings of this Study

This study shows that there are reciprocal changes in the cross-sectional area of the psoas muscle in patients with L4-5 lumbar disc herniation. This finding is important, because the failure of the balance due to asymmetric right and left PM CSA sizes may lead to preoperative or postoperative pain. The intervertebral disc is an important structure in the passive stability of the lumbar spine. It is also exposed to a relevant proportion of the resulting stresses, and the role of the muscles as active stabilizers and the relevance of posture and movement optimization seems to be an important issue, because muscle force imbalance may lead to kinetic instability of the spine (36). The asymmetric nature of PM in this study suggests that the left and right PM provides non-equal stabilization of the lower lumbar spine.

Currently, spinal stabilization procedures have increasingly been used as a standard treatment for complicated degenerative spinal disorders, such as failed back surgery syndrome. This stabilization system may assist to shift abnormal load transmission because pain sometimes is not caused by the loss of stability in the vertebral column (22). Instead, pain may be caused by the loss of distribution of load (22). Good outcomes after surgery are an important issue (14). Psoas muscle asymmetry may lead to worse clinical outcomes and spinal instability may lead to worse outcomes after lumbar discectomy. We think that the anatomy and asymmetric feature of this muscle is important.

Why was the MRI preferred in this study?

The neurosurgical practice is confronted by an explosion of technology (38). In the 1980s, the advent of magnetic resonance imaging (MRI) (13) and the progressive increase in the definition of this modality of imaging led to the use of this modality in spinal disorders (21). Sensitivity CT scans and MR images are different (16). MRI scans are an excellent, noninvasive means of imaging the entire lumbar spine (23). It is also useful for evaluating the muscle CSA and composition quantitatively because of its good soft-tissue contrast and its being radiation-free (36). We used a scoring system. This scoring system is only based on pathological changes or protrusions on the lumbar MRI. The L4-5 lumbar disc scoring of patients was compared to the CSA of psoas muscle of both sides, and a statistically significant difference was found between the left and right side ($p < 0.05$).

Limitations

There is no validated method to measure actual PM muscle volume. Another limitation is the sample size of the present study. If a researcher selects fewer samples, it may lead to the missing of any significant difference even if it exists in the population (10,24). The psoas muscle is one of the spinal stabilization muscles (others are erector spina and multifidus muscle), and fatty degeneration may affect the result of this study.

CONCLUSION

Testable hypotheses are important (14). PM supports and maintains the stability of the lumbar spine. We hypothesized that patients with larger CSA of psoas muscle affect the enhanced static and dynamic stability of the spine and developing LDH, but found that there are reciprocal changes of CSA of the psoas muscle at the level of left side L4-5 LDH. The causes of these reciprocal changes remain to be determined. We suggest that pathophysiologic changes related to the asymmetrical PM may contribute to issues involving sagittal and coronal imbalance in patients with LDH. The nervous system act as an orchestra with complex harmonic combinations (11), so it can be easy to understand the effect of any PM asymmetry that will be translated into an alteration of the biomechanical feature of the lumbar spine, and occurrence of LDH. This study indicates that this asymmetric nature of PM seems to be a key feature in patients with L4-5 lumbar disc herniations, and its cause and clinical

importance should be proven. We think that stabilization procedures correct the asymmetry of the spine in part. So the comprehension of the asymmetric PM muscle anatomy is decisive and revolutionary in the understanding and treatment of the LDH. The present study also suggests that patients with LDH may have a balance defect or an unrecognized minimal instability depending on asymmetric PM anatomy. More studies are required.

AUTHORSHIP CONTRIBUTION

Study conception and design: AK

Data collection: HG, OEB

Analysis and interpretation of results: BO

Draft manuscript preparation: OEB

Critical revision of the article: AK

Other (study supervision, fundings, materials, etc...): AK

All authors (OEB, AK, BO, HG) reviewed the results and approved the final version of the manuscript.

REFERENCES

1. Akca N, Ozdemir B, Kanat A, Batick OE, Yazar U, Zorba OU: Describing a new syndrome in L5-S1 disc herniation: Sexual and sphincter dysfunction without pain and muscle weakness. *J Craniovertebr Junction Spine* 5(4):146-150, 2014
2. Aydin MD, Kanat A, Aydin A, Aydin A, Demirci T, Ozmen S: Estimating basilar artery upper rupture limit by dangerous alarming diameter of arteries (DADA) following bilateral common carotid artery ligation; a new theorem. *Int J Neurosci*, 2020 (Online ahead of print)
3. Balik MS, Kanat A, Erkut A, Ozdemir B, Batick OE: Inequality in leg length is important for the understanding of the pathophysiology of lumbar disc herniation. *J Craniovertebr Junction Spine* 7:87-90, 2016
4. Barker KL, Shamley DR, Jackson D: Changes in the cross-sectional area of multifidus and psoas in patients with unilateral back pain: The relationship to pain and disability. *Spine (Phila. Pa. 1976)* 29:E515-519, 2004
5. Chon J, Kim H-S, Lee JH, Yoo SD, Yun DH, Kim DH, Lee SA, Han YJ, Lee HS, Han YR, Han S, Kim Y: Asymmetric atrophy of paraspinal muscles in patients with chronic unilateral lumbar radiculopathy. *Ann Rehabil Med* 41:801-807, 2017
6. Cooper RG, St Clair Forbes W, Jayson MI: Radiographic demonstration of paraspinal muscle wasting in patients with chronic low back pain. *Br J Rheumatol* 31:389-394, 1992
7. Dangaria TR, Naesh O: Changes in cross-sectional area of psoas major muscle in unilateral sciatica caused by disc herniation. *Spine (Phila. Pa. 1976)* 23:928-931, 1998
8. Danneels LA, Vanderstraeten GG, Cambier DC, Witvrouw EE, De Cuyper HJ: CT imaging of trunk muscles in chronic low back pain patients and healthy control subjects. *Eur Spine J* 9(4):266-272, 2000
9. Dohzono S, Sasaoka R, Takamatsu K, Hoshino M, Nakamura H: Prognostic value of low psoas muscle mass in patients with cervical spine metastasis. *J Clin Neurosci Off J Neurosurg Soc Australas* 66:56-60, 2019

10. Findik H, Kanat A, Aydin MD, Cakir M, Ozmen SA, Okutucu M, Baykal O, Sipal S: Describing a new mechanism of retinal detachment secondary to ophthalmic artery vasospasm following subarachnoid hemorrhage: An experimental study. *J Neurol Surg A Cent Eur Neurosurg* 80:430-440, 2019
11. Gasenzer ER, Kanat A, Neugebauer E: Neurosurgery and music; effect of Wolfgang Amadeus Mozart. *World Neurosurg* 102:313-319, 2017
12. Kanat A: Acute posttraumatic subdural hematomas: "Intradural" computed tomographic appearance as a favorable prognostic factor. *Neurosurgery* 43:685-686, 1998
13. Kanat A: Brainstem gliomas and gamma knife. *J Neurosurg* 107:708, 2007
14. Kanat A: Patient-evaluated outcome after surgery for basal meningiomas. *Neurosurgery* 51:1530-1532, 2002
15. Kanat A: Risk factors for neurosurgical site infections after craniotomy: A prospective multicenter study of 2944 patients. *Neurosurgery* 43:189-190, 1998
16. Kanat A, Aydin Y: Recurrent meningiomas. *J Neurosurg* 91:720-721, 1999
17. Kanat A, Kayaci S, Yazar U, Kazdal H, Terzi Y: Chronic subdural hematoma in adults: Why does it occur more often in males than females? Influence of patient's sexual gender on occurrence. *J Neurosurg Sci* 54:99-103, 2010
18. Kanat A, Ozdemir B: In Reply to the Letter to the Editor regarding Restoration of Anterior Vertebral Height by Short-Segment Pedicle Screw Fixation with Screwing of Fractured Vertebra for the Treatment of Unstable Thoracolumbar Fractures. *World Neurosurg* 101:793, 2017
19. Kanat A, Turgut M, de Divitiis O: Letter to the editor regarding the manuscript of "the longest angiographic and clinical follow-up of microsurgically treated giant intracranial aneurysms: Experience with 70 cases". *World Neurosurg* 140:462, 2020
20. Kanat A, Yazar U: Spinal surgery and neurosurgeon: Quo vadis? *J Neurosurg Sci* 57:75-79, 2013
21. Kanat A, Yazar U, Kazdal H, Sonmez OF: Introducing a new risk factor for lumbar disc herniation in females: Vertical angle of the sacral curvature. *J Korean Neurosurg Soc* 52:447-451, 2012
22. Kanat A, Yazar U, Ozdemir B, Kazdal H, Balik MS: Neglected knowledge: Asymmetric features of lumbar disc disease. *Asian J Neurosurg* 12:199-202, 2017
23. Kazdal H, Kanat A, Batacik OE, Ozdemir B, Senturk S, Yildirim M, Kazancioglu L, Sen A, Batacik S, Balik MS: Central sagittal angle of the sacrum as a new risk factor for patients with persistent low back pain after caesarean section. *Asian Spine J* 11:726-732, 2017
24. Kilic M, Aydin MD, Demirci E, Kilic B, Yilmaz I, Tanriverdi O, Kanat A: Unpublished neuropathologic mechanism behind the muscle weakness/paralysis and gait disturbances induced by sciatic nerve degeneration after spinal subarachnoid hemorrhage: An experimental study. *World Neurosurg* 119:e1029-e1034, 2018
25. Kim WH, Lee SH, Lee DY: Changes in the cross-sectional area of multifidus and psoas in unilateral sciatica caused by lumbar disc herniation. *J Korean Neurosurg Soc* 50:201-204, 2011
26. Mak D, Chisholm C, Davies AM, Botchu R, James SL: Psoas muscle atrophy following unilateral hip arthroplasty. *Skeletal Radiol* 49:1539-1545, 2020
27. Ozdemir B, Kanat A, Batacik OE, Gucer H, Yolas C: Ligamentum flavum hematomas: Why does it mostly occur in old Asian males? Interesting point of reported cases: Review and case report. *J Craniovertebral Junction Spine* 7:7-12, 2016
28. Ozdemir B, Kanat A, Erturk C, Batacik OE, Balik MS, Yazar U, Celiker FB, Metin Y, Inecikli MF, Guvercin AR: Restoration of anterior vertebral height by short-segment pedicle screw fixation with screwing of fractured vertebra for the treatment of unstable thoracolumbar fractures. *World Neurosurg* 99:409-417, 2017
29. Ploumis A, Michailidis N, Christodoulou P, Kalaitzoglou I, Gouvas G, Beris A: Ipsilateral atrophy of paraspinal and psoas muscle in unilateral back pain patients with monosegmental degenerative disc disease. *Br J Radiol* 84:709-713, 2011
30. Polat HB, Kanat A, Celiker FB, Tufekci A, Beyazal M, Ardic G, Turan A: Rationalization of using the MR diffusion imaging in B12 deficiency. *Ann Indian Acad Neurol* 23:72-77, 2020
31. Sajko S, Stuber K: Psoas major: A case report and review of its anatomy, biomechanics, and clinical implications. *J Can Chiropr Assoc* 53:311-318, 2009
32. Samanci Y, Celik SE: Low back pain and internet: Infopollution. *Turk Neurosurg* 27:804-808, 2017
33. Senkal S, Sir E: Comparison of ultrasonography and conventional fluoroscopy guided caudal epidural injection in chronic low back pain. *Turk Neurosurg* 31:119-123, 2021
34. Siccardi MA, Tariq MA, Valle C: Anatomy, Bony Pelvis and Lower Limb, Psoas Major. In: StatPearls [Internet]. Treasure Island (FL): StatPearls Publishing, 2020
35. Valentin S, Licka T, Elliott J: Age and side-related morphometric MRI evaluation of trunk muscles in people without back pain. *Man Ther* 20:90-95, 2015
36. Wan Q, Lin C, Li X, Zeng W, Ma C: MRI assessment of paraspinal muscles in patients with acute and chronic unilateral low back pain. *Br J Radiol* 88:20140546, 2015
37. Yaltirik K, Gudu BO, Isik Y, Altunok C, Tipi U, Atalay B: Volumetric muscle measurements indicate significant muscle degeneration in single-level disc herniation patients. *World Neurosurg* 116: e500-e504, 2018
38. Yolas C, Kanat A, Aydin MD, Altas E, Kanat IF, Kazdal H, Duman A, Gundogdu B, Gursan N: Unraveling of the effect of nodose ganglion degeneration on the coronary artery vasospasm after subarachnoid hemorrhage: An experimental study. *World Neurosurg* 86:79-87, 2016