

# Encephalitis due to COVID-19 in a Patient Who Has Undergone Transsphenoidal Pituitary Surgery

Suna Askin TURAN<sup>1</sup>, Gulcin Hilal ALAY<sup>2</sup>, Derya ADEMOGLU<sup>2</sup>, Guldem TURAN<sup>2</sup>

<sup>1</sup>Basaksehir Cam and Sakura City Hospital, Department of Neurology, Istanbul, Turkey

<sup>2</sup>Basaksehir Cam and Sakura City Hospital, Department of Intensive Care, Istanbul, Turkey

**Corresponding author:** Gulcin Hilal ALAY ✉ gulcinhilalalay@gmail.com

## ABSTRACT

Central and peripheral nervous system involvement of COVID-19 has been reported in 25% of cases. COVID-19 is associated with encephalitis and most often presenting with confusion and disorientation, and mortality decreases with early diagnosis and treatment. The patient who was admitted with confusion and fever and found COVID-19 PCR positivity in both cerebrospinal fluid (CSF) and the nasopharyngeal swab is presented here. A 71-year-old female patient who underwent transsphenoidal pituitary tumor surgery 4 months ago, was in an acute confusional state with fluctuations in consciousness and agitation. It was suggested that bilateral temporal areas of the brain and paramedian region of the pons compatible with encephalitis in the T2 and FLAIR axial sections of magnetic resonance imaging (MRI). Nasopharyngeal and CSF SARS-CoV-2 RNA PCR was studied since thorax CT was compatible with COVID-19 pneumonia and in both samples, PCR was found positive. Encephalitis for toxic and metabolic causes was excluded. In this case, COVID-19 encephalitis was treated with dual antiviral (favipiravir and acyclovir) and steroid therapy. The uniqueness of this case is not only the presence of a very few reported cases of both Nasopharyngeal and CSF SARS-CoV-2 RNA PCR positivity but also previous history of transsphenoidal pituitary surgery 4 months ago.

**KEYWORDS:** COVID-19, Encephalitis, Intensive care unit, Transsphenoidal pituitary surgery

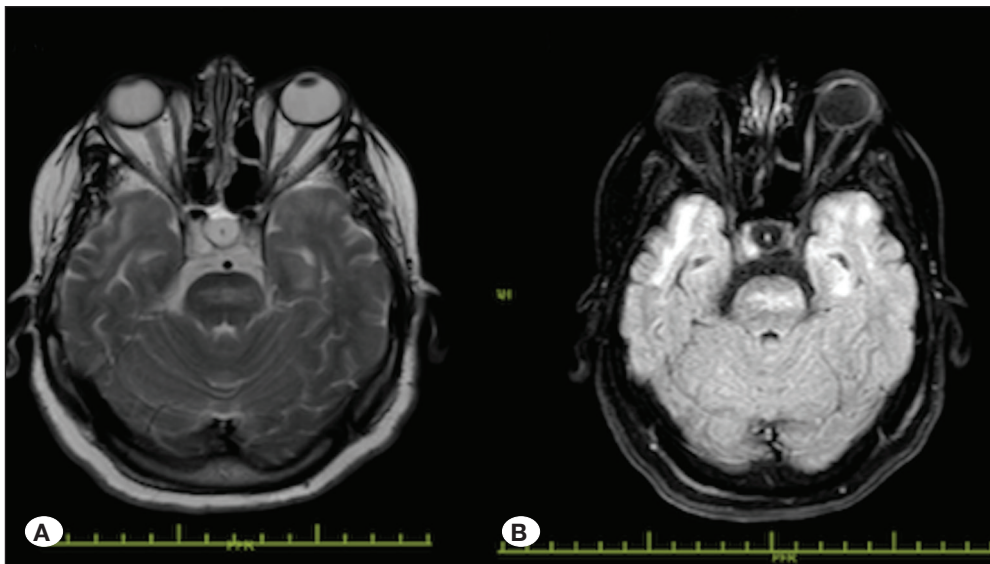
## INTRODUCTION

The COVID-19 outbreak spread all over the world in a short time, starting from the 2019 city of Wuhan, China. Although it causes severe respiratory failure, pneumonia, diarrhea, central and peripheral nervous system involvement has also been reported (7). Central nervous system involvement has been reported in 25% of COVID-19 cases. In addition to non-specific symptoms such as dizziness, headache, confusion, meningoencephalitis, seizures, stroke, and neuroimmunological disorders have been detected (5,11).

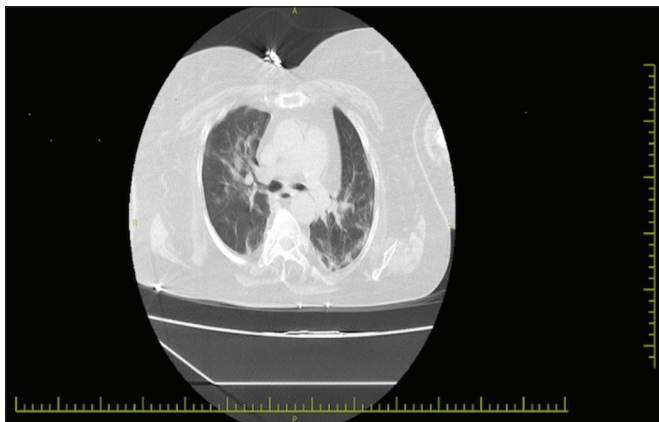
Encephalopathy is change in consciousness, common brain dysfunction and confusion, ranging from delirium to deep coma. Seizures, headache, and extrapyramidal findings can be seen in encephalopathy. Multi-organ failure (liver, renal, and acute respiratory insufficiency) is one of the severe

complication of encephalitis. Rapid blood tests, cranial imaging and CSF analysis should be planned in patients with symptoms of fever, headache, focal neurological deficits, seizures, and mental status changes. Encephalopathy cases due to COVID-19 are also increasing in the literature (6,12). Desai et al. reviewed 33 meningoencephalitis cases attributed to Covid-19 infection; presented with delirium or altered sensation (71%), aphasia or dysarthria (53%), headache (34%), seizures (34%), focal neurological deficits (18%). The cases treated with antiviral alone or adding immunosuppressants such as steroids, intravenous immunoglobulins and/or plasmapheresis was recovered good for all cases (3).

The patient who was admitted with confusion, fever, and diagnosed with encephalitis due to COVID-19 after four months from transsphenoidal pituitary surgery is presented in this case report.



**Figure 1:** Cranial magnetic resonance imaging (MRI) scans. Axial T2W (A), and fluid-attenuated inversion recovery (FLAIR) (B) images at admission: Bilateral temporal lobe mesial region on the left and abnormal signal area in the medial of pons.



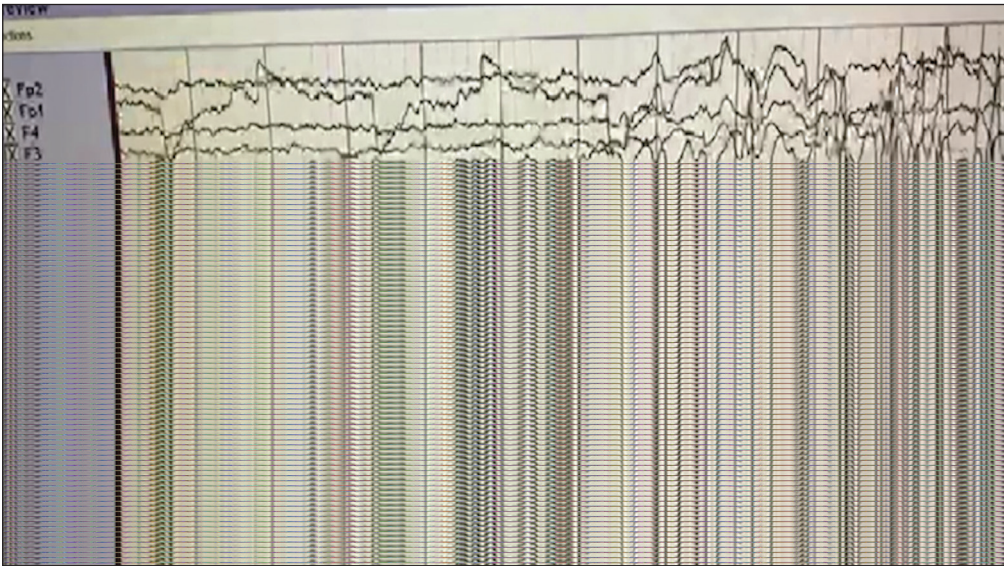
**Figure 2:** Thorax CT parenchyma section: Scattered ground-glass opacities were observed in the lung parenchyma, especially in peripheral areas. ( COVID-19 Pneumonia?).

## ■ CASE PRESENTATION

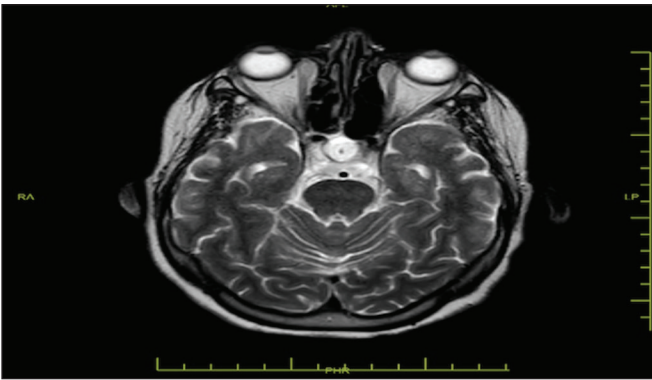
A 71-year-old female patient was admitted to emergency service with high fever, fatigue and confusion. She had hypothyroidism, hypertension, and transsphenoidal hypophyseal tumor operation history 4 months ago on her medical history. She was using levotriksin 50 mg/day and prednisolone 10 mg/day. She did not have an alcohol and substance use disorder history associated with her medical condition in the emergency service. The physical examination findings of the patient were as follows: body temperature 38.2°C, arterial blood pressure 78/46 mmHg, heart rate 88 beats per minute, breath rate 20 /min, SpO2 97% in room air. Neurological examination was revealed that she was in an acute confusional state with fluctuations in consciousness and agitation. She gave inappropriate answers to the asked questions to examine the patient's cooperation and orientation status. Neck stiffness and other meningeal irritation tests were normal. Cranial nerves were intact and motor and sensory exam-

inations were normal. Deep tendon reflexes were normal. Walking and coordination tests could not be evaluated clearly due to agitation. Rough breath sounds were heard during her thorax auscultation examination. The abdomen was comfortable with palpation, and bowel sounds were normoactive. The patient was transferred to intensive care unit due to sepsis and confusional status. The patient's blood tests, cranial and thoracic imagings, and nasopharyngeal swab tests for SARS-CoV-2 PCR analysis were performed in the intensive care unit. Lymphopenia ( $1,05 \cdot 10^9/l$ ) and acute phase reactant elevation (CRP :146 mg/L, procalcitonin 0,136 ng/ml, ferritin: 811 ng/ml.) were detected in the blood tests analysis. The thorax CT imaging was revealed diffuse ground-glass opacity in bilateral lung parenchyma. Cranial MRI (T2 and flair) was taken for evaluating the intracranial reasons of the acute confusional state. In cranial MRI, hyperintensities in pons paramedian region and bilateral medial temporal lobes in T2 and Flair axial sections are accepted as viral encephalitis by the neuroradiologists (Figures 1A and 1B). A lumbar puncture was performed in the lateral decubitus position for examination of the CSF. The CSF opening pressure was slightly high (270 mmH<sub>2</sub>O), clear and odorless (Protein: 320 mg/dl, Glucose: 91.2 mg/dl, WBC: <5 cells/cm<sup>2</sup>, RBC: 150 cells/cm<sup>2</sup>). There was no growth in CSF culture. The PCR screening of CSF for Herpes-simplex virus, Epstein-Barr virus, and tuberculosis was negative. Since thorax CT findings were compatible with COVID-19 pneumonia (Figure 2), nasopharyngeal swab sampling and CSF SARS-CoV-2 RNA PCR analysis were performed. The SARS-CoV-2 RNA PCR results of both samples were positive. Toxic and metabolic causes of encephalitis were excluded.

After the patient diagnosed with COVID-19 pneumonia and COVID-19 encephalitis, favipiravir treatment was initiated orally (2x800 mg loading, 2x200 mg maintenance dose) and continued for ten days. The enoxaparin (4000 IU twice a day, subcutan) and methylprednisolone (40 mg twice a day, intravenous) treatment were also given. Since false negativity rate of Herpes Simplex virus PCR analysis were higher,



**Figure 3:** EEG findings of the patient: Ground activity was in 8-9 alpha rhythm, repeating three times, 4-5 sec generalized epileptiform discharges, and slow activity was followed in two-third second delta rhythm. Epileptic activity available.



**Figure 4:** Follow-up cranial MRI axial T2W image of the patient after two months was within normal limits.

empirical Acyclovir treatment (3x10 mg/kg/day, intravenous) for herpes encephalitis was initiated and continued for 14 days. On the Electroencephalography (EEG) analysis, there was epileptiform discharge and there was no visible seizure (Figure 3). After her neurology consultation, her agitation was thought to be a seizure, and carbamazepine 2x200 mg orally treatment was initiated.

On the 8<sup>th</sup> day of these treatments, the patient was conscious and the infection parameters (CRP: 22 mg/L, procalcitonin: 0,03 ng/mL) were regressed. The patient did not need oxygen support during hospitalization. On the 20<sup>th</sup> day of hospitalization, she was discharged from intensive care unit and transferred to the pandemic service. The patient was discharged from pandemic ward after 8 days to home without any problem. The control cranial MRI was performed two months after the first admission and it was revealed normal intracranial findings (Figure 4). However, control EEG could not be performed due to the increased number of hospitalized COVID-19 patients.

## DISCUSSION

SARS-CoV-2 may cause cerebrovascular events, encephalitis, polyneuropathy, cranial neuropathy, and myopathy by affecting the nervous system (2). Many mechanisms have been proposed to explain the central nervous system involvement. These mechanisms have a common pathway in that the virus crosses the blood-brain barrier via circulating lymphocytes or the olfactory bulb (8).

In this case, using prednisolone since the surgery for four months might be a reason for immunosuppression and vulnerable for COVID-19 infection for the patient. Also previous transsphenoidal hypophyseal tumor surgery may be a cause of COVID-19 encephalitis. Meningoencephalitis is a very rare complication of transsphenoidal surgery for pituitary adenoma, occurring in 0.4–9% of patients (10). Koboyashi et al. reported three cases of severe streptococcal pneumonia meningoencephalitis after surgery out of 1965 patients undergoing transsphenoidal surgery between 2004 and 2010. Clinical events occurred 1-2 months after surgery without any history of sinusitis or pneumonia. The writers suggested that reduced resistance to infection may play a role in the occurrence of streptococcal pneumonia meningoencephalitis in our three patients (9). In the literature, we have not found COVID-19 encephalitis after transsphenoidal surgery. But COVID-19 pneumonia after the transsphenoidal surgery can be seen. Recently Young JS et al, reported 3 patients with postoperative COVID-19 infections following endonasal transsphenoidal pituitary surgery. One of the patients was admitted to emergency after 3 weeks later with a fever, nausea/vomiting, and headache, and on examination he found hypotensive due to adrenal insufficiency. On analysis, he was tested COVID-19 positive. He responded to hydrocortisone for his adrenal insufficiency and took medicine symptomatically for the viral disease (15). The writers claim that stress factor of surgery and hospitalisation are risk factors for COVID-19 infection.



Notification of COVID-19 associated encephalitis cases is increasing day by day. The most common symptom of encephalitis cases in the literature is the impairment of consciousness (22%) as in our case (12). Neck stiffness, tonic-clonic seizures, and speech disorder are other reported complaints.

The first reported case of meningoencephalitis originated from Wuhan and presented with epileptic seizures and confusion (13). An important feature of the case is that the COVID-19 virus was not detected in the nasopharyngeal swab, only CSF PCR virus positivity was detected. In addition, hyperintensity was detected in the temporal lobe and hippocampus area in cranial MRI. This case is important in terms of showing that neuroinvasion can develop in patients without respiratory symptoms or in whom no virus can be detected in the nasopharyngeal swab (13).

Mondal et al. reported a systematic review including 25 articles and a total of 54 patients with encephalitis (12). It was reported that SARS-CoV-2 PCR positivity was detected 5.55% of cases in CSF and 92.6% in nasopharyngeal swab (12). The fact that SARS-CoV-2 PCR positivity in both CSF and nasopharyngeal swab is a unique characteristic of our case.

Although tachycardia and low oxygen saturation are among the common findings of COVID-19, the heart rate and oxygen saturation were normal during the follow-up in our patient. Higher blood CRP, D-Dimer and LDH levels have been reported in cases of COVID-19 encephalitis as in COVID-19-associated pneumonia (12). Similar to other viral encephalitis, lymphocytic pleocytosis and high protein levels are expected in the CSF analysis in COVID-19 encephalitis (14). In this case, higher blood CRP, D-dimer, LDH levels, and higher CSF protein levels were detected as expected.

In cases of COVID-19 associated encephalitis, EEG findings have been reported as focal epileptiform discharges and generalized slowing. As focal epileptiform discharges indicate focal seizures, generalized slowing also indicates a change in consciousness (1,6). There was no focal seizure in this patient, and a generalized slowdown was found in her EEG. Patient's coordination disturbances, impairment of consciousness, agitation, and unresponsiveness to antipsychotics thought to be due to epileptic seizures. The regression in complaints and neurological symptoms after the initiation of carbamazepine 200 mg tablets twice a day supports this.

Neuroimaging abnormalities in COVID-19 associated encephalopathy are usually in the form of T2/FLAIR hyperintensity signal at subcortical or cortical white matter. Sometimes normal neuroimaging can be seen (6). Most frequently reported signal abnormalities in severe COVID-19 associated encephalopathy were located in the medial temporal lobe with or without hemorrhage. The presence of hemorrhage was frequent and associated with worse respiratory, neurological clinical status (7). We detected hyperintensity in medial temporal and paramedian pons region without hemorrhage. Like as the literature, our patient was not in a bad clinical status.

In this case, COVID-19 encephalitis was treated with dual antiviral (favipiravir and acyclovir) and steroid therapy. In the literature azithromycin, favipiravir, acyclovir, and steroid combinations were used (12). Dogan et al. reported six COVID-19 related encephalitis cases in which they used plasmapheresis (4). Five patients had improved with plasmapheresis but one of these six patients has died in intensive care unit. They suggested that plasmapheresis enables unconsciousness and normalization of serum ferritin levels (4).

## ■ CONCLUSION

COVID-19 can be associated with encephalitis and most often presenting symptoms are confusion and disorientation. Higher protein levels and lymphocytic pleocytosis in CSF analysis, temporal region hyperintensity in cranial MRI, and focal epileptiform discharge and generalized deceleration in EEG support the diagnosis. Since transsphenoidal surgery may be a risk factor for COVID-19 related encephalitis, these surgeries can be delayed during the COVID-19 pandemic if possible.

## ■ AUTHORSHIP CONTRIBUTION

**Study conception and design:** SAT

**Data collection:** SAT, GHA

**Analysis and interpretation of results:** SAT, DA

**Draft manuscript preparation:** SAT, GHA

**Critical revision of the article:** GHA, DA

**Other (study supervision, fundings, materials, etc...):** GT

All authors (SAT, GHA, DA, GT) reviewed the results and approved the final version of the manuscript.

## ■ REFERENCES

1. Ahmed MU, Hanif M, Ali MJ, Haider MA, Kherani D, Memon GM, Karim AH, Sattar A: Neurological manifestations of COVID-19 (SARS-CoV-2): A review. *Front Neurol* 11:518, 2020
2. Bridwell R, Long B, Gottlieb M: Neurologic complications of COVID-19. *Am J Emerg Med* 38(7):1549.e3-1549.e7, 2020
3. Desai I, Manchanda R, Kumar N, Tiwari A, Kumar M: Neurological manifestations of coronavirus disease 2019: Exploring past to understand present. *Neurol Sci* 42(3):773-785, 2021
4. Dogan L, Kaya D, Sarikaya T, Zengin R, Dincer A, Akinci IO, Afsar N: Plasmapheresis treatment in COVID-19-related autoimmune meningoencephalitis: Case series. *Brain Behav Immun* 87:155-158, 2020
5. Ellul MA, Benjamin L, Singh B, Lant S, Michael BD, Easton A, Kneen R, Defres S, Sejvar J, Solomon T: Neurological associations of COVID-19. *Lancet Neurol* 19(9):767-783, 2020
6. Garg RK, Paliwal VK, Gupta A: Encephalopathy in patients with COVID-19: A review. *J Med Virol* 93(1):206-222, 2020
7. Kremer S, Lersy F, de Sèze J, Ferré JC, Maamar A, Carsin-Nicol B, et al. Brain MRI findings in severe COVID-19: A retrospective observational study. *Radiology* 297(2):E242-E251, 2020

8. Korálnik IJ, Tyler KL: COVID-19: A global threat to the nervous system. *Ann Neurol* 88(1):1-11, 2020
9. Kobayashi N, Fukuhara N, Fukui T, Yamaguchi-Okada M, Nishioka H, Yamada S: Clinical characteristics of streptococcus pneumoniae meningoencephalitis after transsphenoidal surgery: Three case reports. *Neurol Med Chir (Tokyo)* 54(8):629-633, 2014
10. Kono Y, Prevedello DM, Snyderman CH, Gardner PA, Kassam AB, Carrau RL: One thousand endoscopic skull base surgical procedures demystifying the infection potential: Incidence and description of postoperative meningitis and brain abscesses. *Infect Control Hosp Epidemiol* 32:77-83, 2011
11. Mao L, Jin H, Wang M, Hu Y, Chen S, He Q, Chang J, Hong C, Zhou Y, Wang D, Miao X, Li Y, Hu B: Neurologic manifestations of hospitalized patients with coronavirus disease 2019 in Wuhan, China. *JAMA Neurol* 77(6):683, 2020
12. Mondal R, Ganguly U, Deb S, Shome G, Pramanik S, Bandyopadhyay D, Lahiri D: Meningoencephalitis associated with COVID-19: A systematic review. *J Neurovirol* 27(1):12-25, 2021
13. Moriguchi T, Harii N, Goto J, Harada D, Sugawara H, Takamino J, Ueno M, Sakata H, Kondo K, Myose N, Nakao A, Takeda M, Haro H, Inoue O, Suzuki- Inoue K, Kubokawa M, Ogihara S, Sasaki T, Kinouchi H, Kojin H, Ito M, Onishi H, Shimizu T, Sasaki Y, Enomoto N, Ishihara H, Furuya S, Yamamoto T, Shimada S: A first case of meningitis / encephalitis associated with SARS-Coronavirus-2. *Int J Infect Dis* 94:55-58, 2020
14. Ye M, Ren Y, Lv T: Encephalitis as a clinical manifestation of COVID-19. *Brain Behav Immun* 88:945-946, 2020
15. Young JS, Oh T, Arora T, Blevins LS, Aghi MK, El-Sayed IH, Kunwar S, Theodosopoulos PV: Letter: COVID conundrum: Postoperative COVID-19 infections following endonasal transsphenoidal pituitary surgery. *Neurosurgery* 88(6):E571-E572, 2021