

Thyroxine Accelerates Functional Recovery in a Rat Model of Sciatic Nerve Crush

Mozhdeh AZIMPOUR¹, Fariba MAHMOUDI¹, Arash ABDOLMALEKI^{2,3}, Abolfazl BAYRAMI¹

¹University of Mohaghegh Ardabili, Faculty of Sciences, Ardabil, Iran

²University of Mohaghegh Ardabili, Faculty of Advanced Technologies, Department of Engineering Sciences, Namin, Iran

³Sabalan University of Advanced Technologies (SUAT), Bio Science and Biotechnology Research Center (BBRC), Namin, Iran

Corresponding author: Fariba MAHMOUDI ✉ f.mahmoudi@uma.ac.ir

ABSTRACT

AIM: To see how thyroxine affects the sensory and motor function of a damaged sciatic nerve in male rats.

MATERIAL and METHODS: Forty adult male Wistar rats were allocated to four groups, 10 individuals each. Then, crush injury was done on the right sciatic nerve in all the groups using a vessel clamp. In thyroxine-treated groups and after the crush, the rats were given regular doses of thyroxine (5 and 10 µg/kg) for one week intraperitoneally. Negative control group was treated intraperitoneally with distilled water as a vehicle. In sham operated group, only surgical procedures were performed without nerve crush. Then, behavioral, histological, and morphometric parameters were assessed at the regeneration time.

RESULTS: After one week of treatment with thyroxine, the motor function improved significantly following a sciatic nerve crush ($P \leq 0.05$). Also, morphometric parameters and sensory restoration improved in thyroxine-treated groups.

CONCLUSION: Findings of this study showed that neuro-protective effects of thyroxine can be due to the stimulatory effects of thyroxine in myelin sheath formation and increasing the expression of SCG10 protein which is required for the development of growth cones.

KEYWORDS: Thyroxine, Sciatic nerve injury, Regeneration

INTRODUCTION

Peripheral nerve lesion is a challenging problem, from which patients suffer following extreme trauma. Around 3 percent of all trauma patients are estimated to undergo peripheral nerve injuries and its prevalence rate increases annually (8). The main cause of sensory and motor disability is peripheral nerve damage, which occurs frequently. Severe damage to peripheral nerve leads to impaired ability to move muscles, impaired normal sensation, loss of muscle innervations, and painful neuropathy (16). The peripheral nervous system has inherent ability to self-regenerate after damage. However, in extreme injuries, recovery is almost insufficient and use of agents that promote the regeneration rate is necessary (24).

In this regard, one of the major epigenetic factors that control the nervous system regeneration is the thyroid hormone. Previous reports show that in hypothyroidism mice, thyroid hormone deficiency limits the nerve regeneration by decreasing axonal development (1,20). Thyroid hormone deprivation causes a decline in the number of myelin fibers and a delay in the expansion of axon diameter in the peripheral nervous system (22,27). According to Kormpakis et al. (13), thyroid hormone was shown to accelerate nerve fiber growth and restore sensory neurons in the individuals with ulnar nerve defects. Previous studies demonstrate that thyroid hormone affects all neurologic activities such as myelination, synaptogenesis, and axogenesis and controls the CNS development (14,28,29). Also, Grandel et al. reported that thyroid hormone promoted recovery in the brain of adult fish by conserving most of

the brain's neural stem cells (10). Thyroid hormone is an essential endocrine signal that is retained in all vertebrates and has regenerative potentials. Furthermore, studies have represented that low levels of thyroid hormone may be useful in the treatment of neurodegenerative disorders (4,9). Although many studies have examined the protective effects of thyroxine on central nervous system disorders, neuroprotective action of thyroxine on peripheral nerve regeneration remains unclear. There are a few reports concerning the effects of thyroxine on peripheral nerve regeneration; however, there is no information about the effects of thyroxine on sciatic nerve crush model. In this paper, we used nerve crush model because nerve crush injury in rats is a commonly used axonotmetic model (an experimental model, in which injury has the potential to recover completely) to study regeneration after nerve damage. Generally, suture technique and materials could cause nonselective inflammatory responses in a transaction model, which highlights the novelty of the present study. The majority of studies that have considered thyroid hormone recovery capacity have been restricted to central nervous system disorders; thus, this animal research was planned to investigate the potential effects of thyroid hormone on functional improvement following sciatic nerve hurt.

■ MATERIAL and METHODS

Drugs and Chemicals

Thyroxine was prepared from Merck (Germany) and was injected daily into the animals as a solution in distilled water at doses of 5µg/kg and 10µg/kg. All the injections were given intraperitoneally.

Animals

Forty male Wistar rats, weighing 230–250 g, were employed for this research. The animals were kept in a 12-h light/dark cycle, temperature of 22 ± 2 °C, and humidity of 60 ± 5% with *ad libitum* access to standard rodent food and water. All the experimental protocols were done according to the regulations of Ethics Committee of Ardabil University of Medical Sciences (code: IR.ARUMS.REC.1398.512).

Grouping and Surgical Procedures

Forty male animals were used in four groups (n=10): sham operated group (only performing surgical procedures without nerve crush), negative control group (nerve crushing and treated in traperitoneally with distilled water as a vehicle), and two experimental groups treated every day with thyroxine at 5 and 10 µg/kg doses, respectively, for one week after the crush.

The rats were first given a combination of ketamine (80 mg/kg body weight) and xylazine (10 mg/kg body weight) to make them unconscious. The foot and lumbar skin were shaved and cleaned with a 10% povidone-iodine solution. The skin and leg muscles were surgically cut; then, the right sciatic nerve became visible and a 4 mm section of it was crushed using a hemostatic forceps for 1 min. Afterwards, the muscle layer and skin were disinfected and sutured. Then, the animals were kept alone in cages until recovery. They were given

buprenorphine (1 mg/kg) for two days following surgery to alleviate pain. After one-week adaptation of the rats in animal houses, all the surgeries were done between 9 a.m. and 12 p.m.

Functional and Sensory Recovery Evaluation

The sciatic functional index (SFI) was utilized to evaluate motor function before and after the nerve crush at 2, 4, 6, and eight weeks after the operation. The amount of SFI was commutated using the formula: $SFI = -38.3[(EPL-NPL)/NPL] + 109.5[(ETS-NTS)/NTS] + 13.3 [(EIT-NIT)/NIT] - 8.8$, in which EPL: experimental print length, NPL: normal print length is the distance from top of the third toe to heel, ETS: experimental toe spread, NTS: space between the first and fifth toes on the nonsurgical side, EIT: experimental intermediary toe spread, and NIT: normal intermediary toe spread as the distance between the second and fourth toes. In general, the SFI value varies between 0 and -100; an SFI of around 0 indicates normal function, while -100 indicates total dysfunction. Also, sensory recoveries of the animals were assessed at the same time using a hot-plate test. A hot-plate test is widely used to assess thermal nociception. Briefly, hot-plate is a broadly utilized test for evaluating the thermal nociception. The hot-plate was set to the temperature of 54 °C; then, the rats were wrapped by a careful towel over its midriff and, afterwards, situated to remain with the influenced rear paw on a hot plate and nociceptive withdrawal reflex was evaluated (11). The cut-off latency of 12 sec was used to avoid the tissue injury in this test.

Histomorphometry

The animals were anesthetized with an intraperitoneal injection of ketamine and xylazine at the end of the tests. Afterwards, distal regenerated nerve segments in each group were extracted for histomorphometric examination. Then, tissue segments were fixed in 2.5 % glutaraldehyde and 1 % osmium tetroxide. The samples were then dehydrated in ethanol and embedded in resin; the thin slices (approximately 1 µm) were prepared and stained using toluidine blue for light microscopy analysis. Afterwards, the Image J program was used to calculate morphometric characteristics such as the number of myelinated fibers, myelin sheath thickness, fiber and axon diameters (21).

Gastrocnemius Histological Assessment

In order to identify and study the gastrocnemius muscle atrophy severity, Masson's trichrome staining was used. In brief, the tissue samples were first fixed in formalin (10%) and, then, embedded in paraffin. The sections with 5 µm thick were prepared from the samples by microtome. Then, the prepared samples were deparaffinised and rehydrated. The samples were stained with Mason trichrome. Finally, the prepared slides were evaluated using a light microscope.

Gastrocnemius Muscle Mass Index

As previously mentioned, the weight of the gastrocnemius muscle mass was assessed 8 weeks after the surgery to detect denervation atrophy. The gastrocnemius muscles on both sides were separated and weighed. Then, gastrocnemius

muscle mass ratio of the surgery side and control side was determined. The gastrocnemius muscle atrophy rate on the operated side was indicated by the muscle mass ratio, with a 100 percent gastrocnemius muscle index (GMI) indicating complete recovery on the operated side.

Statistical Analysis

Statistical analyses were done using SPSS Statistics 16.0 software. To determine the statistical significance, all the data were analyzed using one-way analysis of variance (ANOVA) and Tukey's post-hoc test. All the data were presented as the mean with standard deviation (SD). The p -value ≤ 0.05 was considered significant statistically.

RESULTS

Examining Motor Function

According to the results of this test, the amount of SFI in healthy rats was (0 to -10), which indicated the normal motor function. Two weeks after sciatic nerve crush, the SFI level was uniformly low in all the experimental groups without any significant difference, showing that the total loss of the motor function. Subsequently, in weeks 4 and 6, the sciatic nerve function index in the thyroxine-treated group (10 $\mu\text{g}/\text{kg}$) increased significantly in comparison with the negative control rats ($p < 0.05$; Figure 1). Also, when comparing the thyroxine-treated group (5 $\mu\text{g}/\text{kg}$) to the negative control group, the improvement rate in the motor function was higher, although not statistically significant. Eight weeks after the injury results, the groups were treated with thyroxine-treated and the negative control group completely improved their motor function (Figure 1).

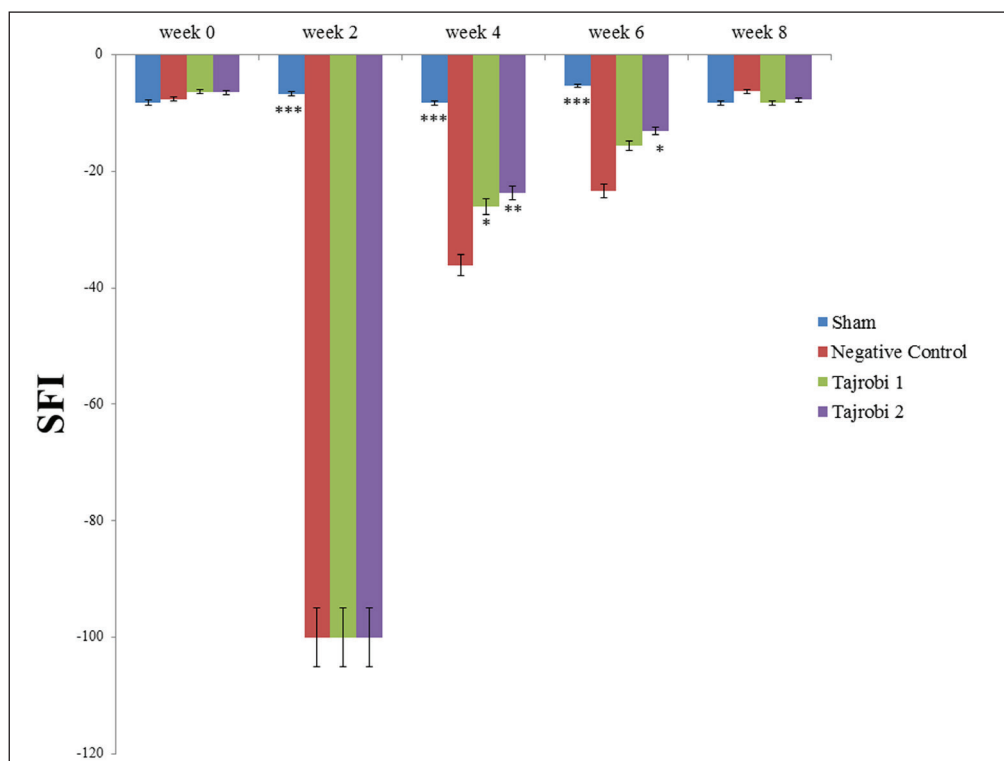


Figure 1: Functional index of sciatic nerve after surgery. Data are presented as mean \pm standard error of mean. $P < 0.05$ *, $p < 0.01$ **, and $p < 0.001$ *** are considered significant compared to the negative control group.

Sensory Recovery Test

Improvement in the sensory function was assessed using a hot-plate test 2, 4, 6, and 8 weeks after the crush. According to the results, the first symptoms of the sensory function improvement were observed 4 weeks after crush. According to the studies, in weeks 4 and 6 after the surgery, the response to the hot-plate test was faster in the group treated with thyroxine (10 $\mu\text{g}/\text{kg}$) than in the negative control group ($p \leq 0.05$; Figure 2). Furthermore, there was no significant difference in heat reaction time between thyroxine-treated (5 $\mu\text{g}/\text{kg}$) and negative control groups (Figure 2).

Histomorphometry Analysis

The results obtained from the morphometric study for each of the experimental groups after staining with toluidine blue are given in Table I. Morphometric results, 8 weeks post-surgery, demonstrated that the fiber number and myelin sheath thickness in the thyroxine-treated group (10 $\mu\text{g}/\text{kg}$) showed a considerable rise when compared to the negative control group ($p < 0.05$; Figure 3A-D). Also, there was no significant difference in the fiber number between the thyroxine-treated (5 $\mu\text{g}/\text{kg}$) and negative control groups. Furthermore, myelin sheath thickness in the thyroxine-treated (5 $\mu\text{g}/\text{kg}$) group was significantly increased in comparison to the negative control group (Table I, Figure 3A-D).

Histological Assessment of Gastrocnemius Muscle

Figure 4 shows the gastrocnemius muscle stained with Mason trichrome in different groups. According to the observed images, it is inferred that the level of the collagen fiber in the

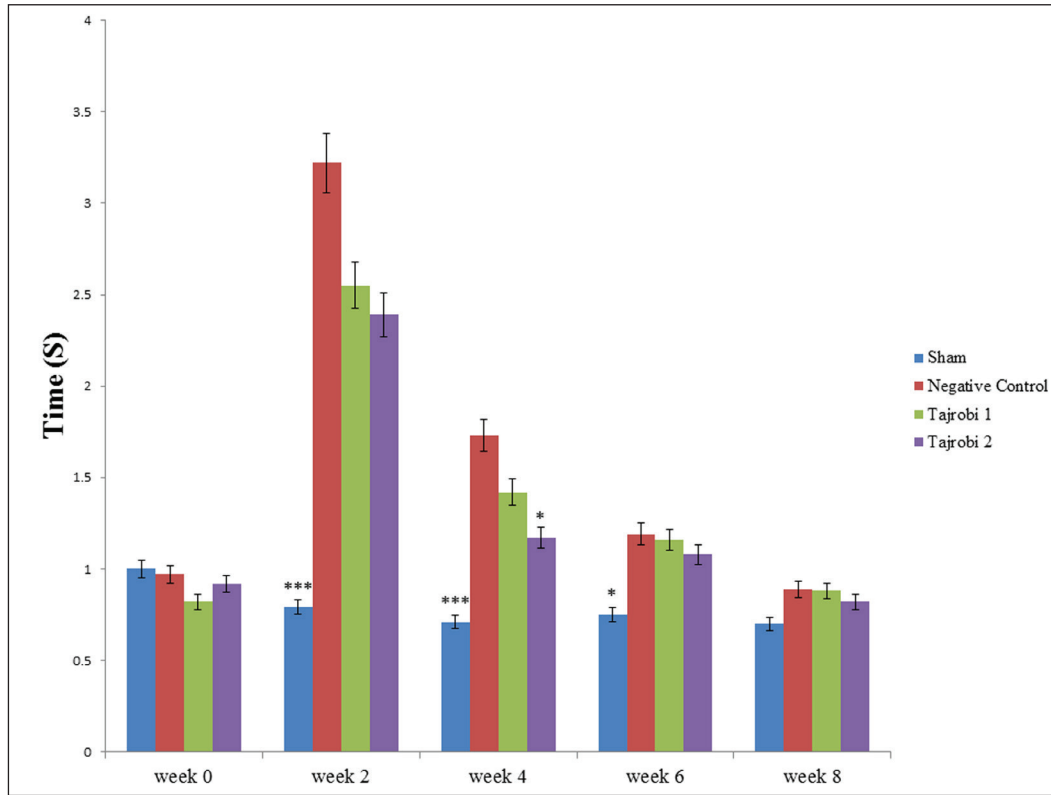


Figure 2: Figure indicates the improvement rate of sensory function in the hot-plate test after surgery. Results are shown as mean \pm standard error of mean. $p < 0.05$ * and *** $p < 0.001$ are considered significant compared to the negative group.

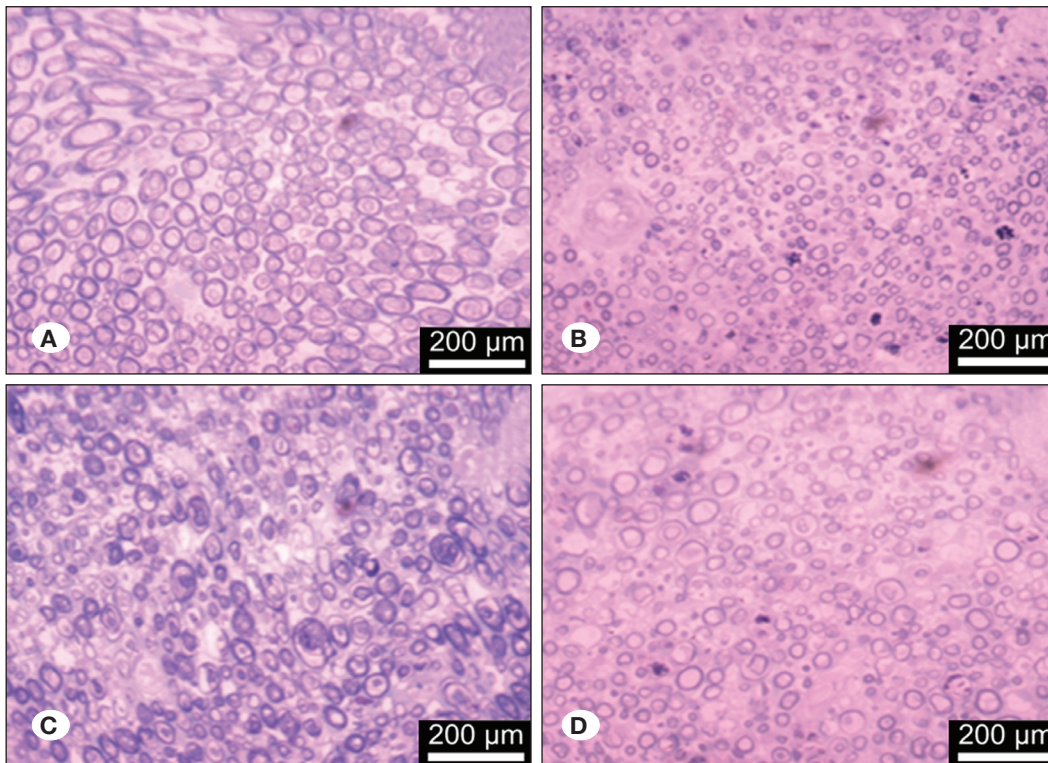


Figure 3: Images of semi-thin transverse sections in the distal part of the sciatic nerve 8 weeks after crush. Sham (A), negative control (B), thyroxinee 5 $\mu\text{g}/\text{kg}$ (C), and thyroxinee 10 $\mu\text{g}/\text{kg}$ (D).

Table 1: Results of Morphometric Examination of the Distal Part of the Sciatic Nerve in the Eighth Week After Surgery. Data are Shown as Mean \pm Standard Error of Mean (n=5), and $p < 0.05$ *, $p < 0.01$ ** and *** $p < 0.001$ were Considered Significant Compared to Negative Control Group

Groups	Number of fibers	Diameter of fibers	Diameter of axon	Thickness of myelin sheath
Sham	4978 \pm 3.9***	6.05 \pm 0.4***	4.08 \pm 0.3***	1.97 \pm 0.2***
Negative control	4559 \pm 4.7	2.01 \pm 0.3	1.47 \pm 0.3	0.52 \pm 0.08
Thyroxine 5 μ g/kg	4387 \pm 11.3*	3.76 \pm 0.13***	2.55 \pm 0.11***	1.21 \pm 0.1***
Thyroxine 10 μ g/kg	9676 \pm 28.6***	4.79 \pm 0.47***	3.53 \pm 0.46***	1.26 \pm 0.05***

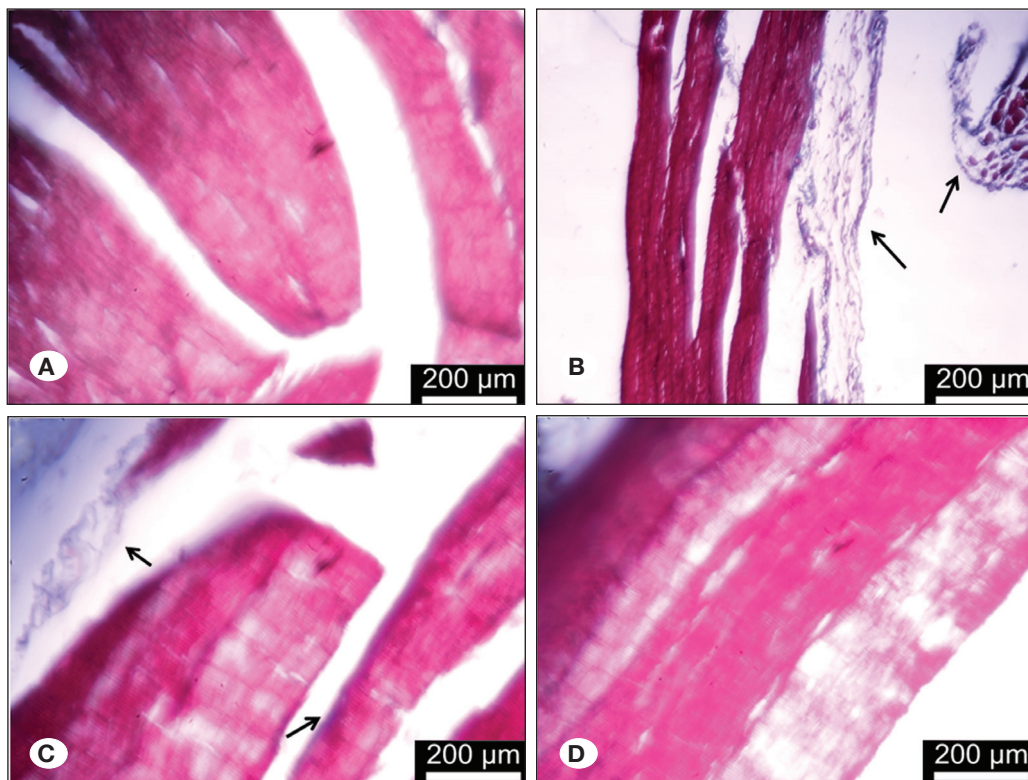


Figure 4: Gastrocnemius muscle stained with Mason trichrome. Sham (A), negative control (B), thyroxine 5 μ g / kg (C), and thyroxine 10 μ g / kg (D).

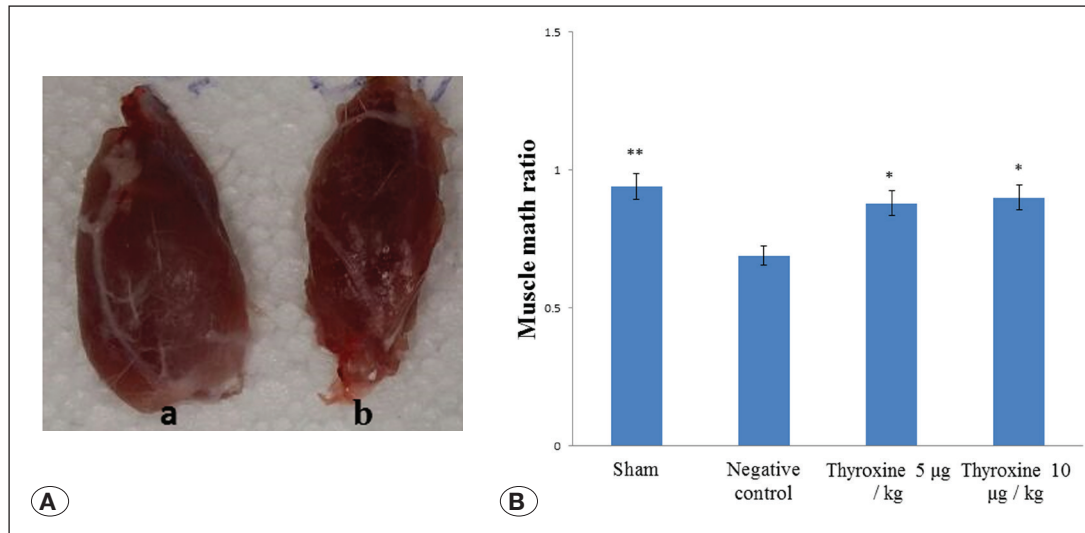
negative control group increased, which indicated muscle atrophy (Figure 4A-D). In addition, in the thyroxine-treated groups, collagen fiber formation was reduced compared to the negative control group. The images also showed that in the sham and thyroxine-treated (10 μ g/kg) groups, there was no level of collagen fiber and atrophy (Figure 4A-D).

Evaluating Gastrocnemius Muscle Mass

Eight weeks after drug treatment with thyroxine, the gastrocnemius muscle in the crushed foot and the healthy foot was separated and weighed. Then, the mean weight ratio of gastrocnemius muscle of the crushed foot to the healthy foot was compared in all the groups. According to the observed results, the operated leg muscle had a different degree of muscle atrophy in all the groups ($p \leq 0.05$; Figure 5). In the groups treated with thyroxine, less degrees of muscle atrophy were observed than other groups ($p \leq 0.05$; Figure 5).

DISCUSSION

Following severe peripheral nerve damage, lack of sensory and motor function severely affects patients' lives. As a result, it is critical to accelerate and improve the restoration of injured axons (30). For years, thyroid hormones have played a crucial role for the normal increase in the nervous system in mammalian embryos and infants (6). According to the present study, treatment with thyroxine at doses of 5 and 10 μ g/kg for one week increased nerve regeneration. Considering the results of SFI, hot-plate, and morphometric analysis, administering thyroxine increased the number of myelin fibers and thickness of myelin sheath; it also improved sensory and motor functions and, thus, led to nerve regeneration. The current study's findings were consistent with those of previous research that have demonstrated the induction of hyperthyroidism in rats could increase axon regeneration at trauma sites. Increasing T3 accelerates the longitudinal growth of regenerative peripheral axons. Also, the protective effect of the hormone

**Figure 5:**

A) Gastrocnemius muscle in the healthy leg of the animal as control (a) and the operated leg (b). The image shows that muscle atrophy occurs in the operated leg. **B)** Comparison of muscle mass ratio 8 weeks after surgery. Data are presented as mean \pm standard error of mean (n=5), $p < 0.05$ * and $p < 0.01$ ** are considered significant compared to the negative control group.

increases in a dose-dependent manner (31). Thyroid hormone carriers across the plasma membrane activate the biological activity of circulating thyroid hormone (3) because both sensory and motor neurons and non-neural cells have T3 receptors (26). T3 has the ability to affect axonal neurons and Schwann cells. Thus, it strengthens several mechanisms for nerve survival and axon regeneration. Neurotrophins, among brain-derived neurotrophic factor (BDNF), neurotrophic factor type 3 (NT3), and nerve growth factor (NGF), are important for neuronal survival and axonal growth. Both BDNF and NT3 are dependent on thyroid hormone, which decreases with thyroid depletion (2). In humans, during the first few days after an adult nervous system injury, BDNF mRNA levels in the CNS and PNS decrease by 50%, indicating that BDNF appears to play a role in neuronal survival. After a traumatic incident, some sensory neurons in the dorsal root ganglion get into an apoptotic process. T3 is thought to have a direct effect on decreasing apoptosis and preserving a large number of sensory neurons (18). By salvage sensory neurons, T3 increases the number of new axons entering the distal portion. One of the most important influences of T3 on peripheral nerve regeneration is the increased myelin sheath formation of new axons. Therefore, treatment with T3 may recover the function of motor and sensory neurons by affecting their maturation and increasing the diameter of the myelin sheath. This efficacy of T3 is possibly a direct stimulant influence on Schwann cells (25). Axotomy can cause peripheral neurons to regrow. Skeletal proteins play a major role in this process since they are involved in axon development, remodeling, growth, transport, and stability. Thyroid hormones (T3) influence the expression of important skeletal proteins involved in regenerating the sciatic nerve (5,15,17,19). In this regard, T3 stimulates SCG10 synthesis which is a regulator of growth cone microtubules (12). The stimulatory effect of T3 on SCG10 expression may furnish a mechanism that improves nerve regeneration. Previous studies have shown that the expression of SCG10 protein in the proximal nerve fragment is significantly enhanced 24 hours after sciatic nerve damage. Because the T3 receptor acts as a ligand-regulated transcription factor, it

may also directly activate SCG10 expression (23). In addition, T3 stimulates the assembly of microtubules that are necessary for axon growth (7).

CONCLUSION

The present findings showed that treatment with thyroxine after peripheral nerve injury accelerated nerve repair and improved sensory and motor function. These results can be due to the stimulatory effects of thyroxine on myelin sheath formation. Thyroxine could decrease the apoptosis and protect the Schwann cells which are necessary for nerve regeneration.

AUTHORSHIP CONTRIBUTION

Study conception and design: FM, AA

Data collection: MA

Analysis and interpretation of results: FM, AA, MA, AB

Draft manuscript preparation: FM, AA, MA

Critical revision of the article: FM

Other (study supervision, fundings, materials, etc...): FM, AA

All authors (FM, AA, AB, MA) reviewed the results and approved the final version of the manuscript.

REFERENCES

1. Ausó E, Cases O, Fouquet C, Camacho M, García-Velasco JV, Gaspar P, Berbel P: Protracted expression of serotonin transporter and altered thalamocortical projections in the barrelfield of hypothyroid rats. *Eur J Neurosci* 14(12):1968-1980, 2001
2. Barde YA: Trophic factors and neuronal survival. *Neuron* 2(6):1525-1534, 1989
3. Bhumika S, Darras VM: Role of thyroid hormones in different aspects of nervous system regeneration in vertebrates. *Gen Comp Endocrinol* 203:86-94, 2014

4. Biondi B, Cappola AR, Cooper DS: Subclinical hypothyroidism: A review. *JAMA* 322(2):153-160, 2019
5. Chan S, Kilby M: Thyroid hormone and central nervous system development. *J Endocrinol* 165(1):1-8, 2000
6. Eayrs J: Influence of the thyroid on the central nervous system. *Br Med Bull* 16(2):122-127, 1960
7. Francon J, Fellous A, Lennon AM, Nunez J: Is thyroxine a regulatory signal for neurotubule assembly during brain development? *Nature* 266(5598):188-190, 1977
8. Ghayour MB, Abdolmaleki A, Behnam-Rassouli M: The effect of Riluzole on functional recovery of locomotion in the rat sciatic nerve crush model. *Eur J Trauma Emerg Surg* 43(5):691-699, 2017
9. Gothié JD, Demeneix B, Remaud S: Comparative approaches to understanding thyroid hormone regulation of neurogenesis. *Mol cell Endocrinol* 459:104-115, 2017
10. Grandel H, Kaslin J, Ganz J, Wenzel I, Brand M: Neural stem cells and neurogenesis in the adult zebrafish brain: origin, proliferation dynamics, migration and cell fate. *Dev Biol* 295(1):263-277, 2006
11. Hargreaves K, Dubner R, Brown F, Flores C, Joris J: A new and sensitive method for measuring thermal nociception in cutaneous hyperalgesia. *Pain* 32(1):77-88, 1988
12. Himi T, Okazaki T, Wang H, McNeill T, Mori N: Differential localization of SCG10 and p19/stathmin messenger RNAs in adult rat brain indicates distinct roles for these growth-associated proteins. *Neuroscience* 60(4):907-926, 1994
13. Korpakakis I, Papalois A, Kinnas P, Zoubos AB, Sioutis I, Dimitriadi A, Soucacos PN, Johnson EO: Silicone tubes with thyroid hormone (T3) and BDNF as an alternative to autografts for bridging neural defects. *Injury* 51(12):2879-2886, 2020
14. Krieger TG, Moran CM, Frangini A, Visser WE, Schoenmakers E, Muntoni F, Clark CA, Gadian D, Chong WK, Kuczynski A, DattNI M, Lyons G, Efthymiadou A, Varga-Khadem F, Simons BD, Chatterjee K, Livesey FJ: Mutations in thyroid hormone receptor $\alpha 1$ cause premature neurogenesis and progenitor cell depletion in human cortical development. *Proc Natl Acad Sci* 116(45):22754-22763, 2019
15. Lazarus JH: Thyroid hormones and neurodevelopment. *Clin Endocrinol* 50(2):147-148, 1999
16. Lee JI, Hur JM, You J, Lee DH: Functional recovery with histomorphometric analysis of nerves and muscles after combination treatment with erythropoietin and dexamethasone in acute peripheral nerve injury. *PLoS one* 15(9):e0238208, 2020
17. Legrand J: Hormones thyroïdiennes et maturation du système nerveux. Thyroid hormones and maturation of the nervous system. *J Physiol (Paris)* 78(7):603-652, 1982-1983
18. Lipska BK, Khaing ZZ, Weickert CS, Weinberger DR: BDNF mRNA expression in rat hippocampus and prefrontal cortex: Effects of neonatal ventral hippocampal damage and antipsychotic drugs. *Eur J Neurosci* 14(1):135-144, 2001
19. Oppenheimer JH, Schwartz HL: Molecular basis of thyroid hormone-dependent brain development. *Endocr Rev* 18(4):462-475, 1997
20. Rabie A, Favre C, Clavel M, Legrand J: Effects of thyroid dysfunction on the development of the rat cerebellum, with special reference to cell death within the internal granular layer. *Brain Res* 120(3):521-531, 1977
21. Raimondo S, Fornaro M, Di Scipio F, Ronchi G, Giacobini-Robecchi MG, Geuna S: Methods and protocols in peripheral nerve regeneration experimental research: Part II—morphological techniques. *Int Rev Neurobiol* 7:81-103, 2009
22. Reier P, Hughes A: An effect of neonatal radiothyroidectomy upon nonmyelinated axons and associated Schwann cells during maturation of the mouse sciatic nerve. *Brain Res* 41(2):263-282, 1972
23. Richardson PM, Ebendal T: Nerve growth activities in rat peripheral nerve. *Brain Res* 246(1):57-64, 1982
24. Rodríguez Sánchez DN, de Lima Resende LA, Boff Araujo Pinto G, de Carvalho Bovolato AL, Possebon FS, Deffune E, Amorim RM: Canine adipose-derived mesenchymal stromal cells enhance neuroregeneration in a rat model of sciatic nerve crush injury. *Cell Transplant* 28(1):47-54, 2019
25. Schenker M, Kraftsik R, Glauser L, Kuntzer T, Bogousslavsky J, Barakat-Walter I: Thyroid hormone reduces the loss of axotomized sensory neurons in dorsal root ganglia after sciatic nerve transection in adult rat. *Exp Neurol* 184(1):225-236, 2003
26. Secades JJ: Citicoline: Pharmacological and clinical review. *Rev Neurol* 63(S03):S1-S73, 2016
27. Stepien BK, Huttner WB: Transport, metabolism, and function of thyroid hormones in the developing mammalian brain. *Front Endocrinol* 10:209, 2019
28. Vancamp P, Butruille L, Demeneix BA, Remaud S: Thyroid hormone and neural stem cells: Repair potential following brain and spinal cord injury. *Front Neurosci* 14:875, 2020
29. Vancamp P, Demeneix BA, Remaud S: Monocarboxylate transporter 8 deficiencies: Delayed or permanent hypomyelination? *Front Endocrinol* 11:283, 2020
30. Voinesco F, Glauser L, Kraftsik R, Barakat-Walter I: Local administration of thyroid hormones in silicone chamber increases regeneration of rat transected sciatic nerve. *Exp Neurol* 150(1):69-81, 1998
31. Yamada KM, Spooner BS, Wessells NK: Ultrastructure and function of growth cones and axons of cultured nerve cells. *J Cell Biol* 49(3):614-635, 1971