



Comparison of Lateral Interbody Fusion and Posterior Interbody Fusion for Discogenic Low Back Pain

Woo Kyung KIM, Seong SON, Sang Gu LEE, Jong Myung JUNG, Byung Rhae YOO

Department of Neurosurgery, Gil Medical Center, Gachon University College of Medicine, Incheon, Republic of Korea

Corresponding author: Seong SON ✉ sonseong@gilhospital.com

ABSTRACT

AIM: To compare lateral (direct [DLIF] or oblique [OLIF]) and posterior (posterior [PLIF] or transforaminal [TLIF]) lumbar interbody fusion results in patients with the same indication of discogenic low back pain.

MATERIAL and METHODS: We enrolled 46 patients who underwent single-level DLIF/OLIF or PLIF/TLIF with at least 1 year of follow-up. Patients were divided into two groups: a lateral group (n=24) who underwent DLIF/OLIF and a posterior group (n=22) who underwent PLIF/TLIF. Clinical, surgical, and radiological outcomes were retrospectively evaluated.

RESULTS: Baseline factors, including demographic data, preoperative symptoms, and preoperative radiological findings, were not significantly different between the two groups. In addition, the clinical and radiological outcomes at 1-year post-surgery did not differ between the two groups. However, the DLIF/OLIF procedure conferred significant advantages as follows: favorable postoperative low back pain and patient satisfaction at 1-week and 1-month post-surgery; shorter operation time (mean 173.33 ± 11.54 versus 208.64 ± 17.48 min, $p < 0.001$); less blood loss during surgery (mean 127.50 ± 41.36 versus 372.73 ± 123.21 mL, $p < 0.001$); and greater restoration of calibrated disc height at 1-year post-surgery (mean 5.80 ± 1.44 versus 0.50 ± 1.22 , $p = 0.008$). There was no statistically significant difference in the incidence of complications between the two groups. However, complications tended to be more frequent in the lateral group; 7 (29.2%) patients in the lateral group and 3 patients (13.6%) in the posterior group.

CONCLUSION: Our findings suggest that the lateral group achieved better perioperative outcomes and disc height restoration than the posterior group, although there was no significant difference in the 1-year clinical outcomes.

KEYWORDS: Intervertebral disc, Intervertebral disc degeneration, Low back pain, Fusion

ABBREVIATIONS: **DLIF:** Direct lumbar interbody fusion, **LBP:** Low back pain, **MRI:** Magnetic resonance imaging, **K-ODI:** Korean version of Oswestry Disability Index, **OLIF:** Oblique lumbar interbody fusion, **PLIF:** Posterior lumbar interbody fusion, **TLIF:** transforaminal interbody fusion, **VAS:** Visual analogue scale

INTRODUCTION

Discogenic low back pain (LBP) originating from disc degeneration or internal disruption without other definite pathologies, such as definite herniation of the nucleus pulposus, spondylolisthesis, or instability, affects nearly 26%–42% of all patients with LBP (35,40). In cases of intractable or persistent discogenic LBP despite sufficient

conservative treatment, lumbar fusion surgery is an active treatment method (3,6,13,14,29).

Posterior interbody fusion, including posterior lumbar interbody fusion (PLIF) and transforaminal interbody fusion (TLIF), has been widely used with sufficient evidence of safety and favorable outcomes since the 1980s, and has been developed for minimally invasive surgery using tubular

Woo Kyung KIM : 0000-0002-0974-903X
Seong SON : 0000-0002-2815-9908
Sang Gu LEE : 0000-0001-9943-4906

Jong Myung JUNG : 0000-0002-3718-7740
Byung Rhae YOO : 0000-0002-5696-5931

retractors (7,8,11,22,26). On the other hand, a minimally invasive lateral approach, including direct lumbar interbody fusion (DLIF) and oblique lumbar interbody fusion (OLIF) using special tubular retractors, has been used as an alternative to posterior interbody fusion (24,30,36,38). Many previous studies have compared outcomes between DLIF/OLIF and PLIF/TLIF (19–21,32,39). However, these studies showed potential bias due to heterogeneity in patient selection or surgical indications.

This study compared the clinical, radiological, and surgical outcomes of lateral fusion surgery and posterior fusion surgery at a single level in a single center based on the same surgical indication, focusing on discogenic LBP without significant nerve root compression. To the best of our knowledge, this is the first study to compare the outcomes of DLIF/OLIF and PLIF/TLIF for discogenic LBP using a retrospective matched cohort design.

MATERIAL and METHODS

Surgical Indications and Patient Selection

This study was approved by the institutional review board of our institution (GBIRB2020-300). The data of all patients who underwent DLIF/OLIF or PLIF/TLIF for discogenic LBP at our institute between January 2008 and December 2018 were collected retrospectively. The requirements for informed consent was waived because of the study’s retrospective design and anonymization of data.

All patients underwent discography to confirm discogenic LBP before surgery (37). A positive pathogenic disc was determined if similar severe LBP was reproduced with a correlated annular tear or leakage of contrast agent on post-procedural computed tomography (34). The indications for

fusion surgery were as follows: 1) intractable LBP despite at least 3 months of conservative treatment; 2) no other diagnosis related to LBP except disc degeneration in imaging studies and clinical investigation; and 3) no surgical contraindications, such as infection or hematologic coagulation disorder.

To minimize the bias related to patient selection and surgical effect, the exclusion criteria were as follows: 1) multi-level surgery; 2) spondylolisthesis; 3) insufficient follow-up of a minimum of 1 year or lack of data; and 4) previous history of surgery on the lumbar spine.

Among the 74 patients who underwent discography and fusion surgery, 28 patients were excluded; 13 who underwent multi-level surgery, 10 with spondylolisthesis, 3 with less than 1-year of follow-up, and 2 with a history of previous surgery. Finally, 46 patients were enrolled in the study cohort and allocated to two groups: a lateral group (n=24) who underwent DLIF/OLIF and a posterior group (n=22) who underwent PLIF/TLIF (Figure 1).

Operative Technique

Three different surgeon performed discography and surgery. The surgical technique and equipment used were determined depending on the surgeon’s preference, equipment availability at the time of surgery, surgery level, and preoperative planning.

In the lateral group, the patients were placed in the lateral decubitus position. An oblique or transverse incision of 5–8 cm was made according to the surgery level. After blunt dissection, a tubular retractor of the DLIF or OLIF system (Medtronic Sofamor Danek, Memphis, TN, USA) was inserted. Discectomy and endplate preparation followed by interbody fusion using polyetheretherketone cages (Clydesdale® or Perimeter®, Medtronic Sofamor Danek, Memphis, TN, USA)

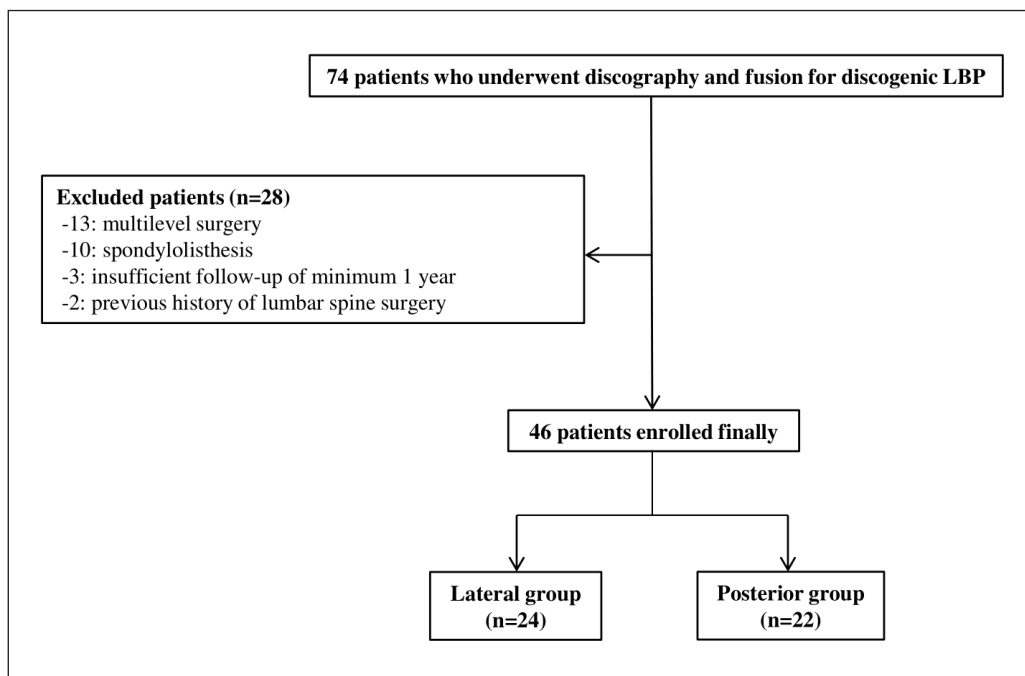


Figure 1: Patient selection.

with aspirated bone marrow and demineralized bone matrix were performed. DLIF was performed at the L1–L4 level and OLIF was performed at the L5–S1 level.

In the posterior group, the patients were placed in the prone position with reduced abdominal pressure. A 4–5 cm midline or slight paramedian incision was made. After unilateral periosteal dissection, a Caspar-type retractor was inserted. After bone work of laminectomy and/or facetectomy according to preoperative plan or surgeon's preference, disc space evacuation and interbody fusion were performed using polyetheretherketone cages (Capstone®, Medtronic Sofamor Danek, Memphis, TN, USA) with aspirated bone marrow and demineralized bone matrix.

In both groups, percutaneous pedicle screw fixation (Sextant®, Medtronic Sofamor Danek, Memphis, TN, USA) was performed under fluoroscopic guidance in the prone position. The wound was sutured in a layer-by-layer fashion after drain insertion, if necessary.

Demographic Data and Baseline Characteristics

Demographic data, including age, sex, body mass index, smoking status, alcohol consumption, bone mineral density measured by T-score on dual-energy X-ray absorptiometry, preoperative symptom duration, and follow-up duration, were analyzed.

Baseline radiological findings of magnetic resonance imaging (MRI), including surgical level, degree of disc degeneration based on Pfirrmann grade (31), endplate degeneration based on Modic change (27), endplate sclerosis (2), facet joint degeneration (5), degree of disc herniation (bulging or protrusion), and the existence of a high-intensity zone implying annular tear (1), were analyzed.

In addition, the cross-sectional area of the paraspinal muscles and fat deposition of the multifidus muscle were analyzed at the L4–L5 level to exclude the effect of paravertebral muscles on the clinical outcomes after surgery (9).

Outcome Evaluation

We performed a retrospective case-control study to compare the outcomes between the two groups. Clinical surveys and radiological data obtained from the outpatient clinic were collected.

Pain was assessed using the visual analog scale (VAS) scores for LBP and leg pain. Condition-specific outcomes were evaluated using the Korean version of the Oswestry Disability Index (K-ODI). Data were collected preoperatively and at each follow-up (1 week, 1 month, and 1-year post-surgery). Patient satisfaction after surgery was assessed using Odom's criteria at each postoperative follow-up.

Surgical outcomes were analyzed using anesthesia time, operation time, estimated intraoperative blood loss, surgical complications, such as iatrogenic durotomy, neurologic aggravation, or surgical site infection; morbidity, such as pneumonia, cardiac problems, or deep vein thrombosis; and duration of hospital stay. Anesthesia time was determined as the period from induction to finish, including patient position

and drape, operation time from skin incision to wound closure, and intervention time for position change in DLIF/OLIF cases.

Plain static and dynamic radiographs were obtained preoperatively, at 1-month post-surgery, and at 1-year post-surgery to evaluate radiological outcomes. The disc height was measured as the average of the anterior and posterior disc height and calibrated using the following formula to overcome variations by X-ray magnification: [average DH (mm)/anteroposterior diameter of L5 body (mm)] × 10.

Segmental angle and lumbar lordosis were measured using Cobb's method to assess changes in lumbar alignment. Fusion rates were assessed based on X-ray findings at 1 year. Fusion was defined as the presence of intervertebral bridging bone or <5° motion and <3 mm translation between the flexion and extension radiographs without a halo surrounding the devices (23).

Findings based on the radiographs were measured by two researchers independently; quantitative factors were assessed as averages and qualitative factors were assessed by consensus. One author (SS) measured all parameters and repeated the measurements after three days. Additionally, the other spine surgeon (BRY) independently measured the parameters again. An inter-rater correlation coefficient was analyzed to confirm the reproducibility, and the values were >0.95 within one observer and >0.90 between observers.

Statistical Analysis

Data management and statistical analyses were performed using SPSS version 26.0 (IBM Corp., Armonk, NY, USA). Pearson's chi-square tests, independent t-tests, non-parametric Mann-Whitney U-tests, and ANOVA tests were used according to the characteristics of the data. The results were expressed as mean ± standard deviation or median with range, depending on whether the data were normally distributed. Statistical significance was accepted for p-values <0.05.

RESULTS

Demographic Data and Baseline Characteristics

No significant intergroup differences were observed in the demographic data and baseline characteristics (Table I). Additionally, there was no difference in preoperative MRI findings, including surgery level, degree of degenerative change, and paraspinal muscle status (Table II). Preoperative simple standing radiographic findings, including disc height, segmental angle, range of motion, and lumbar lordosis, did not differ between the two groups (Table II).

Clinical Outcomes

Preoperative back pain VAS scores were not significantly different between the two groups and decreased progressively during follow-up in both groups ($p < 0.001$, Friedman ANOVA test). However, back pain VAS scores were found to be more favorable in the lateral group than in the posterior group at 1 week and 1-month post-surgery when assessed by the non-parametric Mann-Whitney U-test (median 3.0 [range,

Table I: Demographic Data and Baseline Characteristics

	Lateral group (n=24)	Posterior group (n=22)	p
Age (years)	42.92 ± 8.24	38.45 ± 9.52	0.242 [†]
Sex, male/female	10/14	12/10	0.684 [‡]
Height (cm)	170.45 ± 8.65	168.45 ± 7.79	0.568 [†]
Weight (kg)	68.41 ± 22.68	66.13 ± 15.56	0.783 [†]
Body mass index (kg/m ²)	23.23 ± 7.12	23.06 ± 3.62	0.945 [†]
Bone mineral density (T-score)	-1.71 ± 0.4	-1.69 ± 0.5	0.798 [†]
Smoking parameters (pack-years)	4.19 (range, 0.00–15.00)	2.27 (range, 0–20.00)	0.379 [‡]
Alcohol consumption (g/week)	0.8 (range, 0.0–322.0)	1.6 (range, 0.0–644.0)	0.608 [¶]
Symptom duration (years)	1.96 (range, 0.50–4.00)	1.86 (range, 0.20–2.00)	0.599 [¶]
Follow up duration (years)	1.75 (range, 1.00–4.00)	3.18 (range, 1.00–10.00)	0.173 [¶]

[†]Independent t-test; [‡]Pearson's chi-square test; [¶]Non-parametric Mann-Whitney U-test.

Table II: Preoperative Characteristics on Magnetic Resonance Imaging and Simple Radiograph

	Lateral group (n=24)	Posterior group (n=22)	p
Level, L2-3/L3-4/L4-5/L5-S1	2/4/8/10	1/1/12/8	0.256 [†]
Degenerative change			
Pfirmann grade, I/II/III/IV/V	0/8/12/4/0	0/6/10/6/0	0.418 [†]
Modic change, 0/I/II/III	14/4/2/1	16/8/0/1	0.466 [†]
Endplate degeneration, 0/I/II/III	20/4/0/0	18/4/0/0	0.772 [†]
Facet joint degeneration, 0/I/II/III	4/14/0/0	1/20/1/0	0.227 [†]
High intensity zone	8	4	0.713 [†]
Type of disc herniation, bulging/protruded	10/14	9/13	0.706 [†]
Para-spinal muscle			
Fat infiltration of multifidus, I/II/III	17/7/0	18/4/0	0.887 [†]
Cross-sectional area of Psoas (mm ²)	452.20 ± 160.28	407.94 ± 247.75	0.676 [‡]
Cross-sectional area of spine erector (mm ²)	1097.91 ± 203.48	1118.12 ± 310.79	0.931 [‡]
Cross-sectional area of Multifidus (mm ²)	270.77 ± 51.01	244.86 ± 68.87	0.381 [‡]
Cross-sectional area of Quadratus (mm ²)	345.82 ± 62.61	347.52 ± 182.15	0.864 [‡]

[†]Pearson's chi-square test; [‡]Independent t-test.

2.0–3.0] in the lateral group versus 4.0 [range, 2.0–5.0] in the posterior group at 1 week, $p=0.005$; and median 1.0 [range, 1.0–2.0] in the lateral group versus 3.0 [range, 2.0–4.0] in the posterior group at 1 month, $p<0.001$). In contrast, there was no difference at 1 year postoperatively (median 1.0 [range, 0.0–1.0] in the lateral group versus 1.0 [range, 0.0–4.0] in the posterior group, $p=0.315$) (Table III). In other words, back pain VAS scores decreased more significantly in the lateral group at 1 week and 1-month post-surgery, although the decline at 1 year was not significantly different between the two groups.

Preoperative leg pain VAS scores were not significantly different between the two groups and decreased gradually after surgery during follow-up in both groups ($p<0.001$, Friedman ANOVA test). Decreases in leg pain VAS scores were not significantly different between the two groups (Table III).

Preoperative K-ODIs were not significantly different between the two groups and decreased progressively during follow-up in both groups ($p<0.001$, Friedman ANOVA test). However, K-ODI was more favorable in the lateral group than in the posterior group at 1week and 1 month postoperatively by

the non-parametric Mann-Whiney U-test (median 26.0 [range 24.0–32.0] in the lateral group versus 32.0 [range 24.0–36.0] in the posterior group at 1 week, p=0.009; and median 10.0 [range 10.0–16.0] in the lateral group versus 24.0 [range 12.0–34.0] in the posterior group at 1 month, p<0.001). In contrast, there was no difference at 1 year postoperatively (median 8.0 [range 4.0–12.0] in the lateral group versus 10.0 [range 4.0–

24.0] in the posterior group, p=0.190) (Table III). Thus, K-ODIs decreased more significantly in the lateral group at 1 week and 1-month post-surgery, although the decline at 1 year was not significantly different between the two groups.

According to Odom’s criteria, patient satisfaction after surgery were favorable in both groups; it was significantly better in the lateral group than in the posterior group at 1 week and

Table III: Clinical Outcomes

	Lateral group (n=24)	Posterior group (n=22)	p
VAS back			
Preoperative	8.0 (range 7.0–9.0)	8.0 (range 8.0–10.0)	0.232 [†]
1 week	3.0 (range 2.0–3.0)	4.0 (range 2.0–5.0)	0.005[†]
1 month	1.0 (range 1.0–2.0)	3.0 (range 2.0–4.0)	<0.001[†]
1 year	1.0 (range 0.0–1.0)	1.0 (range 0.0–4.0)	0.315 [†]
VAS leg			
Preoperative	2.0 (range 1.0–3.0)	2.0 (range 1.0–4.0)	0.449 [†]
1 week	1.0 (range 0.0–2.0)	1.0 (range 0.0–3.0)	0.436 [†]
1 month	0.0 (range 0.0–2.0)	1.0 (range 0.0–2.0)	0.190 [†]
1 year	0.0 (range 0.0–1.0)	0.0 (range 0.0–1.0)	0.280 [†]
K-ODI			
Preoperative	73.0 (range 70.0–78.0)	71.0 (range 70.0–78.0)	0.393 [†]
1 week	26.0 (range 24.0–32.0)	32.0 (range 24.0–36.0)	0.009[†]
1 month	10.0 (range 10.0–16.0)	24.0 (range 12.0–34.0)	<0.001[†]
1 year	8.0 (range 4.0–12.0)	10.0 (range 4.0–24.0)	0.190 [†]
Odom’s criteria at 1 week			0.027[‡]
Excellent	12	4	
Good	12	15	
Fair	0	3	
Poor	0	0	
Odom’s criteria at 1 month			0.007[‡]
Excellent	20	10	
Good	4	12	
Fair	0	0	
Poor	0	0	
Odom’s criteria at 1 year			0.322[‡]
Excellent	22	18	
Good	2	4	
Fair	0	0	
Poor	0	0	

K-ODI: Korean Oswestry Disability Index; **VAS:** Visual analog scale, [†]non-parametric Mann-Whitney U-test; [‡]Pearson’s chi-square test.

1-month post-surgery by the Pearson's chi-square test ("Excellent" reported by: 12 patients [50.0%] in the lateral group versus 4 patients [18.1%] in the posterior group at 1 week, $p=0.027$; and 20 patients [83.3 %] in the lateral group versus 10 patients [45.5%] in the posterior group at 1 month, $p=0.007$). However, patient satisfaction at 1 year did not differ between the groups (Table III).

Surgical Outcomes

The lateral group consisted of 14 patients with DLIF and 10 patients with OLIF, and the posterior group consisted of nine patients with PLIF and 13 patients with TLIF.

The operation time was significantly shorter in the lateral group than in the posterior group (173.3 ± 11.5 minutes in the lateral group versus 188.6 ± 17.5 minutes in the posterior group, $p<0.001$, independent t-test). Additionally, estimated blood loss was significantly lower in the lateral group than in the posterior group (127.5 ± 41.4 mL in the lateral group versus 372.7 ± 123.2 mL in the posterior group, $p<0.001$, independent t-test). The duration of hospital stay did not differ between the two groups (Table IV).

There were no severe complications after the procedure in either group and the overall complication rates were not different between the two groups. However, there was a tendency for more complications in the lateral group; seven (29.2%) patients in the lateral group (transient mild leg weakness and/or transient thigh numbness/pain due to injury of the psoas muscle in 5 patients with DLIF, mild dysesthesia in the unilateral leg due to injury of the superior hypogastric plexus in 1 patient with OLIF, and minute injury of the left common iliac vein wall and properly managed by immediate primary suture in 1 patient with OLIF) and three patients (13.6%) in the posterior group (iatrogenic durotomy during surgery in 1 patient with PLIF, and transient thigh numbness/pain in 1 patient with PLIF and in 1 patient with TLIF). One patient in the lateral group complained of persistent mild

dysesthesia of the unilateral leg, whereas none in the posterior group had any persistent complications. There was one case of postoperative morbidity due to pneumonia in the posterior group (Table IV).

Radiological Outcomes

The mean calibrated disc height at the index level was not different between the groups preoperatively. The mean calibrated disc height was significantly increased at 1-month post-surgery and then gradually decreased at 1-year post-surgery in both groups ($p<0.001$, ANOVA test); there was no significant difference between the two groups during follow-up. However, the degree of increase between pre-operation and 1-month values was significantly higher in the lateral group than in the posterior group (10.40 ± 5.54 mm in the lateral group versus 5.49 ± 3.05 mm in the posterior group, $p=0.010$, independent t-test). Additionally, the degree of increase between pre-operation and 1-year values was significantly higher in the lateral group than in the posterior group (5.80 ± 1.44 mm in the lateral group versus 0.50 ± 1.22 mm in the posterior group, $p=0.008$, independent t-test). However, the degree of decrease between the 1 month and 1-year values was not different between the two groups (4.60 ± 1.51 in the lateral group versus 5.01 ± 2.84 in the posterior group, $p=0.579$, independent t-test) (Table V).

The mean segmental angle of the index level was not different between the groups preoperatively. At 1-month post-surgery, the mean segmental angle was greater in the lateral group than in the posterior group ($10.14 \pm 5.16^\circ$ in the lateral group versus $6.11 \pm 2.44^\circ$ in the posterior group, $p=0.038$, independent t-test). Interestingly, the mean segmental angle at 1 month was significantly increased in the lateral group and decreased in the posterior group ($3.50 \pm 2.45^\circ$ in the lateral group versus $-2.12 \pm 2.01^\circ$ in the posterior group, $p=0.020$, independent t-test). However, there was no difference between the two groups at 1-year post-surgery (Table V).

Table IV: Surgical Outcomes

	Lateral group (n=24)	Posterior group (n=22)	Difference	p
Surgery technique	DLIF/OLIF=14/10	PLIF/TLIF=9/13		
Anesthesia time (min)	228.33 \pm 17.49	258.63 \pm 20.50	30.30 (95% CI, 13.82–46.79)	0.001[†]
Operation time (min)	173.33 \pm 11.54	208.64 \pm 17.48	35.30 (95% CI, 22.57–48.04)	<0.001[†]
Estimated blood loss (mL)	127.50 \pm 41.36	372.73 \pm 123.21	245.23 (95% CI, 166.98–323.48)	<0.001[†]
Hospital stay (days)	12.0 (range 10.0-19.0)	13.00 (range, 11.0-16.0)		0.566 [‡]
Complication (n)	7 (29.2%)	3 (13.6%)		0.118 [¶]
Morbidity (n)	0	1		NA

CI: Confidence interval, **DLIF:** Direct lumbar interbody fusion, **NA:** not available, **OLIF:** Oblique lumbar interbody fusion, **PLIF:** Posterior lumbar interbody fusion, **TLIF:** Transforaminal interbody fusion, [†]Independent t-test; [‡]Non-parametric Mann-Whitney U-test; [¶]Pearson's chi-square test.

Lumbar lordosis was not significantly different between the groups preoperatively. Although mean lumbar lordosis was not different at 1-month post-surgery, it increased significantly in the lateral group, whereas it decreased in the posterior group ($6.07 \pm 5.54^\circ$ in the lateral group versus $-0.12 \pm 8.14^\circ$ in the posterior group, $p=0.030$, independent t-test). However, there was no difference between the two groups at 1-year post-surgery (Table V).

The fusion rate did not differ between the two groups at 1-year post-surgery (91.7% (22/24) in the lateral group and 86.3% (19/22) in the posterior group, $p=0.322$, Pearson's chi-square test) (Figure 2).

■ DISCUSSION

Posterior fusion surgery of the lumbar spine (including PLIF or TLIF) is a classical fusion technique familiar to surgeons, which allows for the confirmation of the nerve route status and to perform direct decompression of the central canal

or foramen (7,8,11,33). However, this procedure has the disadvantages such as posterior paraspinal muscle dissection and injury, direct manipulation of the thecal sac or nerve root, risk of iatrogenic dural tear, shorter height and narrower cross-sectional area of the inserted cage than the anterior approach, and limited correction of deformity (12,15,33). Lateral fusion surgery (including DLIF or OLIF) using a retroperitoneal approach helps avoid the aforementioned disadvantages of the posterior approach with a larger height and wider cross-sectional area of the cage and indirect decompression of the foramen (16,25,30). However, the lateral approach has disadvantages such as the risk of injury to the psoas muscle, major vessels, peritoneum, hypogastric sympathetic plexus injury, and lumbar plexus damage (4,10,17,18).

Many previous studies have compared outcomes between lateral and posterior fusion techniques in degenerative lumbar spine disease, such as central stenosis, foraminal stenosis, spondylolisthesis, or deformity (19-21,26,28,32,39). However, almost all studies involved patient selection bias due to

Table V: Radiological Outcomes

	Lateral group (n=24)	Posterior group (n=22)	Difference	p
Calibrated disc height				
Preoperative	20.02 ± 6.09	23.42 ± 3.45	-3.40 (95%CI, -9.91–3.11)	0.314 [†]
1 month	30.42 ± 6.1	28.91 ± 4.3	1.51 (95%CI, -3.06–4.58)	0.534 [†]
1 year	25.82 ± 4.3	23.92 ± 2.3	1.90 (95%CI, -3.48–5.50)	0.440 [†]
Δ (1month-preoperative)	10.40 ± 5.54	5.49 ± 3.05	4.91 (95%CI, 3.40–6.44)	0.010[†]
Δ (1year-1month)	-4.60 ± 1.51	-5.01 ± 2.84	0.41 (95%CI, -1.09–1.91)	0.579 [†]
Δ (1year-preoperative)	5.80 ± 1.44	0.50 ± 1.22	5.30 (95%CI, 3.82–6.80)	0.008 [†]
Segmental angle (°)				
Preoperative	6.64 ± 1.81	8.23 ± 2.55	-1.59 (95%CI, -5.53–2.35)	0.573 [†]
1 month	10.14 ± 5.16	6.11 ± 2.44	4.03 (95%CI, 0.28–7.78)	0.038[†]
1 year	6.92 ± 1.22	5.70 ± 1.16	1.22 (95%CI, -0.56–3.01)	0.153 [†]
Δ (1month- preoperative)	3.50 ± 2.45	-2.12 ± 2.01	5.62 (95%CI, 1.74–9.50)	0.020[†]
Δ (1year-1month)	-3.22 ± 4.03	0.41 ± 2.12	-2.81 (95%CI, -11.70–6.08)	0.256 [†]
Δ (1year- preoperative)	0.28 ± 1.42	-2.53 ± 2.89	2.81 (95%CI, -0.98–6.60)	0.080 [†]
Lumbar lordosis (°)				
Preoperative	35.65 ± 7.00	36.05 ± 12.65	-0.40 (95%CI, -5.31–4.51)	0.925 [†]
1 month	41.72 ± 2.43	35.93 ± 5.27	5.79 (95%CI, -1.69–13.27)	0.231 [†]
1 year	39.75 ± 9.24	34.40 ± 17.89	5.35 (95%CI, -1.40–12.10)	0.206 [†]
Δ (1month- preoperative)	6.07 ± 5.54	-0.12 ± 8.14	6.19 (95%CI, 2.23–10.15)	0.030[†]
Δ (1year-1month)	-1.97 ± 6.85	-1.53 ± 7.52	-0.44 (95%CI, -3.6–3.60)	0.259 [†]
Δ (1year- preoperative)	4.10 ± 8.25	-1.65 ± 13.41	2.45 (95%CI, -5.40–10.30)	0.077 [†]
Fusion rate	22 (91.7%)	18 (81.8%)		0.322 [‡]

CI: Confidence interval, [†]Independent t-test; [‡]Pearson's chi-square test.

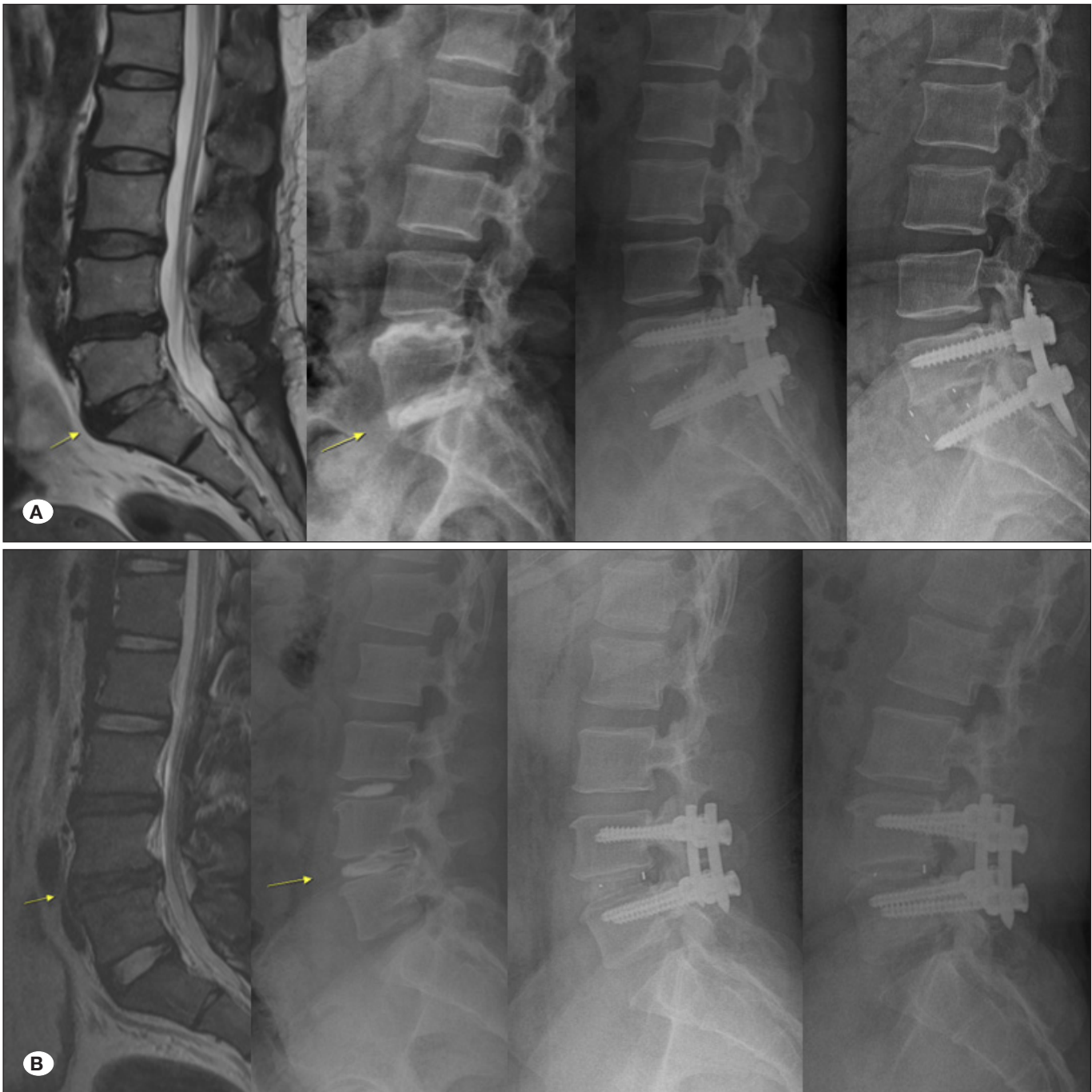

Figure 2: Representative case illustrations. **A)** A 46 years-old female patient with severe low back pain underwent oblique lumbar interbody fusion at the L5–S1 level. Preoperative MRI and discography revealed degenerative disc disease at the L5–S1 level. Immediate postoperative simple radiograph showed significantly increased disc height of the L5–S1 level. Finally, 1-year after surgery, a simple radiograph showed a fused state with maintained disc height of the L5–S1 level. **B)** A 22 years-old male patient with intractable low back pain underwent unilateral transforaminal lumbar interbody fusion at the L4–L5 level. Preoperative MRI and discography revealed degenerative disc disease with endplate sclerosis at the L4–L5 level. Immediate postoperative simple radiograph showed increased disc height of the L4–L5 level. However, 1-year after surgery, a simple radiograph showed slightly decreased disc height of the L4–L5 level.

heterogeneity in surgical indications or diagnoses (19,20). In cases of spondylolisthesis or deformity, both lateral and posterior approaches are valid treatment options. However, if symptomatic central spinal stenosis and/or foraminal stenosis is combined, the lateral approach can be limited in terms of the difficulty of definite decompression of the thecal sac and nerve root. Although the effect of indirect decompression is expected in the lateral approach, surgeons should consider the risk of insufficient decompression or re-compression of the foramen due to subsidence after surgery. Therefore, the choice of the detailed surgical method depends on the exact diagnosis, even for similar diseases. For example, in a study with spondylolisthesis, the choice of surgical technique is decided according to the detailed status of stenosis or nerve root compression rather than by randomized decision, and the bias of patient selection is inevitable.

In contrast, in cases of discogenic LBP due to disc degeneration without significant nerve root compression and radiating leg pain, either the posterior or lateral approach may be used for disc space evacuation and fusion. In this study, the selected surgical indication was discogenic LBP due to disc degeneration without significant radiating leg pain. Among patients selected using this homogeneous surgical indication, we compared the actual clinical, surgical, and radiological outcomes related to the surgical approach without bias in patient selection.

According to clinical outcomes, although the 1-year outcome was not different, immediate LBP, K-ODIs, and patient satisfaction at 1 week or 1-month post-surgery were more favorable in the lateral group than in the posterior group. In terms of minimal clinically significant difference, although the clinical result at 1 week was not significantly different between the two groups, the clinical result at 1 month was significantly more favorable in the lateral group than in the posterior group. We speculated that this finding implies more procedure-related LBP and limitation of daily life in the posterior group within 1-month post-surgery. Erector spine muscle or multifidus muscle injury and violation of the facet joint and ligament complex may cause procedure-related LBP and limited improvement of daily life in the short-term period after surgery (12,15). In contrast, lateral muscle injury, including the external and internal oblique muscles, and the psoas muscle, may cause relatively mild procedure-related LBP.

Surgical outcomes such as operation time and estimated blood loss were favorable in the lateral group, although the duration of hospital stay and complication rate were not significantly different between the groups. Once the approach was achieved via a tubular retractor in the lateral group, disc space evacuation and cage insertion were performed rapidly. This shortened operation time and lower blood loss sufficiently offset the difficulty and unfamiliarity of the surgical technique and the requirement for change in patient position.

Although not statistically significant, the lateral group tended to have more surgery-related complications. In particular, transient hip joint weakness or dysesthesia of the thigh due to psoas muscle injury were not rare after the lateral approach.

However, almost all psoas muscle-related complications were minor and transient and did not affect clinical outcomes at 1 year after surgery. On the other hand, during the lateral approach, particularly during OLIF, careful attention is required to avoid damage to the superior hypogastric plexus or major vessels.

Although radiological outcomes at 1-year post-surgery were comparable, an increase in the disc height, restoration of the segmental angle of the index level, and lumbar lordosis at 1-month post-surgery were more effective in the lateral group than in the posterior group. We speculated that sufficient disc space evacuation, endplate preparation, and insertion of a higher cage with a wider cross-sectional area may have affected this difference. Furthermore, these differences in radiographic results might affect the difference in clinical outcomes at 1 month after surgery. However, the disc height and lordosis were synchronized because of subsidence rebound.

This study has some limitations. It was impossible to control for all variations due to retrospective study design. Parameters related to sagittal balance, including sagittal vertical axis and pelvic incidence, were not evaluated because of data unavailability. Additionally, the sample size of the final cohort was small. Moreover, heterogeneity of the surgical technique may have introduced a bias. However, this study offers a meaningful general comparison of lateral and posterior fusion, and to the best of our knowledge, this is the first research to report such a comparison in patients with discogenic LBP. A prospective study with strictly controlled conditions or comprehensive studies with larger sample size is necessary to confirm our results.

■ CONCLUSION

Although 1-year outcomes after surgery were not different, short-term outcomes were more favorable in the lateral group than in the posterior group in terms of minimized paraspinal muscle injury, feasible disc space evacuation, and sufficient disc height and alignment restoration.

■ ACKNOWLEDGEMENTS

This research was supported by the National Research Foundation of Korea (NRF) grant funded by the Korea government (MSIT) (No.2021M3I2A1077405). The funders had no role in the study design, data collection and analysis, or preparation of the manuscript.

We would like to thank Editage (www.editage.co.kr) for English language editing.

■ AUTHORS' CONTRIBUTIONS

Dr. SS designed the study protocol and took responsibility for the collection of data and the reliability of data analysis. Dr. WKK managed the literature searches and wrote the first draft, and Dr. SS revised the draft of the manuscript. Dr. SGL, JMJ, and BRY reviewed all the contents of this article and approved the manuscript.

■ REFERENCES

1. Aprill C, Bogduk N: High-intensity zone: A diagnostic sign of painful lumbar disc on magnetic resonance imaging. *Br J Radiol* 65:361-369, 1992
2. Benneker LM, Heini PF, Anderson SE, Alini M, Ito K: Correlation of radiographic and MRI parameters to morphological and biochemical assessment of intervertebral disc degeneration. *Eur Spine J* 14:27-35, 2005
3. Carreon LY, Glassman SD, Howard J: Fusion and nonsurgical treatment for symptomatic lumbar degenerative disease: A systematic review of Oswestry Disability Index and MOS Short Form-36 outcomes. *Spine J* 8:747-755, 2008
4. Cummock MD, Vanni S, Levi AD, Yu Y, Wang MY: An analysis of postoperative thigh symptoms after minimally invasive transposas lumbar interbody fusion. *J Neurosurg Spine* 15:11-18, 2011
5. Fujiwara A, Tamai K, Yamato M, An HS, Yoshida H, Saotome K, Kurihashi A: The relationship between facet joint osteoarthritis and disc degeneration of the lumbar spine: An MRI study. *Eur Spine J* 8:396-401, 1999
6. Gibson JN, Waddell G: Surgery for degenerative lumbar spondylosis: Updated Cochrane Review. *Spine (Phila Pa 1976)* 30:2312-2320, 2005
7. Hackenberg L, Halm H, Bullmann V, Vieth V, Schneider M, Liljenqvist U: Transforaminal lumbar interbody fusion: A safe technique with satisfactory three to five year results. *Eur Spine J* 14:551-558, 2005
8. Harms J, Rolinger H: A one-stager procedure in operative treatment of spondylolistheses: Dorsal traction-reposition and anterior fusion (author's transl). *Z Orthop Ihre Grenzgeb* 120:343-347, 1982
9. Hildebrandt M, Fankhauser G, Meichtry A, Luomajoki H: Correlation between lumbar dysfunction and fat infiltration in lumbar multifidus muscles in patients with low back pain. *BMC Musculoskelet Disord* 18(1):12, 2017
10. Houten JK, Alexandre LC, Nasser R, Wollowick AL: Nerve injury during the transposas approach for lumbar fusion. *J Neurosurg Spine* 15:280-284, 2011
11. Houten JK, Post NH, Dryer JW, Errico TJ: Clinical and radiographically/neuroimaging documented outcome in transforaminal lumbar interbody fusion. *Neurosurg Focus* 20:E8, 2006
12. Hu ZJ, Zhang JF, Xu WB, Zhao FD, Wang JY, Fan SW, Fang XQ: Effect of pure muscle retraction on multifidus injury and atrophy after posterior lumbar spine surgery with 24 weeks observation in a rabbit model. *Eur Spine J* 26:210-220, 2017
13. Ibrahim T, Tleyjeh IM, Gabbar O: Surgical versus non-surgical treatment of chronic low back pain: A meta-analysis of randomised trials. *Int Orthop* 32:107-113, 2008
14. Kaiser MG, Eck JC, Groff MW, Ghogawala Z, Watters WC, 3rd, Dailey AT, Resnick DK, Choudhri TF, Sharan A, Wang JC, Dhall SS, Mummaneni PV: Guideline update for the performance of fusion procedures for degenerative disease of the lumbar spine. Part 17: Bone growth stimulators as an adjunct for lumbar fusion. *J Neurosurg Spine* 21:133-139, 2014
15. Kawaguchi Y, Matsui H, Tsuji H: Back muscle injury after posterior lumbar spine surgery. Part 2: Histologic and histochemical analyses in humans. *Spine (Phila Pa 1976)* 19:2598-2602, 1994
16. Kepler CK, Sharma AK, Huang RC, Meredith DS, Girardi FP, Cammisa FP Jr, Sama AA: Indirect foraminal decompression after lateral transposas interbody fusion. *J Neurosurg Spine* 16:329-333, 2012
17. Knight RQ, Schwaegler P, Hanscom D, Roh J: Direct lateral lumbar interbody fusion for degenerative conditions: Early complication profile. *J Spinal Disord Tech* 22:34-37, 2009
18. Le TV, Burkett CJ, Deukmedjian AR, Uribe JS: Postoperative lumbar plexus injury after lumbar retroperitoneal transposas minimally invasive lateral interbody fusion. *Spine (Phila Pa 1976)* 38:E13-20, 2013
19. Lee N, Kim KN, Yi S, Ha Y, Shin DA, Yoon DH, Kim KS: Comparison of outcomes of anterior, posterior, and transforaminal lumbar interbody fusion surgery at a single lumbar level with degenerative spinal disease. *World Neurosurg* 101:216-226, 2017
20. Lee YS, Kim YB, Park SW, Chung C: Comparison of transforaminal lumbar interbody fusion with direct lumbar interbody fusion: Clinical and radiological results. *J Korean Neurosurg Soc* 56:469-474, 2014
21. Lin GX, Akbary K, Kotheeranurak V, Quillo-Olvera J, Jo HJ, Yang XW, Mahatthanatrakul A, Kim JS: Clinical and radiologic outcomes of direct versus indirect decompression with lumbar interbody fusion: A matched-pair comparison analysis. *World Neurosurg* 119:e898-e909, 2018
22. Lin PM, Cautilli RA, Joyce MF: Posterior lumbar interbody fusion. *Clin Orthop Relat Res* 180:154-168, 1983
23. McAfee PC, Boden SD, Brantigan JW, Fraser RD, Kuslich SD, Oxland TR, Panjabi MM, Ray CD, Zdeblick TA: Symposium: A critical discrepancy-a criteria of successful arthrodesis following interbody spinal fusions. *Spine (Phila Pa 1976)* 26:320-334, 2001
24. McAfee PC, Regan JJ, Geis WP, Fedder IL: Minimally invasive anterior retroperitoneal approach to the lumbar spine. Emphasis on the lateral BAK. *Spine (Phila Pa 1976)* 23:1476-1484, 1998
25. Miscusi M, Ramieri A, Forcato S, Giuffrè M, Trungu S, Cimatti M, Pesce A, Familiari P, Piazza A, Carnevali C, Costanzo G, Raco A: Comparison of pure lateral and oblique lateral inter-body fusion for treatment of lumbar degenerative disk disease: A multicentric cohort study. *Eur Spine J* 27:222-228, 2018
26. Mobbs RJ, Phan K, Malham G, Seex K, Rao PJ: Lumbar interbody fusion: Techniques, indications and comparison of interbody fusion options including PLIF, TLIF, MI-TLIF, OLIF/ATP, LLIF and ALIF. *J Spine Surg* 1:2-18, 2015
27. Modic MT, Steinberg PM, Ross JS, Masaryk TJ, Carter JR: Degenerative disk disease: Assessment of changes in vertebral body marrow with MR imaging. *Radiology* 166:193-199, 1988
28. Ni J, Fang X, Zhong W, Liu N, Wood KB: Anterior lumbar interbody fusion for degenerative discogenic low back pain: Evaluation of L4-S1 fusion. *Medicine (Baltimore)* 94:e1851, 2015

29. Noshchenko A, Hoffecker L, Lindley EM, Burger EL, Cain CM, Patel VV: Long-term treatment effects of lumbar arthrodeses in degenerative disk disease: A systematic review with meta-analysis. *J Spinal Disord Tech* 28:E493-521, 2015
30. Ozgur BM, Aryan HE, Pimenta L, Taylor WR: Extreme lateral interbody fusion (XLIF): A novel surgical technique for anterior lumbar interbody fusion. *Spine J* 6:435-443, 2006
31. Pfirrmann CW, Metzdorf A, Zanetti M, Hodler J, Boos N: Magnetic resonance classification of lumbar intervertebral disc degeneration. *Spine* 26:1873-1878, 2001
32. Phan K, Thayaparan GK, Mobbs RJ: Anterior lumbar interbody fusion versus transforaminal lumbar interbody fusion-systematic review and meta-analysis. *Br J Neurosurg* 29:705-711, 2015
33. Potter BK, Freedman BA, Verwiebe EG, Hall JM, Polly DW Jr, Kuklo TR: Transforaminal lumbar interbody fusion: Clinical and radiographic results and complications in 100 consecutive patients. *J Spinal Disord Tech* 18:337-346, 2005
34. Sachs BL, Vanharanta H, Spivey MA, Guyer RD, Videman T, Rashbaum RF, Johnson RG, Hochschuler SH, Mooney V: Dallas discogram description. A new classification of CT/discography in low-back disorders. *Spine* 12:287-294, 1987
35. Schwarzer AC, Aprill CN, Derby R, Fortin J, Kine G, Bogduk N: The prevalence and clinical features of internal disc disruption in patients with chronic low back pain. *Spine* 20:1878-1883, 1995
36. Silvestre C, Mac-Thiong JM, Hilmi R, Roussouly P: Complications and morbidities of mini-open anterior retroperitoneal lumbar interbody fusion: Oblique lumbar interbody fusion in 179 patients. *Asian Spine J* 6:89-97, 2012
37. Son S, Lee SG, Kim WK, Ahn Y, Jung JM: Disc height discrepancy between supine and standing positions as a screening metric for discogenic back pain in patients with disc degeneration. *Spine J* 21:71-79, 2021
38. St Clair S, Tan JS, Lieberman I: Oblique lumbar interbody fixation: A biomechanical study in human spines. *J Spinal Disord Tech* 25:183-189, 2012
39. Teng I, Han J, Phan K, Mobbs R: A meta-analysis comparing ALIF, PLIF, TLIF and LLIF. *J Clin Neurosci* 44:11-17, 2017
40. Verrills P, Nowesenitz G, Barnard A: Prevalence and characteristics of discogenic pain in tertiary practice: 223 consecutive cases utilizing lumbar discography. *Pain Medicine* 16:1490-1499, 2015