



Sagittal Spinal Deformity in Patients with Idiopathic Normal Pressure Hydrocephalus

Karina A. LENARTOWICZ¹, Ryan M. NAYLOR², Anthony L. MIKULA², Jonathan GRAFF-RADFORD³, David T. JONES³, Jeremy K. CUTSFORTH-GREGORY³, Neill R GRAFF-RADFORD⁴, Jeremy L. FOGELSON^{2,5}, Petrice M. COGSWELL⁶, Benjamin D. ELDER^{2,5,7}

¹Mayo Clinic Alix School of Medicine, Mayo Clinic, Rochester, Minnesota, USA

²Mayo Clinic, Department of Neurological Surgery, Rochester, MN, 55905, USA

³Mayo Clinic, Department of Neurology, Rochester, MN, 55905, USA

⁴Mayo Clinic, Department of Neurology, Jacksonville, FL, 32224, USA

⁵Mayo Clinic, Department of Orthopedic Surgery, Rochester, MN, 55905, USA

⁶Mayo Clinic, Department of Radiology, Rochester, MN, 55905, USA

⁷Mayo Clinic, Department of Biomedical Engineering, Rochester, MN, 55905, USA

Corresponding author: Benjamin D. ELDER ✉ elder.benjamin@mayo.edu

ABSTRACT

AIM: Idiopathic normal pressure hydrocephalus (iNPH) is characterized by postural instability, often with a forward leaning posture. However, the presence of concomitant spinal sagittal plane deformity and spinopelvic alignment and have not been studied in this population. The objective of this study was to measure the baseline spinopelvic parameters and characterize the sagittal, and coronal plane deformities in patients with iNPH.

MATERIAL and METHODS: We analyzed a series of patients at one academic institution who underwent ventriculoperitoneal shunting for iNPH with pre-shunt standing full length x-rays. The series of patients was enrolled consecutively to minimize selection bias. We quantified comorbid sagittal plane spinal deformity based on the Scoliosis Research Society-Schwab classification system by assessing pelvic incidence and lumbar lordosis mismatch (PI-LL), pelvic tilt (PT), and sagittal vertical axis (SVA).

RESULTS: Seventeen patients (59% male) were included in this study. Mean (\pm standard deviation) age was 74 ± 5.3 years with a body mass index (BMI) of 30 ± 4.5 kg/m². Six patients (35%) had marked sagittal plane spinal deformity by at least one parameter: five (29%) had greater than 20° PI-LL mismatch, three (18%) had >9.5 cm SVA, and one (6%) had PT greater than 30°. Additionally, the thoracic kyphosis exceeded the lumbar lordosis in nine patients (53%).

CONCLUSION: Positive sagittal balance, with thoracic kyphosis exceeding lumbar lordosis, is common in iNPH patients. This may lead to postural instability, especially in patients whose gait does not improve following shunting. These patients may warrant further investigation and workup, including full length standing x-rays. Future studies should assess for improvement in the sagittal plane parameters following shunt placement.

KEYWORDS: Idiopathic normal pressure hydrocephalus, Adult spinal deformity, Postural instability, Scoliosis Research Society-Schwab classification, Health-related quality of life

ABBREVIATIONS: ASD: Adult spinal deformity, BMI: Body mass index, CSF: Cerebrospinal fluid, cSVA: C2-C7 sagittal vertical axis, iNPH: Idiopathic normal pressure hydrocephalus, LL: Lumbar lordosis, PI: Pelvic incidence, PI-LL: Pelvic incidence minus lumbar lordosis, PT: Pelvic tilt, SRS-Schwab: Scoliosis Research Society – Schwab, SVA: Sagittal vertical axis, TK: Thoracic kyphosis, VP: Ventriculoperitoneal, VPS: Ventriculoperitoneal shunt

Karina A. LENARTOWICZ : 0000-0002-7130-877X
Ryan M. NAYLOR : 0000-0003-3067-1000
Anthony L. MIKULA : 0000-0002-5143-3733
Jonathan GRAFF-RADFORD : 0000-0003-2770-0691
David T. JONES : 0000-0002-4807-9833

Jeremy K. CUTSFORTH-GREGORY : 0000-0002-5689-4424
Neill R GRAFF-RADFORD : 0000-0001-9847-9096
Jeremy L. FOGELSON : 0000-0002-9118-5607
Petrice M. COGSWELL : 0000-0002-8128-4476
Benjamin D. ELDER : 0000-0002-7782-7829

INTRODUCTION

Idiopathic normal pressure hydrocephalus (iNPH) is characterized by the triad of cognitive decline, urinary incontinence and gait disturbance, in the setting of ventriculomegaly without increased cerebrospinal fluid (CSF) pressure (1,20). Gait dysfunction has been reported in 89-100% of patients with iNPH (8,17,27,30,31,33) and is defined as a hypokinetic, broad-based gait with a forward leaning posture (1,5,32). The prevalence of iNPH increases exponentially as the age of the patient increases, with a reported incidence of 0.5 to 5.5 per 100,000 people per year (14,20,22). In the elderly, this postural and gait derangement increases the likelihood of falls, which are associated with high morbidity and mortality (13,19,40). Diversion of CSF via ventriculoperitoneal shunting (VPS) is the mainstay of treatment in patients with iNPH, although up to 15-20% of continue to note gait dysfunction up to 3 years after shunt placement, and patients rarely return to the functional level of healthy controls (14,34).

Adult spinal deformity (ASD) encompasses a broad group of structural abnormalities that are more common in the elderly and lead to global sagittal and coronal imbalance (7,39). Due to increased work required to maintain normal posture and subsequent pain, ASD commonly presents with gait abnormalities and decreased walking endurance (11,21). Similar to iNPH, the prevalence and severity of ASD increases in patients greater than 60 years old, with a reported prevalence in the literature between 32% and 68% (12,25,36). Therefore, both iNPH and ASD may present as a progressive impairment in gait and postural instability in elderly patients. Due to the overlapping features of iNPH and ASD and the relatively high percentage of iNPH patients with persistent gait disturbances after VPS placement, we aim to characterize sagittal and coronal plane deformities for patients with iNPH.

MATERIAL and METHODS

Patients

Approval for this study was obtained from the Mayo Clinic institutional review board (IRB no. 19-000836). Standing, full-length scoliosis x-rays were obtained for a consecutive series of patients from a single institution who underwent ventriculoperitoneal (VP) shunt placement for iNPH by the senior author. Patients were included in the study over an 18-month period from December 1, 2017, to June 30, 2019 to minimize selection bias. Standing full length X-rays consisted of anterior-posterior and lateral full-length radiographs with knees in extension and arms folded in front of the chest. We retrospectively collected basic demographic parameters including the age, sex, and body mass index (BMI) from the electronic medical record.

A board-certified neurologist and neurosurgeon evaluated all patients during workup for iNPH and prior to inclusion in this study. All patients had radiographic evidence of ventriculomegaly as defined by Evans' index >0.3, without evidence of an obstructive etiology. All patients had improvement in their walking following a large volume, 30 mL

lumbar puncture and were noted to have opening pressures less than 25 cm H₂O. Gait velocity was assessed over a ten-meter distance through video recordings of gait which were obtained before and after a lumbar tap test as part of the diagnostic workup.

Imaging Metrics

For each patient the senior author measured the spinopelvic parameters and spinal deformity as outlined by the Scoliosis Research Society-Schwab (SRS-Schwab) ASD classifications system for sagittal balance by measuring the following spinopelvic parameters: pelvic tilt (PT), pelvic incidence (PI), sagittal vertical axis (SVA), and lumbar lordosis (LL) (Figure 1) (37). The lumbar lordosis was measured by the sagittal plane Cobb angle between the superior endplate of L1 and superior aspect of the sacrum. Thoracic kyphosis (TK) was similarly measured between T2 and T12. Global alignment was classified as normal if SVA was less than 4 cm, moderate deformity if greater than 4 cm but less than 9.5 cm, and finally, marked deformity if greater than 9.5 cm. Pelvic tilt was deemed non-pathologic if less than 20°, moderate deformity if greater than 20° but less than 30°, and marked deformity if greater than 30°. Lumbar lordosis was within normal limits if within 10° of PI, moderate deformity if mismatch was between 10° and 20°, and marked deformity if the mismatch was greater than 20°.

Statistical Analysis

The association between gait velocity preceding and following high volume lumbar puncture in patients with and without marked spinal deformity was determined using an unpaired two-tailed student's *t* test. We defined statistical significance as *p*<0.05.

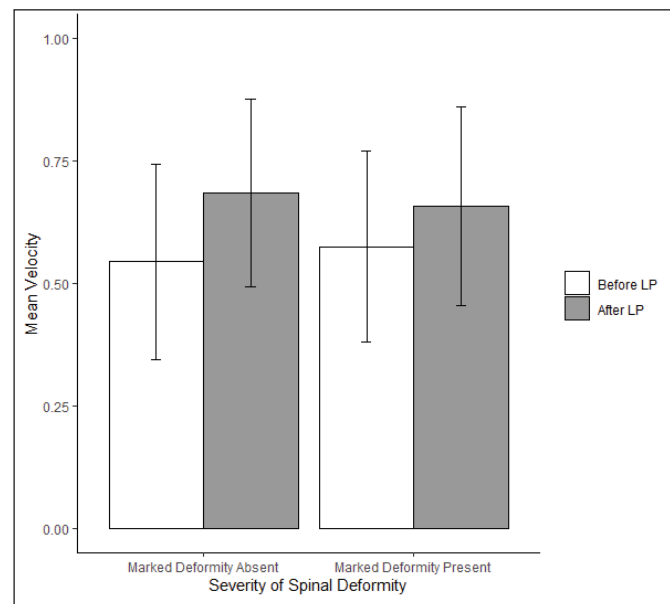


Figure 1: Mean gait velocities before and immediately after a high-volume lumbar puncture in patients with and without marked spinal deformity.

RESULTS

Seventeen patients (ten men, seven women) were identified and subsequently included in the study. The average age was 74 ± 5.3 years, and BMI was 30 ± 4.5 kg/m². Prior surgeries included one lumbar decompression, one hip arthroplasty, and two total knee arthroplasties.

In this cohort, six of 17 (35.3%) patients met at least one radiographic criterion for having marked spinal deformity (Table I). Pelvic tilt was normal in eight patients (47%), moderate deformity in eight patients (47%), and marked deformity in one patient (6%). Sagittal vertical axis was normal in seven patients (41%), moderate deformity in seven patients (41%), and marked deformity in three patients (18%). For PI to LL mismatch, four patients (24%) had measurements within normal limits, eight patients with moderate deformity (47%), and five patients (29%) with marked PI-LL mismatch. Six patients demonstrated marked deformity in at least one parameter, while no patient demonstrated marked deformity in all three parameters. Measurement of TK and LL revealed three patients (18%) in which LL exceeded TK, five patients (30%) in which TK and LL were comparable, and nine patients (53%) where TK exceeded LL (Table II).

Gait analysis was undertaken through analysis of video recordings of patients walking 10 m to determine the gait

velocity before and after high volume lumbar puncture (Figure 1). One patient without marked spinal deformity was unable to walk 10 m prior to undergoing LP. The mean gait (\pm standard deviation) velocity in the remaining patients (n=10) without marked spinal deformity prior to lumbar puncture was 0.54 ± 0.20 m/s and 0.68 ± 0.19 m/s after lumbar puncture (p=0.13). For the six patients with marked spinal deformity the mean gait velocity prior to high volume lumbar puncture was 0.57 ± 0.19 m/s and after high-volume lumbar puncture was 0.65 ± 0.19 m/s (p=0.49).

DISCUSSION

In a cohort of patients with iNPH and forward leaning posture, we found comorbid spinal deformity demonstrating marked deformity in at least one radiographic parameter as defined by the SRS-Schwab Deformity Classification (37). Deformity in any of these parameters is highly associated with reduced Health-Related Quality of Life Scores (HRQoL), as well as pain and disability in the elderly population (28). Such deformities may impact functional outcomes following shunt placement for iNPH. In our cohort, 6% of patients demonstrated marked PT, 18% of patients had marked global sagittal imbalance defined by SVA, and 30% of patients demonstrated a high degree of PI-LL mismatch. Thoracic kyphosis exceeded lumbar lordosis in 53% of patients. No significant coronal plane, cervical plane, or cervicothoracic sagittal plane deformities were observed in our cohort. Finally, mild pelvic obliquity was observed in our cohort with a mean pelvic obliquity of $2.3 \pm 1.9^\circ$.

Positive sagittal imbalance, anterior deviation of the C7 plumb line measurement, is highly correlated with Health-Related Quality of Life Scores (28), and successful surgical treatment with corrective surgery (6,15,16,26,41). Current literature reports an increasing incidence of ASD in patients greater than 60 years of age (42) and in the majority of patients who undergo surgery for ASD are older than 65 years of age (2,9). The incidence of ASD is poorly defined in the literature, however, previous studies report the prevalence of asymptomatic adult scoliosis between 1.4% and 32% (12,18,42), and in those aged 60 years or older as high as 68% (36). These data represent a deformity in the coronal plane with a Cobb exceeding 10°, while the prevalence of marked sagittal plane spinal deformities is likely far lower. A study by Schwab et al. demonstrated that 24% of healthy patients greater than the age of 60 years had a Cobb angle higher than 20° (36), while a further study of 2973 patients over 40 years of age reported only 57 patients (1.9%) with moderate or marked sagittal spinal deformity with an angle greater than 24.50° (25). Further research is warranted to truly understand the prevalence of marked sagittal spinal deformity in the elderly population and in patients with NPH. Due to the disagreement in previous reports and paucity of large studies of the prevalence of ASD, it is difficult to make direct comparisons. We observed a high rate of thoracic hyper-kyphosis in our cohort, with 53% of our patients having a thoracic kyphosis exceeding lumbar lordosis, compared to the prevalence of hyper-kyphosis of 20-40% in prior reports (23,24,35). While larger scale studies are warranted to

Table I: Spinal Deformity Parameters in Patients with iNPH

| | Number of Patients (%) |
|--------------|------------------------|
| PT | |
| < 20° | 8 (47) |
| 20-30° | 8 (47) |
| > 30° | 1 (6) |
| SVA | |
| < 4 cm | 7 (41) |
| 4-9.5 cm | 7 (41) |
| > 9.5 cm | 3 (18) |
| PI-LL | |
| < 10° | 4 (24) |
| 10-20° | 8 (47) |
| > 20° | 5 (29) |

iNPH: Idiopathic normal pressure hydrocephalus, **PT:** Pelvic tilt, **SVA:** Sagittal vertical axis, **PI-LL:** Pelvic incidence minus lumbar lordosis.

Table II: Relationship Between TK and LL in Patients with iNPH

| | Number of Patients (%) |
|---------|------------------------|
| TK < LL | 3 (18) |
| TK = LL | 5 (29) |
| TK > LL | 9 (53) |

iNPH: Idiopathic normal pressure hydrocephalus, **TK:** Thoracic kyphosis, **LL:** Lumbar lordosis.

fully understand the true incidence of both symptomatic and asymptomatic ASD in the elderly population, we observed a high rate of marked spinal deformity and thoracic kyphosis exceeding lumbar lordosis in patients with comorbid iNPH.

Unlike the management of adolescent and child spinal deformities, for which the degree of radiographic deformity dictates treatment, the management of ASD is primarily driven by the degree of functional impact, pain, and disability (3). Basic measurements that can help guide treatment include LL, PI, PT, and SVA. Gait analysis is an additional tool to assess functional impact of iNPH and spinal deformity. In our study, there was no significant difference between gait velocities before lumbar puncture and after lumbar puncture in patients with marked ASD and those patients without spinal deformity, although this is likely due to the small sample size. However, in patients with marked spinal deformity, we observed a blunted response to LP when compared to the patients without marked deformity. Further studies with a larger population are warranted to understand this observation. Based on these results, iNPH patients who fail VPS treatment and demonstrate a potential sagittal plane deformity on physical examination should be considered for workup and possible treatment for adult spinal deformity. It should be noted that none of the patients in this series went on to have a major reconstructive spinal surgery.

In addition to assessing sagittal plane deformity, we assessed the for a correlation between lumbar lordosis and thoracic kyphosis in our cohort. More than half of the patients with iNPH had a thoracic kyphosis that exceeded their lumbar lordosis. The impact of this deformity can be understood through Dubousset's "cone of economy", which describes the range of spinal alignments needed to minimize energy expenditure in order to maintain an upright posture or to ambulate (10). Positioning towards the outside edge of this cone results in increased positive balance and therefore increased energy utilization, which, over time, may lead to pain, fatigue, and disability (38). Positioning outside of the cone necessitates the use of an external support such as a cane or walker. Biomechanical analysis of gait and posture in patients with iNPH demonstrates decreased postural stability and increased sway in this patient population, which is associated with a component of the gait dysfunction encountered in this disorder (4,29,43). Gait analysis has further defined iNPH by a triad of reduced stride length, decreased foot-to-floor clearance, and a broad-based gait (44). Based on our results indicating that thoracic kyphosis exceeds the lumbar lordosis in the majority of iNPH patients, the forward leaning posture commonly observed in iNPH may be due in part to the thoracolumbar kyphosis. Surgical interventions in patients with comorbid severe deformity or unresponsive to shunting in iNPH, should, therefore, address the need to return patients to the "cone of economy", through analysis and correction of underlying thoracic hyper-kyphosis.

This study has some limitations. Most significantly are the retrospective methodology and small sample size. Additionally, this is a series from a single surgeon from one academic institution which may limit the generalizability of

this study to general clinical practice, though we obtained x-rays consecutively to minimize selection bias. Due to our methodology, it remains unclear whether these findings represent random chance, true correlation between ASD and iNPH, or a more complicated causal relationship between these two pathologies. As this was a purely descriptive study, biomechanical analysis of gait and balance were not undertaken. We also did not determine whether these patients had symptomatic or asymptomatic adult spinal deformity. Further studies that assess health-related quality of life measures, pre-operative symptom burden, surgical interventions, and follow-up after shunt placement are warranted. Additionally, it would be important to determine if the degree of deformity is reversible following shunt placement. This would allow a more complete assessment of the clinical impact of ASD on patients with iNPH and provide information regarding the interplay between VP shunt placement and the spinopelvic parameters of ASD. Considering these limitations, detailed prospective assessment of these concomitant pathologies is warranted in further studies.

■ CONCLUSION

Comorbid, marked spinal deformity may be present in patients with iNPH, which may compound the forward leaning posture, postural instability, and gait dysfunction of iNPH. Obtaining full length standing x-rays should be considered in the iNPH population when there is suspicion for concomitant underlying spinal pathology. Future studies are required to better define the relationship between these two pathologies.

AUTHORSHIP CONTRIBUTION

Study conception and design: RMN, ALM, BDE

Data collection: KAL, RMN, ALM, BDE

Analysis and interpretation of results: KAL, RMN, ALM, JGR, DTJ, JKCG, NRGR, JLF, PMC, BDE

Draft manuscript preparation: KAL, RMN, ALM

Critical revision of the article: JGR, DTJ, JKCG, NRGR, JLF, BDE

Other (study supervision, fundings, materials, etc.): BDE

All authors (KAL, RMN, ALM, JGR, DTJ, JKCG, NRGR, JLF, PMC, BDE) reviewed the results and approved the final version of the manuscript.

■ REFERENCES

1. Adams R, Fisher C, Hakim S, Ojemann R, Sweet W: Symptomatic occult hydrocephalus with normal cerebrospinal-fluid pressure: A treatable syndrome. *New England J Med* 273:117-126, 1965
2. Andersson G: The burden of musculoskeletal diseases in the United States: Prevalence, societal and economic cost. *Amer Academy of Orthopaedic*, 2008
3. Bess S, Boachie-Adjei O, Burton D, Cunningham M, Shaffrey C, Shelokov A, Hostin R, Schwab F, Wood K, Akbarnia B: Pain and disability determine treatment modality for older patients with adult scoliosis, while deformity guides treatment for younger patients. *Spine* 34:2186-2190, 2009

4. Blomsterwall E, Svantesson U, Carlsson U, Tullberg M, Wikkelsö C: Postural disturbance in patients with normal pressure hydrocephalus. *Acta Neurol Scand* 102:284-291, 2000
5. Bugalho P, Guimarães J: Gait disturbance in normal pressure hydrocephalus: A clinical study. *Parkinsonism Relat Disord* 13:434-437, 2007
6. Cho KJ, Suk SI, Park SR, Kim JH, Kang SB, Kim HS, Oh SJ: Risk factors of sagittal decompensation after long posterior instrumentation and fusion for degenerative lumbar scoliosis. *Spine* 35:1595-1601, 2010
7. Cobb J: Outline for study of scoliosis. *Instruct Course Lect* 5: 261-275, 1948
8. Damasceno BP, Carelli EF, Honorato DC, Facure JJ: The predictive value of cerebrospinal fluid tap-test in normal pressure hydrocephalus. *Arq Neuropsiquiatr* 55:179-185, 1997
9. Drazin D, Shirzadi A, Rosner J, Eboli P, Safee M, Baron EM, Liu JC, Acosta FL: Complications and outcomes after spinal deformity surgery in the elderly: Review of the existing literature and future directions. *Neurosurg Focus* 31:E3, 2011
10. Dubousset J: Three-dimensional analysis of the scoliotic deformity. In: Weinstein SL (ed), *The Pediatric Spine: Principles and Practice*. Raven Press, 1994
11. Engsberg JR, Bridwell KH, Reitenbach AK, Urich ML, Baldus C, Blanke K, Lenke LG: Preoperative gait comparisons between adults undergoing long spinal deformity fusion surgery (thoracic to L4, L5, or sacrum) and controls. *Spine* 26:2020-2028, 2001
12. Francis RS: Scoliosis screening of 3,000 college-aged women: The Utah Study—phase 2. *Phys Ther* 68:1513-1516, 1988
13. Fuller GF: Falls in the elderly. *Am Fam Physician* 61:2159-2168, 2000
14. Giordan E, Palandri G, Lanzino G, Murad MH, Elder BD: Outcomes and complications of different surgical treatments for idiopathic normal pressure hydrocephalus: A systematic review and meta-analysis. *J Neurosurg* 131:1024-1036, 2018
15. Glassman SD, Berven S, Bridwell K, Horton W, Dimar JR: Correlation of radiographic parameters and clinical symptoms in adult scoliosis. *Spine* 30:682-688, 2005
16. Glassman SD, Bridwell K, Dimar JR, Horton W, Berven S, Schwab F: The impact of positive sagittal balance in adult spinal deformity. *Spine* 30:2024-2029, 2005
17. Graff-Radford NR, Godersky JC: Normal pressure hydrocephalus. The onset of gait abnormality before dementia predicts a good surgical outcome. *Arch Neurol* 43(9):940-942, 1986
18. Grevitt M, Khazim R, Webb J, Mulholland R, Shepperd J: The short form-36 health survey questionnaire in spine surgery. *J Bone Joint Surg* 79:48-52, 1997
19. Gryfe CI, Amies A, Ashley MJ: A longitudinal study of falls in an elderly population: I. Incidence and morbidity. *Age Ageing* 6:201-210, 1977
20. Hakim S, Adams RD: The special clinical problem of symptomatic hydrocephalus with normal cerebrospinal fluid pressure. Observations on cerebrospinal fluid hydrodynamics. *J Neurol Sci* 2:307-327, 1965
21. Imagama S, Ito Z, Wakao N, Seki T, Hirano K, Muramoto A, Sakai Y, Matsuyama Y, Hamajima N, Ishiguro N: Influence of spinal sagittal alignment, body balance, muscle strength, and physical ability on falling of middle-aged and elderly males. *Eur Spine J* 22:1346-1353, 2013
22. Jaraj D, Rabiei K, Marlow T, Jensen C, Skoog I, Wikkelsø C: Prevalence of idiopathic normal-pressure hydrocephalus. *Neurology* 82:1449-1454, 2014
23. Kado DM, Huang MH, Karlamangla AS, Barrett-Connor E, Greendale GA: Hyperkyphotic posture predicts mortality in older community-dwelling men and women: A prospective study. *J Am Geriatr Soc* 52:1662-1667, 2004
24. Kado DM, Prenovost K, Crandall C: Narrative review: Hyperkyphosis in older persons. *Ann Intern Med* 147:330-338, 2007
25. Kebaish KM, Neubauer PR, Voros GD, Khoshnevisan MA, Skolasky RL: Scoliosis in adults aged forty years and older: prevalence and relationship to age, race, and gender. *Spine* 36:731-736, 2011
26. Kim YJ, Bridwell KH, Lenke LG, Rhim S, Cheh G: An analysis of sagittal spinal alignment following long adult lumbar instrumentation and fusion to L5 or S1: Can we predict ideal lumbar lordosis? *Spine* 31:2343-2352, 2006
27. Krauss JK, Droste DW, Vach W, Jens P R, Orszagh M, Borremans JJ, Tietz A, Seeger W: Cerebrospinal fluid shunting in idiopathic normal-pressure hydrocephalus of the elderly: effect of periventricular and deep white matter lesions. *Neurosurgery* 39:292-300, 1996
28. Lafage V, Schwab F, Patel A, Hawkinson N, Farcy JP: Pelvic tilt and truncal inclination: Two key radiographic parameters in the setting of adults with spinal deformity. *Spine* 34:E599-E606, 2009
29. Lundin F, Ledin T, Wikkelsø C, Leijon G: Postural function in idiopathic normal pressure hydrocephalus before and after shunt surgery: A controlled study using computerized dynamic posturography (EquiTest). *Clin Neurol Neurosurg* 115:1626-1631, 2013
30. Malm J, Kristensen B, Karlsson T, Fagerlund M, Elfverson J, Ekstedt J: The predictive value of cerebrospinal fluid dynamic tests in patients with the idiopathic adult hydrocephalus syndrome. *Arch Neurol* 52:783-789, 1995
31. Meier U, Zeilinger F, Kintzel D: Signs, symptoms and course of normal pressure hydrocephalus in comparison with cerebral atrophy. *Acta Neurochir* 141:1039-1048, 1999
32. Nikaido Y, Akisue T, Kajimoto Y, Tucker A, Kawami Y, Urakami H, Iwai Y, Sato H, Nishiguchi T, Hinoshita T: Postural instability differences between idiopathic normal pressure hydrocephalus and Parkinson's disease. *Clin Neurol Neurosurg* 165:103-107, 2018
33. Petersen RC, Mokri B, Laws ER: Surgical treatment of idiopathic hydrocephalus in elderly patients. *Neurology* 35:307-307, 1985
34. Pujari S, Kharkar S, Metellus P, Shuck J, Williams MA, Rigamonti D: Normal pressure hydrocephalus: Long-term outcome after shunt surgery. *J Neurol Neurosurg Psychiatry* 79:1282-1286, 2008

35. Ryan SD, Fried LP: The impact of kyphosis on daily functioning. *J Am Geriatr Soc* 45:1479-1486, 1997
36. Schwab F, Dubey A, Gamez L, El Fegoun AB, Hwang K, Pagala M, Farcy J-P: Adult scoliosis: Prevalence, SF-36, and nutritional parameters in an elderly volunteer population. *Spine* 30:1082-1085, 2005
37. Schwab F, Ungar B, Blondel B, Buchowski J, Coe J, Deinlein D, DeWald C, Mehdian H, Shaffrey C, Tribus C: Scoliosis Research Society—Schwab adult spinal deformity classification: A validation study. *Spine* 37:1077-1082, 2012
38. Schwab FJ, Blondel B, Bess S, Hostin R, Shaffrey CI, Smith JS, Boachie-Adjei O, Burton DC, Akbarnia BA, Mundis GM: Radiographical spinopelvic parameters and disability in the setting of adult spinal deformity: A prospective multicenter analysis. *Spine* 38:E803-E812, 2013
39. Silva FE, Lenke LG: Adult degenerative scoliosis: Evaluation and management. *Neurosurg Focus* 28:E1, 2010
40. Siracuse JJ, Odell DD, Gondek SP, Odom SR, Kasper EM, Hauser CJ, Moorman DW: Health care and socioeconomic impact of falls in the elderly. *Am J Surg* 203:335-338, 2012
41. Smith JS, Bess S, Shaffrey CI, Burton DC, Hart RA, Hostin R, Klineberg E, Group ISS: Dynamic changes of the pelvis and spine are key to predicting postoperative sagittal alignment after pedicle subtraction osteotomy: A critical analysis of preoperative planning techniques. *Spine* 37:845-853, 2012
42. Smith JS, Shaffrey CI, Glassman SD, Berven SH, Schwab FJ, Hamill CL, Horton WC, Ondra SL, Sansur CA, Bridwell KH: Risk-benefit assessment of surgery for adult scoliosis: An analysis based on patient age. *Spine* 36:817-824, 2011
43. Soelberg SP, Jansen E, Gjerris F: Motor disturbances in normal-pressure hydrocephalus. Special reference to stance and gait. *Arch Neurol* 43:34, 1986
44. Stolze H, Kuhtz-Buschbeck JP, Drücke H, Jöhnk K, Illert M, Deuschl G: Comparative analysis of the gait disorder of normal pressure hydrocephalus and Parkinson's disease. *J Neurol Neurosurg Psychiatry* 70:289-297, 2001