Turk Neurosurg, 2022

Original Investigation

DOI: 10.5137/1019-5149.JTN.37286-21.2

Received: 04.12.2021
Accepted: 14.02.2022

Published Online: 08.08.2022

# Experimental Investigation of the Secondary Changes in Imaging After Lumbar Disc Nucleoplasty in Rabbits

Haidong YIN[1,2], Xinmei ZHANG[3], Zhiping HUANG[1], Xiuhua WU[1], Qingan ZHU[1]

[1]Southern Medical University, Nanfang Hospital, Department of Spinal Surgery, Guangzhou, Guangdong Province, China
[2]Panyu Hospital of Chinese Medicine, Department of Orthopaedics, Guangzhou, Guangdong Province, China
[3]Southern Medical University, Shunde Hospital, Department of Cardiovascular Medicine, Foshan, Guangdong Province, China

**Corresponding author:** Qingan ZHU ✉ qinganzhu@gmail.com

## ABSTRACT

**AIM:** To explore the changes in imaging after lumbar disc nucleoplasty in rabbits.

**MATERIAL and METHODS:** Twenty-four rabbits were randomly selected for X-ray, computerized tomography (CT), and magnetic resonance imaging (MRI) at 2, 6, and 12 weeks post operation. Moreover, their L3/4, L4/5, and L5/6 intervertebral discs were randomly selected as the untreated, annulus puncture, and nucleoplasty groups, respectively. Changes in disc height index (DHI%) and MRI grade were measured and compared. CT three-dimensional reconstruction was used to evaluate adjacent bone endplate changes.

**RESULTS:** The untreated group's DHI% decreased slightly at different time points ($p>0.05$), while that of the nucleoplasty and annulus puncture groups decreased progressively ($p<0.05$). At six weeks post operation, the nucleoplasty group's DHI% was significantly lower than that of the annulus puncture group ($p<0.05$), with mild osteosclerosis and local rough changes in the endplate. At 12 weeks post operation, a "bone bridge" connection was observed in the nucleoplasty group. There was no significant difference in MRI grade between the untreated and annulus puncture groups at different time points ($p>0.05$). MRI grades of the intervertebral disc in the nucleoplasty and annulus puncture groups showed a progressive increase ($p<0.05$). Compared with the annulus puncture at the same time point, the nucleoplasty group's MRI grade of the intervertebral disc was significantly higher ($p<0.05$). Thus, damage caused by an annulus puncture can lead to progressive degeneration of the lumbar disc.

**CONCLUSION:** Nucleoplasty may have a cumulative effect with the injury of the annulus puncture. Clinicians need to comprehensively consider advantages and disadvantages of nucleoplasty, strictly grasp indications of treatment, and prevent long-term complications.

**KEYWORDS:** Nucleoplasty, Complications, Lumbar disc, X-ray

**ABBREVIATIONS: CT:** Computerized tomography, **DHI:** Disc height index, **IVDD:** Intervertebral disc degeneration, **MRI:** Magnetic resonance imaging

## INTRODUCTION

Diseases caused by intervertebral disc degeneration (IVDD) are commonly called degenerative diseases of the intervertebral disc, including a series of common clinical diseases such as cervical spondylosis and lumbar disc herniation (4,6). In 1934, Mixter and Barr were the first to successfully report the use of discectomy to treat IVDD (5). Since then, discectomy has been widely applied and has

Haidong YIN : 0000-0001-7695-3527
Xinmei ZHANG : 0000-0002-5476-2217
Zhiping HUANG : 0000-0001-5515-0258
Xiuhua WU : 0000-0003-4306-6141
Qingan ZHU : 0000-0002-1131-8298

become the main method to treat degenerative disc disease in clinical practice (23). However, the recurrence rate of the disease is high, the cause of which is not yet clear.

In July 2000, percutaneous disc nucleoplasty was first used in the United States to treat lumbar disc herniation (7); later, it was gradually popularized and applied in many hospitals (10,17,21). Because the operation of percutaneous disc nucleoplasty is performed through the fiber ring puncture channel, it is difficult to determine whether it may lead to aggravation of degenerative disc changes in the long-term. Very few basic studies have reported the above issues in the literature (1,16). However, the method of annulus puncture could simulate the posterior discectomy of nucleus pulposus (15) as well as demonstrate the imaging and histopathological changes after aspiration of the nucleus pulposus of the lumbar disc (8).

Therefore, this study aimed to explore the secondary changes in imaging after percutaneous disc nucleoplasty in rabbits through randomized controlled animal experiments. This study's results can provide important reference for the clinical selection of treatment plans for degenerative diseases of the intervertebral disc.

## MATERIAL and METHODS

### Laboratory Animals and Equipment

A total of 24 healthy four-month-old female New Zealand white rabbits, weighing 2.3 ± 0.3 kg, were used in this study. Before the experiment, all rabbits were examined using X-ray and magnetic resonance imaging (MRI) to confirm that there was no abnormality in the lumbar vertebrae and intervertebral disc. The rabbits were kept in a single cage for one week under standard conditions.

The 19G trocar puncture needle, nucleus pulposus working electrode, and orthopedic cryoplasma operation system were all provided by Arthrocare (Figure 1A). The imaging equipment mainly included the 3.0T MRI scanner (Siemens, Germany), 128 slice spiral computerized tomography (CT) scanner (Toshiba, Japan), Dr machine (Tsushima, Japan), and C-arm X-ray machine (Philippe, Netherlands).

The experimental protocol was reviewed and approved by the Experimental Animal Ethics Committee of Southern Medical University.

### Experimental Grouping

The rabbits were fasted for 8 h before the operation and then weighed to calculate the amount of anesthetic. The rabbits were anesthetized by injecting zolazepam hydrochloride (France Vick Co., Ltd.) at a dosage of 5 mg/kg in their ear edge vein. After the pain reaction disappeared, the researchers moved the rabbits into the prone position, fixed the limbs, prepared the skin, disinfected them, and spread the towel on the left lumbar back (Figure 1B). C-arm X-ray fluoroscopy was used to locate the lumbar intervertebral space. The L3/4, L4/5, and L5/6 intervertebral discs of the 24 experimental rabbits were randomly assigned as to the untreated, annulus puncture, and nucleoplasty groups (Figure 2).

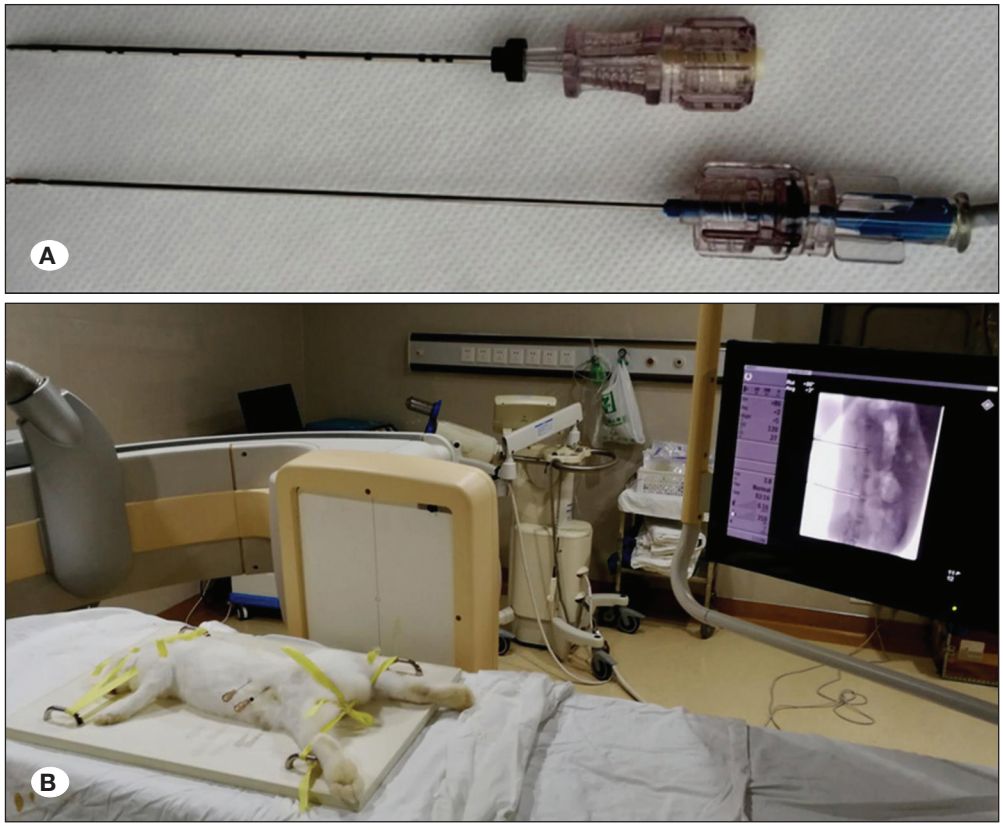


**Figure 1:** Equipment and operation. **A)** 19G trocar needle (upper) and nucleoplasty electrode (lower). **B)** Rabbit fixation for the operation. L3/4 for the annulus puncture, L4/5 for the untreated operation, and L5/6 for nucleoplasty.

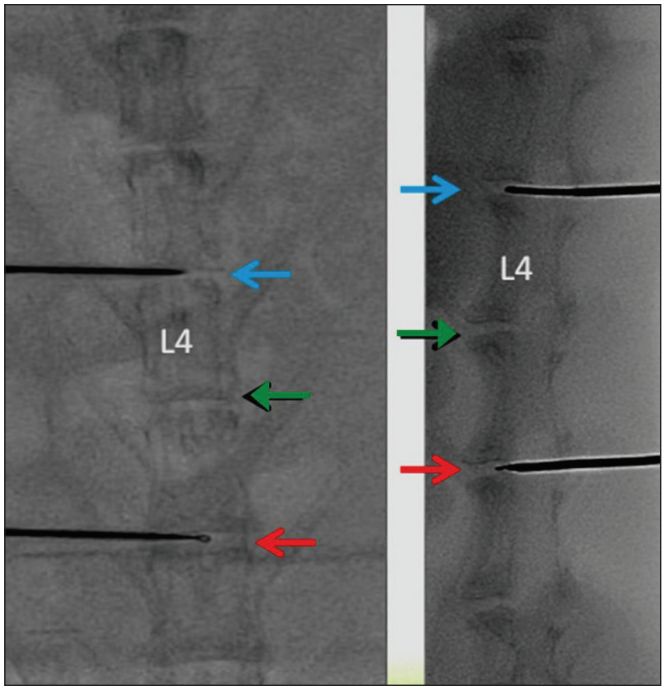


**Figure 2:** Anterolateral fluoroscopy during the operations. L3/4 annulus puncture is represented by blue arrows, L4/5 untreated operation is represented by green arrows, and L5/6 nucleoplasty is represented by red arrows.

### Operative Strategies

#### *Annulus puncture*

The central line of the horizontal left side of the target intervertebral space was about 4–6 cm from the needle entry point. The puncture needle directly penetrated the skin at the needle entry point with a 19G casing needle. The angle between the puncture needle and the horizontal plane ranged from 0° to 10°, and the puncture needle was inserted into the targeting intervertebral disc under the guidance of X-ray (puncture depth was about 5 mm). The perspective in the positive and lateral positions confirms that the puncture needle tips were all located in the middle of the intervertebral disc. The puncture needle remained in the intervertebral disc for 20 s or under; then, the puncture needle was pulled out, and sterile dressing was used to cover the puncture hole.

#### *Nucleoplasty*

During the operation, fluoroscopy confirmed that the tips of the trocar puncture needle were all located in the middle of the intervertebral disc. Then, the inner core of the trocar needle was pulled out, and the nucleus pulposus forming electrode connected with the plasma operation system was placed into the target intervertebral disc along the trocar. The tip of the electrode was located in the center of nucleus pulposus to the opposite side (the puncture depth was 6–7 mm). The energy level of the plasma host was set to level 2. If the nerve reflex of the lower limb was induced by thermal coagulation for one second, the position of the working electrode needed to be readjusted. If the nerve reflex of the lower limb was not induced, the ablation thermal coagulation operation was carried out. First, the ablation and thermocoagulation were performed for 5 s and 180 degrees, respectively. Then, the tip of the electrode retreated 2–3 mm, and the ablation and thermocoagulation were repeated again near the inner layer of the fibrous ring near the puncture site. After all operations, the working electrode and puncture needle were pulled out, and a sterile dressing covered the puncture hole after disinfection.

At the end of the above experiments, all rabbits were put back into the cage for routine feeding without antibiotics. Eight rabbits were randomly selected at 2, 6, and 12 weeks after the operation. Finally, X-ray, CT, and MRI scans of the lumbar spine were performed after anesthesia.

### Observation Indexes

#### *General situation*

The survival, mental state, limb mobility, and defecation of the experimental rabbits were observed after the operation.

#### *X-ray and CT*

The target disc height was evaluated using the disc height index (DHI) according to a previous study (20). The DHI was calculated as follows:

$$DHI\% = (postoperative\ DHI\ /\ preoperative\ DHI) \times 100\%.$$

According to the three-dimensional reconstruction of the CT sagittal plane, changes in the adjacent endplates and osteophytes at the edge of the vertebral body were evaluated.

The sagittal T2 scanning parameters of the MRI are listed as follows: repetition time/echo time 3,500/100 ms, Fov12, layer thickness 2.5 mm, and interval 0 mm. According to the changes in signal intensity and the area of lumbar disc on the T2 weighted image, we could judge whether there is degeneration or not. According to the improved Thompson standard (20), the MRI grades of the intervertebral disc were divided into four: grade I (normal), grade II (signal intensity slightly weakened but with the high signal area significantly reduced), grade III (signal intensity moderately weakened), and grade IV (signal intensity significantly weakened).

### Statistical Analysis

Data were analyzed using SPSS 21.0 software (IBM Corp., Armonk, NY, USA). DHI% was analyzed using the one-way analysis of variance. MRI grades of the intervertebral disc was analyzed using the Friedman test. If the difference was statistically significant, multiple comparisons between groups were conducted. The significant difference was assigned as $p<0.05$.

## RESULTS

### General Conditions of the Rabbits Pre- and Post-Operations

In the whole processes of experimentation, all the rabbits survived. On the second day after the operations, their mental

state, limb mobility, and defecation all recovered to the status at the preoperative period.

### Nucleoplasty Operation Reduced the DHI Values

The lateral X-ray and CT showed that DHI% values of the nucleoplasty and annulus puncture groups demonstrated a progressive downward trend at 2, 6, and 12 weeks post operation, illustrating a significant difference. The DHI% values of the untreated group showed a slight downward trend, but without significant differences. Compared with the untreated group at the same time point, DHI% values of the nucleoplasty and annulus puncture groups decreased significantly. At six weeks after the operations, DHI% values of the nucleoplasty group were significantly lower compared with those of the annulus puncture group, but without significant differences between the two groups at other time points. See Table I ($p>0.05$) for detailed results.

### Lumbar Lateral X-ray and CT Findings

At 2, 6, and 12 weeks after the operations, height of the intervertebral space in the untreated group was equal to that prior to the operations, demonstrating no formation of osteosclerosis or osteophyte in the endplate (Figures 3–5A and 3–5B). In the nucleoplasty and annulus puncture groups, height of the intervertebral space decreased slightly at two weeks after the operations, but without sclerosis and osteophyte formation in the adjacent vertebral endplates (Figures 3–5A and 3–5B). At six weeks after the operations, height of the intervertebral space in the nucleoplasty group decreased significantly, and it showed slight osteosclerosis and local rough change in the endplate. At six weeks after the operations, height of the intervertebral space in the annulus puncture group also decreased significantly, but without obvious endplate sclerosis and osteophyte hyperplasia. At 12 weeks after the operations, height of the intervertebral space in the nucleoplasty and annulus puncture groups continued to decline (Figures 3–5A and 3–5B). The adjacent endplates showed osteosclerosis, and osteophyte hyperplasia was obvious. Moreover, the connection of the anterior "bone bridge" could be observed in the nucleoplasty group.

### Nucleoplasty Operation Enhanced MRI Grades of the Intervertebral Disc

There were no significant differences in MRI grades at different time points in the untreated group. MRI grades of the intervertebral disc in the annulus puncture and nucleoplasty groups at different time points (improved Thompson standard) increased gradually with significant differences. Compared

**Table I:** Percentages for the DHI of Intervertebral Disc in Each Group at Different Time Points Post the Operation

| Groups | 2 weeks | 6 weeks | 12 weeks |
|---|---|---|---|
| Nucleoplasty group (%) | 85.45 ± 3.32* | 52.18 ± 4.69*,# | 41.64 ± 5.06* |
| Untreated group (%) | 97.24 ± 2.10 | 95.67 ± 3.33 | 94.75 ± 4.11 |
| Annulus puncture group (%) | 86.92 ± 3.77* | 62.44 ± 5.78* | 43.75 ± 4.27* |

**p<0.05 vs. Untreated group at the same time points. #p<0.05 vs. Annulus puncture group at the same time points.*

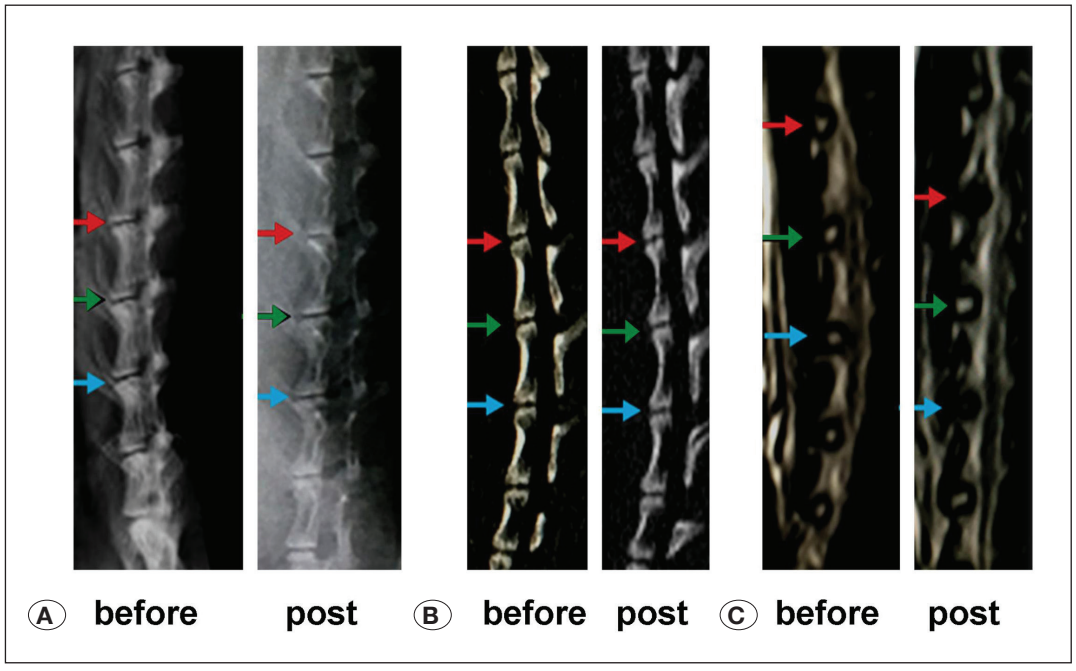


**Figure 3:** Comparison of the preoperative and postoperative X-day, computerized tomography (CT), and magnetic resonance imaging (MRI) at two weeks. **A)** X-ray before/post operation. **B)** CT before/post operation. **C)** MRI before/post operation. L3/4 annulus puncture: blue arrows, L4/5 untreated operation: green arrows, and L5/6 nucleoplasty: red arrows.

with the untreated group at the same time point, MRI grades of the intervertebral disc in the nucleoplasty and annulus puncture groups were significantly higher. Compared with the annulus puncture group at the same time point, MRI grades of the intervertebral disc in the nucleoplasty group was significantly higher. See Table II ($p<0.05$) for more details on these findings.

### Lumbar MRI Findings

At 2, 6, and 12 weeks after the operations, the signal intensity and area of intervertebral disc in the untreated group were not changed significantly compared with those prior to the operations (Figures 3C and 4C; $p>0.05$).

According to Figures 3C and 4C, in the annulus puncture group, there were still some bright signals at two and six weeks after the operation, but the signal intensity and area were significantly reduced compared with those before the operations (Table II; $p<0.05$). Meanwhile, the boundary between the nucleus pulposus and annulus fibrosus was still clear. At 12 weeks after the operations, the signal intensity decreased significantly, and the intervertebral disc lost its normal shape. The nucleus pulposus showed stratified changes, and the boundary between the nucleus pulposus and the annulus fibrosus was unclear (Figure 5C).

In the nucleoplasty group, signal intensity of the disc was significantly weakened from two weeks after the operations, and the boundary between the nucleus pulposus and annulus fibrosus was slightly blurred (Figure 3C). At six weeks after the operations, the shape of the disc began to change, and some of the nucleus pulposus protruded into the spinal canal (Figure 4C). The disc degeneration and protrusion increased significantly 12 weeks after the operations (Figure 5C).

## DISCUSSION

IVDD is a long and complex process, involving natural, environmental, and other factors. However, the exact etiology and pathophysiological mechanism of IVDD have

**Table II:** MRI Grading of Intervertebral Disc at Different Time Points Post the Operation

| Thompson grading | Nucleoplasty group*,# | | | Untreated group | | | Annulus puncture group* | | |
|---|---|---|---|---|---|---|---|---|---|
| | 2 weeks | 6 weeks | 12 weeks | 2 weeks | 6 weeks | 12 weeks | 2 weeks | 6 weeks | 12 weeks |
| I | 0 | 0 | 0 | 8 | 7 | 6 | 0 | 0 | 0 |
| II | 2 | 0 | 0 | 0 | 1 | 2 | 7 | 2 | 0 |
| III | 5 | 5 | 1 | 0 | 0 | 0 | 1 | 6 | 4 |
| IV | 1 | 3 | 7 | 0 | 0 | 0 | 0 | 0 | 4 |

** p<0.05 vs. Untreated group at the same time points. # p<0.05 vs. Annulus puncture group at the same time points.*

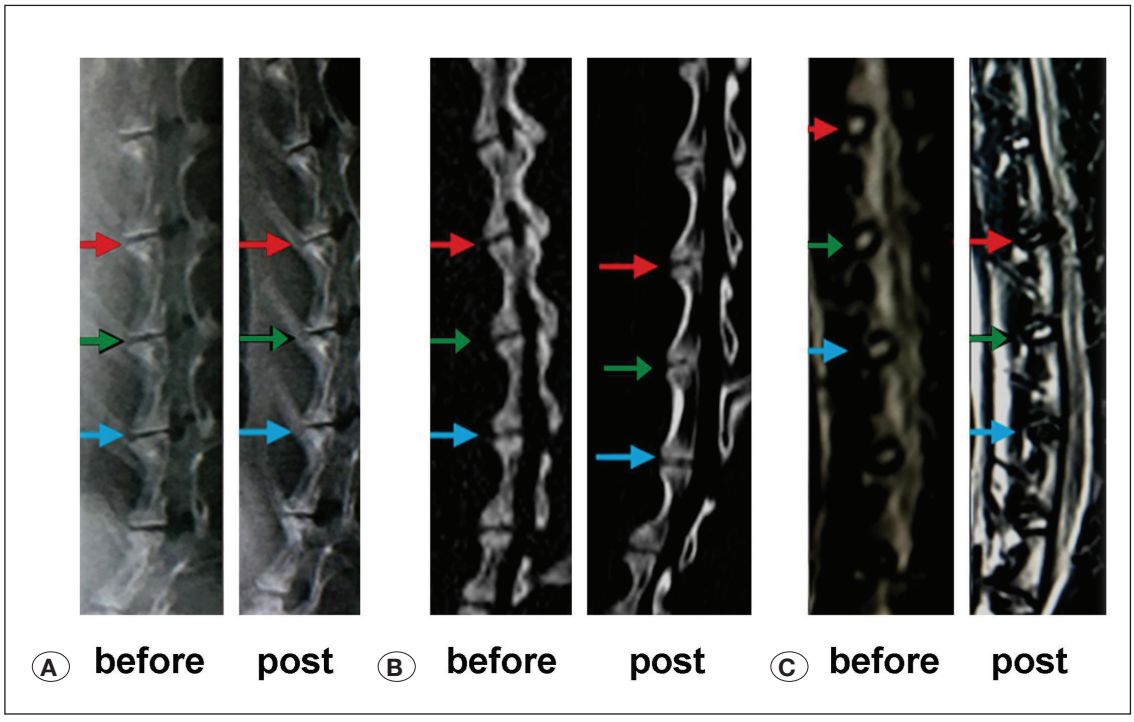


**Figure 4:** Comparison of the preoperative and postoperative X-day, computerized tomography (CT), and magnetic resonance imaging (MRI) at six weeks. **A)** X-ray before/post operation. **B)** CT before/post operation. **C)** MRI before/post operation. L3/4 annulus puncture: blue arrows, L4/5 untreated operation: green arrows, and L5/6 nucleoplasty: red arrows.

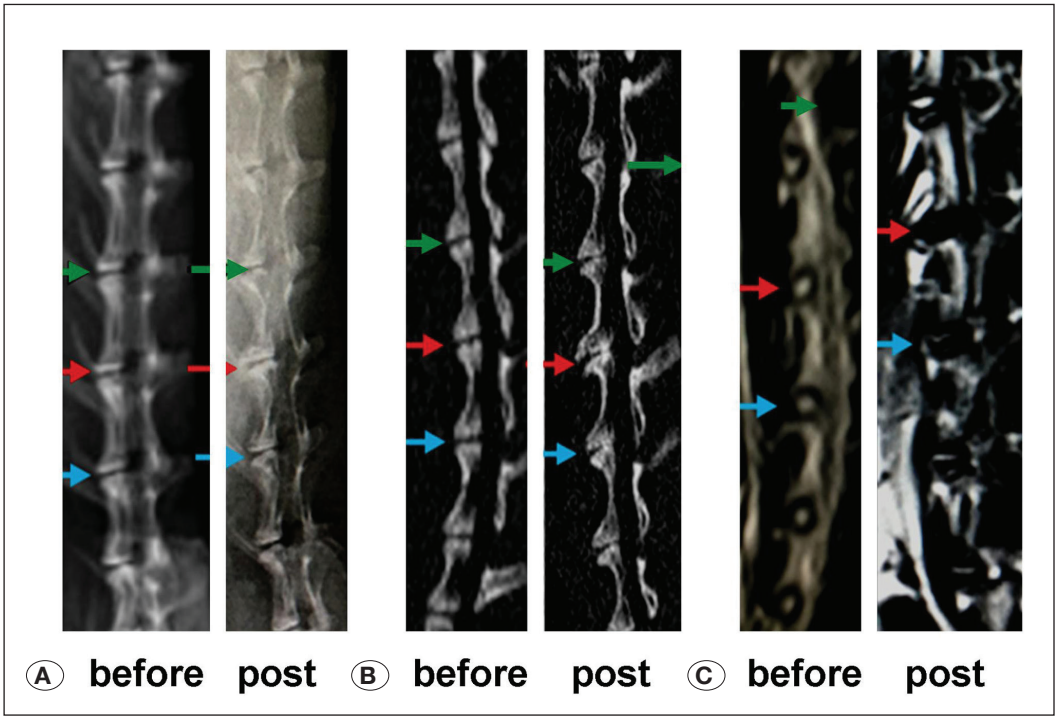


**Figure 5:** Comparison of the preoperative and postoperative X-day, computerized tomography (CT), and magnetic resonance imaging (MRI) at 12 weeks. **A)** X-ray before/post operation. **B)** CT before/post operation. **C)** MRI before/post operation. L3/4 annulus puncture: blue arrows, L4/5 untreated operation: green arrows, and L5/6 nucleoplasty: red arrows.

not been fully elucidated in the literature (22). In this study, rabbits were selected as the model animal for IVDD. Guo et al. confirmed that the intervertebral discs of rhesus monkeys are the most similar to humans; however, rhesus monkeys are rare, expensive, and lack economy in China (9). Rabbits are common animals, and their intervertebral disc structure is basically the same as that of humans. Meanwhile, the rabbit is gentle and easy to operate, and it has good modeling repeatability. Therefore, rabbit is more practical as an animal model for IVDD. At present, the most commonly used method to construct IVDD model is the annulus puncture approach (13,15,18). Kwon and other researchers believed that the rabbit IVDD model could also be successfully constructed by percutaneous annulus puncture under the guidance of X-ray fluoroscopy (14). For the puncture needle specifications and puncture frequency, Masuda et al. reported that three kinds of fine needles (16G, 18G, and 21G) could successfully induce the degeneration of lumbar intervertebral disc in rabbits after the puncture (20). We believe that the degree and speed of disc degeneration are closely related to the diameter of the puncture needle. The degree of disc degeneration in the larger diameter group (16G and 18G) is more serious than that in the smaller diameter group (21G). Additionally, Kim et al. found that a three-time 21G annulus puncture was more likely to cause degeneration of the intervertebral disc than a one-time 18G annulus puncture (11). Therefore, we thought that the frequency of needling can also affect disc degeneration. For the puncture depth and needle retention time, Aoki et al. (2) found that degeneration of the intervertebral disc in the 5-mm group was more serious than that in the 1-mm group. In this study, both the annulus puncture and nucleoplasty groups used X-ray fluoroscopy to guide the percutaneous puncture of target intervertebral disc, which could reduce surgical trauma as well as improve survival rate and puncture accuracy of experimental animals. To avoid the influence of different puncture needle specifications, frequencies, depths, and retention times on findings, the 19G puncture needle was used in both groups. Meanwhile, combined with X-ray fluoroscopy positioning, the puncture frequency was controlled once, puncture depth was controlled at 5 mm, and retention time of the puncture needle in both groups was controlled at 20 s.

The present findings showed that with the prolonged time after the operation, there was no significant difference in disc height for the untreated group, although there was a slight downward trend. At the same time, there was no endplate sclerosis or osteophyte formation at all time points in the untreated group. In the annulus puncture group, disc height decreased with prolonged time after the operation. There were no significant changes in the intensity and area of the MRI signal in the untreated group. In the annulus puncture group, the signal intensity and area of the disc decreased or decreased in different degrees from two weeks after the operation, and the MRI grading of the disc increased progressively. At 12 weeks after the operation, the intervertebral disc lost its normal shape, the boundary between the nucleus pulposus and annulus fibrosus was unclear, and stratified changes appeared.

This study confirmed that the 19G trocar needle can lead to progressive degeneration of the lumbar disc in rabbits after an injury of the fiber ring. Due to the shortcomings of the X-ray plain film and MRI, this study innovatively proposed to combine CT three-dimensional reconstruction technology to observe subtle early changes in the bone endplate. At the same time, it found that endplate sclerosis and osteophyte formation appeared in the puncture group at 12 weeks after the

operation. These results suggest that the injury of the annulus puncture could lead to degeneration of the intervertebral disc in the operation segment.

Nucleoplasty can reduce the pressure on the intervertebral disc, reduce the stimulation and compression of disc tissues on the peripheral nerve, and achieve the therapeutic purpose (7,19). The indications of nucleoplasty are mainly the discogenic low back pain and inclusive lumbar disc herniation with an intact fibrous ring (7,17,20). A previous study showed that nucleoplasty does not cause thermal or structural damage to the surrounding tissues (fiber ring, endplate, spinal cord, and nerve root) (3). However, Klessinger believed that there may be some side-effects of nucleoplasty due to the presence of a fiber ring puncture injury (12).

In this study, considering the risk of increased puncture injury of the fibrous ring during nucleoplasty, in addition to the routine setting of the untreated group as the blank control, the whole layer puncture group of the fibrous ring was added as control. Each rabbit's L3/4, L4/5, and L5/6 intervertebral discs were randomly selected as part of the untreated, annulus full-thickness puncture, and nucleoplasty operation groups. The imaging manifestations of the above three groups at different observation time points were analyzed and compared. We found that the DHI% in the nucleoplasty group decreased gradually with prolonged time and was significantly lower compared with that in the annulus puncture group. Combined with the CT scan, early endplate hardening was observed. At 12 weeks after the operation, sclerosing of the endplate and osteophyte hyperplasia in the nucleoplasty group were more serious compared with those in the annulus puncture group. Additionally, compared with the annulus puncture group at the same time point, MRI grading of the intervertebral disc in the nucleoplasty group was significantly higher. In the second week after the operation, MRI signal intensity and area of the intervertebral disc in the nucleoplasty group were significantly weakened or decreased, as they might have been influenced by the ablation and vaporization. Water loss of the nucleus pulposus in the nucleoplasty group might be more serious compared with that in the annulus puncture group. At 6 and 12 weeks after the operation, degeneration and protrusion of the intervertebral disc in the nucleoplasty group were more serious compared to those in the annulus puncture group. This result suggests that, based on the injury of the annulus puncture, removal of some nucleus pulposus in the nucleoplasty group might result in a change in the internal environment and stress distribution of the intervertebral disc or influence the stability of the operative segment. The above factors might also result in obvious acceleration or aggravation of the degeneration speed and process of the intervertebral disc in the nucleoplasty group.

Indeed, many previous studies have obtained conclusions both in favor of and against nucleoplasty. Therefore, it is very important to study the precautions when applying nucleoplasty in selecting clinical surgical methods. Based on previous studies and our findings, nucleoplasty is a kind of surgical technique demonstrating both safe and successful outcomes, especially when conducted with appropriate indications in cervical and lumbar disc herniations. Therefore, we believe that application of the nucleoplasty technique (especially for well-planned nucleoplasty technique) would contribute to the evaluation of disc degeneration.

## CONCLUSION

The 19G trocar puncture can cause progressive degeneration of the lumbar disc in rabbits. Because of ablation of the vaporized part of the nucleus pulposus tissue, nucleoplasty may have a cumulative effect with the injury of the annulus puncture, which leads to acceleration of disc degeneration and aggravation of the degree. This study suggests that clinicians need to comprehensively consider the advantages and disadvantages of nucleoplasty, strictly grasp the indications of treatment, and prevent long-term complications. In future studies, we recommend improving the biomechanical test of the operative segment and inspecting the histology or molecular biology related to disc degeneration. The findings of this study have implications for clinicians in choosing the appropriate surgical method (whether to use nucleoplasty method or not) after considering the treatment indications, long-term complications, histology, and molecular biology. This study also contributes to the literature, especially in terms of evaluating disc degeneration.

## AUTHORSHIP CONTRIBUTION

**Study conception and design:** QZ

**Data collection:** HY, XZ, ZH, XW

**Analysis and interpretation of results:** HY, QZ

**Draft manuscript preparation:** HY

**Critical revision of the article:** QZ

All authors (HY, XZ, ZH, XW, QZ) reviewed the results and approved the final version of the manuscript.

## REFERENCES

1. Adam D, Pevzner E, Gepstein R: Comparison of percutaneous necleoplasty and open discectomy in patients with lumbar disc protrusions. Chirurgia (Bucur) 108:94-98, 2013
2. Aoki Y, Akeda K, An H, Muehleman C, Takahashi K, Moriya H, Masuda K: Nerve fiber ingrowth into scar tissue formed following nucleus pulposus extrusion in the rabbit anular-puncture disc degeneration model: Effects of depth of puncture. Spine 31:E774-E780, 2006
3. Chen YC, Lee SH, Sanez Y, Lehman N: Histologic findings of disc, endplate and neural elements after coblation of nucleus pulposus: An experimental nucleoplasty study. Spine J 2003:466-470, 2003
4. Farrokhi MR, Karimi MH, Ghaffarpasand F, Sherafatian M: MicroRNA-199a upregulation mediates lumbar intervertebral disc degeneration and is associated with clinical grades of degeneration. Turk Neurosurg 30:104-111, 2020

5. Frymoyer JW, Donaghy RM: The ruptured intervertebral disc. Follow-up report on the first case fifty years after recognition of the syndrome and its surgical significance. Bone Joint Surg 67A:1113-1116, 1985
6. Fujita N, Ishihara S, Michikawa T, Azuma K, Suzuki S, Tsuji O, Nagoshi N, Okada E, Yagi M, Tsuji T, Takayama M, Matsumoto H, Nakamura M, Matsumoto M, Watanabe K: Potential association of metabolic and musculoskeletal disorders with lumbar intervertebral disc degeneration: Cross-sectional study using medical checkup data. J Orthop Sci 25:384-388, 2020
7. Gerges FJ, Lipsitz SR, Nedeljkovic SS: A systematic review on the effectiveness of the nucleoplasty procedure for discogenic pain. Pain Physician 13:117-132, 2010
8. Gregory DE, Bae WC, Sah RL, Masuda K: Disc degeneration reduces the delamination strength of the annulus fibrosus in the rabbit annular disc puncture model. Spine J 14:1265-1271, 2014
9. Guo C, Hu Y, Wu X, An F: The development of degenerative disc animal model in rhesus monkey. Zhonghua Wai Ke Za Zhi 38:548-551, 31, 2000
10. Karaman H, Tufek A, Olmez Kavak G, Yildirim ZB, Temel V, Celik F, Akdemir MS, Kaya S: Effectiveness of nucleoplasty applied for chronic radicular pain. Med Sci Monit 17:CR461-CR466, 2011
11. Kim KS, Yoon ST, Li J, Park JS, Hutton WC: Disc degeneration in the rabbit: A biochemical and radiological comparison between four disc injury models. Spine 30:33-37, 2005
12. Klessinger S: The frequency of re-surgery after lumbar disc nucleoplasty in a ten-year period. Clin Neurol Neurosurg 170: 79-83, 2018
13. Kong MH, Do DH, Miyazaki M, Wei F, Yoon SH, Wang JC: Rabbit model for in vivo study of intervertebral disc degeneration and regeneration. J Korean Neurosurg Soc 44: 327-333, 2008
14. Kwon YJ: A minimally invasive rabbit model of progressive and reproducible disc degeneration confirmed by radiology, gene expression, and histology. J Korean Neurosurg Soc 53: 323-330, 2013
15. Lei T, Zhang Y, Zhou Q, Luo X, Tang K, Chen R, Yu C, Quan Z: A novel approach for the annulus needle puncture model of intervertebral disc degeneration in rabbits. Am J Transl Res 9: 900-909, 2017
16. Li C, Qi Y, Liu G, Yin X, Jin Y, Jiang Z, Li P, Kang X, Ye C: Long-term clinical outcomes of percutaneous cervical necleoplasty for cervical degenerative diseases with neck pain and cervical vertigo. World Neurosurg 133:e205-e210, 2020
17. Liliang PC, Lu K, Liang CL, Chen YW, Tsai YD, Tu YK: Nucleoplasty for treating lumbar disk degenerative low back pain: An outcome prediction analysis. J Pain Res 9:893-898, 2016
18. Luo TD, Marquez-Lara A, Zabarsky ZK, Vines JB, Mowry KC, Jinnah AH, Ma X, Berwick BW, Willey JS, Li Z, Smith TL, O'Gara TJ: A percutaneous, minimally invasive annulus fibrosus needle puncture model of intervertebral disc degeneration in rabbits. J Orthop Surg (Hong Kong) 26(3):230949018792715, 2018
19. Masala S, Massari F, Fabiano S, Ursone A, Fiori R, Pastore F, Simonetti G: Nucleoplasty in the treatment of lumbar diskogenic back pain: One year follow-up. Cardiovasc Intervent Radiol 30:426-432, 2007
20. Masuda K, Aota Y, Muehleman C, Imai Y, Okuma M, Thonar EJ, Andersson GB, An HS: A novel rabbit model of mild, reproducible disc degeneration by an anulus needle puncture: Correlation between the degree of disc injury and radiological and histological appearances of disc degeneration. Spine 30:5-14, 2005
21. Ren DJ, Liu XM, Du SY, Sun TS, Zhang ZC, Li F: Percutaneous nucleoplasty using coblation technique for the treatment of chronic nonspecific low back pain: 5-year follow-up results. Chin Med J (Engl) 128:1893-1897, 2015
22. Singh K, Masuda K, An HS: Animal models for human disc degeneration. Spine J 5:267S-279S, 2005
23. Yan SZ, Di J, Shen Y: Adjacent segment degeneration following anterior cervical discectomy and fusion versus the bryan cervical disc arthroplasty. Med Sci Monit 23:2692-2700, 2017