

# Evaluation of Willis Polygon Morphometry with Cranial Tomographic Angiography

Rukiye CIFTCI<sup>1</sup>, Aymelek CETIN<sup>2</sup>, Hilal Er ULUBABA<sup>3</sup>, Deniz SENOL<sup>4</sup>, Fahri Safa CINARLI<sup>5</sup>, Davut OZBAG<sup>6</sup>

<sup>1</sup>Bandirma Onyedi Eylul University, Faculty of Medicine, Department of Anatomy, Balıkesir, Turkey

<sup>2</sup>Inonu University, Faculty of Medicine, Department of Anatomy, Malatya, Turkey

<sup>3</sup>Yesilyurt Hasan Çalık State Hospital, Malatya, Turkey

<sup>4</sup>Duzce University, Faculty of Medicine, Department of Anatomy, Duzce, Turkey

<sup>5</sup>Inonu University, Department of Movement and Training Science, Malatya, Turkey

<sup>6</sup>Medeniyet University, Faculty of Medicine, Department of Anatomy, Istanbul, Turkey

This study has been presented as an oral presentation at the 21<sup>st</sup> National Anatomy Congress between 27 and 29 April 2020, Online, Turkey.

**Corresponding author:** Rukiye CIFTCI ✉ rukiyekelesciftci@hotmail.com

## ABSTRACT

**AIM:** To examine the morphometric properties of the vessels forming the Willis polygon (WP) in patients with type 2 diabetes mellitus (T2DM) and hypertension (HT) and compare them with healthy individuals.

**MATERIAL and METHODS:** Cranial Tomographic Angiography (CTA) of 168 individuals were analyzed retrospectively. The individuals included in the study were divided into four groups according to the diagnosis. Group 1 included 40 individuals who were diagnosed with HT, Group 2 included 43 individuals who were diagnosed with DM, Group 3 included 42 individuals who were diagnosed with DM and HT, and Group 4 was the control group and included 43 individuals. The diameter and length measurements of the vessels forming the WP were included in our study.

**RESULTS:** According to the results of the Kruskal Wallis H test, in female patients statistically significant differences were detected in the diameter measurements of the right and left A1 segment of the ACA, the diameter measurement of the left A2 segment, the diameter measurements of the right and left P1 and P2 segments of the ACP, the diameter measurements of the right and left AComP. ( $p<0.05$ ), in male patients statistically significant differences were found in the diameter of the right A1 segment of the ACA, the diameter and segment length measurements of the right and left P1 segments of the ACP, of the right and left P2 diameter measurements, and segment length measurements of the left AComP ( $p<0.05$ ).

**CONCLUSION:** We also found that the vessel diameters were similar in the HT, DM and HT+DM groups, and smaller than the control group. In addition, we think that knowing WP morphometric measurements will both guide the radio-anatomical evaluations to be made and increase the level of microanatomical knowledge in surgical treatment.

**KEYWORDS:** Computed tomography angiography, Polygon of Willis, Hypertension, Diabetes mellitus, Diameter

## INTRODUCTION

The Willis polygon (WP) is an anastomotic polygon at the base of the brain that supplies blood to the brain structures. It consists of the a. cerebri anterior (ACA), a. communicans anterior (AComA), a. cerebri posterior (ACPs) and a. communicans posterior (AComP) arteries. The ACA is divided into two segments, including A1 and A2, and the ACP

is divided into two segments, including P1 and P2 (9). WP is a potential collateral pathway in which adequate distribution of cerebral blood flow can be maintained in the event of impaired or reduced flow in one or more of its proximal vessels. The ability to redistribute blood flow, the presence and size of component vessels depends on the morphology of the polygon (13).

Rukiye CIFTCI  : 0000-0002-5894-5256  
Aymelek CETIN  : 0000-0002-4645-2059  
Hilal Er ULUBABA  : 0000-0003-2124-4525

Deniz SENOL  : 0000-0001-6226-9222  
Fahri Safa CINARLI  : 0000-0002-7552-367X  
Davut OZBAG  : 0000-0001-7721-9471

HT is one of the most important health problems in the Western World. HT, defined as a systolic blood pressure higher than 140 mm Hg or a diastolic blood pressure higher than 90 mm Hg. It affects 25% of the general population and is the main risk factor for serious diseases affecting the brain, heart and kidneys (14). The brain is the main target of the harmful effects of HT, responsible for a high rate of the death and morbidity (5).

DM is a heterogeneous metabolic disorder characterized by hyperglycemia, which develops due to insufficient insulin secretion (1). In type 2 diabetes, destruction of pancreatic h cells through autoimmune mechanisms leads to insulin deficiency and patients need insulin therapy to survive. DM can cause retinopathy, kidney failure, and cardiovascular diseases and it affects the brain vessels (2).

Pathologies such as DM and HT can affect the structure of the vessel wall, which may cause an important clinical picture such as stroke. The vessel wall tension, which is low under normal conditions, increases due to HT and DM (4).

In an anatomical study, CTA has a very important place for safer microvascular surgical interventions. In the literature, there are detailed studies on each artery forming the WP, however, there are few studies on the entire polygon. The aim of this study is to contribute to clinical evaluations by examining the relationship between the morphological features of the vessels participating in the structure of WP and DM and HT.

## ■ MATERIAL and METHODS

### Patient Population

The morphometric analyzes were performed retrospectively on 168 brain CTA images of the patients between the ages of 40-65, who admitted to Malatya Inonu University Faculty of Medicine Department of Radiology, between 2012 and 2020. Ethical approval for the study was obtained from Clinical Research Ethics Committee of Malatya Inonu University (Code: 2020/583).

Patients with cerebral aneurysm, acute ischemic stroke, those with a history of embolism, previous endovascular treatment, and chronic hyperlipidemia were excluded from the study. In addition, CT images with artifacts were excluded from the study. The individuals included in the study were divided into four groups.

Group 1 (G1): Patients who were diagnosed with HT

Group 2 (G2): Patients who were diagnosed with DM

Group 3 (G3): Patients who were diagnosed with both DM and HT

Group 4 (G4): Patients who have not been diagnosed with DM or HT ( Control group).

### Imaging Method

The CTA images of the patients included in the study were obtained by the double source spiral CTA (Somatom Definition Flash, Simens Healthcare, Forchheim, Germany), located in the Radiology Department of İnönü University. The device

was 256 slice multislice CT with a dose of 120 kv 35 mA and section thickness of 0.6 mm, and the amount of contrast material was 100 ml.

According to the scanning protocol, the patients were placed on the table in a supine position with the head forward and the arms at the sides and the scanning area was adjusted from vertex to mentum. Using the 'bolus tracking' method, a single section from the 'Region of interest' pattern to the aorta was placed on the reference image, and the threshold contrast value was set to 100 HU to start scanning. A low-osmolarity non-ionic iodinated contrast material of 80-100 ml was injected into the median cubital vein with an automatic pump with an injection rate of 4-5 ml/sec and 40 ml of saline solution was injected after the contrast agent for homogeneous distribution (Figure 1).

The following measurements were made on the CTA images of the patients:

1. ACP diameter (right-left):
2. P1 segment: It originates from the A. basilaris termination site from the AComP in the cisterna interpeduncularis.
3. P2: Around the mesencephalon from AComP
4. ACA vessel diameter (right-left):
5. A1: a. originates from the terminal of the bifurcation of the carotis interna
6. A2: lies in front of the lamina terminalis along the rostrum of the corpus callosum
7. P1: segment length
8. P2: segment length
9. A1: segment length
10. A2: segment length
11. AComA vessel diameter

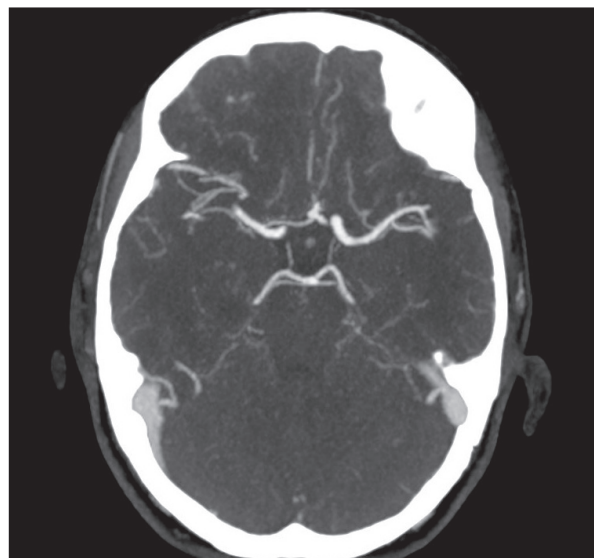


Figure 1: Cranial tomographic angio image of the Willis Polygon.

12. AComP vessel diameter (right-left)
13. Length of AComA
14. Distance between AComPs
15. A.basilaris vessel diameter
16. Diameter measurement of the cavernous segment of the ACI (Figure 2).

The images were evaluated from axial sections. Then, all three planes (axial, sagittal, coronal) were examined by using maximum intensity projection (MIP) images. Diameter measurements of the vascular structures forming the WP were measured from the proximal part of the vascular structure in axial sections. Again, the lengths of the vascular structures forming the WP were examined in three planes and measured in the most appropriate plane according to the vascular anatomy of the patients. Variations in WP were also examined. Measurements were made by a single radiologist.

### Statistical Analysis

The conformity of the data to the normal distribution was examined with the Kolmogorov Smirnov test and it was determined that the data did not show normal distribution. The data that did not show normal distribution were expressed as median, minimum (min) and maximum (max) values. Mann-Whitney U test was used to compare the parameters of male and female patients in the same group. Kruskal Wallis H test was used to compare the parameters of the patients between the groups. Paired comparisons were performed by using Mann-Whitney U test as a Post-Hoc test in order to determine which group caused the difference for the parameters that differed between the groups. Post-Hoc test was given as Model Viewer table. A value of  $p < 0.05$  were considered statistically significant. Statistical analyses were performed by using IBM SPSS Statistics 22.0 for Windows package program.

## RESULTS

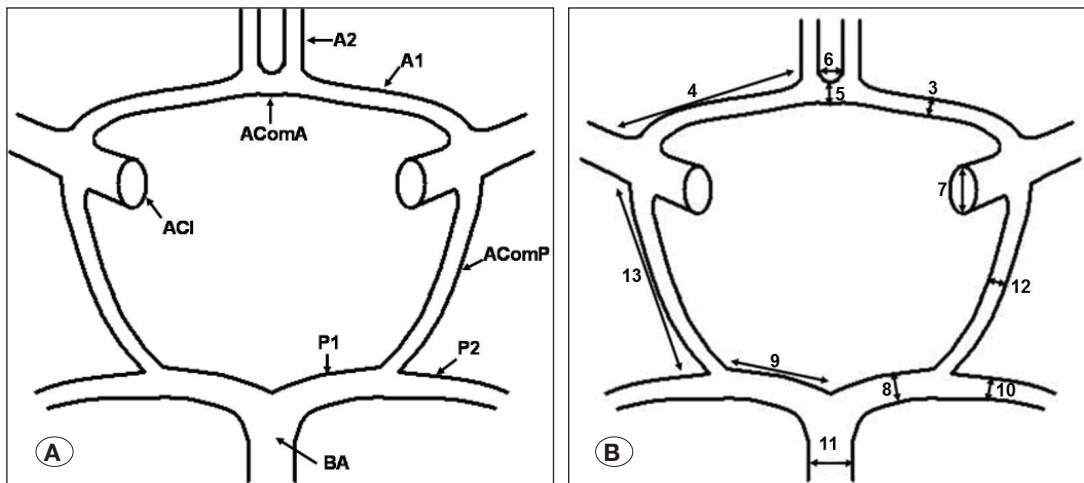
In our study, CTA (Computed Tomography Angiography) images of 512 patients were reviewed, 168 (65 female, 103 male) individuals were measured retrospectively after excluding 344 patients who did not meet the inclusion criteria (Figure 3). The mean age of female patients was  $57.25 \pm 1.1$  years, and the mean age of male patients was  $59.39 \pm 0.7$  years.

Table I, there was no statistically significant difference in both genders in the groups ( $p > 0.05$ ).

Kruskal Wallis H test was used to compare vessel measurements between groups in male patients. According to the result of the Kruskal Wallis H test, statistically significant differences were found in the diameter of the right A1 segment of the ACA, the diameter and segment length measurements of the right and left P1 segments of the ACP, of the right and left P2 diameter measurements, and segment length measurements of the left AComP ( $p < 0.05$ ) (Table II, III).

According to the analysis results, for the right ACA (A1) diameter in male patients; between Group 2 and Group 4, for right ACP (P1) diameter; between Group 2 and Group 4, for left ACP (P1) diameter; between Group 2 and Group 4 and Group 1, for the right ACP (P2) diameter; between Group 2 and Group 1, between Group 2 and Group 4 and Group 1 for left ACP (P2) diameter, Group1, Group2 and Group3 and Group 4 for right ACP (P1) length, Group1 for left ACP (P1) length It was determined that there was a difference between Group 2 and Group 4, and between Group 1 and Group 2 for left AComP length ( $p < 0.05$ ) (Figure 3, 4).

Kruskal Wallis H test was used to compare vessel measurements between groups in female patients. According to the results of the Kruskal Wallis H test, statistically significant differences were detected in the diameter measurements of the right and left A1 segment of the ACA, the diameter measure-



**Figure 2:** Locations of diameter and length measurement on Willis Polygon (11). **A)** Schematic drawing of the Willis polygon, **B)** Display of the measured parameters on the WP (**A1:** Arteria Cerebri Anterior (ACA) A1 segment, **A2:** Arteria Cerebri Anterior (ACA) A2 segment, **ACI:** Arteria Carotis Interna, **AComA:** Arteria Communicans Anterior, **AComP:** Arteria Communicans Posterior, **P1:** Arteria Cerebri Posterior P1 segment, **P2:** Arteria Cerebri Posterior P2 segment, **AB:** Arteria Basilaris).

**Table I:** Age of Groups by Diagnosis

Gender	G1 (n=40)	G2 (n=43)	G3 (n=42)	G4 (n=43)	p
	Median (min-max)	Median (min-max)	Median (min-max)	Median (min-max)	
Male, age (year)	62 (44-65)	63 (40-65)	57 (44-65)	62 (40-65)	0.09
Female, age (year)	59 (40-65)	52.5 (47-65)	60 (42-65)	59 (40-65)	0.08

**Table II:** Comparison of Vessel Diameters Between Groups in Male Patients

Variables (mm)	G1 (n=19)	G2 (n=33)	G3 (n=24)	G4 (n=28)	p
	Median (min-max)	Median (min-max)	Median (min-max)	Median (min-max)	
ACA (A1). right	2 (0.8- 2.5)	2 (1- 2.4)	2 (1- 2.8)	2.1 (1.5- 3)	<b>.017*</b>
ACA (A1). left	2.1 (1.7- 2.7)	2 (1.3- 2.5)	2 (0.5- 2.6)	2.2 (1.3- 2.6)	.325
ACA (A2). right	2 (1.5- 2.4)	1.9 (1.5- 2.1)	1.9 (1.6- 2.7)	2 (1.4- 2.7)	.123
ACA (A2). left	2 (1.7- 2.4)	1.9 (1.5- 2.3)	1.9 (1.5- 2.5)	1.9 (1.4- 2.4)	.247
ACP (P1). right	2 (0.5- 2.4)	1.9 (1.5- 2.4)	1.9 (1.6- 2.4)	2.2 (1.3- 2.7)	<b>.031*</b>
ACP (P1). left	2.1 (1.7- 2.4)	1.9 (1.3- 2.2)	2 (1.3- 2.4)	2.1 (1.3- 2.5)	<b>.002**</b>
ACP (P2). right	2 (1.3- 2.2)	1.8 (1.3- 2.2)	1.9 (1.5-2.2)	1.9 (1.3- 2.5)	<b>.018*</b>
ACP (P2). left	2 (1.6- 3.2)	1.8 (1.4- 2.2)	1.9 (1.5- 2.4)	2 (1.6-2.3)	<b>.001**</b>
AComA	1.5 (0.6- 2.2)	1.4 (0.7- 2.2)	1.4 (0.7-2.3)	1.5 (0.9- 2.4)	.493
AComP right	1.2 (1- 1.8)	1.2 (0.5- 2.5)	1.5 (0.6- 2)	1.5 (0.6- 2)	.322
AComP left	1.2 (0.7- 2.1)	1.4 (0.5- 2.3)	1.5 (0.8- 1.8)	1.6 (0.8- 2)	.502
a.Basilaris	2.9 (2.2- 4.9)	2.6 (2.3- 3.4)	3 (2.4- 4.1)	2.9 (1.9- 4.9)	.102
ACI right	4.1 (2.7-5.5)	3.8 (3.2-4.5)	4.2 (3.5-4.8)	4.5 (4-5.4)	.646
ACI left	4.1 (2.8-5.6)	3.9 (3-4.4)	4.1 (3.6-5.3)	4.5 (4.1-4.9)	.725

\*: Significant differences at the  $p < 0.05$  level, \*\*: **A1:** Arteria Cerebri Anterior (ACA) A1 segment, **A2:** Arteria Cerebri Anterior (ACA) A2 segment, **ACI:** Arteria Carotis Interna, **AComA:** Arteria Communicans Anterior, **AComP:** Arteria Communicans Posterior, **P1:** Arteria Cerebri Posterior P1 segment, **P2:** Arteria Cerebri Posterior P2 segment, **AB:** Arteria Basilaris.

**Table III:** Comparison of Vessel Length and Distance Between Groups in Male Patients

Variables (mm)	G1 (n=19)	G2 (n=33)	G3 (n=24)	G4 (n=28)	p
	Median (min-max)	Median (min-max)	Median (min-max)	Median (min-max)	
ACA (A1). right	13.2 (8.7- 16)	13.3 (10.2- 17)	14.4 (9- 18.6)	14.9 (11.2- 19.2)	.055
ACA (A1). left	13 (9.8- 16.6)	13.1 (10-15.8)	13.8 (9.7- 19)	14 (11.4- 18.7)	.375
ACP (P1). right	8.5 (5.1- 11.8)	8 (5.6- 12.4)	8.4 (5.5- 13.9)	10.8 (6.2- 17.3)	<b>.001**</b>
ACP (P1). left	8.2 (5.8- 11.4)	8.2 (4.8- 11.9)	8.9 (5- 17.8)	9.2 (7- 16)	<b>.005**</b>
AComA.	2.3 (1.3- 4.5)	2.5(0.9- 4)	2.8 (1.5- 6.4)	3 (1.7- 5.2)	.280
AComP. right	9.9 (7.7- 14)	10.8 (5.6- 14.7)	10.6 (5.9- 14)	10.5 (8- 13.1)	.594
AComP. left	7.5 (5.8- 14.3)	11.3 (9.7- 12)	9.8 (6.3- 19.6)	10.9 (9.1- 12.3)	<b>.002**</b>
Dis AComPs	10.4 (6.7- 19.5)	12.5 (6.6- 25.2)	11.4 (6.2- 24)	16.3 (10.9- 24.4)	.282

\*: Significant differences at the  $p < 0.05$  level, \*\*: **A1:** Arteria Cerebri Anterior (ACA) A1 segment, **AComA:** Arteria Communicans Anterior, **AComP:** Arteria Communicans Posterior, **P1:** Arteria Cerebri Posterior P1 segment, **Dis AComP:** Arteria Commicans Posteriors distance.

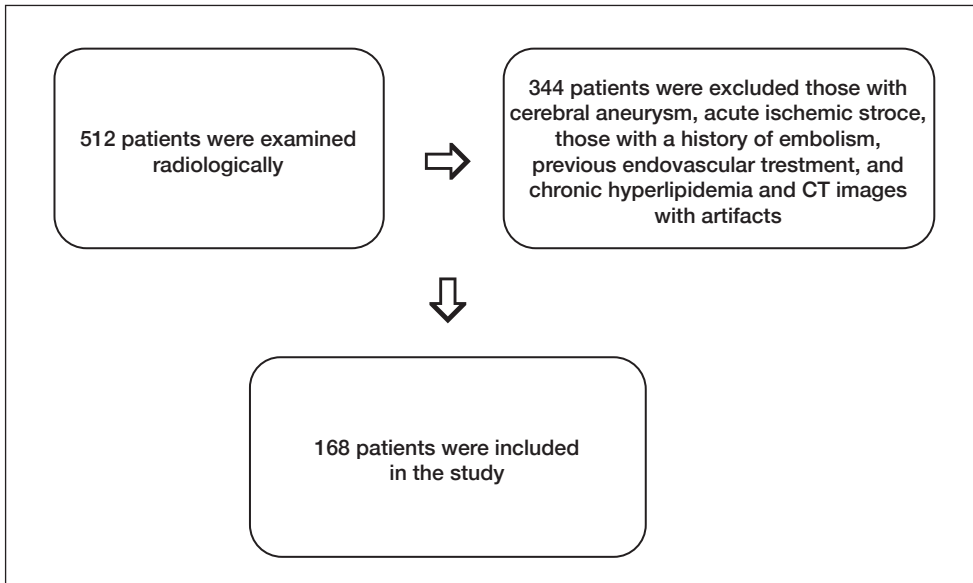


Figure 3: Flow chart of the study.

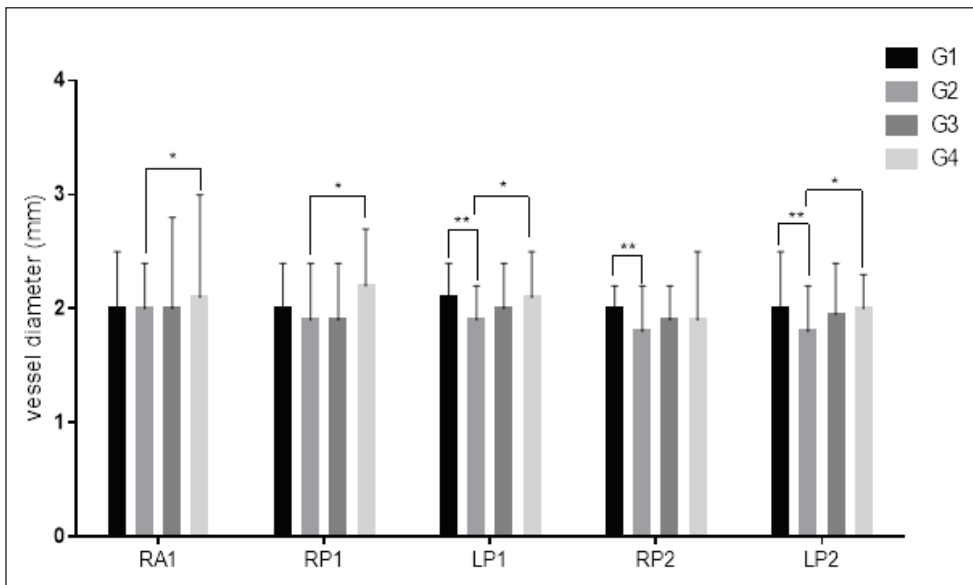


Figure 4: Post-Hoc test results of vessel diameter in male patients (\*: Significant differences at the  $p < 0.05$  level, \*\*: Significant differences at the  $p < 0.01$  level: **RA1**: right Arteria Cerebri Anterior (ACA) A1 segment; **RP1, LP1**: right and left Arteria Cerebri Posterior P1 segment; **RP2, LP2**: right and left Arteria Cerebri Posterior P2 segment.

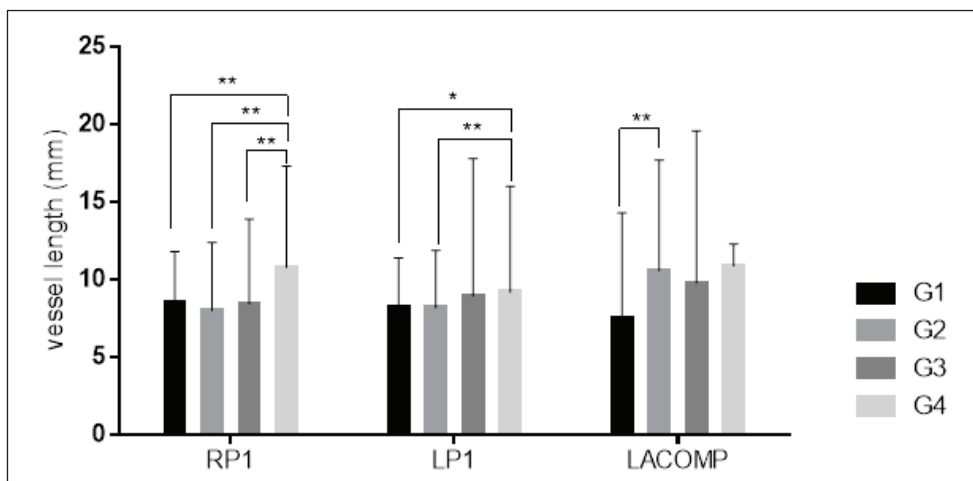


Figure 5: Post-Hoc test results of vessel length in male patients (\*: Significant differences at the  $p < 0.05$  level, \*\*: Significant differences at the  $p < 0.01$  level: **RP1, LP1**: right and left Arteria Cerebri Posterior P1 segment; **LACOMP**: left Arteria Communicans Posterior.

ment of the left A2 segment, the diameter measurements of the right and left P1 and P2 segments of the ACP, the diameter measurements of the right and left AComP ( $p < 0.05$ ) (Table IV). There was no significant difference in segment length measurements of vessels in female patients ( $p > 0.05$ ) (Table V).

In female patients, right ACA (A1) diameter, between Group 3 and Group 4, left ACA (A1) diameter, between Group 3 and Group 4, left ACA (A2) diameter; between Group 3 and Group

4, for right ACP (P1) diameter; between Group 2 and Group 4, for left ACP (P1) diameter; between Group 2 and Group 4, for right ACP (P2) diameter; Group 2 between Group 3 and Group 4, between Group 2 and Group 3 and Group 4 for left ACP (P2) diameter, Group 3 and Group 4 for AComA length, Group 3 with Group 4 and Group 2 for left AComP diameter. It was found that there is a difference (Figure 6).

**Table IV:** Comparison of Vessel Diameters Between Groups in Female Patients

Variables (mm)	G1 (n=21)	G2 (n=10)	G3 (n=18)	G4 (n=15)	P
	Median (min-max)	Median (min-max)	Median (min-max)	Median (min-max)	
ACA (A1) right	1.9 (1.4-2.5)	1.8 (1.7-2.4)	1.7 (0.5- 2.3)	2 (1.6- 2.6)	.017*
ACA (A1) left	2 (0.9- 2.7)	1.9 (1.5-2.3)	2 (0.9- 2.3)	2.3 (2- 2.6)	.003**
ACA (A2) right	1.8 (1.6- 2.5)	1.7 (1.5- 2)	1.9 (1.5- 2.1)	1.9 (1.8- 2.4)	.101
ACA (A2) left	1.9 (1.5- 2.3)	1.7 (1.3- 2.2)	1.9 (1.4- 2.2)	2.1 (1.7- 2.3)	.026*
ACP (P1) right	1.9 (1.1- 2.5)	1.6 (1.2- 2)	1.8 (1.2- 2.4)	2.2 (1.3- 2.9)	.006**
ACP (P1) left	2 (1.5- 2.5)	1.7 (1.1-2.1)	2 (1.5- 2.6)	2.2 (0.8- 2.6)	.047*
ACP (P2) right	1.9 (1.6- 2.5)	1.8 (1.5- 1.9)	1.8 (1.4- 2.3)	2 (1.7- 2.5)	.016*
ACP (P2) left	1.9 (1.6- 2.4)	1.8 (1.5- 2)	1.9 (1.5- 2.5)	2.2 (1.8- 2.4)	.002**
AComA	1.4 (0.5- 1.7)	1.4 (0.8- 1.9)	1.4 (0.8- 2)	1.6 (1- 1.9)	.554
AComP right	1.4 (0.5- 2.1)	1.6 (1.5- 1.8)	1.1 (0.8- 2)	1.7 (1.1- 2.4)	.044*
AComP left	1.3 (0.7- 1.9)	1.6 (1.3- 1.8)	1.1 (0.6- 1.6)	1.6 (1.1- 2)	.003**
a.basilaris	2.7 (2.3- 3.2)	2.7 (2.3- 3)	2.7 (2.3- 3.5)	2.7 (2.4- 3.5)	.686
ACI right	4.5 (3.8-5.5)	4.1 (3.7-5)	4.5 (3.3-6.1)	4.5 (4-5.4)	.076
ACI left	4.5 (3.8-5.5)	4.1 (3.2-5.3)	4.6 (3.6-5.4)	4.5 (4.1-4.9)	.060

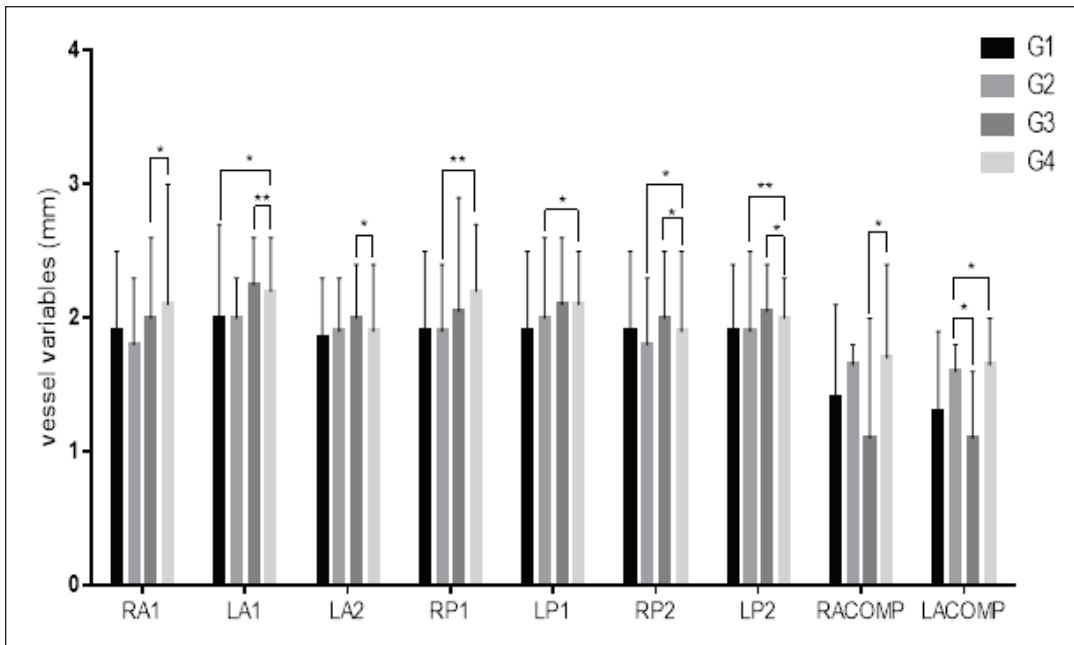
\*: Significant differences at the  $p < 0.05$  level, \*\*: **A1:** Arteria Cerebri Anterior (ACA) A1 segment, **A2:** Arteria Cerebri Anterior (ACA) A2 segment, **ACI:** Arteria Carotis Interna, **AComA:** Arteria Communicans Anterior, **AComP:** Arteria Communicans Posterior, **P1:** Arteria Cerebri Posterior P1 segment, **P2:** Arteria Cerebri Posterior P2 segment, **AB:** Arteria Basilaris.

**Table V:** Comparison of Vessel Length and Distance Between Groups in Female Patients

Variables (mm)	G1 (n=21)	G2 (n=10)	G3 (n=18)	G4 (n=15)	P
	Median (min-max)	Median (min-max)	Median (min-max)	Median (min-max)	
ACA (A1). right	11.8 (9.5- 14.6)	13 (11.6- 15.3)	12.1 (9.5-16.5)	12.6 (7- 19.2)	.342
ACA (A1). left	11 (9.4- 14.3)	12.6 (11.3-14.2)	12.3 (9.7-14.3)	11.3 (9.8- 16.4)	.110
ACP (P1). right	7.2 (4.8- 10.2)	6.9 (4.4- 10.7)	6.8 (4.1- 10.1)	7.7 (4.6- 10.2)	.517
ACP (P1). left	8.3 (5.5- 9.8)	6.7 (5- 9.7)	8.2 (5.5- 12.6)	8.5 (5.1- 12.1)	.167
AComA.	2.3 (1.4- 15.6)	2.1 (1.4- 2.7)	2.1 (1.2- 4.2)	2.9 (1.9- 4)	.051
AComP. right	8.5 (3- 11.2)	7.8 (5.9- 9.8)	10.1 (6.1-13.6)	9.6 (8.6- 11.7)	.214
AComP. left	7.5 (5.1- 11.2)	9.2 (7.1- 11.5)	9.1 (2.8- 14)	9.5 (7.5- 11.1)	.232
Dis AComPs	10.9 (6.3- 25.1)	12.6 (12.2- 13)	14.8 (7.9-19.1)	14.7 (11- 18.7)	.291

\*: Significant differences at the  $p < 0.05$  level, \*\*: **A1:** Arteria Cerebri Anterior (ACA) A1 segment, **AComA:** Arteria Communicans Anterior, **AComP:** Arteria Communicans Posterior, **P1:** Arteria Cerebri Posterior P1 segment, **Dis AComP:** Arteria Commicans Posteriors distance.





**Figure 6:** Post-Hoc test results of vessel diameter in female patients (\*: Significant differences at the  $p < 0.05$  level, \*\*: Significant differences at the  $p < 0.01$  level: **RA1, LA1:** right and left Arteria Cerebri Anterior; **LA2;** left Arteria Cerebri Anterior (ACA) A2 segment; **LP1, RP1:** right and left Arteria Cerebri Posterior P1 segment; **RP2, LP2:** right and left Arteria Cerebri Posterior P2 segment: **RACOMP, LACOMP:** right and left Arteria Communicans Posterior.

## DISCUSSION

WP takes part in the equal distribution of blood coming from both sides of the brain and in maintaining the blood supply in all parts of the brain in case of occlusion of any of the arteries supplying the brain. Thus, it protects the brain from ischemia (15,18,22). WP is the main determinant of the degree of neurological deficits. The aim of our study was to contribute to clinical evaluations by examining the relationship between the morphological features of the vessels participating in the structure of WP and pathologies such as DM and HT.

It has been observed that morphological information about WP has been investigated in cadaver studies since the 20<sup>th</sup> century and later in angiographic studies. In the last two decades, efforts to increase the knowledge gained by much more detailed examinations using newer imaging technologies such as Doppler, CTA and magnetic resonance show the interest in the anatomy of this artery. CTA, one of the frequently used technologies, is a sensitive, specific and highly accurate method for imaging both internal and external vascular structure. It is superior to carotid doppler in distinguishing carotid occlusion from a very high degree occlusion (6).

Shatri et al. scanned the MRA images of 133 individuals aged 18-83 years and examined the length and diameter measurements of the cerebral vessels included in the WP according to age and gender (20). They stated that 53% of the patients were  $\geq 40$  years old and 52% were women. They found that the mean vessel diameters of the male patients were larger compared to the female patients, except AComP. In our study, 39% of the patients were females. The rate of male patients was higher in our study, whereas the rate of female patients was higher in the studies in the literature.

ACA is one of the largest final branches. It supplies the ACI and the medial surface of the cerebral hemisphere. In a study, the mean diameter of the A1 segment of the ACA was

found to be 2.6 mm (0.9-4), and the mean length was 12.7 mm (7.2-18) (19). Other researchers' findings paralleled this conclusion (3,7,13,21). In our study, the mean vessel diameter measurements were lower in HT and DM patients compared to the literature, while those of the control group were similar to the literature. In this case, we think that symptoms such as HT and DM cause narrowing of the vessel diameter.

The ACP crosses the oculomotor nerve and extends from the AB to the AComP. In the literature determined that the mean diameter of the P1 segment of the ACP was 2.6 mm (0.9-4), segment length was 7 mm (3-20), P2 diameter was 2.7 mm (1.6-4) (14,19). In our study, the diameter measurement of cerebral vessels is lower compared to the literature. We think that pathologies such as HT and DM cause atherosclerosis in the vessels and narrow the vessel diameter. We found that diameter and segment length of ACP were smaller in patients with DM.

The AComA originates from the ACA and is the important anastomosis as it connects the right and left ACA (17). In a literature review, the mean diameter of the AComA segment was calculated as 1.5mm (0.2-3.4) and the segment length was 2.6 mm (0.3-7) (13). In another study, the diameter of the AComA segment was reported to be 1.4 mm. Our results were similar to the literature.

The AComP is an important element of the collateral circulation between the anterior and posterior circle of the WP. Kamath examined 100 cadavers to investigate length and diameter measurements of WP and reported that AComP segment length was  $13.5 \text{ mm} \pm 3.4$  on the right,  $13.3 \text{ mm} \pm 3.3$  on the left. The diameter of AComP was reported to be  $1.5 \text{ mm} \pm 0.7$  on the right and  $1.4 \text{ mm} \pm 0.7$  on the left (10). In our study, we determined that the diameter and segment lengths of cerebral vessels in HT and DM patients were similar to each other and lower compared to the literature.

In the literature, seven segments of ACI have been defined (15,16). In our study, we evaluated measurements of the cavernous segment since it is included in the structure of WP. In a study, the mean ACI segment length was reported to be  $4.8 \text{ mm} \pm 1.5$  on the right and  $4.7 \text{ mm} \pm 1.5$  on the left and diameter was  $4.2 \text{ mm} \pm 0.9$  on the right and  $4.2 \text{ mm} \pm 0.9$  on the left (1). In our study, we determined that the ACI diameter measurements were lower than the literature in both HT and DM patients, and the difference between the measurements was higher in DM patients. We think that DM causes further narrowing in the AC diameter.

If some arteries of WP are too thin or absent, radiological intervention may become impossible. This obstructive condition is important in cerebrovascular diseases and cerebrovascular surgery (8).

In our study, when the diameter measurements were compared according to the groups, we found that they were similar in the HT, DM and HT+DM groups, and smaller compared to the control group. We think that pathologies such as HT and DM cause atherosclerosis in the vessel and narrow the vessel diameter.

In a study, which examined 51 DM and HT patients and 54 DM patients were in terms of cerebrovascular events or death rate, it was found that rate of cerebrovascular events and death was higher in DM and HT patients. In the same study, it was stated that the mortality rate was higher in male DM patients compared to females (12).

Although HT and DM are common diseases that are known to cause hypertrophic formation in brain vessels, no study was found comparing the segment lengths of individuals with HT and DM in the literature review. Although the lack of publications to compare our work creates a limitation for the discussion section, it will form a basis for new studies to be made in this field.

Being knowledgeable of the variations of the diameter and length of the arteries of the WP according to age, gender, and systemic diseases (HT, DM) is of great importance in anatomy lessons as well as in interventional radiology and operations.

## CONCLUSION

Diseases such as HT and DM negatively affect WP. It causes diseases that affect human life such as cerebrovascular events, Alzheimer's disease, and cognitive disorders by disrupting the vascular structure of the brain. We also found that the vessel diameters were similar in the HT, DM and HT+DM groups, and smaller than the control group. We think that pathologies such as HT and DM cause atherosclerosis in the vessel and narrow the vessel diameter.

The dimensions of vascular structures are important in neurovascular procedures. For intracranial access in the treatment of aneurysm, cerebral hemorrhage, vascular malformation, cerebrovascular disease and tumor, WP is the main vascular structure. Knowing the variation of the diameter and segment length of the vessels in WP according to common chronic diseases such as HT and DM may help in determining the size of

invasive devices such as catheters and stents before starting the treatment of patients.

## AUTHORSHIP CONTRIBUTION

Study conception and design: RC, HEU, FSC, RC, DS

Data collection: RC, HEU, FSC, RC, DS

Analysis and interpretation of results: RC

Draft manuscript preparation: RC, HEU, FSC, RC, DS

Critical revision of the article: AC, DO

Other (study supervision, fundings, materials, etc...): HEU, FSC, RC, DS, AC, DO

All authors (RC, AC, HEU, DS, FSC, DO) reviewed the results and approved the final version of the manuscript.

## REFERENCES

- Ahmet RG: The physiologic and biochemical effects of diabetes on the balance between oxidative stress and antioxidant defense system. *Med J Of Islamic Academy of Sci* 15(1):31-42, 2005
- Biessels GJ, Kappelle A, Bravenboer B, Erkelens D, Gispen W: Cerebral function in diabetes mellitus. *Diabetologia* 37(7):643-650, 1994
- Chen HW, Yen PS, Lee CC, Chen CC, Chang PY, Lee SK: Magnetic resonance angiographic evaluation of circle of Willis in general population: A morphologic study in 507 cases. *Chin J Acad Radiol* 29(5):223-229, 2004
- Chi Y, Lu Z: Association between patency of the circle of Willis and diabetes mellitus in patients with cerebral ischaemic stroke. *J Int Med Res* 45(2):723-732, 2017
- Dahlöf B: Prevention of stroke in patients with hypertension. *Am J Cardiol* 100(3):17-24, 2007
- Gabrielsen TO, Greitz T: Normal size of the internal carotid, middle cerebral and anterior cerebral arteries. *Acta Radiol Diagn* 10:1-10, 1970
- Hafez KA, Affifi NM, Saudi FZ: Anatomical variations of the circle of Willis in males and females on 3D MR angiograms. *Egypt J Hosp Med* 26(1):106-121, 2007
- Hillen B: The variability of the circulus arteriosus (Willis): Order or anarchy? *Cells Tissues Organs* 129(1):74-80, 1987
- Hoksbergen AW, Majoie CB, Hulsmans FJH, Legemate DA: Assessment of the collateral function of the circle of Willis: Three-dimensional time-of-flight MR angiography compared with transcranial color-coded duplex sonography. *Am J Neuroradiol* 24(3):456-462, 2003
- Kamath S: Observations on the length and diameter of vessels forming the circle of Willis. *J Anat* 133(3):419-423, 1981
- Karatas A, Yilmaz H, Coban G, Koker M, Uz A: The anatomy of circulus arteriosus cerebri (circle of Willis): A study in Turkish population. *Turk Neurosurg* 26(1):54-61, 2016
- Kolawole B, Ajayi AL: Prognostic indices for intra-hospital mortality in Nigerian diabetic NIDDM patients: Role of gender and hypertension. *J Diabetes Complicat* 14(2):84-89, 2000
- Krabbe-Hartkamp MJ, Van der Grond J, De Leeuw F, De Groot J, Algra A, Hillen B: Circle of Willis: Morphologic variation on three-dimensional time-of-flight MR angiograms. *Radiol* 207(1):103-111, 1998



14. Messerli FH, Williams B, Ritz E: Essential hypertension. *The Lancet* 370(9587):591-603, 2007
15. Odar V: *Anatomi Ders Kitabı*. Ankara: Elif Matbaacılık 1980: 517-542
16. Osborn AG: *Diagnostic Cerebral Angiography*. Philadelphia: Lippincott Williams&Wilkins, 1999:462-465
17. Paulsen F, Waschke J: *Sobotta Atlas of Human Anatomy, volume 3, English: Head, Neck and Neuroanatomy*. Urban & Fischer, 2013:266-268
18. Rai AT, Hogg JP, Cline B, Hobbs G: Cerebrovascular geometry in the anterior circulation: An analysis of diameter, length and the vessel taper. *J Neurointerv Surg* 5(4):371-375, 2013
19. Saeki N, Rhoton AL: Microsurgical anatomy of the upper basilar artery and the posterior circle of Willis. *J Neurosurg* 46(5):563-578, 1977
20. Shatri J, Bexheti D, Bexheti S, Kabashi S, Krasniqi S, Ahmetgjakaj I: Influence of gender and age on average dimensions of arteries forming the circle of Willis study by magnetic resonance angiography on Kosovo's population. *Open Access Maced. J Medical Sci* 5(6):714-719, 2017
21. Tekale VM, AMBIYE MV: A study of circle of Willis by MR angiography. *Int J Anat Res* 4(3):2542-2546, 2016
22. Voljevica A, Talovic E, Pepic E, Kacic AP: Morphometric analysis of Willis circle arteries. *Archives of Pharmacy Practice* 4(2):77, 2013