



# Perinatal Presentation of a Congenital Intramedullary Capillary Hemangioma in a Neonate Born with Hydrocephalus and Paraplegia

Mohammad Amin Dabbagh OHADI<sup>1</sup>, Seyed Farzad MAROUFI<sup>1</sup>, Keyvan Tayebi MEYBODI<sup>1</sup>, Moeinadin SAFAVI<sup>2</sup>, Farideh NEJAT<sup>1</sup>, Zohreh HABIBI<sup>1</sup>

<sup>1</sup>Tehran University of Medical Sciences, Children's Medical Center Hospital, Department of Pediatric Neurosurgery, Tehran, Iran

<sup>2</sup>Tehran University of Medical Sciences, Children's Medical Center Hospital, Department of Pediatric Pathology, Tehran, Iran

**Corresponding author:** Habibi ZOHREH ✉ zohreh\_h56@yahoo.com

## ABSTRACT

Spinal intramedullary capillary hemangioma is a rare condition. Although most spinal/spinal cord hemangiomas are inborn in origin, perinatal presentation is uncommon.

We present a neonate with an intramedullary hemangioma, born with communicating hydrocephalus and complete paraplegia. Spinal imaging showed an intradural mass with hemorrhagic foci, a low-lying conus medullaris, and scalloping of dorsal elements. Ventriculoperitoneal shunting was performed in an emergent setting, with cerebrospinal fluid showing a brownish appearance with high viscosity which implied a possible old hemorrhage. Tissue sample was taken from the spinal lesion in an elective setting. Histopathological examination revealed capillary lobules and extralobular large vessels resembling abnormal veins.

The mentioned clues suggested that this congenital hemangioma had become symptomatic from the prenatal period. Though it is a rare event, it should be kept in mind while evaluating a neonate with communicating hydrocephalus and weakness of extremities with or without cutaneous hemangiomatous stigmata.

**KEYWORDS:** Congenital, Intramedullary, Capillary hemangioma, Neonatal, Hydrocephalus, Paraplegia

**ABBREVIATIONS:** MRI: Magnetic resonance imaging, VP: Ventriculoperitoneal, CSF: Cerebrospinal fluid, WHO: World Health Organization

## INTRODUCTION

Congenital spinal tumors are rare entities, assumed to be caused by possible embryonic errors (7). Spinal Hemangiomas are infrequent benign vascular tumors, accounting for 3-8 percent of all spinal cord tumors (6). Different sub-types of these tumors are classified in the World Health Organization (WHO) histopathological grade I. Although spinal hemangiomas are congenital in origin, symptomatic presentation during the early postnatal period could hardly be found in the literature.

Herein, we report a case of intradural hemangioma, manifesting at birth-time with complete paraplegia and hydrocephalus.

## CASE PRESENTATION

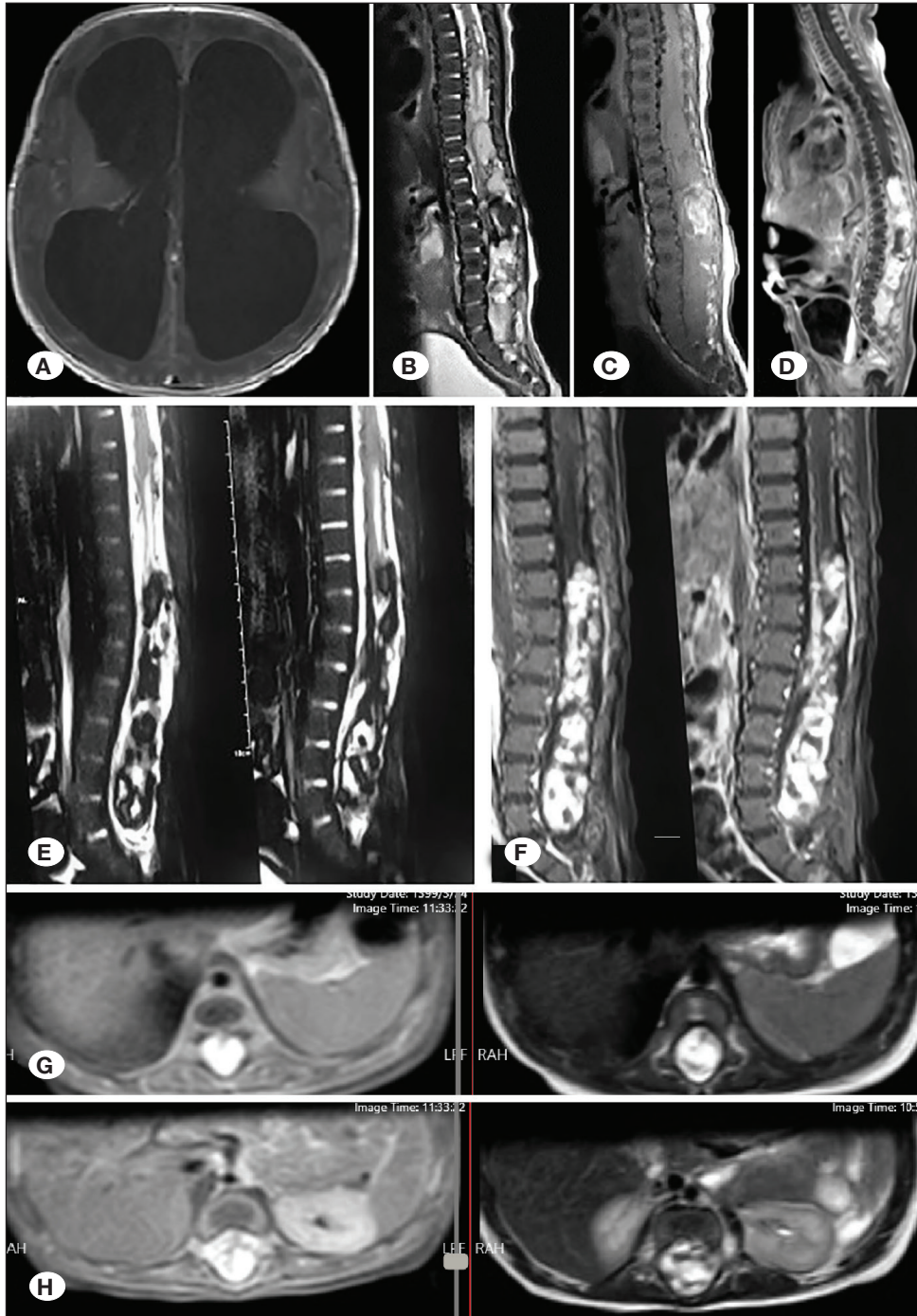
An 11-day neonate was referred to our center with an enlarged head and paraplegia. He was the firstborn of healthy non-consanguineous parents. No prenatal assessments were available. Soon after delivery, he was found to be completely paraplegic. On admission, he had a large head with a full

Mohammad Amin Dabbagh OHADI : 0000-0002-3709-3138  
Seyed Farzad MAROUFI : 0000-0001-7542-0411  
Keyvan Tayebi MEYBODI : 0000-0002-0241-3015

Moeinadin SAFAVI : 0000-0002-4042-7506  
Farideh NEJAT : 0000-0002-4095-404X  
Zohreh HABIBI : 0000-0002-5771-1167

and tense fontanelle. A kyphotic hump was found in the lower back, but no midline cutaneous stigmata or palpable mass was detected. Hemoglobin level was 8/9 gm/dL, while other lab tests were in the normal range. Brain magnetic resonance imaging (MRI) showed severe communicating hydrocephalus. Spine MRI demonstrated a huge intradural lesion with hemorrhagic foci, from the lower thoracic to the end of the thecal sac, with the widening of the spinal canal and scalloping of dorsal elements. The lesion showed heterogeneous enhancement after gadolinium administration

(Figure 1). The patient underwent ventriculoperitoneal (VP) shunting in an emergent setting. Cerebrospinal fluid (CSF) had a brownish-yellow appearance with a thick viscosity. The results of cytology examination and alpha-fetoprotein of CSF were negative. Hydrocephalus was controlled after shunting, and the patient was followed to put on weight for further management. At three months of age, a new MRI showed the same enhancing mass while hemosiderin deposition inside the lesion was expanded compared to the previous MRI (Figure 1). Tissue sampling was planned at this



**Figure 1:** **A)** Brain MRI showing communicating hydrocephalus; T2-weighted **(B)** and T1-weighted **(C)** spine MRI demonstrating a huge intradural lesion with hemorrhagic foci from the lower thoracic to the end of thecal sac, with widening of spinal canal and scalloping of dorsal elements; **D)** Heterogenous enhancement after gadolinium administration; **E)** T2-weighted MRI after 3 months showing more extended hemosiderin deposition inside the lesion compared to the previous MRI, **F)** The same enhancing lesion on T1-weighted image after 3 months; Post-gadolinium injection T1-weighted (Left) and T2-weighted (Right) axial images at the level of lower thoracic **(G)** and upper lumbar **(H)** showing the lesion expanding through all over the intracanal area.

step for further treatment. The patient underwent osteoplastic laminotomy, and the thick dura was opened. A calcified dense mass containing old hemorrhage was intermingled with neural tissue. Cauda equina, conus medullaris, and the lower part of the spinal cord were indistinguishable from the lesion, while the thin dysgenetic cord was lying lower than the normal position. Tissue samples were taken and loose duraplasty was performed. Histopathological examination revealed capillary lobules and extralobular large vessels resembling abnormal veins (Figure 2). The postoperative period was uneventful. Propranolol was prescribed to control hemangiomatous lesion. No new symptom was detected during 1 year of follow-up, and no further spine MRI was done due to the parent's refusal. Even so, the patient was under follow-up for shunted hydrocephalus, and no sign of raised intracranial pressure (ICP) or increased head circumference was found during follow-up. The developmental milestones were compatible with his chronological age, and the upper extremities function was perfect at the time of the last follow-up.

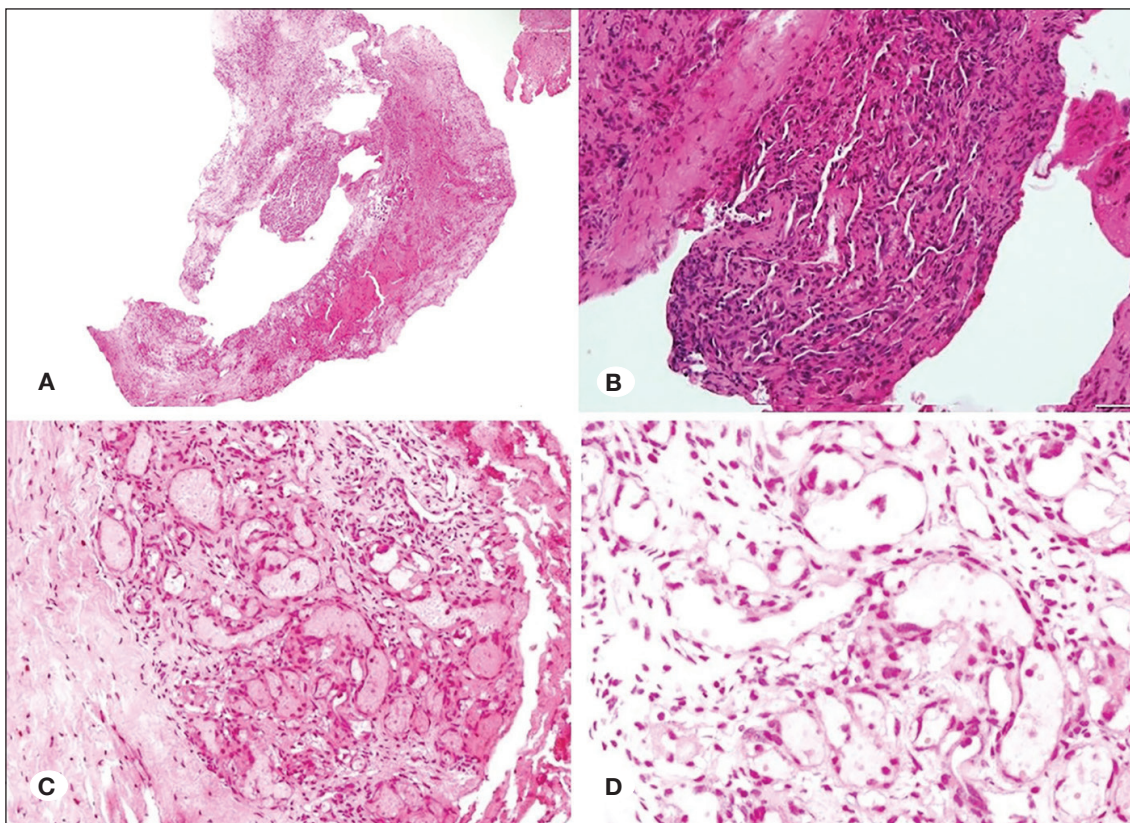
## DISCUSSION

Hemangiomas are benign vessel-rich congenital tumors, classified as capillary and cavernous types based on the morphology of tumor vessels (1,5,6). Spinal hemangiomas can be located in intramedullary, extramedullary, or extradural space (6). Clinical symptoms depend on the size, location, and accompanying hemorrhage (6,9). Sensory-motor defect and

pain are the most common symptoms, while hydrocephalus may rarely follow any spinal cord tumors (5).

Hemangiomas are mostly congenital in origin, but they may present at any age with different manifestations. Some cases would be detected before the onset of symptoms, through neuroimaging to assess a midline dorsal cutaneous hemangioma. Presentation at birth with established neurological symptoms is an infrequent event. Accompanied neonatal hydrocephalus makes the condition even rarer.

The unique feature regarding the current case is the presentation at birth time. Early clinical manifestation up to three months of age supports the congenital origin of tumors (5). Moreover, there are several clues in favor of prenatal symptomatic events. Dense paraplegia and established hydrocephalus detected just after birth proposes a congenital intral-lesional hemorrhage. Hyperproteinorachia and/or arachnoiditis following bleeding would be the underlying cause of hydrocephalus. Hydrocephalus could be also developed because of the blockade of CSF dynamics caused by an intradural spinal mass. Dorsal elements scalloping and low-lying conus medullaris also reinforce the possibility of intrauterine expansion of the lesion. The mass itself and hemorrhagic products had probably hindered the normal development and ascent of the distal part of spinal cord in the fetus. MRI findings of hyperintense mass with signal void foci on T2 sequence suggest old hemorrhagic products. The brownish color of CSF during



**Figure 2: A-D)** Histologic sections show both capillary lobules and extralobular large vessels with resemblance to abnormal veins (hematoxylin and eosin stain, magnification x40(A) x100(B) x200(C) x400(D).

VP shunting and low hemoglobin level are other proofs of perinatal intralesional hemorrhage.

Prenatal sonography may help early diagnosis of congenital spinal lesions including hemangiomas (8). This study had not been performed in the current case. MRI is another modality for reliable diagnosis before and after birth (6). Surgical resection or decompression is recommended for symptomatic intradural hemangiomas, while adjuvant radiotherapy and medications have been considered for partial resection in some cases (6). In the current case, since the neurological deficit was established at birth time, surgical intervention was postponed till the child be in a stable condition to tolerate major surgery. The primary aim was tissue sampling to rule out malignant lesions requiring adjuvant therapy. At surgery, the mass was found to be unresectable and intradural compression was not observed. Even so, prophylactic duraplasty was done for any probable mass enlargement or further hemorrhage. In unresectable hemangiomas some medications may be of use, including beta-blockers, antineoplastic agents, interferons, and steroids. The aim of medical therapy is the preservation of organ function or procrastination of definitive intervention (1). In the current case, spinal cord dysgenesis dissuaded us to benefit from the mentioned drugs. Nonetheless, a beta-blocker was prescribed for 1 year.

There are 5 reported cases of spinal intramedullary capillary hemangiomas detected during infancy, none of them were symptomatic from birth time (2-4,10). Three infants presented with dorsal cutaneous hemangiomas without any neurological sign (3,4). Two other patients developed hydrocephalus after 2 months of age (2,10), one of whom had also a spastic paraparesis (10). To our knowledge, the current case is a unique report of an intramedullary hemangioma with established neurological symptoms and hydrocephalus at birth-time. The lesson learned is that neonates born with hydrocephalus and limb weakness, with no cutaneous signs of spina bifida, may harbor a congenital spinal cord lesion with or without bleeding tendency.

## CONCLUSION

Congenital intradural spinal hemangiomas are rare conditions, which are inborn in origin but could be presented at any age. Perinatal presentation as hydrocephalus and weakness of lower extremities without skin stigmata is a scarce event, but it should be kept in mind while evaluating a neonate.

## AUTHORSHIP CONTRIBUTION

Study conception and design: ZH

Data collection: ZH

Draft manuscript preparation: MADO, SFM

Critical revision of the article: KTM, MS

Other (study supervision, fundings, materials, etc...): FN, ZH

All authors (MADO, SFM, KTM, MS, FN, ZH) reviewed the results and approved the final version of the manuscript.

## REFERENCES

- Holland KE, Drolet BA: Infantile hemangioma. *Pediatr Clin North Am* 57(5):1069-1083, 2010
- Iannelli A, Lupi G, Castagna M, Valleriani A, Becherini F: Intramedullary capillary hemangioma associated with hydrocephalus in an infant. *J Neurosurg* 103 Suppl 3:272-276, 2005
- Karikari IO, Selznick LA, Cummings TJ, George TM: Spinal capillary hemangioma in infants: report of two cases and review of the literature. *Pediatr Neurosurg* 43(2):125-129, 2007
- Mawk JR, Leibrock LG, McComb RD, Trembath EJ: Metameric capillary hemangioma producing complete myelographic block in an infant. Case report. *J Neurosurg* 67(3):456-459, 1987
- Morais BA, Cardeal DD, Ribeiro E, Ribeiro R, Frassetto FP, Andrade FG, Matushita H, Teixeira MJ: Hydrocephalus: A rare initial manifestation of sporadic intramedullary hemangioblastoma: Intramedullary hemangioblastoma presenting as hydrocephalus. *Childs Nerv Syst* 33(8):1399-1403, 2017
- Rahyussalim AJ, Situmeang A, Safri AY, Fadhly ZI: Intradural intramedullary mixed type hemangioma: Optimizing the surgical management through intraoperative neurophysiological monitoring. *Case Rep Surg* 2015:984982, 2015
- Schwartz HG: Congenital tumors of the spinal cord in infants. *Ann Surg* 136(1):183-192, 1952
- Sivrikoz TS, Has R, Esmer AC, Kalelioglu I, Yuksel A, Taskin OC: Prenatal diagnosis of tethered spinal cord associated with sacrococcygeal teratoma. *J Clin Ultrasound* 44(8):506-509, 2016
- Smith AB, Soderlund KA, Rushing EJ, Smirniotopolous JG: Radiologic-pathologic correlation of pediatric and adolescent spinal neoplasms: Part 1, Intramedullary spinal neoplasms. *Am J Roentgenol* 198(1):34-43, 2012
- Vaishya S, Chauhan A, Patir R, Gupta RK: Intramedullary capillary hemangioma presenting with hydrocephalus and spastic paraparesis in 2-month-old infant. *World Neurosurg* 125:451-455, 2019