Turk Neurosurg, 2023

Original Investigation

DOI: 10.5137/1019-5149.JTN.41572-22.3

Received: 10.07.2022
Accepted: 29.09.2022

Published Online: 04.01.2023

Topographical Anatomy of the Superficial Temporal Artery

Tugba MORALI GULER[1], Ayhan COMERT[2], Yigit GUNGOR[2], Yahya Efe GUNER[3], Yagiz Emre SAYACI[4], Ali Can KORKMAZ[2], Ela COMERT[5], Gokmen KAHILOGULLARI[6]

[1]Karabuk University, School of Medicine, Department of Neurosurgery, Karabuk, Turkey
[2]Ankara University, School of Medicine, Department of Anatomy, Ankara, Turkey
[3]Yuksek Ihtisas University School of Medicine, Department of Neurosurgery, Ankara, Turkey
[4]Ankara Memorial Hospital, Department of Neurosurgery, Ankara, Turkey
[5]Kirikkale University School of Medicine, Department of Otolaryngology, Kirikkale, Turkey
[6]Ankara University School of Medicine, Department of Neurosurgery, Ankara, Turkey

Corresponding author: Gokmen KAHILOGULLARI ✉ gokmenkahil@hotmail.com

ABSTRACT

AIM: To describe in detail the gross anatomy of the superficial temporal artery (STA), its course and branches, its relationships with the branches of the facial nerve, and certain anatomical and surgical landmarks to preserve these structures in daily neurosurgical practice and use the STA during revascularization surgery.

MATERIAL and METHODS: This cadaveric study was conducted on 16 cadaver heads bilaterally, in which 32 silicon/latex-injected STAs were dissected using a microdissection technique in a neuroanatomy laboratory. The distances between the facial nerve, tragus, STA, superficial temporal vein (STV), and imaginary lines created between important anatomical landmarks were measured. The curvilinear lengths of STA and STV were also measured.

RESULTS: The average distances of the most posteriorly located branch of the facial nerve to the frontal region and the tragus at the midpoint of zygoma in the horizontal plane, at the superior border of the zygoma and at the level of the superior border of the parotid gland, were measured as 25.39, 29.84, and 15.56 mm, respectively. The average distance directly measured between the tragus and STA was 39.29 mm, and that between the tragus and STV was 20.26 mm. The average curvilinear lengths of the frontal and parietal branches of STA were 97.63 and 96.45 mm, respectively.

CONCLUSION: Understanding the clinical anatomy of the STA and its branches and its relationships with other structures is of critical importance for a successful and noncomplicated surgery. Our findings will be useful not only for surgical approaches such as pterional craniotomy and orbitozygomatic approaches but also for cerebral revascularization.

KEYWORDS: Anatomy, Cadaver, Anatomic study, Superficial temporal artery, Superficial temporal vein

INTRODUCTION

The superficial temporal artery (STA), one of the terminal branches of the external carotid artery, supplies the face, scalp, auricle, tragus, lobule, parotid gland and duct, muscles as masseter, temporalis, orbicularis, and external acoustic meatus with some branches of the external carotid artery (3,11). It enters and courses deep into the parotid gland posterior to the ramus of the mandible immediately after its origin. After exiting the gland, it passes superficially over the zygomatic arch. It often divides into an anteriorly located frontal branch and a posteriorly located parietal branch above the zygomatic arch, but sometimes this bifurcation is at the level of the zygomatic arch or just below this level (3,8,9,18). However, surgeons avoid using this segment of the artery as a graft because of the close relationship of the STA with the facial nerve above the zygomatic arch (9). The superficial temporal vein (STV) runs in close relation to the artery and the parietal and frontal branches of the STA and is commonly

Tugba MORALI GULER : 0000-0003-1083-1601
Ayhan COMERT : 0000-0002-9309-838X
Yigit GUNGOR : 0000-0002-9134-8066
Yahya Efe GUNER : 0000-0001-9660-5941
Yagiz Emre SAYACI : 0000-0002-9397-3834
Ali Can KORKMAZ : 0000-0002-2217-9326
Ela COMERT : 0000-0001-7739-2717
Gokmen KAHILOGULLARI : 0000-0001-8137-0510

accompanied by thin communicating veins that originate from the STV (8).

The facial nerve exits through the stylomastoid foramen and lies within the fatty tissue deep into the middle of the anterior border of the mastoid process. Then, it courses anterolaterally over the mandibular ramus into the substance of the parotid gland. It divides into five major branches in the parotid gland cervical, marginal mandibular, buccal, zygomatic, and frontotemporal branches. Understanding the course of the facial nerve is of critical importance as any damage may cause paralysis of important muscles such as the frontal, orbicularis oculi, and corrugator supercilii muscles (1,12,18). Preservation of the facial nerve and its branches is important during pterional craniotomy and orbitozygomatic approaches (10). Conversely, during cerebral revascularization surgical procedures (for moyamoya disease or extracranial–intracranial bypass when treating certain types of aneurysms), the STA plays a major role as it is one of the most commonly used donor vessels (9,13,15). The zygomatico-orbital artery branches from the STA and provides the blood supply of suprazygomatic territory (5,6).

Preserving the STA and its branches and the facial nerve and its branches in daily neurosurgical practice and the usage of STA during revascularization surgery can be accomplished by understanding the detailed anatomy of these important structures. This study investigated the detailed gross anatomy of the STA, its course and branches, its relationships with the branches of the facial nerve, especially around the zygomatic arch, and certain anatomical and surgical landmarks.

MATERIAL and METHODS

A total of 16 cadaver heads were examined bilaterally (including 32 STAs) that were dissected at the Department of Anatomy, Ankara University School of Medicine. Specimens with no history of trauma or pathology of the central nervous system were included. All dissections were performed in cadavers with silicon (or latex)-injected arteries using the microdissection technique, which was performed using microsurgical tools under a microscope (Zeiss-Opmi-Vario, Germany). All morphometric measurements were conducted by the same teams using calipers with a precision of 0.01 mm (Digital caliper Mitutuyo). A modified frontotemporal incision extending under the tragus to the level of the angle of the mandible was performed in all specimens, after which the STA and the facial nerve were followed and dissected until the end of all branches. The transverse facial artery and the auricular branches were observed. The zygomatico-orbital arteries were identified.

The following parameters were measured in this study: the distance between the most posteriorly located branch of the facial nerve to the frontal region, except for the branch that stimulates the temporal muscle, and the tragus at the midpoint of zygoma in the horizontal plane (a1), at the superior (a2) and inferior (a3) borders of the zygoma, and at the level of the superior border of the parotid gland (a4).

An imaginary line was created between the tragus and the point where the superior temporal line and the orbital rim meet. The distance of the STA (b1) and the STV (b2) bifurcation to this line and the distance between the frontal branch at the midpoint of zygoma in the horizontal plane and this line (b3) were measured.

The distance directly measured between the tragus and STA (c1) and STV (c2) and the curvilinear distance (the actual distance) of the frontal (d1) and parietal (d2) branches of the STA were measured. The distance between the most posteriorly located branch of the facial nerve to the frontal region, except for the branch that stimulates the temporal muscle, and the STA at the midpoint of zygoma in the horizontal plane (e) was measured.

An imaginary line was created between the superior attachment point of the ear with the skin and the point where the superior temporal line and the orbital rim meet. The distance of the STA bifurcation to this line with a 90angle (f1), the distance of the most posteriorly located branch of the facial nerve to the frontal region, except for the branch that stimulates the temporal muscle to this line at the level of the midpoint of zygoma in the horizontal plane (f2), and the distance of the STV bifurcation to this line with a 90 angle (f3) were measured.

Finally, another imaginary line was created between the tragus and lateral canthus. The distance of the STA (g1) and STV (g2) to this line with a 90angle and the distance of the most posteriorly located branch of the facial nerve to the frontal region, except for the branch that stimulates the temporal muscle to this line at the level of midpoint of zygoma in the horizontal plane, (g3) were measured.

Measurements were performed for the trunk of the zygomatico-orbital artery: the distance between zygomatico-orbital artery and the tragus (i1), between the zygomatico-orbital artery and the upper border of the zygomatic arch (i2), and between the zygomatico-orbital artery and the superior border of the basis of the temporal process of the zygomatic bone (i3) were used to show the course of the zygomatico-orbital artery as measured before in another anatomical study (6).

All data were analyzed using SPSS (version 20; SPSS, Chicago, IL, USA). Descriptive data were summarized as mean and standard deviation (std). (Figure 1A–C and Figure 2A, B).

RESULTS

The average distance between the most posteriorly located branch of the facial nerve to the frontal region, except for the branch that stimulates the temporal muscle, and the tragus at the midpoint of zygoma in the horizontal plane (a1) was 25.39 mm (range: 20.93–30.67 mm). The average distance between the most posteriorly located branch of the facial nerve to the frontal region, except for the branch that stimulates the temporal muscle, and the tragus at the superior border of the zygoma (a2) was 29.84 mm (range: 26.44–32.23 mm), and the same distance at the inferior (a3) border of the zygoma was 23.83 mm (range: 18.76–29.62 mm). The average distance between the most posteriorly located branch of the

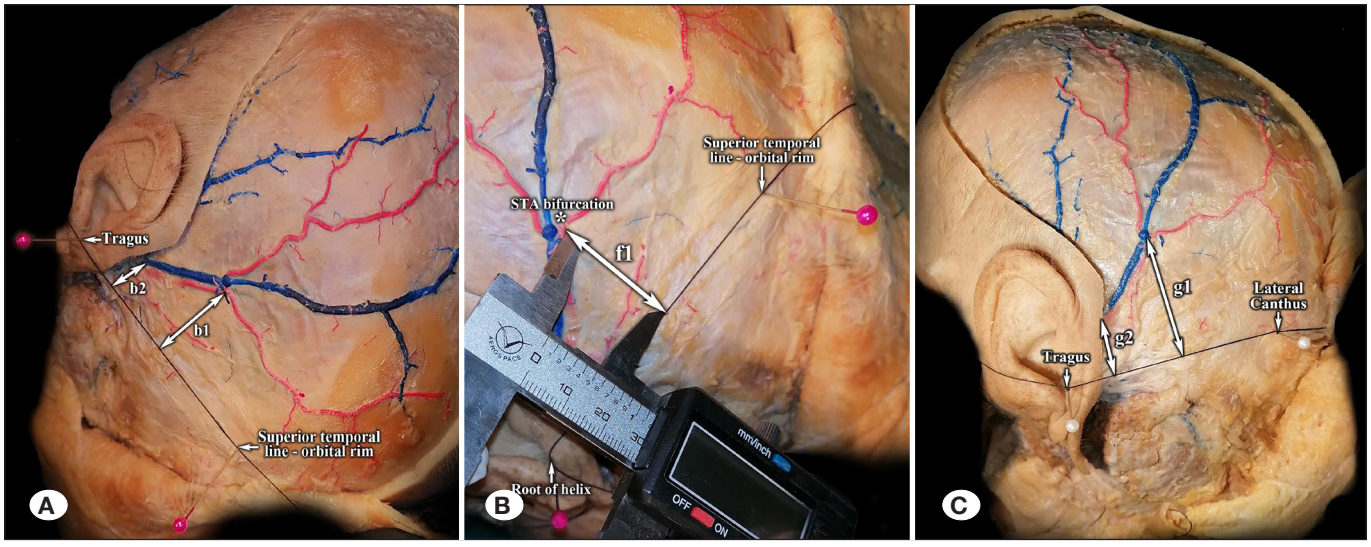

Figure 1A-C: Measurements were performed based on three imaginary lines. These lines and the measurements according to these lines are illustrated. All abbreviations concerning measurements are the same as those mentioned in the text and in Table I.

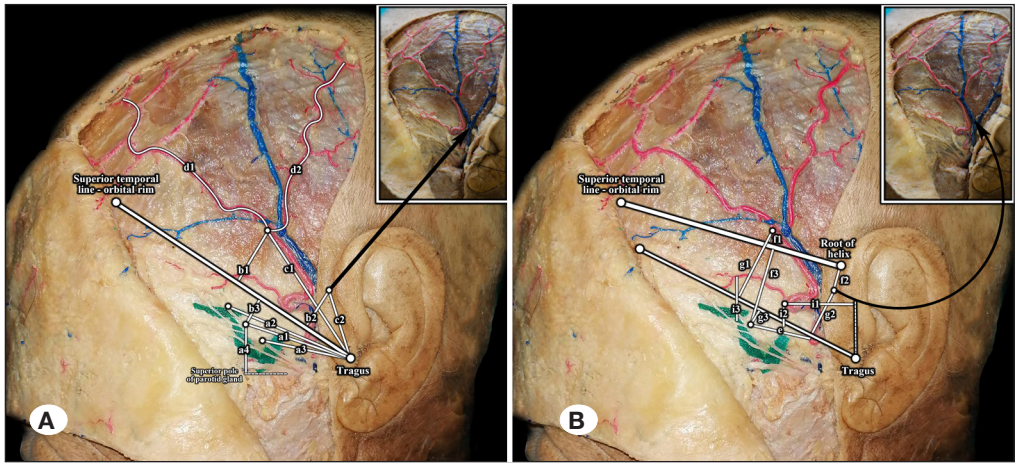

Figure 2A, B: Measurements shown in Table I are demonstrated. Bifurcation of STV (superficial temporal vein) was not clearly visible; hence, it is indicated by picture-in-picture. All abbreviations concerning measurements are the same as those mentioned in the text and in Table I.

facial nerve to the frontal region, except for the branch that stimulates the temporal muscle, and the tragus at the level of the superior border of the parotid gland (a4) was 15.56 mm (range: 9.99–22.47 mm).

After the creation of the imaginary line between the tragus and the point where the superior temporal line and the orbital rim meet, the average distance of the STA (b1) was 20.95 mm (range: 5.81–41.86 mm), and the average distance of the STV (b2) bifurcation to this line was 13.01 mm (range: 10.69–14.49 mm). Finally, the average distance between the frontal branch at the midpoint of zygoma in the horizontal plane and this line (b3) was 4.85 mm (range: 0.01–10.32 mm).

The average distance directly measured between the tragus and STA (c1) was 39.29 mm (range: 21.28–54.01 mm), and the distance between the tragus and STV (c2) was 20.26 mm (range: 14.12–24.55 mm). The average curvilinear distances (the actual distance) of the frontal (d1) and parietal (d2) branches of STA were 97.63 mm (range: 55.47–175.11 mm) and 96.45 mm (range: 44.69–181.65 m), respectively. The average distance between the most posteriorly located branch of the facial nerve to the frontal region, except for the branch that stimulates the temporal muscle and STA at the midpoint of zygoma in the horizontal plane (e), was 9.83 mm (range: 7.42–12.49 mm).

After the creation of the imaginary line between the superior attachment point of the ear with the skin and the point where the superior temporal line and the orbital rim meet, the average distance of the STA bifurcation to this line with a 90angle (f1) was 11.01 mm (range: 0.01–19.34 mm), the distance of the most posteriorly located branch of the facial nerve to the frontal region, except for the branch that stimulates the temporal muscle to this line at the level of the midpoint of zygoma in the horizontal plane (f2), was 25.62 mm (range: 10.47–36.3 mm), and the distance of the STV bifurcation to this line with a 90angle (f3) was 16.78 mm (range: 10.89–20.25 mm).

After the creation of the imaginary line between the tragus and lateral canthus, the average distances of STA (g1) and STV (g2)

to this line with a 90° angle were 27.21 mm (range: 7.47–48.02 mm) and 14.44 mm (range: 2.03–20.64 mm), respectively. The average distance of the most posteriorly located branch of the facial nerve to the frontal region, except for the branch that stimulates the temporal muscle to this line at the level of midpoint of zygoma in the horizontal plane (g3), was 1.23 mm (range: 0.01–5.12 mm). The transverse facial artery and the auricular branches running to the helix and tragus existed in all cadaver specimens. The zygomatico-orbital arteries were identified in 27 specimens (from the total 32 STAs, 84.37%). Only two zygomatico-orbital arteries originated from the frontal branch of STA. The mean diameter of the zygomatico-orbital artery was 1.14 ± 0.3 mm. The distance between zygomatico-orbital artery origin and midpoint of the tragus was 11.71 ± 6.12 mm anteriorly (i1). The distance between the zygomatico-orbital artery and the upper border of the zygomatic arch (i2) and between the zygomatico-orbital artery and the superior border of the basis of the temporal process of the zygomatic bone (i3) was 15.24 ± 4.1 (i2) mm and 20.87 ± 6.09 (i3) mm, respectively. Injection into this zone is not recommended and to be careful will minimize vascular complications during procedures. (Table I, Figures 1-4).

DISCUSSION

In the temporal region, two branches of the facial nerve; that is temporal and zygomatic branches, have complex anatomy. Here facial nerve branches coursed through multiple layers of fascia and fat tissue (4,11). In the temporal region of the temporal muscle and scalp, three separate layers of fat were described by Coscarella et al. The first layer is in the subgaleal plane named the suprafascial fat pad which lies just over the most superficial fascia of the temporalis. The second layer is the interfacial fat pad which is between the superficial and deep fascial layers of the temporalis. The subfascial fat pad is the third layer which is located under the deepest fascial layer of temporalis (4).

Yaşargil et al described the preservation of the frontotemporal branch of the facial nerve using the interfacial technique during pterional craniotomy (18). Before this description, frontalis muscle palsy had been reported in approximately 30% of patients when the subgaleal elevation of the scalp flap was performed with the elevation of the temporalis separately (12). Temporal branches to the frontalis course in the loose areolar tissue under the superficial layer of the temporal fascia, this was not a rare complication (12,18). It is known that the use of the interfacial technique has reduced the incidence of frontalis palsy significantly. However, in daily practice, this complication can still occur. Hence, it is extremely important to understand the detailed anatomy of this region to reduce the occurrence of this complication.

The STA has been used for various procedures such as extracranial–intracranial bypass, biopsy for diagnosing temporal arteritis, and various reconstructive surgeries (11,13,15,16,17). Moreover, the STA is extremely important by itself as it supplies blood to half of the parotid gland, the posterior half of the temporomaxillary joint, the entire horizontal portion of the scalp, and the entire upper lateral half of the face (11). In this regard, it is critically important to understand the anatomy of the STA and its branches and its relationships with other structures such as the STV and the frontal branch of the facial nerve for a successful and noncomplicated surgery.

Marano et al. were examined this issue comparatively (7). As described in this study, Romanes stated that the bifurcation of the STA was 2.5 cm above the zygoma and Krayenbuhl and Yaşargil explained that the STA bifurcation was 2–3 cm above the zygomatic arch, whereas Gray and Goss explained it as being 5 cm above the zygoma. Furthermore, Marano et al stated that the bifurcation of the STA was at the level of the zygoma in two specimens, but they detected no bifurcation below the zygomatic arch in any of the specimens. Stock et al reported that the bifurcation of the artery was above the zygomatic arch in 60% of cases, whereas Chen et al reported the same finding in 86.5% of cases (2,14). Similarly, Pinar and Govsa reported that the bifurcation points of the STA were above the zygomatic arch in 74.07% of specimens (11), whereas Cobb et al reported a higher rate of STA bifurcations of 96% occurring above the zygomatic arch (3).

In the study of Marano et al, the typical recipient angular branch of the Middle cerebral artery (MCA) was approximately 6 cm above the external auditory canal, so they believed

Table I: All Parameters Measured were Listed. All Abbreviations about Measurements were the Same in the Text

Parameters (mm)	a1	a2	a3	a4	b1	b2	b3	c1	c2	d1	d2
Mean value	25.39	29.84	23.83	15.56	20.95	13.01	4.85	39.29	20.26	97.63	96.45
Min-(std) Max	20.93 - 0.67	26.44 - 32.23	18.76 - 29.64	9.99 - 22.47	5.81 - 41.86	10.69 - 14.49	0.01 - 10.32	21.28 - 54.01	14.12 - 24.55	55.47 - 175.11	44.69 - 181.65

Parameters (mm)	e	f1	f2	f3	g1	g2	g3	h*	i1	i2	i3
Mean value	9.83	11.01	25.62	16.78	27.21	14.44	1.23	1.14	11.71	15.24	20.87
Min-(std) Max	7.42 - 12.49	0.01 - 19.34	10.47 - 36.3	10.89 - 20.25	7.47 - 48.02	-2.03 - 20.64	0.01 - 48.02	(0.3)	(6.12)	(4.1)	(6.09)

Min: *Minimum value,* ***Max:*** *Maximum value,* ***std:*** *Standard deviation value.*

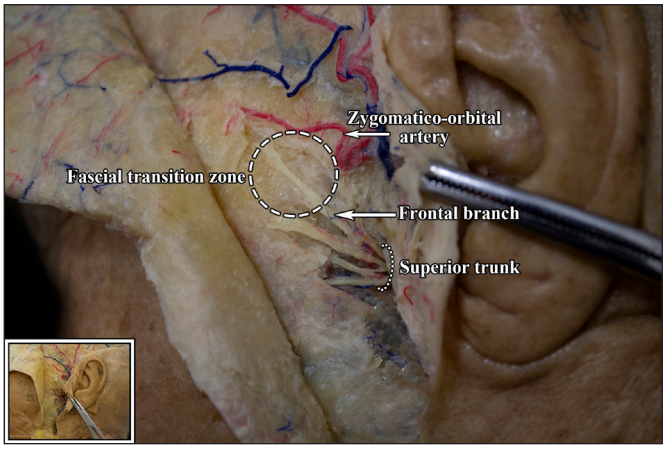

Figure 3: The course of the frontal branch of the facial nerve on the left side of the face is shown. Dashed lined ring indicates the fascial transitional zone of the frontal branch of the facial nerve on the zygomatic arch. The dotted line half-ring indicates the superior trunk of the facial nerve, which is also shown in picture-in-picture.

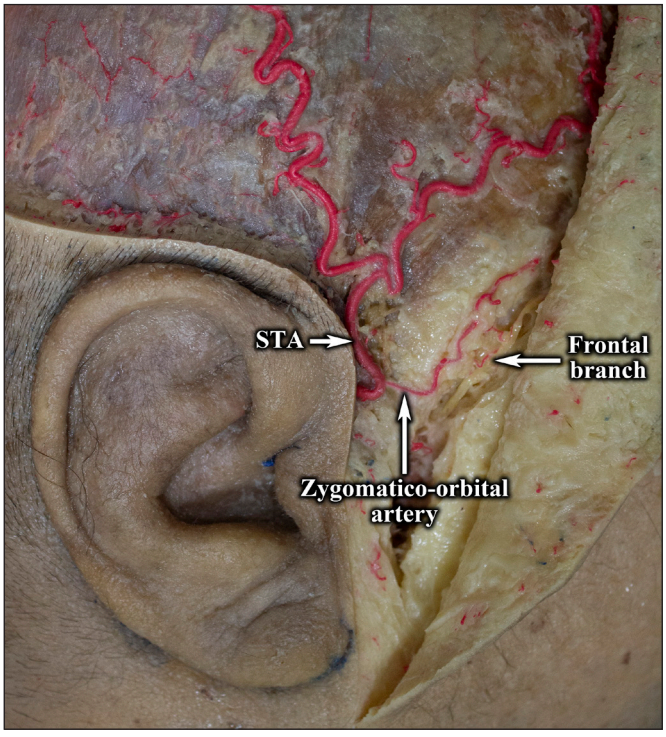

Figure 4: Close relationship between the zygomatico-orbital artery and the frontal branch of the facial nerve is shown on the right side of the face.

that the minimal working length of the STA should be 70 mm and found that a suitable frontal branch and a suitable parietal branch were present in 90% and 71% of patients, respectively (7). According to Pinar and Govsa, a suitable frontal branch and a suitable parietal branch were found in 89% and 78% of specimens, respectively (11). Knowledge of the arterial features of the lateral forehead region is essential for an aesthetic surgeon. Furthermore, the STA and its branches are suitable for use in microvascular anastomoses.

CONCLUSION

According to this study, the distance directly measured between the tragus and STA was approximately 40 mm, and that between the tragus and STV was approximately 20 mm. The distance between the zygomatico-orbital artery and the upper border of the zygomatic arch was approximately 15 mm and 20 mm superiorly to the superior border of the basis of the temporal process of the zygomatic bone, respectively. Injection into this zone is not recommended and being careful will minimize vascular complications. Moreover, the average distance between the most posteriorly located branches of the facial nerve to the frontal region, except for the branch that stimulates the temporal muscle and STA at the midpoint of zygoma in the horizontal plane, was approximately 10 mm.

These results might be important and appropriate for not only several surgical approaches such as pterional craniotomy and orbitozygomatic approaches but also cerebral revascularization procedures such as extracranial–intracranial bypass operations.

ACKNOWLEDGMENT

The authors sincerely thank those who donated their bodies to science so that anatomical research could be performed. Results from such research can potentially increase mankind's overall knowledge that can then improve patient care. Therefore, these donors and their families deserve our highest gratitude.

AUTHORSHIP CONTRIBUTION

Study conception and design: TMG, GK, EC, AC
Data collection: TMG, ACK, YES, EC, GK, AC
Analysis and interpretation of results: TMG, YES, YG, EC, GK, AC
Draft manuscript preparation: TMG, ACK, YES, EC, GK, AC
All authors (TMG, AC, YG, EG, YES, ACK, EC, GK) reviewed the results and approved the final version of the manuscript.

REFERENCES

1. Babakurban ST, Cakmak O, Kendir S, Elhan A, Quatela VC: Temporal branch of the facial nerve and its relationship to fascial layers. Arch Facial Plast Surg 12(1):16-23, 2010
2. Chen TH, Chen CH, Shyu JF, Wu CW, Lui WY, Liu JC: Distribution of the superficial temporal artery in the chinese adult. Plast Reconstr Surg 104(5):1276-1279, 1999
3. Cobb MIPH, Galvin L, Gonzalez LF: Superficial temporal artery: The "C" shape half-buttonhole configuration as it courses over the zygomatic arch. Surg Radiol Anat 38(4):493-495, 2016
4. Coscarella E, Vishteh AG, Spetzler RF, Seoane E, Zabramski JM: Subfascial and submuscular methods of temporal muscle dissection and their relationship to the frontalis branch of the facial nerve. J Neurosurg 92(5):877-880, 2000

5. Higashino T, Sawamoto N, Hirai R, Arikawa M: Zygomatico-orbital artery as a recipient vessel for microsurgical head and neck reconstruction. J Craniofac Surg 24(4):e385-e387, 2013
6. Liu S, Yan W, Wang G, Zhao R, Qiu H, Cao L, Wang H: Topographic anatomy of the zygomatico-orbital artery: Implications for improving the safety of temporal augmentation. Plast Reconstr Surg 148(1):19-27, 2021
7. Marano SR, Fischer DW, Gaines C, Sonntag VK: Anatomical study of the superficial temporal artery. Neurosurgery 16(6): 786-790, 1985
8. Medved F, Manoli T, Medesan R, Janghorban Esfahani B, Stahl S, Schaller HE, Brodoefel H, Ernemann U, Korn A: In vivo analysis of the vascular pattern of the superficial temporal artery based on digital subtraction angiography. Microsurgery 35(5):380-386, 2015
9. Meybodi AT, Lawton MT, El-Sayed I, Davies J, Tabani H, Feng X, Benet A: The infrazygomatic segment of the superficial temporal artery: Anatomy and technique for harvesting a better interposition graft. Oper Neurosurg (Hagerstown) 13(4): 517-521, 2017
10. Meybodi AT, Lawton MT, Yousef S, Sánchez JG, Benet A: Preserving the facial nerve during orbitozygomatic craniotomy: Surgical anatomy assessment and stepwise illustration. World Neurosurg 105: 359-368, 2017
11. Pinar YA, Govsa F: Anatomy of the superficial temporal artery and its branches: its importance for surgery. Surg Radiol Anat 28(3): 248-253, 2006
12. Poblete T, Jiang X, Komune N, Matsushima K, Rhoton, AL: Preservation of the nerves to the frontalis muscle during pterional craniotomy. J Neurosurg 122(6):1274-1282, 2015
13. Schirmer CM, David CA: Superficial temporal artery dissection: A technical note. Oper Neurosurgery 72(1):6-8; discussion 8, 2013
14. Stock AL, Collins HP, Davison TM: Anatomy of the superficial temporal artery. Head Neck Surg 2(6):466-469, 1980
15. Tamura Y, Aoki A, Yamada Y, Nonoguchi N, Yagi R, Tucker A, Kuroiwa T: Dissection of both frontal and parietal branches of the superficial temporal artery for bypass surgery through a single linear skin incision. Acta Neurochir (Wien) 153(8):1645-1648, 2011
16. Tayfur V, Edizer M, Magden O: Anatomic bases of superficial temporal artery and temporal branch of facial nerve. J Craniofac Surg 21(6):1945-1947, 2010
17. Upton J, Rodgers C: Free parietotemporalis fascial flap. In: Strauch B, Vasconez LO, Hall-Findlay EJ (eds), Grabb's Encyclopedia of Flaps. Philadelphia, PA: Lippicott-Raven, 1998: 285:117Y21
18. Yasargil MG, Reichman MV, Kubik S: Preservation of the frontotemporal branch of the facial nerve using the interfascial temporalis flap for pterional craniotomy. Technical article. J Neurosurg 67(3):463-466, 1987