

# Results of Intraoperative Sodium Fluorescein Video Angiography and Its Repeated Use in a Series of Brain Aneurysm Surgeries

Lutfi Sinasi POSTALCI, Buruc ERKAN

Healty Sience Universty, Basaksehir Cam and Sakura City Hospital, Department of Neurosurgery, Istanbul, Turkey

**Corresponding author:** Lutfi Sinasi POSTALCI ✉ [lutfup@gmail.com](mailto:lutfup@gmail.com)



To watch the surgical videoclip, please visit <http://turkishneurosurgery.org.tr/uploads/jtn-42655-video.mp4>

## ABSTRACT

**AIM:** To present the properties of NaF-V use in intracranial aneurysm surgery and to discuss the limitations of repeated NaF-V administration.

**MATERIAL and METHODS:** The clinical findings and imaging results during and after surgery for patients with aneurysm who underwent surgery between September 2020 and June 2022 were examined. NaF-V and micro-Doppler imaging were used to control the flow of the parent and perforating arteries and obliteration of the aneurysm dome. The dose of sodium fluorescein administered via the central venous route was 5 mg/kg.

**RESULTS:** Overall, 102 aneurysms were treated during 95 operations in 92 patients. NaF-V was applied at least once in all operations, twice in 17, and thrice in 3 operations. The period between repeated doses of NaF-V ranged from 4 to 50 min. The method allowed for the desired imaging of the parent and perforating arteries in all cases but failed to provide satisfactory results regarding the complete obliteration of the aneurysm dome in three cases. No NaF-V-related complications were encountered in any case.

**CONCLUSION:** Sodium fluorescein is safe, with a high minimum toxic dosage, and provides benefits, even in repeated use, in the evaluation of perforating and parent arteries. NaF-V is effective when used alternatively or in combination with various methods.

**KEYWORDS:** Aneurysm, Brain surgery, Sodium fluorescein video angiography

**ABBREVIATIONS:** CT: Computed tomography, DSA: Digital subtraction angiography, GCS: Glasgow Coma Scale, ICG-V: Indocyanine green video angiography, NaF-V: Sodium fluorescein video angiography

## INTRODUCTION

The most significant complication of intracranial aneurysm surgery is improper clipping (13,15,24,26). Partial or complete blockage of a parent artery or perforating arteries adjacent to an aneurysm and other arteries by clipping may result in cerebral infarction and neurological morbidity

(3,7,23,26). The patency of the parent and perforating arteries branching near the aneurysm requires evaluation (19,25). There are several methods available for this purpose that utilize conventional cerebral arteriography, micro-Doppler imaging, somatosensory evoked potential/motor evoked potential (SEP/MEP) monitoring, or video angiography with the use of

various agents such as sodium fluorescein or indocyanine green that show intravascular coagulation (6). Intraoperative digital subtraction angiography (DSA) is considered the gold standard. However, intraoperative DSA is time-consuming, not always readily available (11), and carries the potential risk of vascular injuries (8).

Direct visual assessment of vascular flow using fluorescein dye has been practiced, and the most prevalent application thereof is the evaluation of the ocular fundus via intravenous fluorescein in various retinal disorders (16). Cerebral fluorescein angiography, developed by Feindel et al. (5), is also used to treat cerebral aneurysms (26). Suzuki et al. published the first report discussing sodium fluorescein video angiography (NaF-V) (24). Although some studies and clinical series focusing on the use of NaF-V in clip ligation for intracranial aneurysm surgery have been published (9,11,12,14,15,19,25) there are still ongoing discussions about the advantages and disadvantages thereof. While studies have emphasized the advantages in aneurysm surgeries in relation to the imaging of perforating arteries, others have indicated that the application areas are limited, especially in venous use (13,14).

We aimed to discuss the findings related to NaF-V use for intracranial aneurysm surgery, focusing on the radiological and clinical results. We also present the advantages and disadvantages of the repeated use of NaF-V.

## ■ MATERIAL and METHODS

We included patients who underwent microsurgical clipping using NaF-V in our clinic for the treatment of intracranial aneurysms. A total of 95 patients with aneurysms who underwent surgery between September 2020 and June 2022 were included. Following approval of this study by the ethics committee of our institution (No. 202259), all data were prospectively obtained, and video footage of all operations was recorded and reviewed by the surgical team.

### Surgical Procedure

Indications for microsurgical clipping were decided by the interventional radiology team of our institution. Four-dimensional DSA was performed in all patients for preoperative diagnostic purposes. Conventional pterional craniotomy was used for anterior system aneurysms, and central craniotomy, allowing for an interhemispheric approach, was used for distal anterior cerebral artery aneurysms. After the aneurysm was clipped, the optimum clip position was confirmed by surgical observation and micro-Doppler imaging (Hadeco, Inc., Kawasaki, Japan), and the microscope was switched to an FL560 module.

A Leica 530 OH-X surgical microscope, equipped with an FL560 integrated fluorescence module (Leica Microsystems GmbH, Wetzlar, Germany), was used for all operations. The FL560 module was tuned for excitation at 460-500 nm and for an emission range consisting of green, yellow, and red spectra in the spectral band at approximately 510 nm. Two different modes of video recording were applied, without changing the ocular vision of the microscope.

The gold standard for verifying the aneurysm was puncture obliteration using a needle or cutting off part of the dome. Brain computed tomography (CT) images were taken postoperatively (within 2-6 hours following the operation) in all cases to eliminate the possibility of any complications or asymptomatic structural changes, such as silent stroke or contusions, as well as to acquire fundamental postoperative images for future comparisons. During the postoperative follow-up, brain CT, magnetic resonance imaging brain diffusion sequences, and computed perfusion tomography were evaluated according to clinical requirements. DSA is preferred to evaluate aneurysmal rest, parent artery occlusion, and stenosis in all patients. In 30 cases, CT brain angiography was preferred for various reasons such as DSA being invasive and carrying the potential for complications, the patient being prone to thrombosis, development of complications in previous DSA, poor general condition of the patient (low Glasgow Coma Scale [GCS] score), and/or the patient not consenting.

### NaF-V procedure

The anesthesia team preoperatively catheterized all patients. Bolus sodium fluorescein was administered to all patients using a central venous catheter. The maximum dose administered to patients was 20 mg/kg (29), and a dose of 5 mg/kg was used for each application during the operation.

## ■ RESULTS

A total of 92 patients (average age 49.9 [29-70] years) were admitted to our hospital with a diagnosis of spontaneous subarachnoid hemorrhage (sSAH) (n=72 [78%]) or incidental intracranial aneurysm (IIA) (n=20 [22%]). In total, 102 aneurysms were treated with 95 surgeries during the study period (Table I). Clinical scoring of the patients with sSAH was performed using the World Federation of Neurological Surgeons Grading System and the Hunt and Hess Scale, and radiological scoring was performed using the modified Fisher scale (Table II). The number of aneurysms that the patients had, and their locations were also recorded (Table III), as were the modified Rankin scores at the end of the average follow-up period of 267 days (Table IV). Aneurysm rests were detected on CT angiography and/or DSA images of five patients after surgery. However, when 3D images without subtraction were examined, none of the rests were located distal to the clip. The causes for aneurysm rests were identified as; inadequate images of aneurysm configurations, posterior communicating artery and anterior communicating artery aneurysms, and/or insufficient remodeling of the aneurysm dome due to parent or perforating artery origin. Of the patients with rests, one patient was re-operated on, and four patients were electively treated with a stent and/or coil by the endovascular team, as the hemorrhagic part of the aneurysm was closed.

One patient with a modified Rankin score of 6 also had Fisher grade 4 sSAH, as seen on CT imaging. The patient presented with an initial GCS score of 14, which slightly improved to a GCS score of 14-15 post microsurgical clipping. The patient developed vasospasm at the 16<sup>th</sup> postoperative hour,

**Table I:** Demographics and Aneurysm Characteristics of Patients

Characteristics	Value
Total number of patients	99
Patient age; range (mean), years	29-70 (49,9)
Patient sex; female/male	53/46
Total number of aneurysms	111
Ruptured/unruptured cases	26/77
Multiple/single aneurysms	27/72
Follow-up period of patients; range (mean), days	6-620 (267)

**Table II:** Frequency of Patient Clinical Evaluation Scores

Score	Modified Fisher	Hunt & Hess	WFNS
0	23	24	24
1	23	20	26
2	1	31	30
3	34	13	5
4	18	7	9
5	-	4	5

Values represent number of patients.

**WFNS:** World Federation of Neurological Surgeons.

**Table III:** Aneurysm Location

Aneurysm location	No. patients	%
Anterior communicating artery	40	36
Middle cerebral artery bifurcation/trifurcation	40	36
Middle cerebral artery - M1 branches	2	1.8
Middle cerebral artery - M2 branches	6	5.4
Posterior communicating artery	10	9.1
Internal carotid artery - proximal	5	4.5
Internal carotid artery - distal	1	0.9
Anterior cerebral artery – A1 branches	3	2.7
Anterior cerebral artery – A2 branches	3	2.7
Anterior choroidal artery	1	0.9
Total	111	100

**Table IV:** Patient Modified Rankin Scores

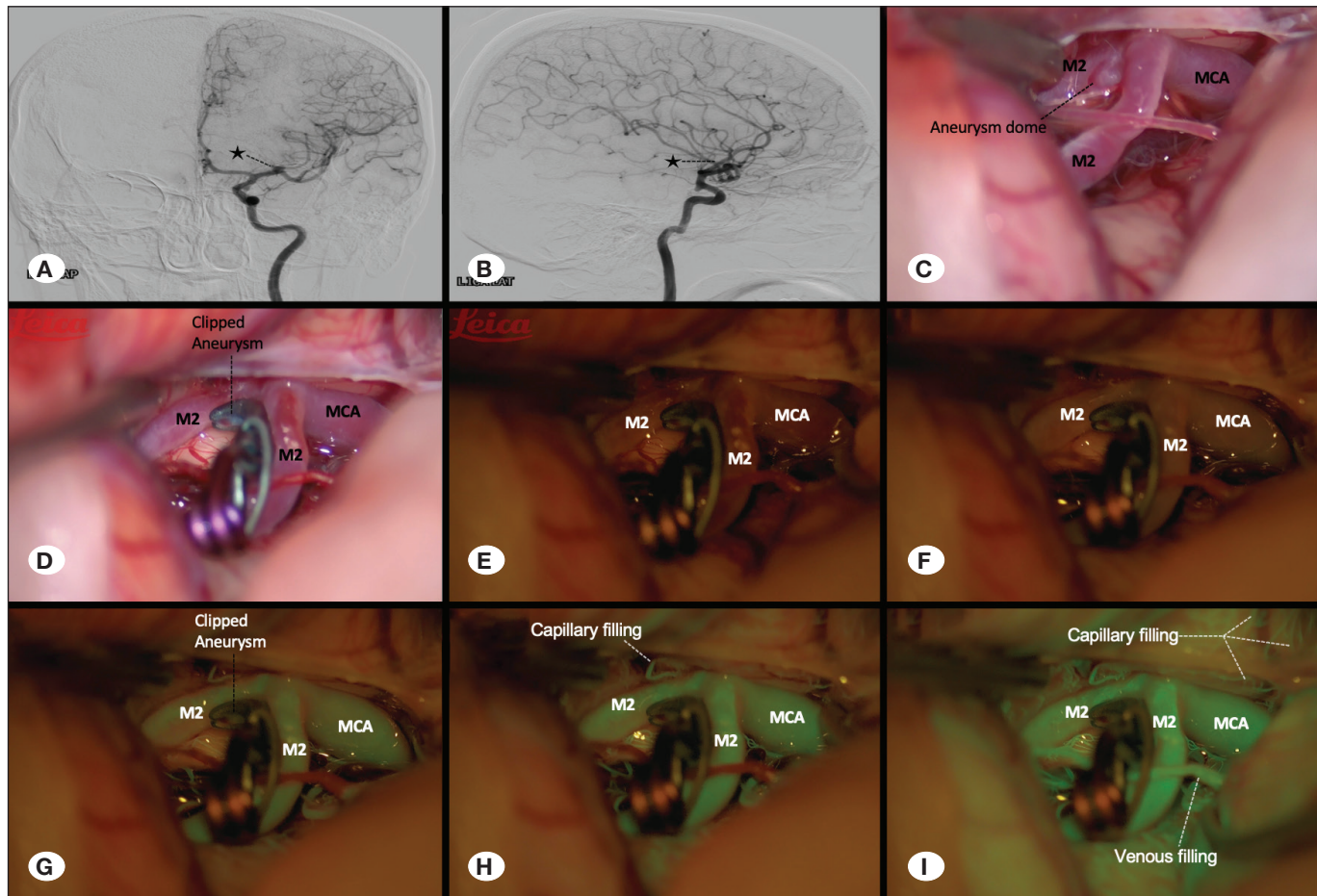
mRS score	No. patients
0	78
1	8
2	2
3	4
4	1
5	5
6	5

**mRS:** Modified Rankin score.

confirmed using DSA, and underwent intra-arterial nimodipine and balloon angioplasty, as vasospasm can result in death due to secondary infarcts. Another patient admitted to our clinic had a GCS score of 12, which decreased to 7 within the short period of time before the diagnostic DSA procedure could be done. The patient rapidly regressed, and rebleeding was detected, after which the patient underwent surgery but died during postoperative follow-up.

NaF-V was applied at least once in all operations (Figure 1, Video 1), twice in 17 operations, and three times in two operations. The time range to the second usage of NaF-V during operations with multiple usages was 4-50 min (Figure 2). The desired imaging of the parent and perforating arteries was achieved in all patients. In surgeries for two PComm aneurysms, a weaker fluorescence glow was achieved because of the strong fluorescence staining of the tentorium, the wall being thick in the proximal segments of the internal carotid artery, and the calcified plaques being denser at this location (Figure 3). In 19 cases, we found that almost all the sodium fluorescein that leaked out was cleared from the tissues where the repeated use of NaF-V occurred more than 10 min after the initial dose. In cases where NaF-V was used again for less than 10 min, when we switched to fluorescent mode, fluorescent residues were observed on the vessel walls, brain parenchyma, and tentorium, and these residues caused weak flashes. The second and/or third use of intravascular sodium fluorescein within 10 min of the initial dosage, maintaining a stronger contrast than fluorescent residues in the surrounding tissues, showed that it could be used for flow control evaluation in the parent and perforating arteries even with repeated usage. This strong flash effect provided sufficient results in detecting the presence of flow, even in patients who were administered additional doses within 4-5 min (Figure 2,4,5).

In three patients, although no initial flow was detected in the dome after the first clipping of the aneurysm and administration of NaF-V, it was observed that there was flow after the dome wall was punctured, and it was evaluated as false negativity. The clips were revised accordingly. False positivity was detected in patients with a calcified dome wall who received multiple sodium fluorescein injections (Figure 6,7,8).



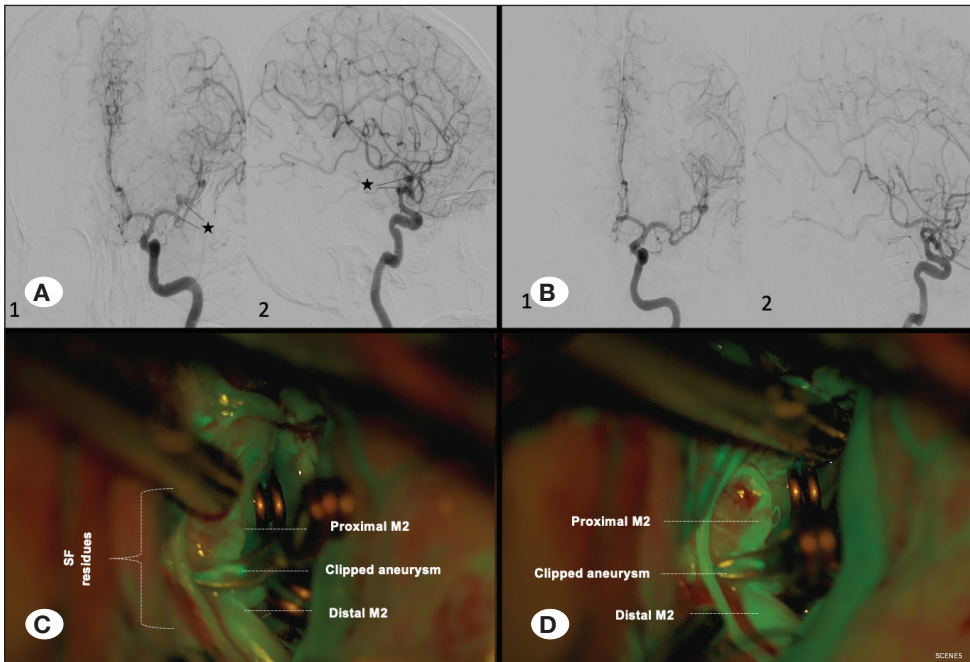
**Figure 1:** A 41-year-old female patient was operated on for an incidentally detected left middle cerebral artery (MCA) bifurcation aneurysm. Progression of sodium fluorescein in the vascular area was observed within seconds after aneurysm clipping (artery-capillary-vein). **A)** Preoperative digital subtraction angiography, anterior-posterior view (star; aneurysm). **B)** Preoperative digital subtraction angiography, lateral view (star; aneurysm). **C)** Morphology of aneurysm. **D)** Clipped MCA aneurysm. **E)** Basal filter image in parent arteries before sodium fluorescein injection. **F)** Early arterial phase after sodium fluorescein injection. **G)** Late arterial phase after sodium fluorescein injection. **H)** Early capillary phase after sodium fluorescein injection. **I)** Venous phase after sodium fluorescein injection (LICA AP, Left internal carotid artery anterior-posterior view; M1- M2, middle cerebral artery - M1- M2 branches; MCA, middle cerebral artery).

In one of our patients with internal carotid artery bifurcation aneurysm, although a temporary clip was placed distal to the choroidal artery, a postoperative choroidal artery infarction developed. It was thought that the temporary clip mobilized the atheroma plaque or that a thrombus close to the orifice of the choroidal artery was located more proximally. Three patients had a perforating artery infarction, which may have caused silent development with a close connection to the surgical corridor (medial lenticulostriate artery, frontobasal branch). For these patients, the perforating artery had to be sacrificed perioperatively or left in a clip and could not be dissected. In five cases, the clip was revised after it was found that the parent and perforating arteries were not stained with sodium fluorescein or were stained later than other arteries located closely (Figure 4). The second evaluation showed that flow was present. There was no unexpected perforation, occlusion of the parent artery, or stenosis in the postoperative control examinations.

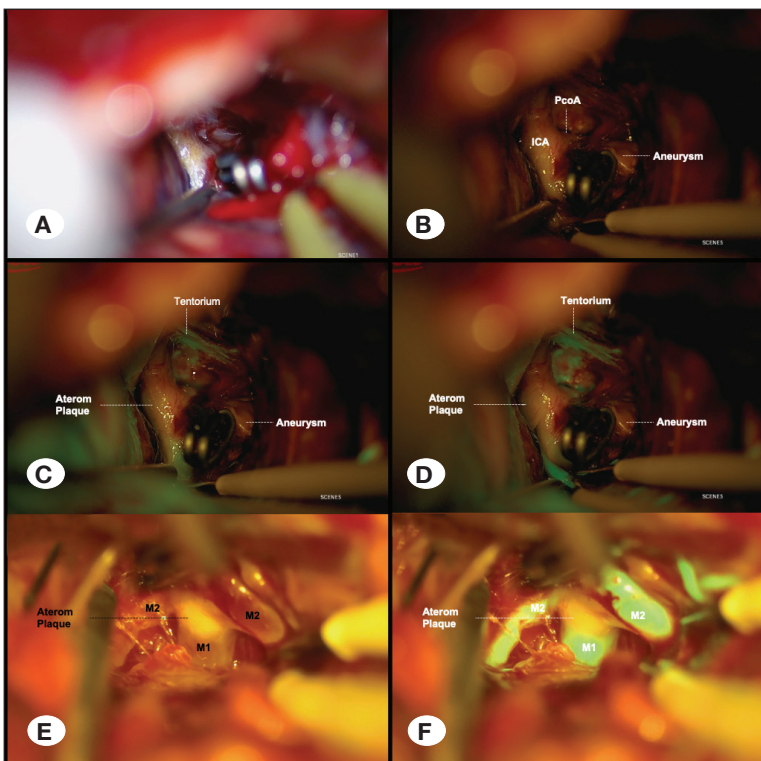
### Systemic Findings of Sodium Fluorescein

No patients in whom NaF-V was applied showed unexpected complications related to the technique. Yellow skin, a side effect of the administration of sodium fluorescein, was observed after administration of the compound, and the skin tone returned to its normal appearance in less than 72 hours. In addition, the urine color of the patients was green for approximately 48 hours. In the preoperative and postoperative periods, the daily renal function (urea and creatinine) and liver enzymes (aspartate aminotransferase, alanine aminotransferase, and gamma glutamyl transferase) of all patients were evaluated. No changes in dosage were made with the use of sodium fluorescein for any of the five patients with elevated liver enzymes or the four patients with impaired renal function in the preoperative period. One patient had severe renal failure in the preoperative period, and a total of 700 mg of sodium fluorescein was administered in two doses during the operation. The patient developed metabolic acidosis on the

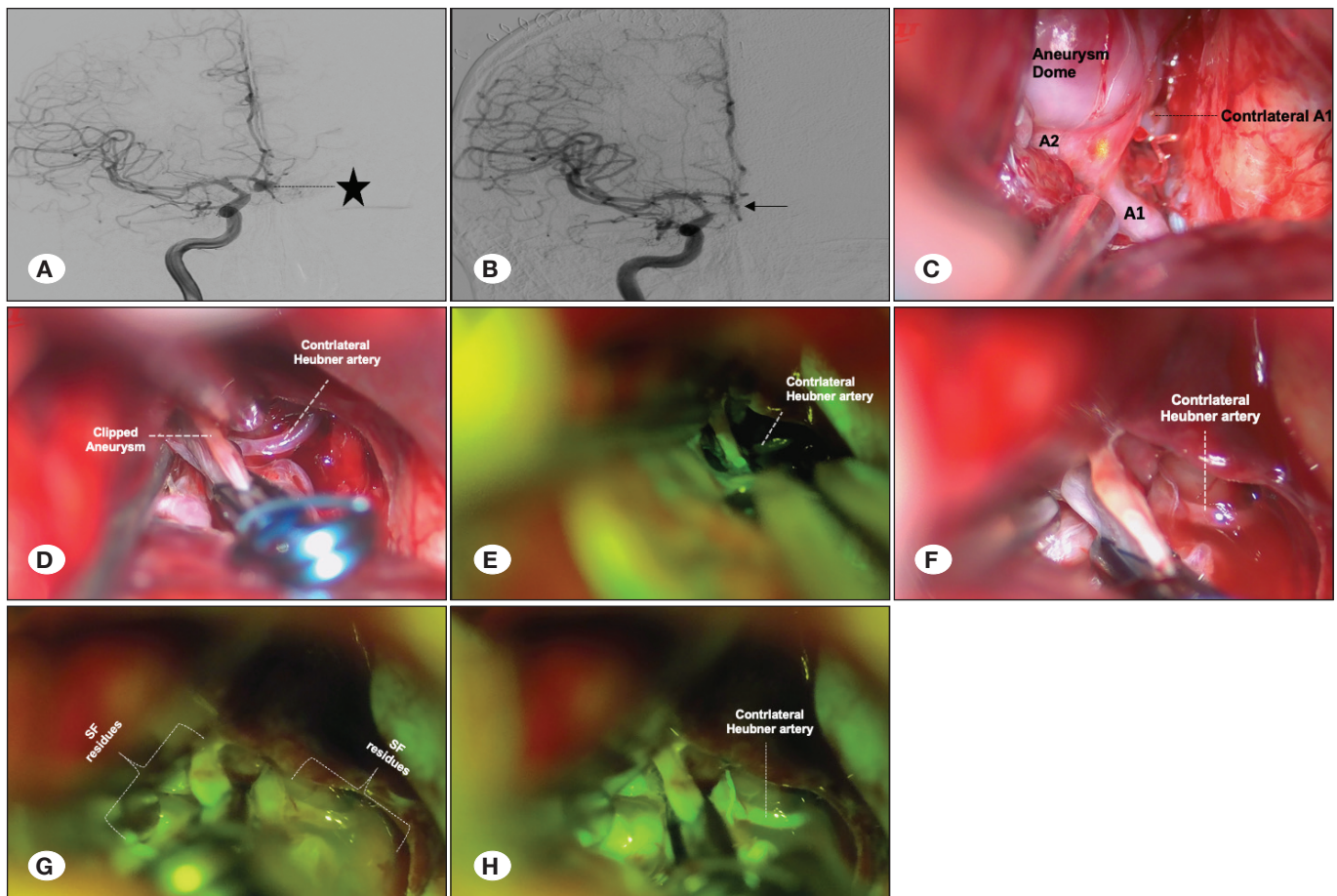




**Figure 2.** A 62-year-old female patient presented with a subarachnoid hemorrhage. Aneurysms detected in the right middle cerebral artery (MCA) bifurcation and M1 segment and right MCA M2 level were treated. During the operation, the right MCA bifurcation and M1 segment aneurysm were clipped first, in that order. NaF-V was administered after these two aneurysm clipping procedures. Four minutes after the first NaF-V administration, the aneurysm on the right MCA M2 segment was clipped and NaF-V was administered once more. Before sodium fluorescein was administered the second time, residual sodium fluorescein flashes were observed in the whole area and in the vessels, but after sodium fluorescein administration, the net flashing in the parent and perforating arteries was sufficient in providing information on vascular flow dynamics. **A)** Digital subtraction angiography; 1- Preoperative anterior-posterior view 2- Preoperative lateral view, (star; aneurysm) **B)** Digital subtraction angiography; 1- Postoperative anterior-posterior view 2- Postoperative lateral view **C)** Before the second sodium fluorescein injection **D)** After the second sodium fluorescein injection (M2, middle cerebral artery – M2 branches; SF, sodium fluorescein residues).



**Figure 3:** A 59-year-old female patient presented with a subarachnoid hemorrhage. A right internal carotid artery (ICA) posterior communicating segment artery aneurysm was clipped. NaF-V was administered after that clipping. Sodium fluorescein was weakly reflected due to the thick wall and calcifications of the ICA. However, sodium fluorescein flashes were observed in the distal branches. The tentorium also strongly reflected sodium fluorescence. **A)** Clipped aneurysm and basal image of the filter before sodium fluorescein injection **B)** Basal image of the filter before sodium fluorescein injection, **C)** Inability to see NaF-V filling in the arterial phase due to atheroma plaque **D)** In the arterial phase, the NaF-V filling was not visible due to the atheromatous plaque, whereas the filling was evident in the distal small vascular branches and tentorium. A 48-year-old female patient presented with a subarachnoid hemorrhage. The right middle cerebral artery (MCA) aneurysm was clipped. The area where the atheroma plaque on the MCA did not reflect the sodium fluorescence was observed. **E)** Basal unfiltered image without sodium fluorescein **F)** Low sodium fluorescence appearance in areas with atheromatous plaques compared to other vascular areas without atheroma (ICA, Internal carotid artery; M1-M2, middle cerebral artery – M1-M2 branches; PcoA, Posterior communicating artery).



**Figure 4:** A 36-year-old male patient presented with a subarachnoid hemorrhage. An anterior cerebral communicating segment aneurysm showing filling from the right side was detected. The aneurysm was clipped, but NaF-V was detected without flow in the left Heubner artery. The clip was revised. NaF-V was administered a second time. Although sodium fluorescein residues were present in the surrounding tissues and vessels, resumed flow was clearly confirmed in the left Heubner artery. **A)** Preoperative digital subtraction angiography, anterior-posterior view, (star; aneurysm). **B)** Postoperative digital subtraction angiography anterior-posterior view, (arrow; clipped aneurysm). **C)** Morphology of the aneurysm. **D)** Post-clip view of the aneurysm. **E)** No flow is observed with NaF-VA in the left Heubner artery. **F)** NaF-V view after clip revision. **G)** Appearance under the filter before the second administration of NaF-V, with sodium fluorescein residues infiltrating the surrounding tissue. **H)** After the second administration of NaF-V, there was significant filling in the contralateral Heubner artery (A1, A2 anterior cerebral artery – A1, A2 branches; SF; sodium fluorescein residues).

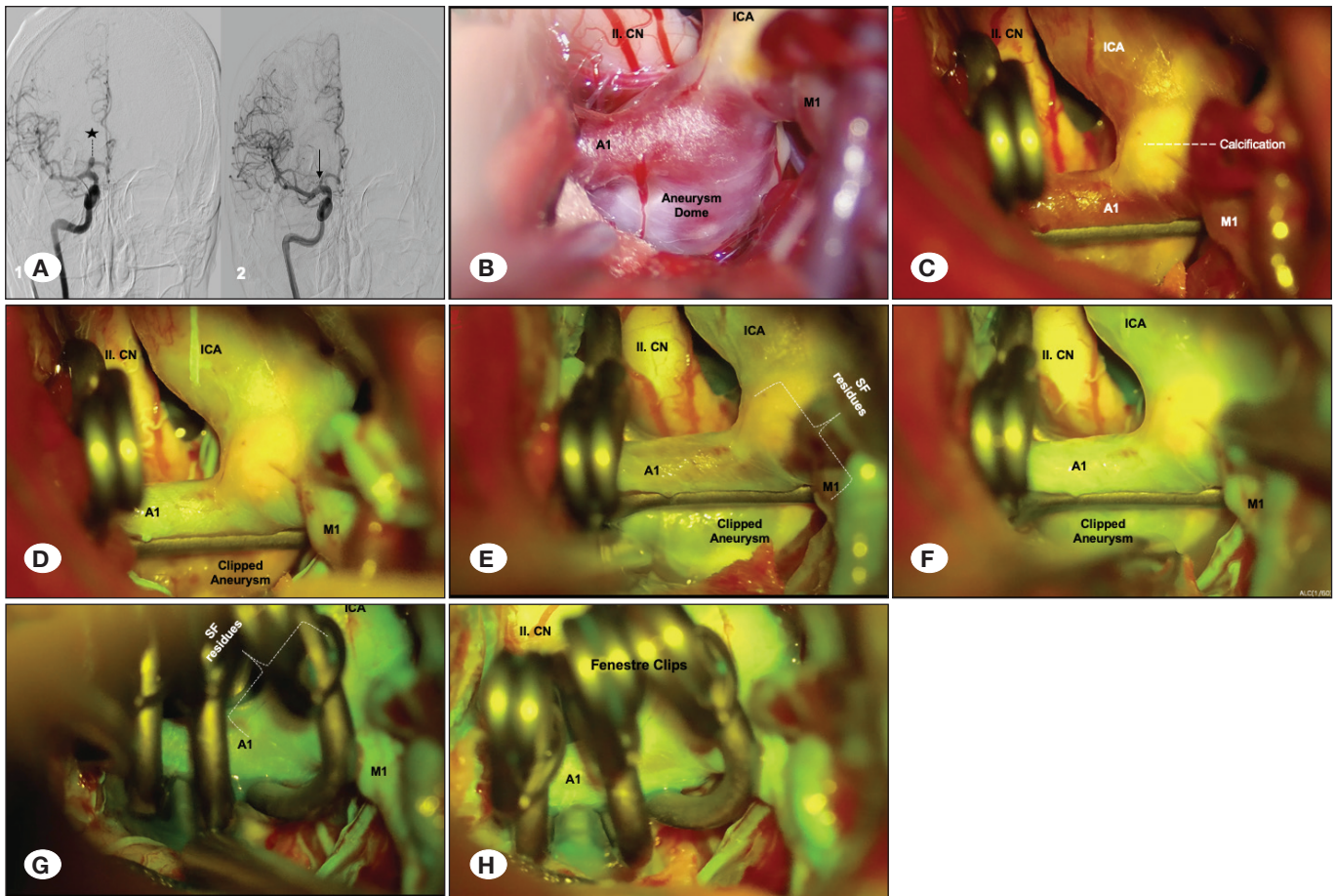
second postoperative day during daily service follow-ups and had an epileptic seizure, which was thought to be related to metabolic acidosis, although the cause could not be directly related to sodium fluorescein. No unexpected postoperative changes were observed in the other patients. An epileptic seizure developed in another patient with no prior history of seizures. This patient had an incidental left middle cerebral artery aneurysm and was diagnosed with hyperperfusion syndrome following occur after daily DSA evaluation on the fifth postoperative day and subsequent perfusion CT. Thus, seizures were associated with the hyperperfusion syndrome that developed after DSA.

## DISCUSSION

We present the results of surgical procedures in which we tested the repeated usage of sodium fluorescein while

maintaining the dosage within the total limit of 20 mg/kg (26,29), which is the minimum toxic dose. We found that NaF-V provided near-perfect results, particularly in the imaging of the parent and perforating arteries. In five cases, NaF-V made it possible to perform the necessary clip revision because it identified cases in which the flow in the arteries decreased or was absent after surgical clipping. In our series, sodium fluorescein provided sufficient advantages in imaging the parent and perforating arteries, with repeated use in 19 cases. No stenosis and/or occlusion of the parent and perforating arteries was encountered in any of the vascular structures that we evaluated using NaF-V in the postoperative period. However, a positive result confirming sufficient obliteration of the aneurysm dome was not obtained in three cases and, although there was flow in the aneurysm dome, adequate fluorescence staining was not observed.

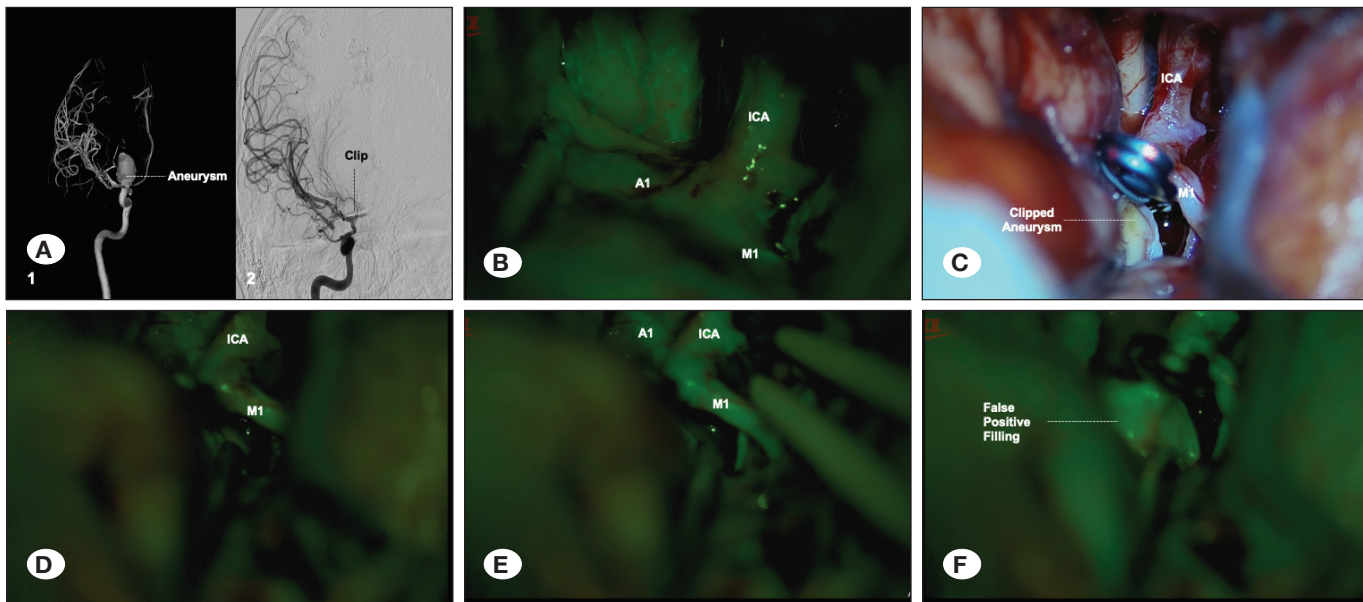




**Figure 5:** An incidentally detected right internal carotid artery bifurcation segment aneurysm was observed in a 55-year-old male patient. NaF-V was used three times during surgery. In the first two clipping procedures, an aneurysm due to insufficient clipping was detected and revised. Sodium fluorescein accumulated in the surrounding tissues and vessel walls with each use, but it contributed to the continuity of flow in the parent and perforating arteries in all uses. **A)** 1-Preoperative digital subtraction angiography, anterior-posterior view, (star; aneurysm) **2-** Postoperative digital subtraction angiography, anterior-posterior view, (arrow; clipped aneurysm). **B)** Morphology of the aneurysm. **C)** Before the sodium fluorescein injection, the areas with calcified plaques appeared brighter under the filter. **D)** After the sodium fluorescein injection, flow dynamics were observed effectively in the parent and perforating arteries; although flashes were observed in the aneurysm dome, no clear conclusion could be reached. Evaluation of the dome was performed with Doppler imaging and insufficient clipping was found. **E)** The clip was revised and NaF-V was used the second time; when viewed in filter mode before sodium fluorescein injection, there were flashes of residues on the surrounding tissue and vessel walls. **F)** After the second injection of sodium fluorescein, the flow dynamics in the parent and perforating arteries were observed effectively, and it became more difficult to reach the blood for complete obliteration of the aneurysm dome; evaluation of the dome was performed with Doppler imaging and insufficient clipping was found. **G)** The clip was revised again with NaF-V used for the third time; when viewed in filter mode before the sodium fluorescein injection, residual flashes on the surrounding tissue and vessel walls were higher compared to the second usage, and higher accumulation of sodium fluorescent residues in the surrounding tissue was observed. **H)** After the third injection of sodium fluorescein, flow dynamics in the parent and perforating arteries could be observed effectively; it was now almost impossible to evaluate the aneurysm in terms of complete obliteration in the dome, and Doppler imaging was used for dome evaluation. (II CN, II cranial nerve; A1, anterior cerebral artery – A1, branches; ICA, Internal carotid artery; M1, middle cerebral artery – M1 branches; SF, sodium fluorescein residues).

Surgeons require that the equipment used to decide the final position of the clip is fast, practical, low-cost, suitable for reuse, of high precision, effective for both parent and perforating arteries, and non-invasive and/or causes minimal side effects. Unfortunately, there is no single type of equipment or method that can satisfy all these requirements. Many authors have noted the advantages of NaF-V over DSA because of

the low sensitivity of DSA in showing perforating arteries and DSA taking more time while not denying the effectiveness of intraoperative DSA in aneurysm surgery (11-14,24,26). Intraoperative DSA requires specialized technological infrastructure. Thus, it cannot be used in centers that do not have the required infrastructure, such as our clinic, and alternatives are, therefore, being investigated.



**Figure 6:** A 38-year-old female patient presented with a subarachnoid hemorrhage. A right internal carotid artery (ICA) bifurcation segment artery aneurysm was clipped. The clip was removed due to the inability to obtain flow in the right anterior cerebral artery by Doppler imaging in surgical observation. Flow was suspected in the right anterior cerebral artery (ACA) after clip removal. NaF-V was used to evaluate the right ACA and the flows were found to be intact. During this evaluation, the aneurysm dome was selected for flashing with sodium fluorescein, and sodium fluorescein residues remained in the aneurysm dome. The aneurysm was clipped, and NaF-V was administered, both for the second time. Despite the residuals, the flow was clearly seen in the parent and perforating arteries, but it was not possible to evaluate the aneurysm dome due to the previous remains. The aneurysm dome was controlled with an injector, and it was ensured that there was no rest. **A)** 1- Preoperative digital subtraction angiography 3D, anterior-posterior view 2- Postoperative digital subtraction angiography, anterior-posterior view, clipped aneurysm. **B)** The aneurysm dome and parent and perforating arteries were filled after the first sodium fluorescein injection. **C)** Image of the clipped aneurysm. **D)** Residual sodium fluorescein residues in the surrounding tissue before the second sodium fluorescein injection. **E)** The flows were clearly evaluated in the parent and perforating arteries after the second sodium fluorescein injection. **F)** After the second sodium fluorescein injection, the dome was filled from a different angle, but there was no flow after the needle puncture, which showed false positivity (A1, anterior cerebral artery – A1, branches; ICA, internal carotid artery; M1, middle cerebral artery – M1 branches).

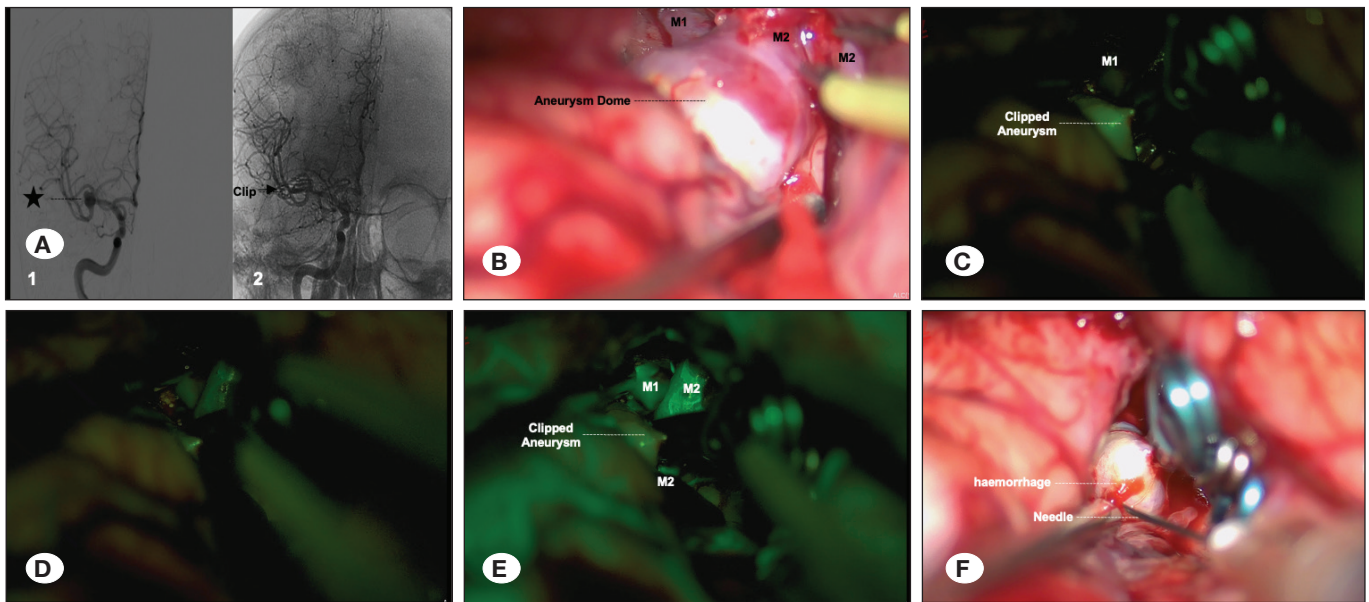
Although intraoperative SEP/MEP and EEG/ECOG monitoring may make the surgeon feel more secure during surgery, these methods have limitations. Neurological damage was observed in cases of posterior system aneurysms without a change in the SEP (22). Therefore, it is recommended to use MEP and SEP monitoring together. However, it is ethically difficult to determine the limits of intraoperative monitoring and calculate its reliability (20). In addition, the reliability of the recordings made using scalp electrodes was low. Therefore, cortical strip/grid electrodes are recommended, but involve a certain degree of complications, particularly in cases of bleeding and an edematous brain (28). Long-term temporary clipping is the preferred method for intentional vein occlusion and ring clip insertion in giant aneurysms. In addition, electrophysiological monitoring is limited to the evaluation of certain perforating and parental arteries (2,11,24).

The advantages of micro-Doppler imaging in aneurysm surgery include safety, affordability, low complication rate, and repeatability (7,10). However, this method may be insufficient to evaluate small perforating arteries (24). In our study, we used perioperative micro-Doppler imaging in combination with NaF-V. Immediately after pilot and final clipping of the aneurysms, we evaluated the distal parent arteries optically

and via Doppler. The application of NaF-V required a minimum of 1-2 minutes, including surgical manipulations necessary to ensure optimal visibility in the surgical field, changing the microscope mode, and the anesthetic team administering the compound. Approximately 30s after compound administration, the drug reaches the cerebral arterial system. However, Doppler imaging allows very quick detection of major occlusions by entering the surgical field within seconds. Therefore, Doppler imaging was performed first in our cases. We believe that the combined use of various methods is advantageous to improve surgical outcomes. Each method has certain advantages and disadvantages compared with the others. Therefore, each surgeon and surgical team can choose one or more of the most suitable methods for them, their centers, and the ways in which they work (7,12,15).

The advantage of indocyanine green video angiography (ICG-V) is apparent in the context of repeatability of the evaluation of the final position of the clip (1,4,7,17). NaF-V is more advantageous than ICG-V for intraoperative imaging of small vessels, especially in deeper locations (14,18,19). In particular, surgeons using supraorbital eyebrow incisions for the treatment of anterior aneurysms have reported that the superiority of NaF-V is even more apparent when using





**Figure 7:** In a 54-year-old female patient, an incidentally detected right middle cerebral artery bifurcation segmental artery aneurysm was clipped and NaF-V was then administered. The filter due to calcification in the aneurysm dome was more prominent than in other tissues. After sodium fluorescein injection, sodium fluorescein flashes were observed first in the arteries, and then in the capillary and venous system. However, no change was detected in the aneurysm dome. Insufficient clipping was detected after control of the dome puncturing with the injector. **A)** 1- Preoperative digital subtraction angiography, anterior-posterior view, (star; aneurysm) 2- Postoperative digital subtraction angiography anterior-posterior view, (arrow; clipped aneurysm). **B)** Morphology of the aneurysm. **C)** View of the dome under the filter before the sodium fluorescein injection. **D)** View of the donor and parent and perforating arteries under filter before sodium fluorescein injection. **E)** After the sodium fluorescein injection, the appearance of the dome, and parent and perforating arteries under the filter was observed, with no change detected in the dome. Sodium fluorescein flashes supported the flow in the parent and perforating arteries. **F)** Control of aneurysm dome by puncturing with the help of injector, and demonstration of bleeding and insufficient clipping of the dome. (M1-M2, middle cerebral artery – M1-M2 branches).

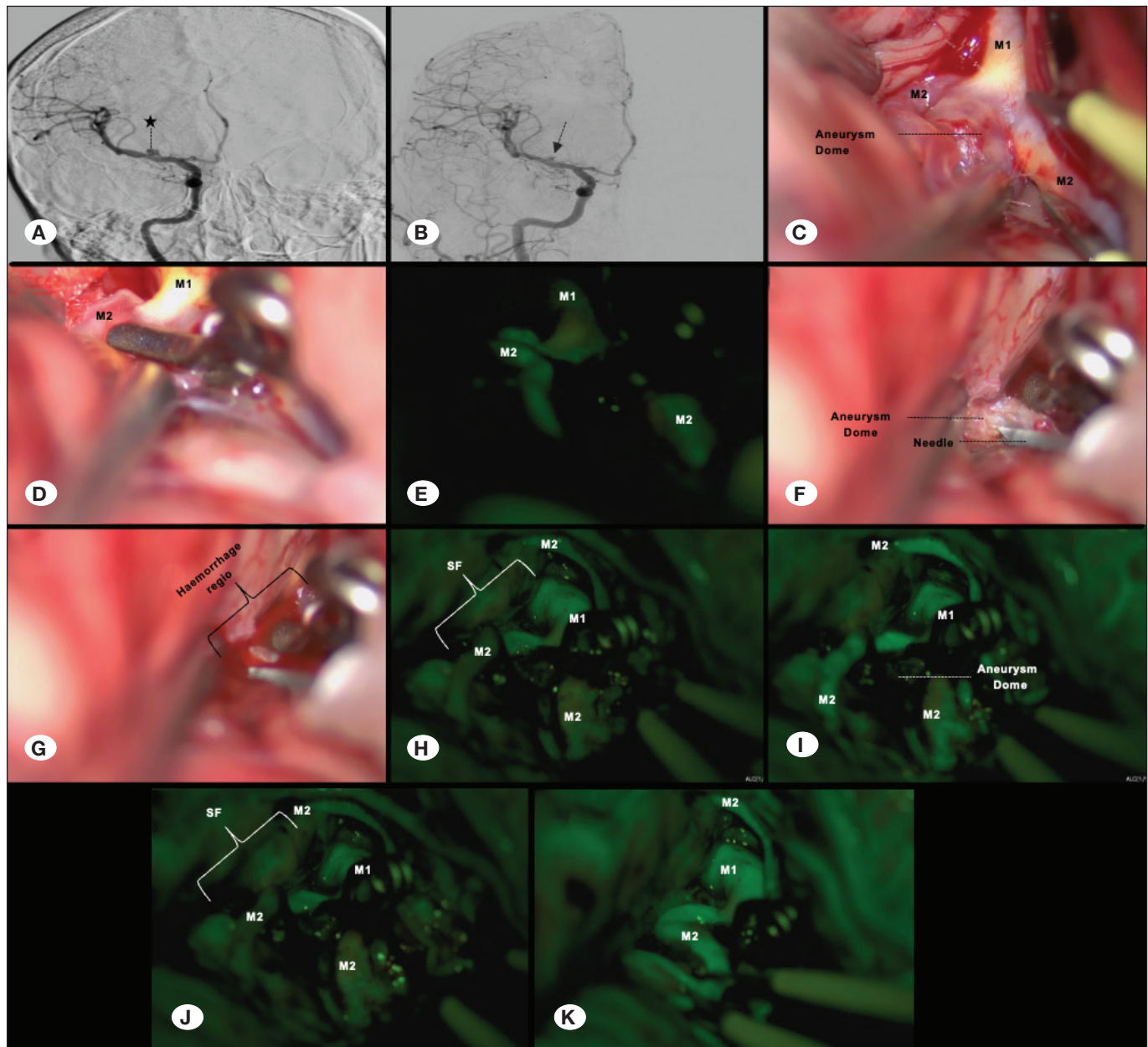
a smaller and narrower corridor (27). Another advantage of NaF-V over ICG-V is that it allows real-time imaging without video recording (14,30).

In aneurysm surgery, the method to evaluate the presence of a residual aneurysm with closed perforating and parent arteries after a clipping procedure may need to be repeated. Kuroda et al. stated that they received clear images via carotid artery injection of a version of their intravenous dose (sodium fluorescein at 500 mg, IV bolus) diluted 500 or even 1000 times (13). Ichikawa et al. used the superficial temporal artery instead of the carotid artery for intra-arterial administration of 25 mg of sodium fluorescein and reported that it was possible to re-administer sodium fluorescein many times at specified doses; however, it was not possible to re-administer sodium fluorescein intravenously before 10 min for the last dose (10). In our study, we preferred intravenous sodium fluorescein as used by Rey-Dios and Cohen-Gadol (19) because of certain disadvantages of its intra-arterial use, such as the short visual period and risks posed by carotid catheterization.

Lane et al. compared the use of ICG-V and NaF-V (sodium fluorescein at 200-75 mg, IV bolus) and concluded that the re-administration of NaF-V compared to ICG-V is less practical, but this disadvantage may be negated when using NaF-V together with ICG-V (14). Kakucs et al. (11) used sodium fluorescein at 500 mg (IV bolus), and Matano et al. (15) used

sodium fluorescein at 250 mg (IV bolus), and both studies showed that there may not be sufficient benefits regarding the repeatability of NaF-V. Zhao et al. (29) stated that NaF-V is disadvantageous compared with ICG-V for re-administration because it leaves residue on the vessel walls. Sodium fluorescein remains in the vessel wall and in the surrounding tissue after seeping out of the vessel, owing to its low molecular weight, and causes prolonged glowing, which leads to misleading results (13,14). Sodium fluorescein residues accumulate in the vascular wall and surrounding tissues at high doses (13,14). Kucukyuruk et al. (12) described the re-administration of intravenous sodium fluorescein at 100-200 mg (IV bolus) and reported that it proved to be beneficial. The beneficial, repeated use of 75 mg of sodium fluorescein as an IV bolus in arteriovenous malformation surgery has also been stated (21).

As suggested by Lane et al., we believe that the tentorium is strongly stained with sodium fluorescein, especially in cases of PComm aneurysms that cause reflections (14). If there is insufficient clipping in aneurysm surgery, late contrasting occurs because the dome is filled later (12). We concluded that late and indistinct glow and calcifications may cause false negatives in the evaluation of the flow owing to the slowing of the flow inside the aneurysm dome. In addition, residual fluorescence that leaks into the surrounding tissue in cases of repeated use can cause false positives. With single dosages



**Figure 8:** A 56-year-old female patient presented with a subarachnoid hemorrhage. NaF-V was administered after clipping the right middle cerebral artery (MCA) bifurcation segment artery aneurysm. Filling was good in the parent and perforating arteries. However, there was no fluorescent staining in the aneurysm dome, although it was controlled by puncturing with an injector and there was insufficient clipping. Aneurysm clipping was revised and then NaF-V was administered twice more. In the second and third applications, although fluorescent residues in the surrounding tissue and vessel walls caused flashes, it provided clear information about perforating and parent artery flows. **A)** Preoperative digital subtraction angiography, anterior-posterior view, (star; aneurysm). **B)** Postoperative digital subtraction angiography, anterior-posterior view, (arrow; clipped aneurysm). **C)** Morphology of the aneurysm. MCA, M1 and M2 branches are seen. **D)** Aneurysm after first clipping. **E)** After the first sodium fluorescein injection. **F)** Control of aneurysm dome with the help of the injector. **G)** Bleeding after puncture of aneurysm dome with injector. **H)** Before the second sodium fluorescein injection. **I)** After the second sodium fluorescein injection. **J)** Before the third sodium fluorescein injection. **K)** After the third sodium fluorescein injection. (M1-M2, middle cerebral artery – M1-M2 branches; SF, sodium fluorescein residues).

of 5 mg/kg and a minimum toxic dosage of over 20 mg/kg (26,29), sodium fluorescein can be used repeatedly, while remaining in the safe dosage range regarding side effects. In addition, although residual fluorescence occurred in the surrounding tissues and walls of the arteries, we achieved satisfactory results with repeated usage of NaF-V in evaluating the presence of flow with the strong staining effect of sodium fluorescein immediately following the injection.

### Limitations

We examined the intraoperative use of NaF-V, but were unable to utilize other methods, such as ICG-V and intraoperative DSA, for technical reasons. Therefore, we could not compare the efficiency of NaF-V with these methods. Another limitation is the absence of aneurysms originating from the basilar artery and posterior system in our series.

### CONCLUSION

NaF-V is a complementary and supportive method for intracranial aneurysm surgery such as micro-Doppler imaging. The contribution of NaF-V in preventing conditions such as perforating artery closure, aneurysmal rest, and parent artery occlusion that cause mortality and morbidity in the final evaluation stage is undeniable. Although fluorescent residues remain on the vessel walls, we believe that this is not an insurmountable obstacle to repeated administration of sodium fluorescein, wherein NaF-V has been shown to be sufficient for flow evaluation. In addition no NaF-V-related complications were encountered in any case.

### ACKNOWLEDGEMENTS

We thank Ebubekir Akpınar MD, Yusuf Kılıç MD and Taha Hanoğlu MD, PhD for her contribution to the article.

#### AUTHORSHIP CONTRIBUTION

Study conception and design: LSP, BE

Data collection: BE

Analysis and interpretation of results: LSP

Draft manuscript preparation: BE

Critical revision of the article: LSP

Other (study supervision, fundings, materials, etc...): LSP, BE

All authors (LSP, BE) reviewed the results and approved the final version of the manuscript.

### REFERENCES

- Akdemir H, Oktem IS, Tucer B, Menku A, Başaslan K, Gunaldı O: Intraoperative microvascular Doppler sonography in aneurysm surgery. *Minim Invasive Neurosurg* 49:312-316, 2006
- Bacigaluppi S, Fontanella M, Manninen P, Ducati A, Tredici G, Gentili F: Monitoring techniques for prevention of procedure-related ischemic damage in aneurysm surgery. *World Neurosurg* 78:276-288, 2012
- Chiang VL, Gailloud P, Murphy KJ, Rigamonti D, Tamargo RJ: Routine intraoperative angiography during aneurysm surgery. *J Neurosurg* 96:988-992, 2002
- Dashti R, Laakso A, Niemelä M, Porras M, Hernesniemi J: Microscope-integrated near-infrared indocyanine green video angiography during surgery of intracranial aneurysms: The Helsinki experience. *Surg Neurol* 71:543-550; discussion 550, 2009
- Feindel W, Yamamoto YL, Hodge CP: Intracarotid fluorescein angiography: A new method for examination of the epicerebral circulation in man. *Can Med Assoc J* 96:1-7, 1967
- Feindel W, Yamamoto YL, Hodge CP: The cerebral microcirculation in man: Analysis by radioisotopic microregional flow measurement and fluorescein angiography. *Clin Neurosurg* 18(CN\_suppl\_1):225-246, 1971
- Fischer G, Stadie A, Oertel JM: Near-infrared indocyanine green video angiography versus microvascular Doppler sonography in aneurysm surgery. *Acta Neurochir* 152:1519-1525, 2010
- Greuter L, Croci DM, Zumofen DW, Ibe R, Westermann B, Mariani L, Soleman J, Guzman R: Augmented reality fluorescence imaging in cerebrovascular surgery: A single-center experience with thirty-nine cases. *World Neurosurg* 151:12-20, 2021
- Hashimoto K, Kinouchi H, Yoshioka H, Kanemaru K, Ogiwara M, Yagi T, Wakai T, Fukumoto Y: Efficacy of endoscopic fluorescein video angiography in aneurysm surgery—novel and innovative assessment of vascular blood flow in the dead angles of the microscope. *Oper Neurosurg (Hagerstown)* 13:471-481, 2017
- Ichikawa T, Suzuki K, Watanabe Y: Intra-arterial fluorescence angiography with injection of fluorescein sodium from the superficial temporal artery during aneurysm surgery: Technical notes (technical notes). *Neurol Med Chir (Tokyo)* 54:490-496, 2014
- Kakucs C, Florian IA, Ungureanu G, Florian IS: Fluorescein angiography in intracranial aneurysm surgery: A helpful method to evaluate the security of clipping and observe blood flow. *World Neurosurg* 105:406-411, 2017
- Kucukyuruk B, Korkmaz TS, Nemayire K, Ozlen F, Kafadar AM, Akar Z, Kaynar MY, Sanus GZ: Intraoperative fluorescein sodium video angiography in intracranial aneurysm surgery. *World Neurosurg* 147:e444-e452, 2021
- Kuroda K, Kinouchi H, Kanemaru K, Nishiyama Y, Ogiwara M, Yoshioka H, Horikoshi T: Intra-arterial injection fluorescein video angiography in aneurysm surgery. *Neurosurgery* 72 Supplement Operative: ons141-150; discussion ons150, 2013
- Lane B, Bohnstedt BN, Cohen-Gadol AA: A prospective comparative study of microscope-integrated intraoperative fluorescein and indocyanine video angiography for clip ligation of complex cerebral aneurysms. *J Neurosurg* 122:618-626, 2015
- Matano F, Mizunari T, Murai Y, Kubota A, Fujiki Y, Kobayashi S, Morita A: Quantitative comparison of the intraoperative utility of indocyanine green and fluorescein video angiographies in cerebrovascular surgery. *Oper Neurosurg (Hagerstown)* 13: 361-366, 2017



16. Norton EW, Gutman F: Diabetic retinopathy studied by fluorescein angiography. *Trans Am Ophthalmol Soc* 63:108-128, 1965
17. Ozgiray E, Akture E, Patel N, Baggott C, Bozkurt M, Niemann D, Baskaya MK: How reliable and accurate is indocyanine green video angiography in the evaluation of aneurysm obliteration? *Clin Neurol Neurosurg* 115:870-878, 2013
18. Raabe A, Spetzler RF: Fluorescence angiography. *J Neurosurg* 108:429-430, 2008
19. Rey-Dios R, Cohen-Gadol AA: Technical principles and neurosurgical applications of fluorescein fluorescence using a microscope-integrated fluorescence module. *Acta Neurochir* 155:701-706, 2013
20. Schramm J, Zentner J, Pechstein U: Intraoperative SEP monitoring in aneurysm surgery. *Neurol Res* 16:20-22, 1994
21. Serrano-Rubio A, Ruiz-Treviño AS, Orenday-Barraza JM, Vázquez-Gregorio R, Lee A, Nathal E: Sodium fluorescein videoangiography as an adjunct to resection of cerebral arteriovenous malformations. *World Neurosurg* 117: e329-e334, 2018
22. Shinoda J, Yano H, Yoshimura SI, Okumura A, Kaku Y, Iwama T, Sakai N: Fluorescence-guided resection of glioblastoma multiforme by using high-dose fluorescein sodium. *Technical note. J Neurosurg* 99:597-603, 2003
23. Stendel R, Pietilä T, Al Hassan AA, Schilling A, Brock M: Intraoperative microvascular Doppler ultrasonography in cerebral aneurysm surgery. *J Neurol Neurosurg Psychiatry* 68: 29-35, 2000
24. Suzuki K, Kodama N, Sasaki T, Matsumoto M, Ichikawa T, Munakata R, Muramatsu H, Kasuya H: Confirmation of blood flow in perforating arteries using fluorescein cerebral angiography during aneurysm surgery. *J Neurosurg* 107:68-73, 2007
25. Świątnicki W, Szymański J, Szymańska A, Komuński P: Intraoperative fluorescein video angiography in intracranial aneurysm surgery: Single-center, observational cohort study. *Acta Neurol Belg* 121:1487-1493, 2021
26. Wrobel CJ, Meltzer H, Lamond R, Alksne JF: Intraoperative assessment of aneurysm clip placement by intravenous fluorescein angiography. *Neurosurgery* 35:970-973; discussion 973, 1994
27. Wu Y, Zhao Y, Yu S, Li F, Cai S, Peng C, Wang Z, Yang Y, Wang B, Yang X: Reconstruction clipping of ruptured anterior circulation aneurysms via supraorbital lateral keyhole approach. *Chin Neurosurg J* 8:3, 2022
28. Yue Q, Zhu W, Gu Y, Xu B, Lang L, Song J, Cai J, Xu G, Chen L, Mao Y: Motor evoked potential monitoring during surgery of middle cerebral artery aneurysms: A cohort study. *World Neurosurg* 82:1091-1099, 2014
29. Zhao X, Belykh E, Cavallo C, Valli D, Gandhi S, Preul MC, Vajkoczy P, Lawton MT, Nakaji P: Application of fluorescein fluorescence in vascular neurosurgery. *Front Surg* 6:52, 2019
30. Zipfel GJ: Editorial: Clipping of neurosurgical aneurysms: The dye is cast. *J Neurosurg* 122: 616-617; discussion 617, 2015