

Is The Modular Dynamic System as Effective as Classical Dynamic Systems in Long Segment Dynamic Thoracolumbar Stabilization?

Caner GUNERBUYUK¹, Mehmet Yigit AKGUN², Ali Fahir OZER²

¹Koc University Hospital, Department of Orthopaedics and Traumatology, Istanbul, Türkiye

²Koc University Hospital, Department of Neurosurgery, Istanbul, Türkiye

Corresponding author: Mehmet Yigit AKGUN ✉ myigitakgun@gmail.com

ABSTRACT

AIM: To evaluate the outcomes of dynamic stabilization in the multilevel degenerative spondylotic spine and to compare the two dynamic systems (Dynesys® and Orthrus®) to reveal the increasing role of dynamic systems in the management of the degenerative spine.

MATERIAL and METHODS: 74 patients who received dynamic stabilization for degenerative pathologies were retrospectively analyzed. Demographic details: preoperative data including neurological status, pain scores, and radiology; and intraoperative data including blood loss, duration of surgery, complications, and postoperative data including the neurologic status, duration of hospital stay, and pain scores were examined.

RESULTS: Patients in both groups showed statistically significant improvements in their Visual Analog Scale and Oswestry Disability Index scores. Significant corrections of thoracic kyphosis (T2-T12), the sagittal vertical axis, and T10-L2 thoracolumbar kyphosis were obtained in our cohort ($p < 0.05$). A total of 4 patients received revision surgery due to screw loosening. Patients were discharged after 3–4 days and mobilized on the first postoperative day.

CONCLUSION: We did not experience any serious issues in terms of stabilization in the cases in which we employed both systems. Our patient clinical results were satisfactory in both systems. Existing systems can be used safely even in long-segment stabilization surgeries.

KEYWORDS: Dynamic stabilization, Posterior, Degenerative spine, Dynesys, Orthrus

INTRODUCTION

The development of dynamic systems took place long after fusion surgery. The emergence and use of pedicular screws only took place 73 years after fusion (23). Following immediately was the idea of a dynamic system constructed using pedicular screws. Whatever the concept, it is not a paradox that the modern designs of dynamic systems and their usage emerge with close dates. The expansion in surgical knowledge and expertise increased along with the development of notions regarding the functions, stability, and instability of the spine.

Pedicular-based dynamic systems are being employed more often each year despite the high number of fusion assertors (2). They are stabilization systems developed for chronic instability where fusion surgery is used unnecessarily. They stabilize the spine in motion. They are divided into two systems in which the rod is movable and the systems in which the screw is movable. It is also feasible to combine the two systems. It is currently employed in multilevel instabilities as well, even though it was previously only used in instabilities involving a single motion segment.

Dynamic stabilizations performed with both the Dynesys and Orthrus systems provide satisfactory results (1,22). By evaluating the literature, we will examine the clinical outcomes of the Dynesys and Orthrus system employed in multilevel instability in this study, which has not before been published.

■ MATERIAL and METHODS

All procedures conducted in this study were approved by the ethical standards of the institutional and national research committee and adhered to the 1964 Helsinki Declaration and its later amendments or comparable ethical standards. Informed consent was collected from all individual participants included in the study (Institutional Review Board of Koc University Hospital (2022.021.IRB.016)).

A retrospective analysis was done on 74 patients who received dynamic stabilization for degenerative diseases at the American and Koc University Hospitals between 2017 and 2020. Patients with instability, including at least three motion segments and above, were included in the study. Our selection criteria for this method included any neurogenic, radicular pain, and/or chronic low-back pain that were resistant to appropriate conservative treatment. Instability was subjectively verified by the patient's axial pain, and objectively by CT findings and dynamic radiographs. Painful degenerative disc disease, degenerative spondylolisthesis, and canal stenosis were indications for surgery. Seventy-four patients with multilevel instability who had dynamic stabilization were included in the study. Dynamic stabilization was conducted using the Dynesys system in 50 patients and the Orthrus system in 24 patients. The system with which the patients would be stabilized was determined randomly.

Demographic details: preoperative data including neurological status, pain scores, and radiology; and intraoperative data including blood loss, duration of surgery, complications, and postoperative data including the neurologic status, duration of hospital stay, and pain scores were examined.

Two-way whole spine X-rays, MR, and CT studies were obtained in all patients, and surgery was planned based on the clinic of each patient. Patients were closely monitored clinically and radiologically in the postoperative 4th and 12th months following the thorough preoperative evaluation of the patients. Radiological evaluation was performed with the calculation of the preoperative, fourth-month, and first-year global kyphosis (T2-T12), lumbar lordosis (T12-S1), thoracolumbar kyphosis (T10-L2), sagittal and coronal balance on the whole spine x-ray. Then, the patients were called for routine controls every year. In the clinical assessment, the patients were assessed neurologically, and the Visual Analog Scale (VAS) and Oswestry Disability Index (ODI) were employed for preoperative and postoperative subjective patient evaluations.

As a clinical concept, all patients received the required medical care following their needs, with assistance from the departments of physiotherapy and algology. However, in the presence of radicular irritation findings and accompanying neurological deficits, surgical treatment was preferred as the primary method. Furthermore, after bone density

measurement, the operation was conducted in two stages in patients with osteoporosis. Osteoporosis is diagnosed radiographically based on bone mineral density determinations from dual-energy X-ray absorptiometry assessment. In patients who underwent two-stage surgery, the roots were relieved after decompression was conducted in the first stage, and a temporary rod was placed only in the decompressed segment.

Surgical Technique

All patients received general anesthesia and were in the prone position for operations. Screws are placed in the spine using the Wiltse paraspinous approach technique by the same surgeon, which has been discussed in many places in the literature (29). Prophylactic Cefuroxime was given to all patients upon initiation of anesthesia and was continued during the following 48 h.

In both the Orthrus and the Dynesys systems, if there is a movement segment that requires intervention such as discectomy or decompression, only the muscles are stripped subperiosteally and the necessary surgical procedure is performed.

In both groups, the surgery was conducted in two stages in cases with a T score of -1.5 and below. In cases where two-stage surgery is required, if there is a neurological deficit, decompressive surgery is carried out only in that region, and unilateral and sometimes bilateral rods are placed on the screws responsible for stabilization in only that segment. In cases with two-stage surgery, the rods of the entire system was placed four months later (21).

Dynamic Systems

Dynesys® dynamic stabilization system (Zimmer Inc, Warsaw, IN, USA): Manufactured by Zimmer Spine. The flexible rod and polyurethane spacers used to create the rigid screw prevent the screws' heads from converging as the rod is stretched (Figure 1).

This system is very easy to use in long-segment stabilization. After the lumbar lordosis is administered with the help of the table, the thread-shaped rod can be easily passed through the screws (Figure 2).

Orthrus system; (Tipsan, Izmir) it is a dynamic screw system with two heads that only move up and down on the horizontal axis. The Orthrus system aims to stabilize every segment in the system as a single separate segment. Each screw head is responsible for stabilizing a motion segment with the head of the screw at the same site above. It creates a modular structure (Figure 3). The screws can be interconnected with titanium, carbon fiber, peek, or any other rod system. The Orthrus dynamic system is easy to use in the patient. Furthermore, revision surgeries can be conducted very easily as it is a modular system (Figure 4).

Statistical Analyses

All statistical analyses were conducted using IBM SPSS 20.0 software (SPSS Inc., Chicago, IL, USA). The chi-square test was used to compare data across groups for categorical

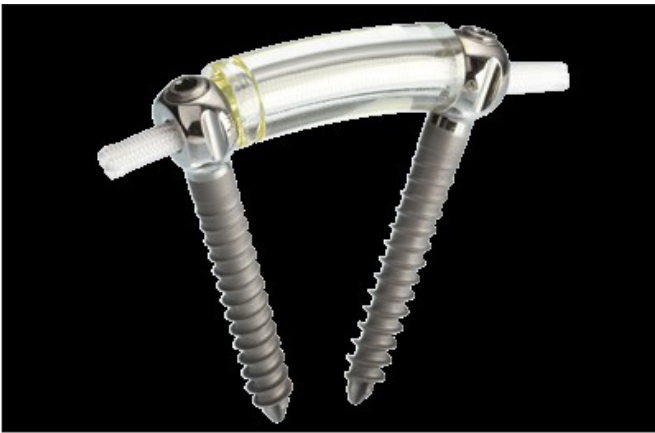

Figure 1: Dynesys dynamic system.

data, while the t-test, ANOVA, or Kruskal–Wallis test (a non-parametric option) was used to compare data between groups for continuous data. A two-tailed $p < 0.05$ was considered to show statistically significant differences.

RESULTS

Dynamic stabilization was conducted using the Dynesys system in 50 patients and the Orthrus system in 24 patients. 46 of the patients were female and 28 were male. The age of the patients ranged from 21 to 88, with a mean age of 64.69 years. The average follow-up is depicted in Table I.

Preoperative pain was prominent in the patients, and neurological findings were mostly root irritation in both groups. Table I provides detailed information on the preoperative

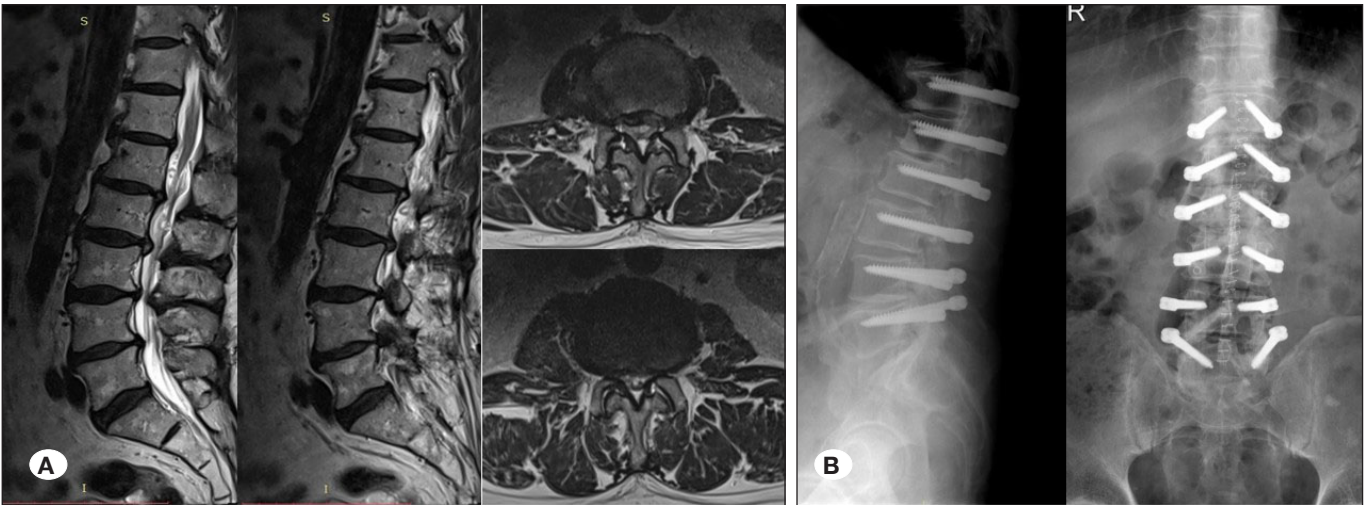


Figure 2: A 70-year-old male patient presented with severe low back pain **A)** L2-3 and L3-4 narrow canal and diffuse degenerative disc disease are seen on MRI **B)** dynamic stabilization was performed using the multilevel Dynesys system.

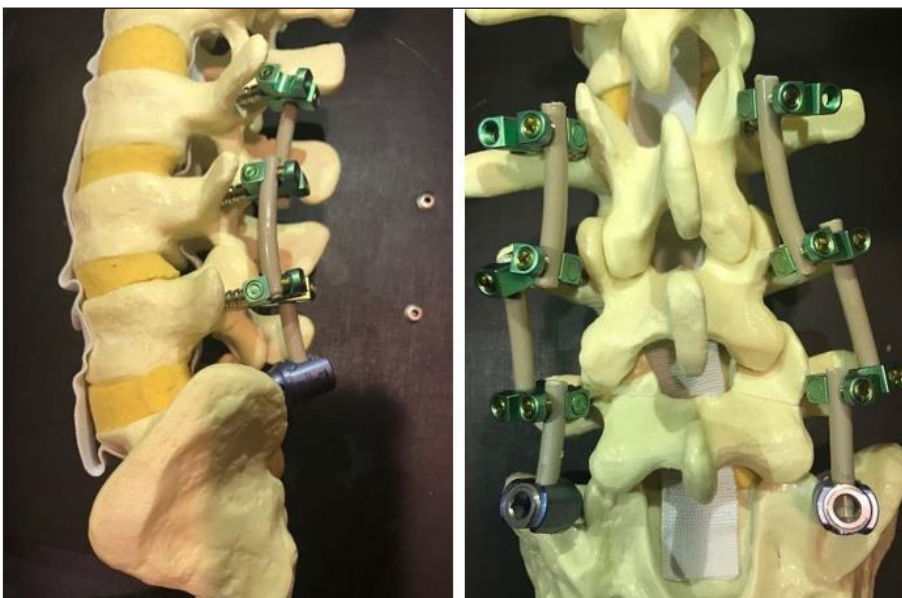

Figure 3: Orthrus dynamic system.

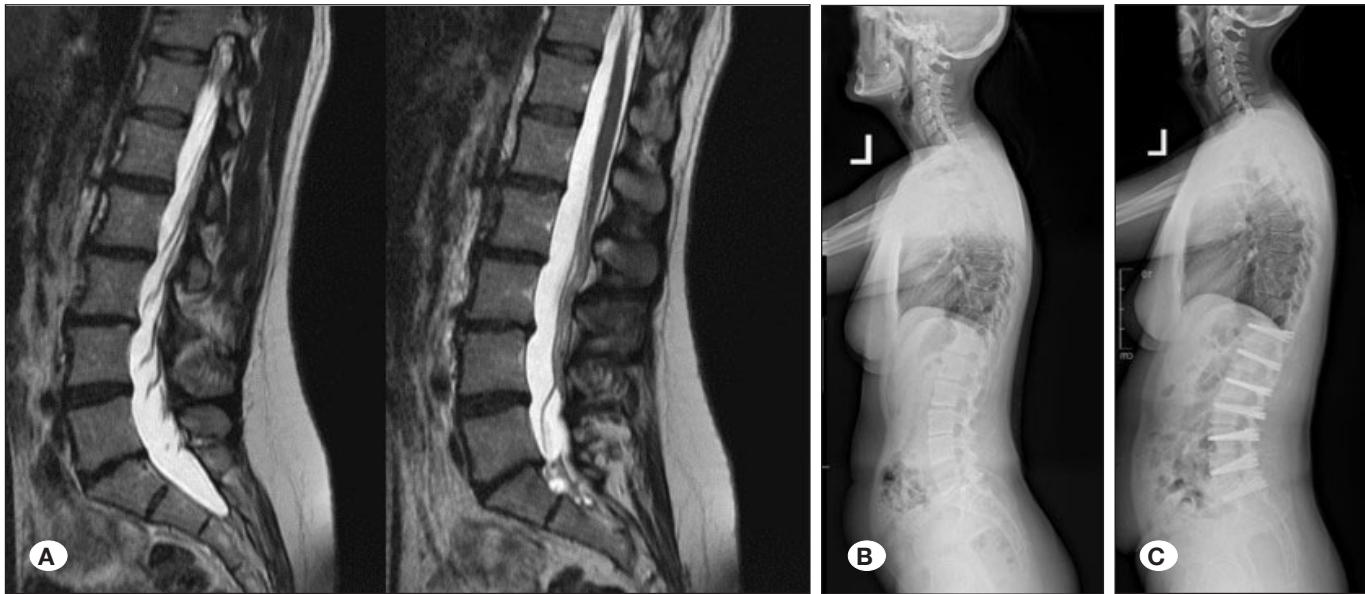


Figure 4: A 46-year-old female patient is unable to stand and walk for a long time due to severe low back pain **A)** Extensive degenerative disc disease is present on MRI **B)** her sagittal balance deteriorates forward **C)** the patient's complaints have improved significantly after the operation and her sagittal balance has improved looks.

diseases and clinical results of the patients. Furthermore, surgical details and pathological levels are illustrated in detail in Table II, III. There was no significant difference in demographic and surgical data in both groups ($p > 0.05$). In Table I, the VAS and ODI findings of the patients who used the Orthrus and Dynesys systems are presented. Statistically significant improvement was observed in both groups in both early and final clinical controls ($p < 0.05$).

Significant corrections of thoracic kyphosis (T2-T12), the sagittal vertical axis (SVA), T10-L2 thoracolumbar kyphosis, lumbar lordosis, and coronal balance were obtained in our cohort ($p < 0.05$). Nevertheless, there was no discernible difference between the readings postoperatively and at the most recent follow-up evaluation ($p > 0.05$). When the two groups were assessed within themselves in radiological parameters, no statistically significant difference was discovered. The reconstruction was stable in all patients at the last follow-up controls. 38 cases had only lumbar and lumbosacral stabilization. These cases and thoracic and thoracolumbar cases were compared, and no statistically significant difference could be obtained in terms of demographic and radiological aspects.

The first postoperative controls were conducted at 4 months to show significant osteosynthesis. Screw loosening was identified in 1 patient in the Orthrus group at the 4th-month follow-up, screw loosening was detected in 3 patients in the Dynesys group, and revision surgery was conducted. Regarding the patients' instrument systems, there were no issues at the last follow-up. Furthermore, infection developed in 4 patients in long-segment Dynesys patients. CSF fistula was seen in one patient in the early postoperative period in both groups. Patients were mobilized on the first postoperative day and discharged after 3–4 days.

Table I: Summarized Data of Patient's

Variables	Patients (n=74)
Age, Years	64.69 ± 21.26
Male/Female	28/46
Dynesys/Orthrus	50/24
Mean Clinical Follow up (month)	25.08
Symptoms	
Radicular pain (Dy/Or)	31/15
Neurogenic claudication (Dy/Or)	20/10
Hypoesthesia (Dy/Or)	23/12
Muscle weakness (Dy/Or)	28/14
Back pain (Dy/Or)	37/18
Pathology	
Stenosis (Dy/Or)	21/11
Listesis (Dy/Or)	13/6
Degenerative disc disease (Dy/Or)	39/19
Instability (Dy/Or)	32/14
Follow up	
Dy VAS (Pre/ 4 th month/12 th month)	7.53/2.48/1.44
Or VAS (Pre/ 4 th month/12 th month)	7.50/2.33/1.41
Dy ODI (Pre/ 4 th month/12 th month)	67.71/25.71/11.14
Or ODI (Pre/ 4 th month/12 th month)	69.91/22.66/9.75
Complications	
Screw loosening (Dy/Or)	3/1
Infection (Dy/Or)	4/0
CSF fistula (Dy/Or)	1/1

Dy: Dynesys **Or:** Orthrus. **VAS:** Visual Analog Scale, **ODI:** Oswestry Disability Index.

■ DISCUSSION

Dynamic systems are systems that have been created due to the inconvenience caused by the exaggerated use of fusion surgery for every spinal issue. It has been claimed that regulating abnormal movement in chronic instability will alleviate the pain, and therefore, it has been said that instead of freezing the movement, it will be sufficient to prevent abnormal movement (13). The philosophy underlying the use of the system is "There is no need to freeze the joint to preserve the abnormal motion in chronic instability" (13). There is a constant load transfer on the graft because the anterior column will share the load transfer from instrumentation in dynamic pedicular systems, increasing the likelihood of fusion development (11,12).

Later, dynamic screw systems were developed. It has been reported that these systems are appropriate for a single motion segment and can be used for the stabilization of at most two motion segments (27).

As a result of intense criticism of the graph ligaments, the Dynesys system was created on its deficiencies (8). The way has also been cleared for lengthy segment stabilizations with the introduction of the Dynesys system. It was used for the first time in multilevel instability and degenerative scoliotic deformities in the follow-up (7). Furthermore, the Orthrus

system is a modular system developed for the stabilization of two motion segments and above (22). It is a dynamic screw system with two heads that move only up and down on the horizontal axis. Because of its modular design, when a problem arises in the system, only the portion connected to that motion segment can be altered, and in cases of issues such as adjacent segment disease, it may be added to the system without having to remove the system altogether because it contains slotted screws, it can be used in two-stage surgery due to its percutaneous placement.

In the literature, it is stated that the clinical results after dynamic stabilization are not superior to fusion, and therefore, dynamic systems are criticized. Even the accuracy of this result indicates the superiority of dynamic systems over fusion because considering the effort spent during surgery, and early and late postoperative complications, it is a surgery that should be preferred more than fusion for stabilization (4,14,16,19,28,30). Data on the use of dynamic systems in patients with multilevel instability are very limited. A comparison of the Orthrus system developed by us and the Dynesys system was made for the first time. In our research, we achieved very satisfactory results in patients who were operated on with both dynamic systems. Furthermore, we did not identify a clinically and radiologically significant difference between the Orthrus and Dynesys systems.

Another criticism is that the loosening of screws is common (15,18,20,24). The patient group that develops chronic instability is mostly middle-aged and osteoporosis is a serious issue, particularly in postmenopausal female patients. However, existing challenges and problems remain valid for fusion surgery as well. Considering the bone density, two-stage surgery can be conducted in patients with a T score of -1.5 and below (21). This also applies to patients with chronic instability who are considering fusion. With two-stage surgeries, the screw loosening problem can be solved to a great extent. Moreover, comparable rates were discovered in the literature when screw loosening rates in dynamic systems were compared with fusion surgery. When the two dynamic systems were compared with each other, no significant difference was discovered. Dynamic systems are as safe as fusion surgery for long-segment stabilization surgeries.

It has been stated in the literature that dynamic stabilization provides satisfactory results in the short segment. Furthermore, it was noted that sagittal spinal alignment was normal in cases with long-segment dynamic stabilization.

Table II: Surgical Data of Patient's

Surgical Data	Patients (n=74)	p-value
Mean op. time (min.)	277.2 (201-349)	
Mean blood loss (mL)	1239 (331-1762)	
Fused Levels (Number)		
4 levels	15	
5 levels	16	
6 levels	11	
7 levels	7	
9 levels	9	
10 levels	11	
11 levels	5	
Anatomic region		
Lumbosacral	13	
Lumbar	25	
Thoracolumbar	22	
Thoracal	14	

Table III: Radiological Parameters

Radiological Parameters	Preoperative	3 rd Months	12 th Months	p-value
Thoracic kyphosis [T2-12]	54.1	46.2	46.1	<0.05
SVA [mm]	22.7	5.7	4.9	<0.05
Thoracolumbar kyphosis [T10-L2]	18.6	6.8	6.4	<0.05
Coronal balance [mm]	2.5	1.2	1.1	>0.05
Lumbar lordosis [L1-L5]	46.1	47.2	47.5	>0.05

SVA: Sagittal vertical axis.

In this study, effective outcomes were obtained with long-segment dynamic stabilization in the radiological parameters and sagittal balances of the patients (1,22).

It should be noted that dynamical systems are not systems that are created to maintain motion. According to biomechanical research, they repair the compromised neutral zone (3,5,9,17,25,26). In cases where the disc is not severely degenerated when the motion segment is stabilized, it has been shown to regenerate and contribute to certain motions of this motion segment. However, although the stabilization system is mobile, fusion has been revealed to develop due to advanced disc degeneration in a significant part of the cases (31). There have been publications reporting that rehydration occurred, and degeneration regressed in patients who had dynamic stabilization in the early stage (6,10). From our cases where we applied Dynesys and Orthrus systems; while fusion was found in patients with severely degenerated motion segments, it was observed that motion was preserved, and discs recovered in cases with less degenerated motion segments.

When the potential complications of fusion surgery and the comorbidities of the geriatric age group come together, distressing clinical situations can occur for the surgeons. In our study, the majority of our patients were a geriatric population. In addition to obtaining satisfactory results with both systems, no serious complications were encountered. Due to the improvement in the radiological parameters of the patients and the capacity of maintaining the segment movement in suitable cases, the dynamic systems provide satisfactory results, particularly in the geriatric population. As a result, it is possible to achieve efficient results in degenerative spine pathologies in this age group with both systems.

CONCLUSION

We did not experience any serious issues in terms of stabilization in the cases in which we used both systems. Our patient clinical findings were satisfactory in both systems. Only the Orthrus system is a more friendly system due to its modular structure.

AUTHORSHIP CONTRIBUTION

Study conception and design: AFO

Data collection: CG, MYA

Analysis and interpretation of results: CG, MYA

Draft manuscript preparation: CG, MYA, AFO

Critical revision of the article: AFO

Other (study supervision, fundings, materials, etc...): CG, MYA, AFO

All authors (CG, MYA, AFO) reviewed the results and approved the final version of the manuscript.

REFERENCES

1. Akyoldas G, Cevik OM, Suzer T, Sasani M, Oktenoglu T, Ozer AF: Dynamic stabilization of the lumbar spine using the Dynesys® system. *Turk Neurosurg* 30(2):190-193, 2020
2. Bono CM, Kadaba M, Vaccaro AR: Posterior pedicle fixationbased dynamic stabilization devices for the treatment of degenerative diseases of the lumbar spine. *J Spinal Disord Tech* 22(5):376-383, 2009
3. Bozkus H, Senoglu M, Baek S, Sawa AG, Ozer AF, Sonntag VK, Crawford NR: Dynamic lumbar pedicle screw-rod stabilization: In vitro biomechanical comparison with standard rigid pedicle screw-rod stabilization. *J Neurosurg Spine* 12(2):183-189, 2010
4. Cakir B, Richter M, Huch K, Puhl W, Schmidt R: Dynamic stabilization of the lumbar spine. *Orthopedics* 29(8):716-722, 2006
5. Chen CS, Huang CH, Shih SL: Biomechanical evaluation of a new pedicle screw-based posterior dynamic stabilization device (Awesome Rod System)-a finite element analysis. *BMC Musculoskelet Disord* 16:81, 2015
6. Cho BY, Murovic J, Park KW, Park J: Lumbar disc rehydration postimplantation of a posterior dynamic stabilization system. *J Neurosurg Spine* 13(5):576-580, 2010
7. Di Silvestre M, Lolli F, Bakaloudis G, Parisini P: Dynamic stabilization for degenerative lumbar scoliosis in elderly patients. *Spine (Phila Pa 1976)* 35(2):227-234, 2010
8. Dubois G, de Gernay B, Schaerer NS, Fennema P: Dynamic neutralization: A new concept for restabilization of the spine. In: Szpalski M, Gunzburg R, Pope MH (eds), *Lumbar Segmental Instability*. Philadelphia: Lippincott Williams and Wilkins, 1999:233-240
9. Erbulut DU, Kiapour A, Oktenoglu T, Ozer AF, Goel VK: A computational biomechanical investigation of posterior dynamic instrumentation: Combination of dynamic rod and hinged (dynamic) screw. *J Biomech Eng* 136(5):051007, 2014
10. Fay LY, Wu JC, Tsai TY, Tu TH, Wu CL, Huang WC, Cheng H: Intervertebral disc rehydration after lumbar dynamic stabilization: Magnetic resonance image evaluation with a mean followup of four years. *Adv Orthop* 2013:437570, 2013
11. Goel VK, Gilbertson LG: Basic science of spinal instrumentation. *Clin Orthop Relat Res* 335:10-31, 1997
12. Goel VK, Konz RJ, Chang HT, Grosland NM, Grobler LJ, Chesmel KD: Hinged-dynamic posterior device permits greater loads on the graft and similar stability as compared with its equivalent rigid device: A three-dimensional finite element assessment. *JPO* 13(1):17-20, 2001
13. Graf H: Lumbar instability: Surgical treatment without fusion. *Rachis* 412:123-137, 1992
14. Grob D, Benini A, Junge A, Mannion AF: Clinical experience with the Dynesys semirigid fixation system for the lumbar spine: Surgical and patient-oriented outcome in 50 cases after an average of 2 years. *Spine (Phila Pa 1976)* 30(3):324-331, 2005

15. Ko CC, Tsai HW, Huang WC, Wu JC, Chen YC, Shih YH, Chen HC, Wu CL, Cheng H: Screw loosening in the Dynesys stabilization system: Radiographic evidence and effect on outcomes. *Neurosurg Focus* 28(6):E10, 2010
16. Korovessis P, Papazisis Z, Koureas G, Lambiris E: Rigid, semirigid versus dynamic instrumentation for degenerative lumbar spinal stenosis: A correlative radiological and clinical analysis of short-term results. *Spine (Phila Pa 1976)* 29(7):735-742, 2004
17. Liu C, Kamara A, Yan Y: Investigation into the biomechanics of lumbar spine micro-dynamic pedicle screw. *BMC Musculoskelet Disord* 19(1):231, 2018
18. Lutz JA, Otten P, Maestretti G: Late infections after dynamic stabilization of the lumbar spine with Dynesys. *Eur Spine J* 21(12):2573-2579, 2012
19. Meyer B, Thomé C, Vajkoczy P, Kehl V, Dodel R, Ringel F; DYNORFUSE Study Group: Lumbar dynamic pedicle-based stabilization versus fusion in degenerative disease: A multicenter, double-blind, prospective, randomized controlled trial. *J Neurosurg Spine* 22:1-10, 2022
20. Ozer AF, Aydın AL, Hekimoglu M, Cerezci O, Basak AT, Ates O, Oktenoglu T, Sasani M: Should iliac wing screws be included in long segment dynamic stabilization? *Cureus* 13(2):e13543, 2021
21. Ozer AF, Basak AT, Ozbek MA, Hekimoglu M, Aydın AL, Ates O, Gunerbuyuk C, Akgul T, Sasani M, Oktenoglu T: Lumbar dynamic stabilization with 2-stage surgery: Early results. *Int J Spine Surg* 20:8306, 2022
22. Ozer AF, Cevik OM, Erbulut DU, Yaman O, Senturk S, Oktenoglu T, Sasani M, Suzer T, Goel V: A novel modular dynamic stabilization system for the treatment of degenerative spinal pathologies. *Turk Neurosurg* 29(1):115-120, 2019
23. Panjabi MM: The stabilizing system of the spine. Part I. Function, dysfunction, adaptation, and enhancement. *J Spinal Disord* 5(4):383-389, 1992
24. Pham MH, Mehta VA, Patel NN, Jakoi AM, Hsieh PC, Liu JC, Wang JC, Acosta FL: Complications associated with the Dynesys dynamic stabilization system: A comprehensive review of the literature. *Neurosurg Focus* 40(1):E2, 2016
25. Schmoelz W, Onder U, Martin A, Stempel AV: Non-fusion instrumentation of the lumbar spine with a hinged pedicle screw rod system: An in vitro experiment. *Eur Spine J* 18(10):1478-1485, 2009
26. Scifert JL, Sairyo K, Goel VK, Grobler LJ, Grosland NM, Spratt KF, Chesmel KD: Stability analysis of an enhanced load sharing posterior fixation device and its equivalent conventional device in a calf spine model. *Spine (Phila Pa 1976)* 24(21):2206-2213, 1999
27. Von Stempel A, Moosmann D, Stoss C, Martin A: Stabilization of the degenerated lumbar spine in the nonfusion technique with cosmic posterior dynamic system. *WSJ* 1:40-47, 2006
28. Wang H, Peng J, Zeng Q, Zhong Y, Xiao C, Ye Y, Huang W, Liu W, Luo J: Dynesys system vs posterior decompression and fusion for the treatment of lumbar degenerative diseases. *Medicine (Baltimore)* 99(21):e19784, 2020
29. Wiltse L, Spencer C. New uses and refinements of the paraspinous approach to the lumbar spine. *Spine*. 1988;13:696-706.
30. Würgler-Hauri CC, Kalbarczyk A, Wiesli M, Landolt H, Fandino J: Dynamic neutralization of the lumbar spine after microsurgical decompression in acquired lumbar spinal stenosis and segmental instability. *Spine (Phila Pa 1976)* 33(3):E66-72, 2008
31. Yilmaz A, Senturk S, Sasani M, Oktenoglu T, Yaman O, Yildirim H, Suzer T, Ozer AF: Disc rehydration after dynamic stabilization: A report of 59 cases. *Asian Spine J* 11(3):348-355, 2017