



DOI: 10.5137/1019-5149.JTN.17618-16.1

Received: 17.03.2016 / Accepted: 25.04.2016

Published Online: 21.09.2016

Original Investigation

Comparative Histopathological Evaluation of Patients with Diabetes, Hypothyroidism and Idiopathic Carpal Tunnel Syndrome

Figen TASER¹, Ayse Nur DEGER², Hakkı DEGER³

¹Dumlupınar University, Medical Faculty, Department of Anatomy, Kutahya, Turkey

²Dumlupınar University, Medical Faculty, Department of Pathology, Kutahya, Turkey

³Dumlupınar University, Evliya Celebi Training Hospital, Neurosurgery Clinic, Kutahya, Turkey

ABSTRACT

AIM: To investigate and compare the histological findings of patients with diabetes, hypothyroidism and idiopathic carpal tunnel syndrome (CTS).

MATERIAL and METHODS: Subsynovial connective tissue samples of 51 idiopathic CTS patients (Group 1), 58 diabetic CTS patients (Group 2) and 16 hypothyroid CTS patients (Group 3) were evaluated in this study. The histopathological examination parameters were; number of fibroblasts, size of collagen fibers, vascular changes (vascular proliferation, intimal thickening and changes of vessel structures), edema and inflammatory infiltration.

RESULTS: In the majority of patients in all 3 groups, non-inflammatory fibrosis was observed in subsynovial connective tissue. Number of fibroblasts, collagen fiber diameter and lengths were statistically different in diabetic CTS patients (Group 2) when compared with other groups. Considering the overall results, neovascularization in subsynovial connective tissue was observed significantly more intensely in diabetic CTS patients (Group 2) and severe edema was found in hypothyroid CTS patients (Group 3).

CONCLUSION: Increased pressure in the carpal tunnel may be a result of reduction of the space or volume increase of the tunnel contents secondary to fibrosis or edema. It may be helpful for the physicians to better understand the causes of this entrapment neuropathy, and these etiological factors should be taken into consideration during the preoperative evaluation of the patients.

KEYWORDS: Carpal tunnel syndrome, Diabetes mellitus, Hypothyroidism, Histopathology, Subsynovial connective tissue, Idiopathic carpal tunnel syndrome

ABBREVIATIONS: CTS: Carpal tunnel syndrome, EMG: Electromyography

INTRODUCTION

Carpal Tunnel Syndrome (CTS) is the most common entrapment neuropathy secondary to different etiological factors. Increased pressure within the carpal tunnel causes disruption of the blood supply of median nerve under ligamentum carpi transversum (6,13). Increased

pressure within the carpal tunnel may also be due to reduction of space or increase of the volume of tunnel contents (4,16-18). Recent studies showed that subsynovial connective tissue could lead to increase in the volume carpal tunnel contents and may change ingredients like vascularity and fluid flows with changing permeability and compliance (7).



Corresponding author: Figen TASER

E-mail: figentaser@yahoo.com

When the anatomical structure of this region is examined, the groove of the palmar side is covered by the flexor retinaculum to form the carpal tunnel. The flexor retinaculum is attached radially to the scaphoid tubercle and the ridge of trapezium, and on the ulnar side to the pisiform and hook of hamate. There are two tenosynovial sheaths in the carpal tunnel. The ulnar sheath covers the tendons of flexor digitorum superficialis and profundus and while the tendon of the flexor pollicis longus passes through a separate radial sheath. The median nerve passes through the tunnel between the tendons of flexor digitorum profundus and flexor digitorum superficialis (25,26).

The most common histological finding in CTS is non-inflammatory synovial fibrosis (7,16-18). Patients with idiopathic CTS may have exposed to an injury in subsynovial connective tissue. Therefore histological findings are similar with those of other tissues like skin, tendon or ligaments. Increased fibroblast density and collagen fiber size, and also vascular proliferation have been shown in recent studies on idiopathic CTS (7).

Thyroid diseases can lead to musculoskeletal dysfunctions such as muscle weakness or CTS (3,21,23). Hypothyroidism can increase the volume within the tunnel by changing fluid balance into the body (12). We could not find any histopathological study on the CTS patients who had hypothyroidism.

Diabetes mellitus can be defined as a neuropathic factor on the development of CTS without increasing the interstitial pressure in the median nerve. Diabetic patients have higher tendency to CTS due to lower threshold for nerve damage (12).

This study was planned to investigate the histopathological findings in subsynovial connective tissue of CTS patients with different etiopathogenesis like diabetes mellitus, hypothyroidism and idiopathic CTS.

■ MATERIAL and METHODS

This is a retrospective study. Subsynovial connective tissue samples of 51 idiopathic CTS patients (Group 1), 58 diabetic CTS patients (Group 2) and 16 hypothyroid CTS patients (Group 3) were evaluated in this study. Informed consent for surgical treatment was obtained from all of the patients in this study.

Paresthesia along the median nerve trace and hand pain during the day or night were the main symptoms of CTS in our patients. Also, positive findings like sensitivity and provocative tests during the physical examination were used to confirm the diagnosis of CTS. The patients with diagnosis of diabetes mellitus at least 5 years, whose hemoglobin A1c results were above 7%, were included in this study as diabetic CTS patient group.

Electromyography (EMG) was performed in all patients with suspected CTS. CTS grade by EMG results was staged as mild, moderate and severe. Non-steroidal anti-inflammatory and vitamin B12 medications and also splints were used for treatment of CTS patients. Patients with continued complaints

unresponsive to these treatments underwent surgical treatment. Standard carpal tunnel release was performed by the surgeon. Patients were operated under local anesthesia with minimally invasive technique. On the palmar side of the hand, a 1 cm vertical incision from the wrist bend to fit the imaginary line between the middle finger and ring finger was made. Skin and subcutaneous incisions were performed and broader view was achieved with surgical devices (Figure 1). Subsynovial connective tissue about 0.5 cm³ in volume was excised after the bright pearl transverse carpal ligament and the median nerve was seen. One cc saline solution was injected to the perineurium in order to decrease the hydrostatic pressure. Thus carpal tunnel was decompressed.

Connective tissue samples in 10% buffered formalin solution were immediately transferred to the histopathology laboratory. Paraffin-embedded blocks were prepared from tissue samples and 4 µm-thickness sections were obtained. Standard hematoxylin-eosin (H&E) staining was performed. This procedure was performed at room temperature.

The histopathological examination parameters were:

1. Number of fibroblasts: Fibroblasts were counted at magnification area (X400).
2. Size of collagen fibers: Mean size (µm) was calculated measuring transverse and longitudinal dimensions of 20 fibers within every magnification area (X400) at slices of each tissue sample.
3. Vascular changes: Vascular proliferation, intimal thickness and changes of vascular structures were evaluated. Findings were classified as “no change”, “mild”, “moderate” and “severe change” of the vessels.
4. Edema: Findings were classified as no change, mild, moderate and severe edema.
5. Inflammatory infiltration: Findings were classified as no inflammation, mild, moderate and severe inflammation.

Statistical analysis for comparisons of idiopathic versus diabetic CTS patients was performed by Student-t test.

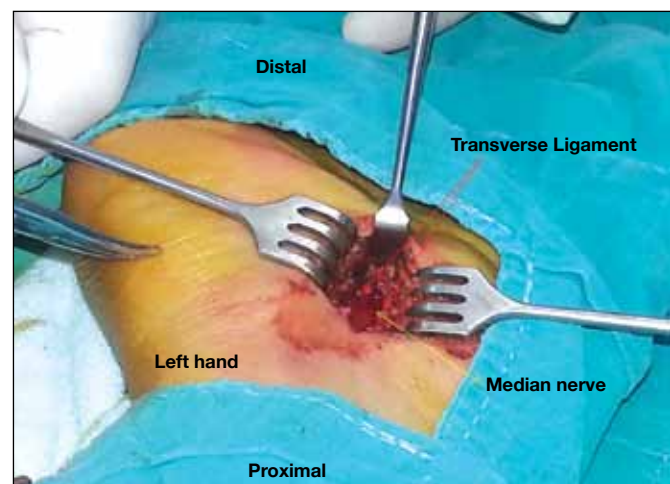


Figure 1: Image of carpal tunnel decompression surgery.

We also used the nonparametric Mann-Whitney U test for comparisons regarding hypothyroid CTS patients because of the patient group. Correlations were determined by Spearman's rank correlation coefficient test using the SPSS 15.0 program. $p < 0.05$ was considered as statistically significant.

■ RESULTS

Evaluation of demonstrative characteristics showed that female patients were more common than male patients in all groups. The female/male percentage rate was 80%/20% for the idiopathic CTS and diabetic CTS groups, and 88%/12% for the hypothyroid CTS group. The mean age was not significantly different between the groups, and it was around 50-55 years. While changes in EMG looked more prominent in diabetic CTS patients group the difference was not statistically significant. Demonstrative characteristics of patients are shown in Table I.

Non-inflammatory fibrosis was observed in the subsynovial connective tissue in the majority of all 3 patient groups. Number of fibroblasts, collagen fiber diameters and lengths were statistically different in the diabetic CTS patients group when compared with other groups ($P < 0.05$) (Figures 2-5). Comparative evaluation of fibroblast proliferation and collagen fiber size of patients with idiopathic CTS, diabetic CTS and hypothyroid CTS patients is shown in Table II.

Vascular proliferation, vascular hypertrophy and intimal thickening were observed in all groups. Moderate and severe increase in vascular changes was especially found in the diabetic CTS group. This increase was statistically

significantly different from the idiopathic CTS and hypothyroid CTS patients groups ($P < 0.05$) (Figures 6, 7). Comparative evaluation of vascular changes in patients with idiopathic CTS, diabetic CTS and hypothyroid CTS is shown in Table III.

Histomorphological changes including fibrosis and vascular changes were more intense in diabetic CTS patients when compared with the other groups ($p < 0.05$).

Tissue edema was seen in varying degrees. Table IV shows comparative evaluation of tissue edema in CTS with different etiopathogenesis. Especially hypothyroid CTS patients had severe edema within the synovial tissue ($p < 0.05$) (Figure 7).

Considering the overall histopathological results, neovascularization in subsynovial connective tissue was significantly more intense in diabetic CTS patients and severe edema was found in hypothyroid CTS patients (Figure 8). There was a positive correlation between fibroblast proliferation, collagen fiber size and vascular changes ($r = 0.675$, $p < 0.001$).

■ DISCUSSION

CTS is a common disease which can be accompanied with inflammatory, metabolic, rheumatologic, immunologic or neuropathic conditions besides of idiopathic cases (1).

There are many studies on the pathophysiological, biochemical, electrophysiological and clinical aspects of CTS (6,7,24,28,30). The most popular theories on the pathogenesis of CTS are mechanical compression, microvascular insufficiency and vibration theories (1). Recent studies demonstrated that non-inflammatory thickening, fibrosis and vascular proliferation

Table I: Demographic Characteristics of CTS Patients with Different Etiological Factors

Parameter	Idiopathic CTS patient group (n=51)	Diabetic CTS patient group (n=58)	Hypothyroid CTS patient group (n=16)
Gender (F/M)	41/10	47/11	14/2
Mean Age-years (Range)	50 (37-74)	53 (16-76)	54 (40-68)
CTS Grade by EMG			
Mild	22 (% 43)	18 (% 31)	5 (% 31)
Moderate	21 (% 41)	26 (% 45)	9 (% 56)
Severe	8 (% 16)	14 (% 24)	2 (% 13)

EMG: Electromyography, **CTS:** Carpal tunnel syndrome, **F:** Female, **M:** Male.

Table II: Comparative Evaluation of Fibroblast Proliferation and Collagen Fiber Size in CTS Patients with Different Etiological Factors

Parameter	Idiopathic CTS patient group (n=51)	Diabetic CTS patient group (n=58)	Hypothyroid CTS patient group (n=16)
Number of fibroblasts	55.77±11.83	62.24 ±15.37*	45.88 ±5.72
Collagen Fiber Diameter (µm)	1.97±0.38	2.74±0.5*	1.99±0.3
Collagen Fiber Length (µm)	8.97±2.21	11.96±2.53*	9.33±2.43

$p < 0.05$ for comparison of diabetic CTS patient group with other groups. **CTS:** Carpal tunnel syndrome.

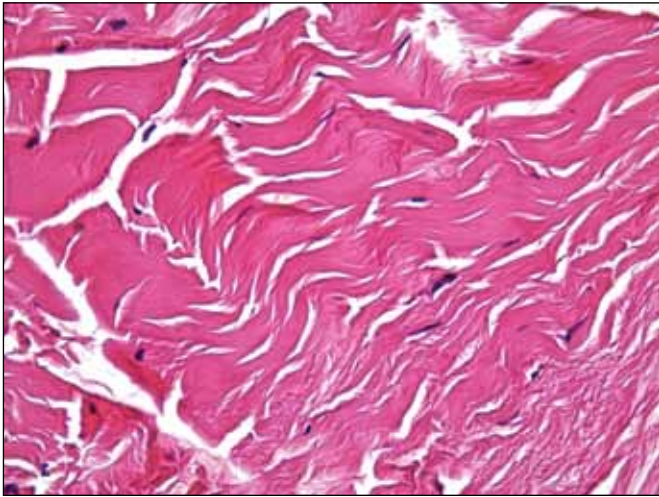


Figure 2: Idiopathic CTS group, fibroblast proliferation (H&E, x400).

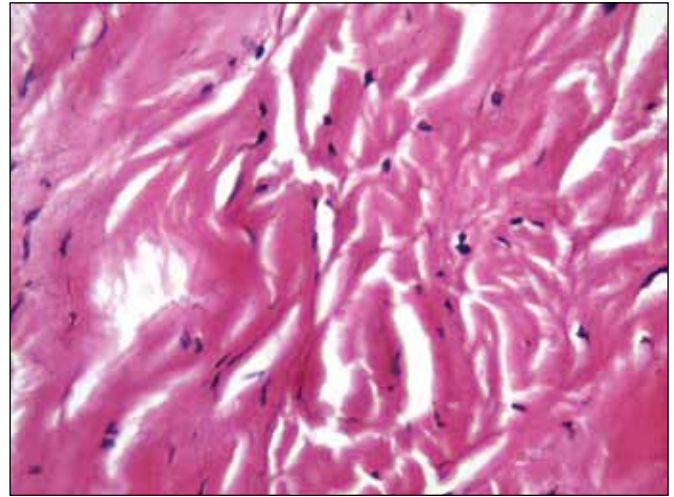


Figure 3: Diabetic CTS group, severe fibroblast proliferation (H&E, x400).

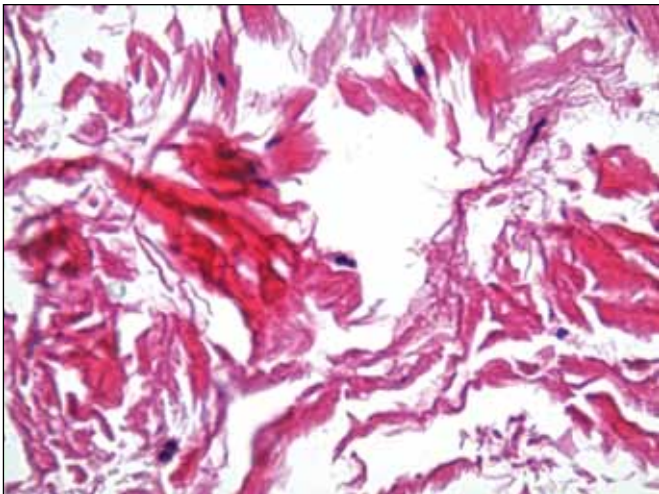


Figure 4: Hypothyroid CTS group, fibroblast proliferation (H&E, x400).

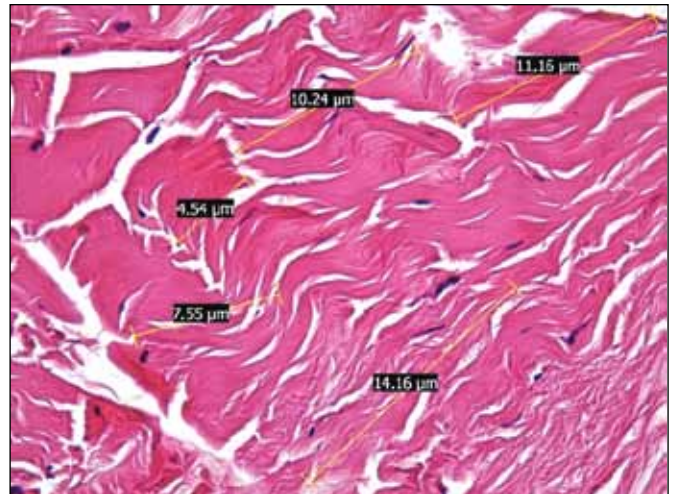


Figure 5: Diabetic CTS group, collagen fiber dimensions (µm). (H&E, x400).

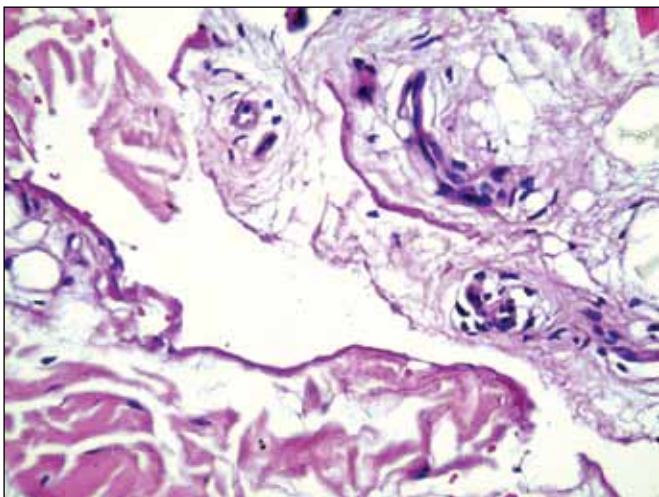


Figure 6: Idiopathic CTS group, relatively mild vascular changes (H&E, x400).

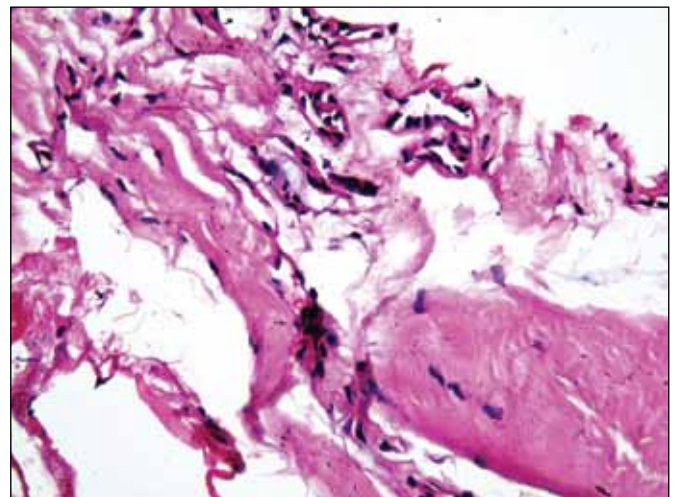


Figure 7: Diabetic CTS group, severe vascular changes, vascular hypertrophy, intimal thickening in the subsynovial tissue (H&E, x400).

within the subsynovial connective tissue play an important role on the development of idiopathic CTS (6,7,30). These histopathological changes might increase the volume and pressure in the carpal tunnel that result in ischemia and reperfusion of the tenosynovium (30).

There are many studies regarding the histopathological changes in idiopathic CTS (6,7,9-11,13). Donato et al. (6) performed a study on idiopathic CTS in 19 female and 7 male patients and found fibrosis and vascular proliferation in the subsynovial connective tissue. Their detailed histopathological study with transmission electron microscopy showed small vessels with stratified and hypertrophied endothelial cells.

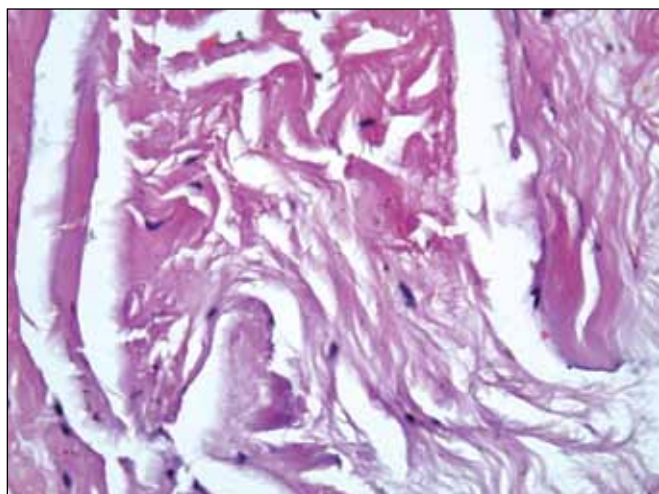


Figure 8: Hypothyroid CTS group, severe tissue edema. (H&E, x400).

They also found that the luminal compartment is absent or narrow and pericytes exist around these small vessels. The junctions between endothelial cells are abnormal with large fusion membranes. Irregular bundles of collagen were shown within the connective tissue fibrosis (6). Ettema et al. (7) found increased fibroblast density, collagen fiber size and vascular proliferation in subsynovial connective tissue of patients with idiopathic CTS (7). Werthel et al. (30) created an animal model of experimental CTS by repeated glucose injections into the carpal tunnel. They found connective tissue proliferation, fibrosis with thicker and irregular fibers of subsynovial connective tissue and also vascular changes (vascular proliferation with an obstructed lumen and thickened wall) (30). Oh et al. (19) measured collagen fibers diameters and calculated their densities using transmission electron microscopy in specimens from ten patients with idiopathic CTS and from ten fresh-frozen cadavers without CTS. They found deformed collagen fibers with a spiraled appearance, phagocytosis of elastin fibrils in diabetic CTS group (19).

Diabetes mellitus especially has a strong relationship with CTS (4,8,14,20,28,29). CTS prevalence is 15-30% in diabetic patients (2,5,22). A number of studies on diabetic and idiopathic CTS are published in the literature (14,28). Karpitskaya et al. (14) found that CTS is associated with physical and personal factors including smoking, obesity, diabetes mellitus, and hypothyroidism in a retrospective case-control study of 514 patients.

The most related article on this subject was published by Tekin et al. (28) and they compared diabetic and idiopathic CTS patients. Synovial hyperplasia, fibrosis and perivascular inflammation were not observed in either group (28). In our study, we have also not seen inflammation. However,

Table III: Comparative Evaluation of Vascular Changes (Percentage) in CTS Patients with Different Etiological Factors

Vascular Changes	Idiopathic CTS patient group (%)	Diabetic CTS patient group (%)	Hypothyroid CTS patient group (%)
No change	33	22	56
Mild increase	45	38	31
Moderate increase	8	21*	13
Severe increase	4	19*	-

* $p < 0.05$ for comparison of diabetic CTS patient group with other groups. **CTS:** Carpal tunnel syndrome.

Table IV: Comparative Evaluation of Tissue Edema (Percentage) in CTS with Different Etiological Factors

Edema	Idiopathic CTS patient group (%)	Diabetic CTS patient group (%)	Hypothyroid CTS patient group (%)
No edema	29	12	6
Mild edema	51	50	5
Moderate edema	8	28	49*
Severe edema	2	10	40*

* $p < 0.05$ for comparison of hypothyroid CTS patient group with other groups. **CTS:** Carpal tunnel syndrome.

increased fibroblasts and fibroblast size that indicated fibrosis were found in all three groups of CTS patients. Tekin et al. (28) indicated that diabetic CTS patients had higher rates of synovial edema (57% in idiopathic CTS & 87% in diabetic CTS), vascular proliferation (30.8% in idiopathic CTS & 90.5% in diabetic CTS) and increased vascular wall thickness (11.5% in idiopathic CTS & 90.5% in diabetic CTS). In our study, we found more significant edema in hypothyroid CTS patients group.

Thyroid diseases are also related with musculoskeletal disorders like adhesive capsulitis, Dupuytren's contracture, trigger finger, limited joint mobility and carpal tunnel syndrome (3,15,16,23,24,26). Shiri found only a modest association between hypothyroidism and CTS in a meta-analysis study (27). Cakir et al. (3) revealed that 9.5% of patients had CTS among 137 thyroid disease patients with musculoskeletal disorders. They also stated that CTS was significantly more prevalent in the hypothyroid patients group (3). Palumbo et al. (21) showed that CTS symptoms are common in hypothyroid patients even when they are euthyroid. They also indicated that standards for assessing normal median nerve latencies may be significantly different in hypothyroid patients (21). Roquer et al. (23) stated that the symptoms of CTS remitted if endocrinopathy is controlled and surgery is usually not necessary in these patients (23). We could not find a histopathological study among CTS patients with thyroid disease. In our study, we found significant severe edema within the synovial tissue in hypothyroid patients with CTS ($p < 0.05$).

■ CONCLUSION

It is crucial to understand and take into consideration the causes of this entrapment neuropathy during preoperative evaluation. This may be helpful for the physicians to plan further treatment of CTS patients with different etiological factors.

■ ACKNOWLEDGEMENT

The authors would like to express their appreciation to Dumlupinar University Scientific Research Unit for their financial support (Project Code: DPU BAP 2012/17).

■ REFERENCES

1. Aroori S, Spence RAJ: Carpal tunnel syndrome. *Ulster Med J* 77(1):6-17, 2008
2. Atroshi I, Gummesson C, Johnson R, Ornstein E, Ranstam J, Rosen I: Prevalence of carpal tunnel syndrome in general population. *JAMA* 282(2):153-158, 1999
3. Cakir M, Samanci N, Balci N, Balci MK: Musculoskeletal manifestations in patients with thyroid disease. *Clin Endocrinol* 59:162-167, 2003
4. Chen LH, Li CY, Kuo LC, Wang LY, Kuo KN, Jou IM, Hou WH: Risk of hand syndromes in patients with diabetes mellitus: A population-based cohort study in Taiwan. *Medicine (Baltimore)* 94(41):e1575, 2015
5. De Krom MC, Knipschild PG, Kester AD, Thijs CT, Boekkooi PF, Spaans F: Carpal tunnel syndrome: Prevalence in the general population. *J Clin Epidemiol* 45(4):373-376, 1992
6. Donato G, Galasso O, Valentino P, Conforti F, Zuccalà V, Russo E, Maltese L, Perrotta I, Tripepi S, Amorosi A: Pathological findings in subsynovial connective tissue in idiopathic carpal tunnel syndrome. *Clin Neuropathol* 28:129-135, 2009
7. Ettema AM, Amadio PC, Zhao C, Wold LE, An KN: A histological and immunohistochemical study of the subsynovial connective tissue in idiopathic carpal tunnel syndrome. *J Bone Joint Surg Am* 86:1458-1466, 2004
8. Fatemi A, Iraj B, Barzanian J, Maracy M, Smiley A: Musculoskeletal manifestations in diabetic versus prediabetic patients. *Int J Rheum Dis* 18(7):791-799, 2015
9. Fuchs PC, Nathan PA, Myers LD: Synovial histology in carpal tunnel syndrome. *J Hand Surg Am* 16:753-758, 1991
10. Gallaso O, Mariconda M, Donato G, Di Mizio G, Padua L, Brando A, Conforti F, Valentino P, Gasparini G: Histopathological, clinical and electrophysiological features influencing post-operative outcomes in carpal tunnel syndrome. *J Orthop Res* 29:1298-1304, 2011
11. Gross AS, Louis DS, Carr KA, Weiss SA: Carpal tunnel syndrome: A clinicopathologic study. *J Occup Environ Med* 37:437-441, 1995
12. Ibrahim I, Khan WS, Goddard N, Smitham P: Carpal tunnel syndrome: A review of the recent literature. *Open Orthop J* 6:69-76, 2012
13. Jinrok O, Zhao C, Amadio PC, An KN, Zobitz ME, Wold LE: Vascular pathologic changes in the flexor tenosynovium (subsynovial connective tissue) in idiopathic carpal tunnel syndrome. *J Orthop Res* 22: 1310-1315, 2004
14. Karpitskaya Y, Novak CB, Mackinnon SE: Prevalence of smoking, obesity, diabetes mellitus, and thyroid disease in patients with carpal tunnel syndrome. *Ann Plast Surg* 48(3):269-273, 2002
15. Kececi H, Degirmenci Y: Hormone replacement therapy in hypothyroidism and nerve conduction study. *Neurophysiol Clin* 36(2):79-83, 2006
16. Llunch AL: Thickening of synovium of the digital flexor tendons: Cause or consequence of the carpal tunnel syndrome? *J Hand Surg Br* 17:209-212, 1992
17. Nakamichi K, Tachibana S: Histology of the transverse carpal ligament and flexor tenosynovium in idiopathic carpal tunnel syndrome. *J Hand Surg Am* 23:1015-1024, 1998
18. Neal NC, McManners J, Stirling GA: Pathology of the flexor tendon sheath in the spontaneous carpal tunnel syndrome. *J Hand Surg Br* 12:229-232, 1987
19. Oh J, Zhao C, Zobitz ME, Wold LE, An KN, Amadio PC: Morphological changes of collagen fibrils in the subsynovial connective tissue in the carpal tunnel syndrome. *J Bone Joint Surg Am* 88(4):824-833, 2006
20. Oktayoglu P, Nas K, Kilinc F, Tasdemir N, Bozkurt M, Yildiz I: Assessment of the presence of carpal tunnel syndrome in patients with diabetes mellitus, hypothyroidism and acromegaly. *J Clin Diagn Res* 9(6):14-18, 2015

21. Palumbo CF, Szabo RM, Olmsted SL: The effects of hypothyroidism and thyroid replacement on the development of carpal tunnel syndrome. *J Hand Surg* 25: 734-739, 2000
22. Pandey A, Usman K, Reddy H, Gutch M, Jain N, Qidwai S: Prevalence of hand disorders in type 2 diabetes mellitus and its correlation with microvascular complications. *Ann Med Health Sci Res* 3(3):349-354, 2013
23. Roquer J, Cano JF: Carpal tunnel syndrome and hyperthyroidism. A prospective study. *Acta Neurologica Scandinavica* 88:149-152, 1993
24. Scelsi R, Zanlungo M, Tenti P: Carpal tunnel syndrome. Anatomical and clinical correlations and morphological and ultrastructural aspects of the tenosynovial sheath. *Ital J Orthop Traumatol* 15:75-80, 1989
25. Schmidt HM, Lanz U: *Surgical Anatomy of the Hand*. Thieme: 2003:29
26. Schuenke M, Schulte E, Schumacher U, Ross LM, Lamperti ED, Voll M: *Thieme Atlas of Anatomy: General Anatomy and Musculoskeletal System*. Thieme: 2006: 248,249, 354
27. Shiri R: Hypothyroidism and carpal tunnel syndrome: A meta-analysis. *Muscle Nerve* 50(6):879-883, 2014
28. Tekin F, Surmeli M, Simsek H, Ceran C, Tezcan S, Taner OF, Simsek HG: Comparison of the histopathological findings of patients with diabetic and idiopathic carpal tunnel syndrome. *Int Orthop* 39(12):2395-2401, 2015
29. Vashishtha M, Varghese B, Mosley F, Kadakia A, de Jager W: Screening for thyroid dysfunction and diabetes in patients with carpal tunnel syndrome. *Surgeon* 18(14):144-149, 2014
30. Werthel JDR, Zhao C, An KN, Amadio PC: Carpal tunnel syndrome pathophysiology: Role of subsynovial connective tissue. *J Wrist Surg* 3:220-226, 2014