

Vertebral Body Pneumatocyst in the Cervical Spine and Review of the Literature

Servikal Omurda Yerleşik Pnömatokist ve Literatürün Gözden Geçirilmesi

ABSTRACT

A pneumatocyst in the cervical spine is extremely rare and to our knowledge only a few reports have been published in the English literature. Although the etiology and natural course of vertebral body pneumatocyst is unclear, nitrogen gas accumulation is claimed. A 65-year-old-man was admitted to the emergency department with neck pain and numbness and incapacity in his both hands and fingers. The radiological images revealed a vertebral located pneumatocyst in the C4 cervical vertebra. In this report, we present a case of cervical pneumatocyst located in the C4 vertebral body. The clinical and radiological features and natural course of the pneumatocyst were evaluated.

KEY WORDS: Cervical spine, Conservative management, CT scan, Pneumatocyst

ÖZ

Servikal omurga yerleşimli pnömatokistler oldukça nadir olarak görülür ve bildiğimize göre İngiliz kaynaklı literatürlerde yayınlamış sadece birkaç makale vardır. Vertebral cisim yerleşimli pnömatokistlerin etyolojisi ve doğal seyri tam olarak bilinmemesine rağmen, nitrojen gazı birikmesinden kaynaklandığı düşünülmektedir. Altmış beş yaşında erkek hasta boyun ağrısı ve her iki el ve parmaklarında hissizlik ve beceriksizlik şikayetiyle acil birimimize başvurdu. Radyolojik görüntülemelerinde servikal omurgada 4. vertebral cisim yerleşimli pnömatokist tesbit edildi. Biz bu yazıda, C4 vertebral cisim yerleşimli servikal pnömatokist olgusu sunuyoruz. Pnömatokistin klinik ve radyolojik özellikleri ve doğal seyri de değerlendirildi.

ANAHTAR SÖZCÜKLER: Servikal omurga, Konservatif tedavi, BT, Pnömatokist

Murat COŞAR¹

Olca EŞER²

Adem ASLAN³

Serhat KORKMAZ⁴

Gazi BOYACI⁵

Bumin DEĞİRMENCI⁶

Ramazan ALBAYRAK⁷

- ¹ Canakkale 18 March University, Faculty of Medicine, Department of Neurosurgery, Canakkale, Turkey
- ^{2,3,4,5} Kocatepe University, Faculty of Medicine, Department of Neurosurgery, Afyonkarahisar, Turkey
- ^{6,7} Kocatepe University, Faculty of Medicine, Department of Radiology, Afyonkarahisar, Turkey

Received: 15.01.2008

Accepted: 14.04.2008

Correspondence address:

Murat COŞAR

PK:89, 17000, Canakkale / TURKEY

Phone: +90 505 8041362

Fax: +90 286 2130393

E-mail: drcosar@hotmail.com

INTRODUCTION

Interosseous gas collection is observed in some pathological processes such as, osteomyelitis, trauma, neoplasm, and osteonecrosis [2,3]. Pneumatocyst is a rare condition in which there is gas-filled cystic lesion of uncertain origin in the bone and it is frequently observed in the ileum and sacrum adjacent to the sacroiliac joint [1]. A pneumatocyst in the cervical spine is extremely rare and to our knowledge only a few reports have been published in the English literature [1-3]. All the published spinal pneumatocyst cases were located below the fourth cervical vertebra and our case is the first pneumatocyst case located in the C4 vertebra. We have not encountered a cervical body pneumatocyst above the C4 level in the literature. In this report, we present a cervical pneumatocyst case located in the C4 vertebral body.

CASE REPORT

A 65-year-old man was admitted to our clinic with neck pain for 2 years' duration. He was suffering from severe neck pain, numbness and incapacity in his both hands and fingers. The neurological examination of the patient revealed atrophy of the thenar and hypothenar muscles in both hands with decreasing capacity of muscle strength. Anteroposterior and lateral x-rays of the cervical spine revealed a radiolucent lesion in C4 vertebral body with cervical stenosis findings and multiple-level degenerative disc disease. Multidetector computed tomography (MDCT) revealed an irregular lesion around 11x11x12 mm in diameter filled with gas (HU=-890) in the C4 vertebral body (Figure 1,2,3). MRI was added to the radiological investigation to eliminate the extra pathologies associated with neural structures and the diagnosis was confirmed. Contrast-enhanced MDCT and MRI showed no enhancement of lesions. Additionally, the lesion was not communicating with the intervertebral disc space but there was communication with the spinal canal. Electromyography of bilateral upper extremities was performed and showed bilateral severe carpal tunnel syndrome (CTS). The patient underwent a bilateral CTS operation in a 3-month period and the cervical neck pain was treated with anti-inflammatory agents. The follow-up neurological examination of the patient was uneventful and cervical radiological images were stable 6 months after the first operation.

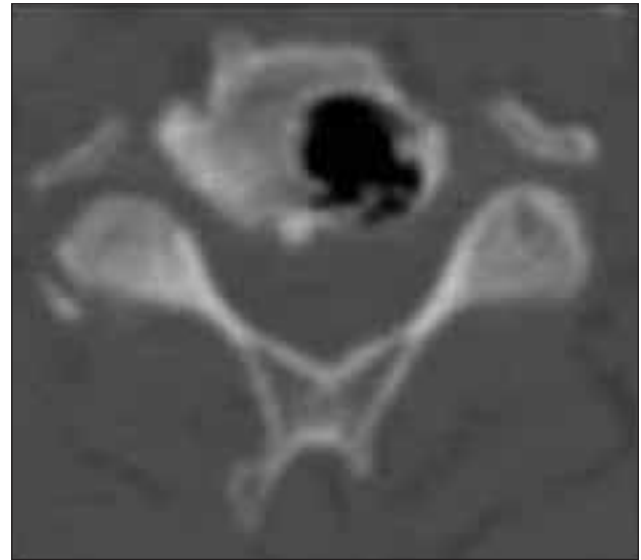


Figure 1: Axial section of cervical vertebrae CT showing pneumatocyst in the body of C4 vertebra.

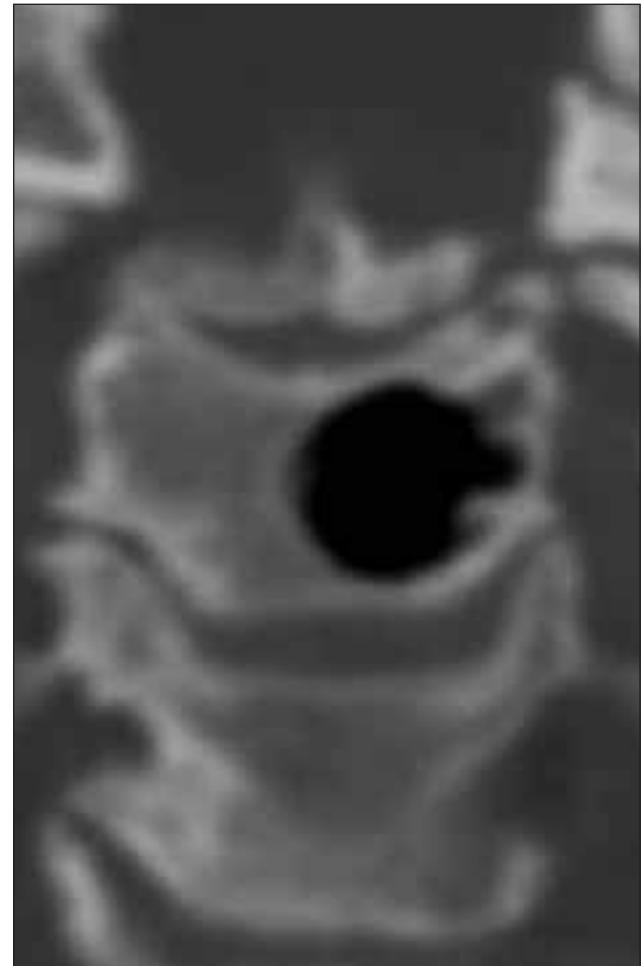


Figure 2: Coronal section of cervical vertebrae showing pneumatocyst in the body of C4 vertebrae.

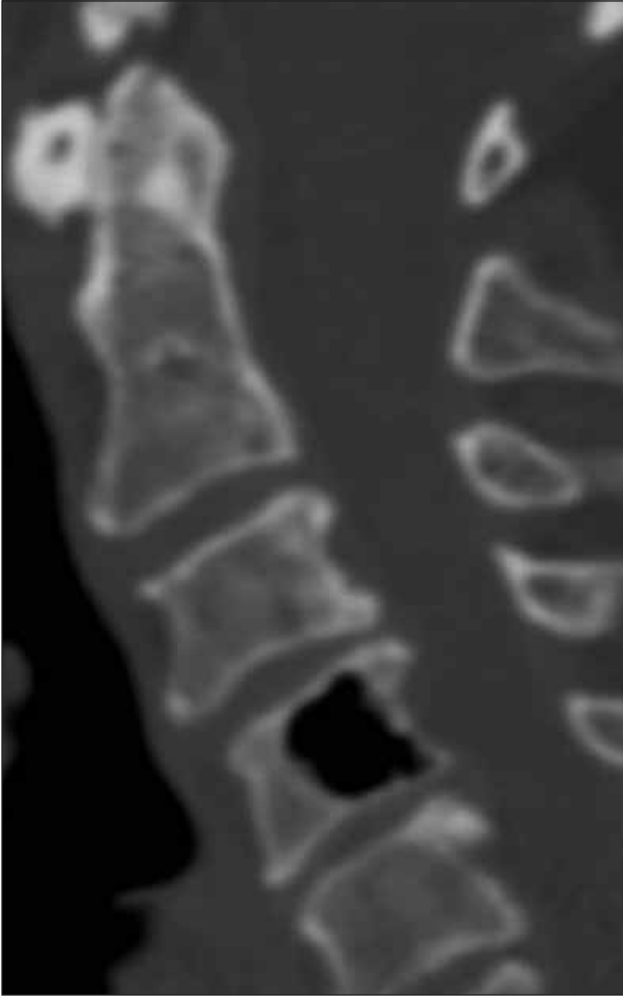

Figure 3: Sagittal section of cervical vertebrae CT showing pneumatocyst in the body of C4 vertebra.

DISCUSSION

The vertebral body is an uncommon localization for gas accumulation and to our knowledge 8 pneumatocyst cases have been reported in the body of the cervical vertebrae. We think that our case is the 9th case located in the cervical vertebral body in the literature. Five of them were located in C5, two in C6 and one in C7 vertebral body [1-3]. Our case was located in the C4 vertebral body. To our knowledge, our case is the highest located pneumatocyst in the body of cervical vertebrae. Five of the nine cervical pneumatocysts were isolated in the vertebral body without any relation to the spinal canal and/or intervertebral disc and the remaining three cases had a relation with the intervertebral disc [1-3]. To our knowledge, our case is the first case communicating with the spinal canal and the biggest one reported in the English literature.

Although the etiology of cervical pneumatocyst is unclear except for pathological conditions, there are a few hypotheses about its natural course. The gas inside the pneumatocyst is primarily nitrogen. Some authors have stated that the cause is spontaneous development of intraosseous gas or vacuum degeneration from an intraosseous ganglion or synovial cyst [1,3]. Nitrogen gas extension from the intervertebral disk and adjacent joints into the vertebral body through the end plate may be the cause of pneumatocysts [1].

The natural course of the pneumatocyst cavity filled with nitrogen gas is unclear. Several authors have declared that the size of the pneumatocyst remained stable in the radiological examinations during 4 years of follow-up [1,2]. Yamamoto et al. [3] reported that the pneumatocyst progressed to fluid-filled cyst and then replaced with granulation tissue during the follow-up period. Kitagawa et al. [2] reported the first enlarging pneumatocyst during their 15-month follow-up.

The radiolucent and osteolytic images of pneumatocyst in plain radiographies may mimic metastatic lesions [3]. CT is the most useful radiological tool for the correct diagnosis of the pneumatocyst. The gas attenuation of pneumatocyst in the cervical body provides a range of CT values between -950 and -580 H [1,3]. Generally, the pneumatocyst shows homogenous hypointensity on T1- and T2-weighted MR images. Artifacts on MRI images are usual for cervical pneumocyst cases. Additionally, no contrast enhancement is seen on CT and MRI images [1].

In conclusion, cervical pneumatocyst in the vertebral body is a benign lesion and requires no specific treatment. However, the clinicians should note that the pneumatocyst may enlarge or be replaced with a fluid cyst during its natural course.

REFERENCES

1. Karasick D, Eason MA: Vertebral pneumatocyst mimicking susceptibility artifact on MR imaging. (letter) *AJR* 170: 221, 1998
2. Kitagawa T, Fujiwara A, Tamai K. Enlarging vertebral body pneumatocysts in the cervical spine. *AJNR* 24(8): 1707-1710, 2003
3. Yamamoto T, Yoshiya S, Kurosaka M: Natural course of an intraosseous pneumatocyst of the cervical spine. *AJR* 179(3): 667-679, 2002