

# Percutaneous Evacuation for Treatment of Subdural Hematoma and Outcome in 28 Patients

## *Subdural Hematomun Perkütan Yoldan Boşaltılması ve 28 Hastanın Sonuçları*

Keyvan MOSTOFI, Dominique MARNET

*Hopital Lorrain, Department of Neurosurgery, St Joseph, France*

Correspondence address: Keyvan MOSTOFI / E-mail: keyvan.mostofi@yahoo.fr

### ABSTRACT

**AIM:** Chronic subdural hematoma is a frequently encountered entity in neurosurgery in particular in elderly patients. There is a high variance in the treatment in literature.

**MATERIAL and METHODS:** We report our experience of percutaneous evacuation of chronic subdural hematoma in 28 patients.

**RESULTS:** From January 2007 to July 2009, 28 patients underwent percutaneous evacuation. 27 of the 28 patients (96.4%) became asymptomatic or improved clinically. Six weeks later, the scan showed the hematoma had completely disappeared in 18 of the cases. We did not have any postoperative infection.

**CONCLUSION:** Treatment of chronic subdural hematoma using a percutaneous operative technique is a minimally invasive method with sufficient outcome and a therapeutic alternative to the craniotomy.

**KEYWORDS:** Subdural hematoma, Percutaneous evacuation, Head trauma, Craniostomy

### ÖZ

**AMAÇ:** Kronik subdural hematom özellikle yaşlı hastalarda oldukça sık karşılaşılan bir sorundur. Literatürde tedavi yaklaşımları arasında önemli farklılıklar vardır.

**YÖNTEM ve GEREÇLER:** Kronik subdural hematomu olan ve perkütan yolla hematomları boşaltılan 28 hasta rapor edilmiştir.

**BULGULAR:** Tedavi edilen 28 hastanın 27'sinin belirtileri klinik olarak düzeldi. Beyin tomografisi ile yapılan 6 ay sonraki kontrollerinde 18 hastada hematomun tamamen kaybolduğu tesbit edildi. Vakaların hiçbirinde ameliyat sonrası enfeksiyon görülmedi.

**SONUÇ:** Kronik subdural hematomların perkütan yoldan cerrahi olarak boşaltılması etkin sonuçlar veren ve kraniyotomiye alternatif olan bir tedavi yöntemidir.

**ANAHTAR SÖZCÜKLER:** Subdural hematom, Cilt yolundan boşaltma, Kafa travması, Kraniyotomi

### INTRODUCTION

Chronic subdural hematoma is a frequently encountered entity in neurosurgery. It tends to occur with a higher frequency in elderly patients who have a greater life expectancy. This usually accompanies a rupture in the cortical veins and is usually traumatic and is more likely to appear in patients who have cerebral atrophy, alcoholism or in patients taking anticoagulants. It is a delayed complication of a benign trauma and often goes unnoticed. The estimated incidence is at 7.4 out of 1000000 [2]. It occurs predominantly in males at 63% according to Miranda et al. [13] The signs for the condition vary greatly. The diagnosis must be carried out in the midst of progressive neurological signs, which are unexplained.

There is a high degree of variance in the treatment, which is approached differently by the various clinics and surgeons. We

are presenting our findings in the treatment of the condition via percutaneous evacuation in an elderly population, a large part of whom are using anticoagulants, and most of whom are under general anesthesia.

### MATERIAL and METHODS

The study has been carried out retrospectively in the department of neurosurgery of the CHU of Fort de France over a period of 32 months, from January 2007 until July 2009. 28 patients displaying symptoms of chronic subdural hematoma were selected and operated using this technique.

The symptoms were headache, hemiparesis, gait disturbances, loss of balance, impaired memory, recurrent falls, confusion, mental disorder, weakness, and dizziness. It is about symptomatic patients receiving a CT scan without injection of contrast. The criteria for selection were: symptomatic

patients, with chronic subdural hematoma diagnosed on CT scan images, exerting a mass effect on midline structures. The hematoma's chronicity was defined by being in crescent shape appearance, hypodense fluid, and to help us we also made use of the Hounsfield Index (showing the density of the hematoma  $\geq 40$ ) calculated by the machine at the time of the initial CT exam. Patients who had a heterogeneous hematoma were not operated on using this technique. In most cases, surgery patients were either elderly undergoing treatment with anticoagulants for various reasons (history of cerebro-vascular accident (CVA), heart disease, etc), thus, making general anesthesia more dangerous and risky.

We quantified the volume of the hematoma using Advantage Workstation software. All 28 patients were operated on by the same surgeon (the principal author) using a percutaneous treatment technique. All procedures were performed under local anaesthesia. The patients were placed in a supine position with raised shoulder on the side of the haematoma and the head turned towards the contralateral side.

After the skin preparation, the main procedure began. The latter consisted of a stroke of the scalpel to cross the scalp. This scar was never greater than 10 mm.

The location of the incision was always chosen to be in the middle of the hematoma by calculating the extent of the hematoma on CT scan.

We used a needle (trocar) of 1.1 mm in diameter and 30 mm in length, and we pierced the dura with the needle very carefully. Once we crossed the dura, we slowly evacuated small amounts of hematoma with a 20ml syringe. We preferred evacuating in several steps in order to avoid causing an abrupt change in intracranial pressure. To avoid injury to the brain, we stopped the evacuation a few mls less than data provided by the machine.

After a half-hour observation period, the patient returned to his room and post-operative observation resumed with an evaluation of the Glasgow Coma score, neurological examination and measurement of constants of blood pressure immediately after surgery and then every hour up to 4 hours and then spacing the review to once a day.

The patients received a control CT scan the day following the surgery. Discharge from hospital was on the average four days post-operation. They were reassessed by the same neurosurgeon a week and a month and half after surgery with a control CT scan. We did not introduce any treatment other than analgesics. Patients were advised to drink water.

## RESULTS

The 28 patients were operated on by a surgeon (the principal author) using a twist-drill treatment method and evacuating the amount of the hematoma measured previously.

The average age was 69.2 years with 19 men and 9 women (Figure 1).

One of the patients had a bilateral subdural hematoma. 27 of the 28 patients (96.4%) became asymptomatic or improved

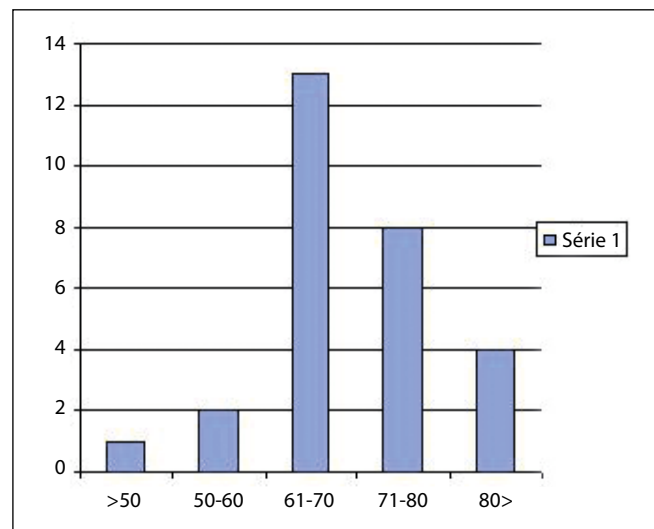


Figure 1: The age of the patients.

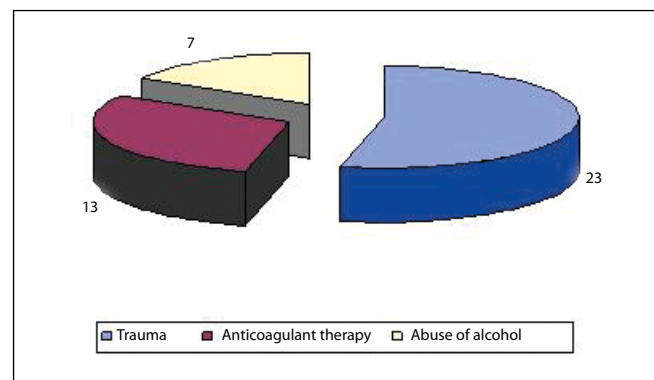


Figure 2: The patients who had alcohol abuse, received anticoagulant therapy and had experienced head trauma.

clinically. Six weeks later, the scan showed the hematoma had completely disappeared in 18 of the cases.

Residual subdural hematoma measuring less than 4mm with no mass effect and no brain asymmetry was seen in 9 cases at the 6 week mark. The only patient who had a recurrence was the patient with bilateral subdural hematoma (recurrence on the left hemisphere that was evacuated before the right side, and pneumocephalus exerting significant mass effect requiring the use of second surgical intervention trephine hole).

Pneumocephalus was present on the first control CT scan taken the day after the intervention in 6 patients. These were no longer seen on the second control CT scan performed 6 weeks after surgery at the time of consultation with the patients.

Among the 28 patients, a thorough examination revealed benign trauma in 23 patients with the said trauma occurring in the final 6 weeks, due to a variety of causes such as near-falls, hits on the head or elsewhere, or other sharp shocks. 13 patients had anticoagulant treatment and 7 patients had a history of alcoholism (Figure 2).

The symptoms observed were headache, gait disturbance, weakness and hemiparesis, memory disturbances, hemiparesis, impairment of memory, confusion, mental impairment, and dizziness (Figure 3).

**DISCUSSION**

Treatment of acute subdural hematoma is still controversial in medical literature and there is no consensus. The main treatment remains surgery. There is a wide spectrum of surgical techniques, namely wide craniectomy, trephine hole and trepan puncture.

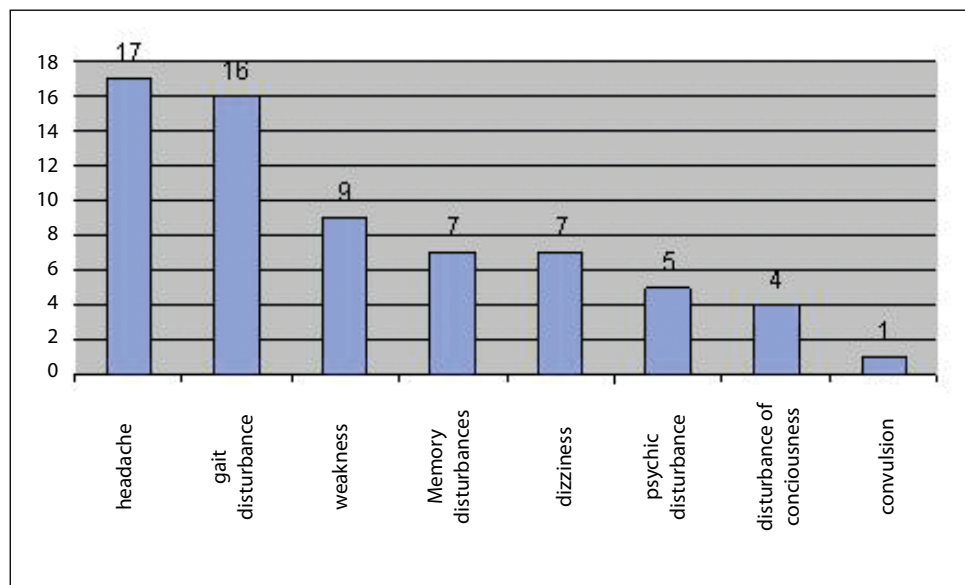
Surgical treatment appears at first sight accessible and easy and accessible but it is not entirely harmless and safe, especially with elderly patients on anticoagulant therapy who have other pathologies. For some of our patients, we found it useful to use this relatively simple and low risk surgical technique (percutaneous puncture of the hematoma), in order to simplify the procedure.

The main diagnostic criterion for the choice of this technique was a chronic subdural hematoma with a hypodense Hounsfield index close to that of water in symptomatic

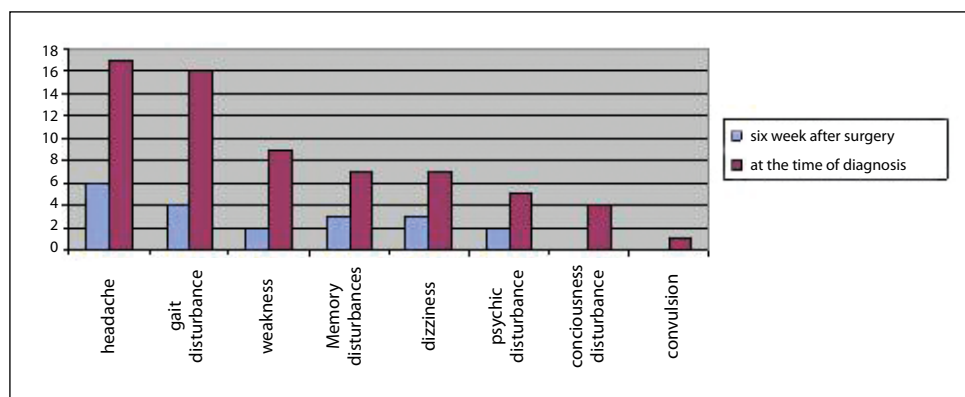
patients. Asymptomatic patients, or those whose CT scan showed no mass effect or with a hemorrhagic component indicating a recent re-bleeding were treated differently. They received either a craniotomy or trephination or trephine puncture with the setting or not of a Jackson-Pratt drain or umbrella drain or a steroid-based drug treatment.

Our results indicate that half of patients had a coagulopathy (13 patients among 28 or 46.4%). We also found 23 patients (82.1%) with a history of trauma in the last two months. 28 patients operated on were all symptomatic. The most common symptoms were headaches (60.7% = 17p) and gait disturbance (57.1% = 16p) that were observed in 50% of patients.

Of the 28, only one patient had a recurrence in the sixth week of intervention. They were not followed up beyond that date. This recurrence was observed in a patient with bilateral subdural hematoma (with the left side evacuated before the right side). The patient had a subdural hematoma on his second CT scan (six weeks after operation although the first control CT scan showed the disappearance of the hematoma). There was also a right pneumocephalus. He underwent bilateral



**Figure 3:** The signs and symptoms of the patients at the preoperative period.



**Figure 4:** The comparison of the symptoms of the patients between the preoperative and postoperative periods.

trepination. On a clinical level, the symptoms (headaches and right hemiparesis) had diminished but reappeared four days before the consultation.

Our surgical method is easily implemented in minimal time. The duration of the procedure never exceeded a half hour (from the time of installation of the patient until the end of the operation). This procedure is performed without using general anesthesia. A single injection of lidocaine was performed on 11 patients and the amount did not exceed 3 ml. Given that the length of the scar never exceeded 10 mm, and the lack of incision, making the risk of bleeding almost zero, we did not see the need for systematic local anaesthesia. We did not need special preparation. We never had any incident involving subcutaneous bleeding.

Our described preoperative calculations allowed a safer and convenient operation without blind manipulations. Both the length of hospital stay and pain associated with the scar greatly decreased. There is no standard dressing and it came down to a simple cleaning with water and Betadine and a bandage for two days. Patients are not constrained to staying in bed until the release of their control CT scans. On average, they got up eight hours after the procedure and they left the hospital 4 days after.

Of the 28 patients, 27 improved or became asymptomatic. 19 of 28 patients (67.9%) became asymptomatic. In 8 other patients (28.5%), we saw an improvement in terms of symptoms. One patient had no improvement (3.6%).

Table IV shows the symptoms in patients six weeks after surgery.

The inner membrane is a cause of recurrent chronic subdural hematoma. The question that arises is poor re-expansion of the brain is a cause of recurrent chronic subdural hematoma, some authors thus advocate wholesale removal of the inner membrane which requires open surgery. In the procedure, the author did not have this notion during his personal experience as he chose several times during open surgery, not to open the inner membrane for reasons of security and fear of re-bleeding.

The technique we have presented is relatively simple and safe. It can be used as an alternative for elderly patients who tend to have elevated vascular risk factors, or are under anticoagulant therapy and are more likely to have complications after a conventional craniectomy intervention even as simple as trephine puncture. The latter involving a larger-incision with a local anesthesia using Xylocaine.

We recommend treatment by percutaneous puncture of chronic subdural haematoma as a first option, thus avoiding open surgery or simple trephine puncture that requires a longer intervention with more risk and more prolonged monitoring.

## REFERENCES

1. Bozturk G, Ayhan S, Akbay A, Palaoglu S: Treatment of subdural hematoma by twist drill craniostomy with irrigation. *Turkish Neurosurgery* 16:19-24, 2006
2. Foelholm R, Waltimo O: Epidemiology of chronic subdural hematoma. *Acta Neurochirurgica (wien)* 32:247-250, 1975
3. Forster MT, Mathé AK, Senft C, Scharrer I, Seifert V, Gerlach R: The influence of preoperative anticoagulation on outcome and quality of life after surgical treatment of chronic subdural hematoma. *J Clin Neurosci* 17(8):975-979, 2010
4. Horn EM, Feiz-Erfan I, Bristol RE, Spetzler RF, Harrington TR: Bedside twist drill craniostomy for chronic subdural hematoma: A comparative study. *Surg Neurol* 65(2):150-153, 2006
5. Hwang SC, Im SB, Kim BT, Shin WH: Safe entry point for twist-drill craniostomy of a chronic subdural hematoma. *J Neurosurg* 110(6):1265-1270, 2009
6. Ibrahim I, Maarrawi J, Jouanneau E, Guenot M, Mertens P, Sindou M: Evacuation of chronic subdural hematomas with the Twist-Drill technique: Results of a randomized prospective study comparing 48-h and 96-h drainage duration. *Neurochirurgie* 56(1):23-27, 2010
7. Lee JY, Ebel H, Ernestus RI, Klug N: Various surgical treatments of chronic subdural hematoma and outcome in 172 patients: Is membranectomy necessary? *Surg Neurol* 61(6):523-527, 2004
8. Kansal R, Nadkarni T, Goel A: Single versus double burr hole drainage of chronic subdural hematomas. A study of 267 cases. *J Clin Neurosci* 17(4):428-429, 2010
9. Kenning TJ, Dalfino JC, German JW, Drazin D, Adamo MA: Analysis of the subdural evacuating port system for the treatment of subacute and chronic subdural hematomas. *J Neurosurg* 113(5):1004-1010, 2010
10. Krupa M: Comparison of two surgical methods as to early results in chronic subdural hematoma. *Ann Acad Med Stetin* 55(1):39-47, 2009
11. Lega BC, Danish SF, Malhotra NR, Sonnad SS, Stein SC: Choosing the best operation for chronic subdural hematoma: A decision analysis. *J Neurosurg* 113(3):615-621, 2010
12. Liu Y, Gong J, Li F, Wang H, Zhu S, Wu C: Traumatic subdural hydroma: Clinical characteristics and classification. *Injury* 40(9):968-972, 2009
13. Miranda LB, Braxton E, Hobbs J, Quigley MR: Chronic subdural hematoma in elderly: Not a benign disease. *J Neurosurg* 24(9):1-5, 2010
13. Mori K, Maeda M: Surgical treatment of chronic subdural hematoma in 500 consecutive cases: Clinical characteristics, surgical outcome and recurrence rate. *Neur Med Chir (Tokyo)* 41:371-381, 2001
14. Mostofi K, Tyburne B, Saint-Prix C, Ishac R: Hématome sous-dural chronique: Traitement par ponction percutanée. À propos de 14 cas. *Neurochirurgie* 54(5) 697, 2008
15. Parlato C, Guarracino A, Moraci A: Spontaneous resolution of chronic subdural hematoma. *Surg Neurol* 53: 312-317, 2000

16. Rychlicki F, Recchioni MA, Burchianti MA, Marcolini P, Messori A, Papo I: Percutaneous twist-drill craniostomy for the treatment of chronic subdural haematoma. *Acta Neurochirurgica* 113(1-2), 38-41, 1991
17. Santos-Ditto RA, Santos-Franco JA, Pinos-Gavilanes MW, Mora-Benítez H, Saavedra T, Martínez-González V: Management of chronic subdural hematoma with twist-drill craniostomy. Report of 213 patients. *Gac Med Mex* 143(3): 203-208, 2007
18. Sindou M, Ibrahim I, Maarrawi J: Chronic sub-dural hematomas: Twist drill craniostomy with a closed system of drainage, for 48 hours only, is a valuable surgical treatment. *Acta Neurochir (Wien)* 152(3):545-546, 2010
19. Soto-Granados M: Treatment of chronic subdural hematoma through a burr hole. *Cir Cir* 78(3):203-207, 2010
20. Sucu HK, Gökmen M, Ergin A, Bezircioğlu H, Gökmen A: Is there a way to avoid surgical complications of twist drill craniostomy for evacuation of a chronic subdural hematoma? *Acta Neurochir (Wien)* 149(6):597-599, 2007
21. Tsai TH, Lieu AS, Kaohsiung SL, Huang TY, Hwang YF: A comparative study of the patients with bilateral or unilateral chronic subdural hematoma: Precipitating factors and postoperative outcomes. *J Trauma* 68(3):571-575, 2010
22. White M, Mathieson CS, Campbell E, Lindsay KW, Murray L: Treatment of chronic subdural haematomas - a retrospective comparison of micraniectomy versus burrhole drainage. *Br J Neurosurg* 24(3):257-260, 2010
23. Wilberger J: Pathophysiology of evolution and recurrence of chronic subdural hematoma. *Neurosurg Clin N* 11: 435-438, 2000