

# Percutaneous Ventriculoatrial Shunting as a Salvage Method in the Pediatric Hydrocephalus Patients with Peritoneal Problems

Kadir OKTAY<sup>1</sup>, Sinan SOZUTOK<sup>2</sup>, Umur Anil PEHLIVAN<sup>3</sup>, Dogu Cihan YILDIRIM<sup>1</sup>, Mevlana AKBABA<sup>1</sup>, Kerem Mazhar OZSOY<sup>1</sup>, Nuri Eralp CETINALP<sup>1</sup>

<sup>1</sup>Cukurova University School of Medicine, Department of Neurosurgery, Adana, Türkiye

<sup>2</sup>Cukurova University School of Medicine, Department of Radiology, Adana, Türkiye

<sup>3</sup>Baskent University School of Medicine, Department of Radiology, Adana, Türkiye

Corresponding author: Kadir OKTAY ✉ drkadiroktay@hotmail.com

## ABSTRACT

**AIM:** To evaluate the efficacy of percutaneous ventriculoatrial shunting as a salvage method for pediatric patients with abdominal complications.

**MATERIAL and METHODS:** Data obtained from 9 patients with ventriculoperitoneal shunt dysfunctions owing to abdominal complications, who underwent ventriculoatrial shunting as salvage treatment at a single institution between January 2019 and September 2021 were retrospectively analyzed. All operations were conducted under the guidance of intraoperative fluoroscopy and ultrasound.

**RESULTS:** The mean age of the enrolled patients was  $8.1 \pm 1.2$  years (2-15 years). Six (67%) patients were male and 3 (33%) were female. The mean number of the patients' ventriculoperitoneal shunt revisions until atrial catheter placement was 7.5 times. The reasons for intraperitoneal catheter failure included peritoneal adhesions in 4 (44.5%) patients, pseudocyst formation in 3 (33.3%), and peritonitis in 2 (22.2%). Seven patients from the study cohort had no problem after ventriculoatrial shunt placement. Only 1 patient had shunt dysfunction related to the ventricular catheter, and ventricular catheter and shunt valve revision was performed 26 months after ventriculoatrial shunt placement. The atrial catheter of the patient was intact. One patient died from the progression of her primary disease (medulloblastoma in the 4<sup>th</sup> ventricle), which was unrelated to the ventriculoatrial shunt.

**CONCLUSION:** Percutaneous ventriculoatrial shunting under the guidance of intraoperative fluoroscopy and ultrasound is a safe, effective, and easy alternative in patients with peritoneal complications and a history of multiple operations.

**KEYWORDS:** Ventriculoatrial shunt, Peritoneal complications, Percutaneous, Ultrasound, Fluoroscopy

## INTRODUCTION

Hydrocephalus is the most common, but challenging disease encountered in neurosurgery, especially in the pediatric population (3,12,22). The prevalence of infant hydrocephalus is estimated to be 0.5–0.8 per 1000 live births (3,12,22). The treatment options for hydrocephalus include endoscopic third ventriculostomy (ETV) and shunt

procedures. In recent years, ETV has been preferred especially in the treatment of obstructive hydrocephalus cases. However, shunt operations are applied in cases where ETV fails or in non-obstructive cases.

Ventriculoperitoneal shunt (VPS) application is the preferred and widely applied method in patients who require a shunt, both due to the ease of insertion and the lower frequency of

severe complications (26). However, abdominal complications of VPS operations should not be underestimated. The abdominal complication rates have been reported to be 25% in the literature (8,20,31). In the present case, the ventriculoatrial shunt (VAS) procedure was applied as the prominent salvage method. In this study, we evaluated pediatric patients with VPS dysfunctions owing to abdominal complications and underwent VA shunting under ultrasound and fluoroscopy guidance as a second-line treatment.

## ■ MATERIAL and METHODS

The present study was performed according to the principles of the World Medical Association's Declaration of Helsinki "Ethical Principles for Medical Research Involving Human Subjects" (amended in October 2013), and Institutional Review Board approval was obtained (14/10/2022-00026). This study included 9 patients with VPS dysfunctions due to abdominal complications, who underwent VA shunting as salvage treatment at a single institution between January 2019 and September 2021. All operations were performed under the guidance of intraoperative ultrasound and fluoroscopy. Patient data including their age, gender, etiology of hydrocephalus, age at the time of insertion of the first VPS, the number of VPS revisions, abdominal complications, outcomes, and complications of VAS, and patients' follow-up examinations were collected.

### Technique of VAS Insertion

In this procedure, the cranial portion is handled as per the standard method. Kocher and Keen points are used as the entry sites in the cranium. A 5-mm incision is created along the anterior edge of the sternocleidomastoid muscle, approximately 2-3 cm below the anterior angle of the mandible. The dermis is dissected to expose the subdermal fat, and the distal catheter is tunneled through the subcutaneous plane between the cranial and cervical incisions. The modified Seldinger method is applied to place the atrial catheter (3). Under intraoperative ultrasound guidance, a 22-gauge needle is advanced into the internal jugular vein (IJV) at approximately a 45-degree angle. Once the venous blood is aspirated, a J-wire is passed through the needle into the vein. The J-wire is advanced under intraoperative fluoroscopic guidance and positioned such that the tip lies in the distal superior vena cava. Electrocardiographic changes may indicate the wire position in the atrium. The needle is removed, and an 8-French dilator and peel-away sheath are advanced over the wire into the IJV. The dilator and J-wire are then removed, and the distal catheter is passed down the peel-away sheath and into the lower right atrium. The sheath is then peeled away and the catheter is flushed with heparinized saline. The optimal position of the catheter tip is the midatrium, which is usually located at the T6-T8 vertebral level. After the confirmation of the atrial catheter's level by fluoroscopy, the ventricular and atrial catheters are connected with a shunt valve.

### Statistical Analysis

SPSS software version 25.0 (IBM Corporation, Armonk, New York, USA) was used to analyze the variables. The

Mann-Whitney U-test was applied with the Monte Carlo results to compare the categorical variables quantitatively. The quantitative variables were presented as the mean  $\pm$  SD (standard deviation) and range (maximum-minimum) and the categorical variables as n (%). The variables were examined at a 95% confidence level, with  $p < 0.05$  considered to indicate statistical significance.

## ■ RESULTS

A total of 9 patients were included in the study. The mean age of the patients was  $8.1 \pm 1.2$  years (2-15 years). Six (67%) patients were male and 3 (33%) were female. The initial causes of hydrocephalus were as follows congenital in 2 (22.2%) patients, myelomeningocele in 2 (22.2%), post-hemorrhagic in 2 (22.2%), posterior fossa tumors in 2 (22.2%), and post meningitis in 1 (11.2%). The mean age of the children at the time of initial VPS placement was 1.7 years (range: 2 days to 6 years) (Table I).

The mean number of the patients' VPS revisions until VAS placement was 7.5 times (range: 5-11 times). The reasons for intraperitoneal catheter failure were as follows; peritoneal adhesions in 4 (44.5%) patients, pseudocyst formation in 3 (33.3%), and peritonitis in 2 (22.2%) (Table I). The mean follow-up of the patients after VAS placement was 32 months (14-46 months). According to the statistical analysis of the variables, the number of VPS revisions increases with decreasing age at the time of the insertion of the first VPS ( $p < 0.05$ ). Seven patients in the study cohort reported no problems after VAS placement. Only 1 patient showed shunt dysfunction related to the ventricular catheter, and ventricular catheter and shunt valve revision was performed 26 months after VAS placement. The atrial catheter of the patient was found intact. One patient died because of the progression of her primary disease (medulloblastoma in the 4<sup>th</sup> ventricle), which was unrelated to her VAS (Table I).

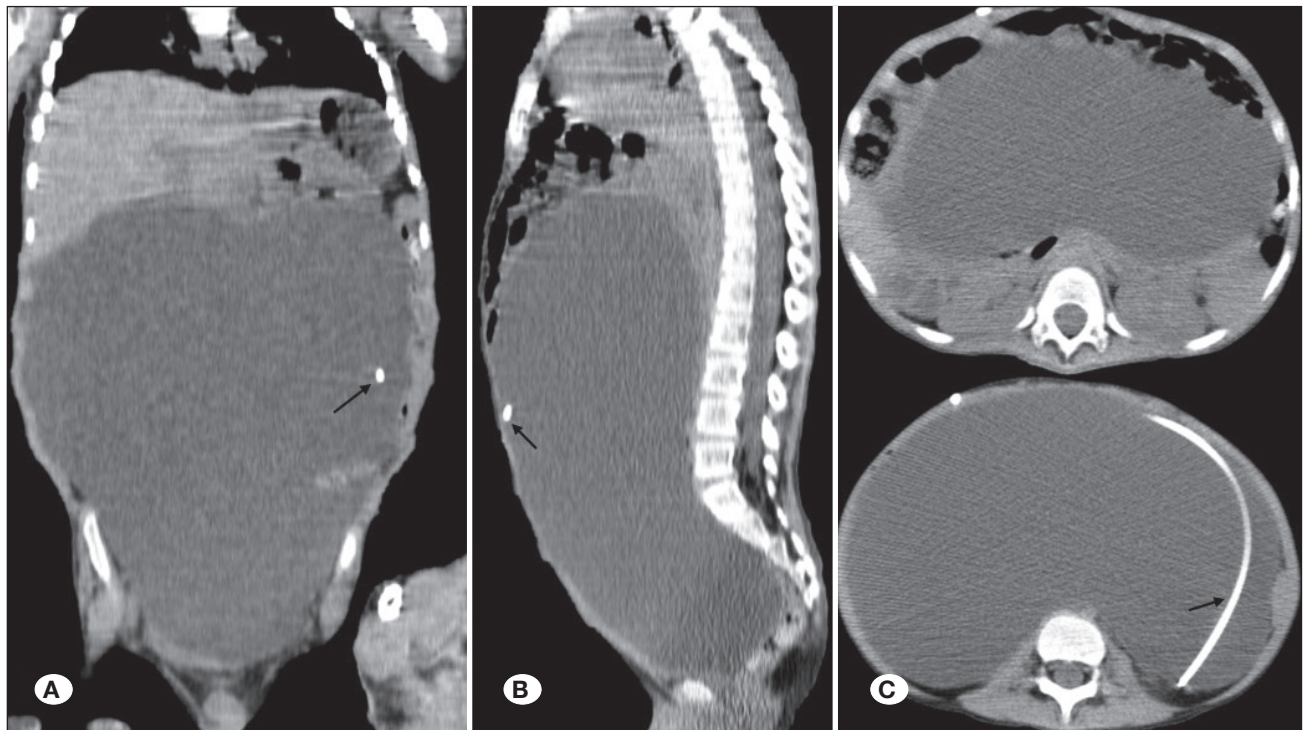
## ■ DISCUSSION

The earliest scientific description of hydrocephalus has been ascribed to Hippocrates (466-377 BC) and Galen of Pergamon (130-200 AD) (1,3). Until modern treatment methods were developed for the treatment of hydrocephalus, several drainage devices for ventricular and lumbar puncture, including catgut strands, horsehair, silk, gold tubes, and silver cannula, were tried (1). In the 1950s, valve-regulated silicone shunts began to be used. However, after that, the discussion started regarding where the distal catheter tips end. Peritoneum, right cardiac atrium, cisternal space (Torkildsen shunt), pleural space, gall bladder, and ureter bladder are some of the options for the distal catheter tips ending (11,21,29,33). The initial valve-regulated silicone shunts were designed as VAS. In 1951, Nulsen and Spitz reported the first successful VAS using a valve system (19). In 1956, John D. Holter—a machine technician from Philadelphia—developed Spitz-Holter valves, and these VAS systems were widely applied in the neurosurgery departments until the early 1970s (4,24,32). Next, the VAS systems were replaced by VPS owing to the difficulty in application and the severe resulting complications (1,3,26).

**Table I:** Data of the Patients

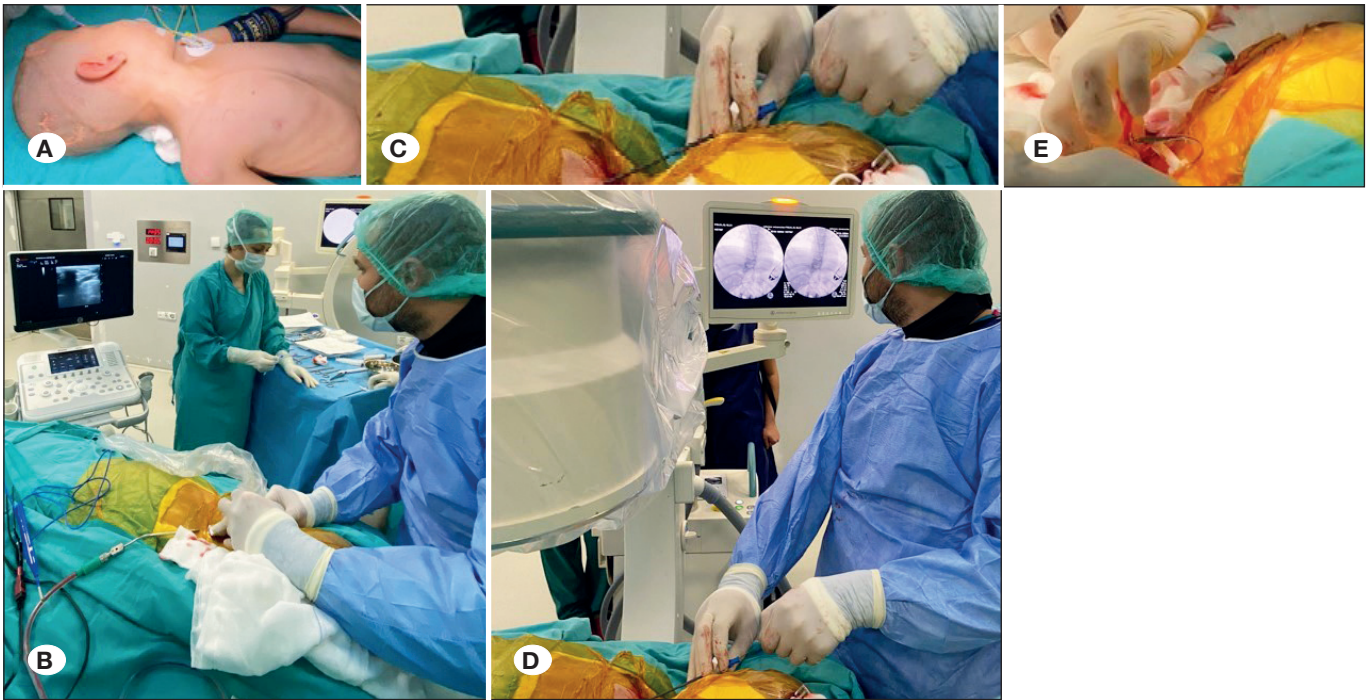
Patient	Age	Gender	Aetiology of hydrocephalus	Age at insertion of the first VPS	The number of VPS revisions	Abdominal complications	Outcome (VAS)	Follow-up (VAS - months)
1	6	M	Congenital	2 months	11	Pseudocyst formation	NR	46
2	2	F	Post-hemorrhagic	1 month	5	Peritoneal adhesions	NR	44
3	15	M	Myelomeningocele	3 days	6	Pseudocyst formation	Shunt revision*	40
4	8	M	Congenital	2 months	9	Pseudocyst formation	NR	36
5	6	M	Post-hemorrhagic	1 month	8	Peritoneal adhesions	NR	34
6	9	M	Pilocytic astrocytoma (cerebellum)	6	6	Peritoneal adhesions	NR	31
7	8	F	Postmeningitis hydrocephalus	5	5	Peritonitis	NR	26
8	7	M	Myelomeningocele	2 days	8	Peritoneal adhesions	NR	18
9	12	F	Medulloblastoma (4 <sup>th</sup> ventricle)	4	10	Peritonitis	Exitus**	14

**M:** Male, **F:** Female, **VPS:** Ventriculoperitoneal shunt, **VAS:** Ventriculoatrial shunt, **NR:** No revision. \* Ventricular catheter and valve revision was performed. Atrial catheter was intact. \*\* She died because of the progression of the primary disease.

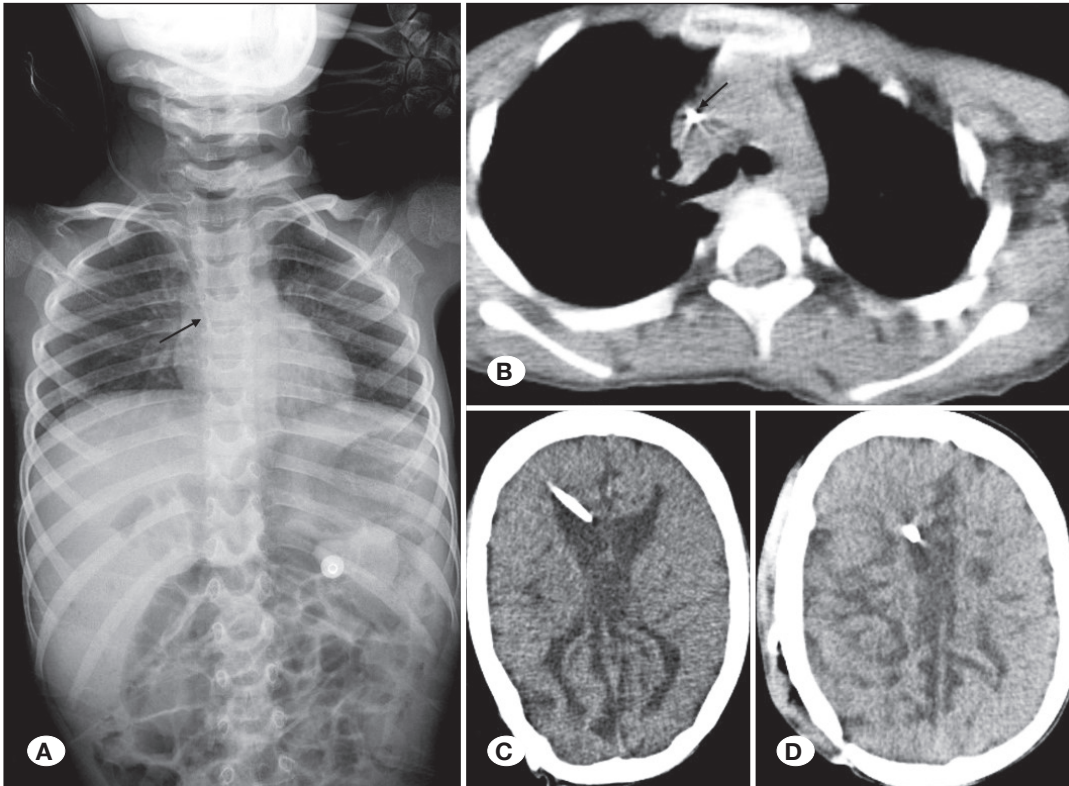


**Figure 1:** Preoperative **A)** coronal, **B)** sagittal, and **C)** axial abdominal computed tomography scans revealing pseudocyst formation and ventriculoperitoneal shunt abdominal catheter in the cyst walls (black arrow).





**Figure 2:** Peroperative images revealing; **A)** position of the patient, **B)** placement of the needle into the internal jugular vein (IJV) under intraoperative ultrasound guidance, **C, D)** advancement of J-wire through the needle into the IJV under intraoperative fluoroscopic guidance, **E)** removal of the peel-away sheath after placement of the distal shunt catheter through the sheath.



**Figure 3:** Postoperative **A)** anteroposterior radiograph, and **B)** axial computed tomography scan showing the atrial catheter tip locating in the midatrium (black arrow). **C)** Preoperative axial brain computed tomography scan revealing ventriculoperitoneal shunt dysfunction. **D)** Postoperative axial brain computed tomography scan revealing resolution of hydrocephalus after ventriculoatrial shunt placement.

VPS operations are susceptible to several complications. The abdominal complication rates of VPS in the literature are 25% (8,20,31,35). The peritoneal complications of VPS include the obstruction of the peritoneal catheter with debris, pseudocyst formation, peritoneal adhesions, the need to lengthen the catheter with growth, inguinal hernia, hydrocele, CSF ascites, peritonitis, intestinal strangulation, and tip migration into the scrotum or intestinal organs (6,8,9,13,20,25,31,35). The most important risk factors for the development of peritoneal complications are previous infection and recurrent shunt revisions (13,25). Pseudocyst formation and abdominal absorption problems occur in patients with a history of multiple operations (13,25). In these cases, another space should be used for the distal catheters and VAS is the preferred method. Consistent with the literature, we believe that the most appropriate indication for VAS is a history of multiple surgeries due to peritoneal complications (3,5,7,26).

A comparison of VAS with VPS revealed no evident superiority over each other. There is no significant difference in the revision rates in the literature (15,26). Susceptibility to infection and distal-end obstructions are more common in VPS (26). However, VPS is more favorable because the complications associated with VPS are potentially less morbid and more easily manageable (15,26). In addition, another disadvantage of VAS is the need for elective lengthening of atrial catheters in a pediatric population. Elective lengthening procedures are periodically required when the atrial catheter becomes short as a result of the growth of the patient (26,32). Rymarczuk et al. reported the rate of elective lengthening procedures as 23% (26).

There are 2 techniques for the insertion of atrial catheters: open and percutaneous. After the VAS application was started with the first silicone Spitz–Holter slit valve in 1956, the VAS application with an open technique was defined in the literature by Pudenz (4,24). In this technique, the junction of the common facial vein and the IJV was detected and the distal catheter was placed directly into the IJV (24). In the subsequent years, the percutaneous approach was developed by using the Seldinger method (2,27). When compared to the open technique, the percutaneous approach is less invasive and involves less bleeding. The incision is much smaller and requires much less dissection (7). All these advantages reduce the risk of infection, which is a major complication of shunt surgeries (2,3,7). Some percutaneous techniques are performed under the guidance of ultrasound and fluoroscopy (5,7,17), ultrasound alone (18,28), or transesophageal echocardiography (10,16). We performed VAS operations under the guidance of intraoperative fluoroscopy and ultrasound in this study.

Some complications may occur with ventricular cannulation in any shunt system, including intraventricular or intraparenchymal hemorrhage, obstruction, break or disconnection at any point, hardware erosion through skin and scalp, seizures, and infection (3,26). In addition, atrial catheter related-complications can occur in VAS surgery, such as atrial catheter migration, thromboembolism, infection, and tricuspid valve dysfunctions (3,23). Thromboembolic complications include

atrial thrombus formation, arrhythmias, thrombosis of the superior vena cava, pulmonary emboli, pulmonary hypertension, and ultimately cor pulmonale (3,23,26,30,32,34). These are the most severe complications and have been reported to occur clinically in 0.4% of all patients with a VAS (3,23). Some authors suggest the use of aspirin to prevent thromboembolic complications (30). Another rare, but fatal complication of VAS is shunt nephritis (3,14,23,32), which is a delayed complication of VAS resulting from prolonged infection with a low-virulence organism (3,14). This complication should be treated with antibiotics and shunt replacement (3).

There are certain limitations of this study. The retrospective nature of the study and the small sample size (9 patients) are the main limitations. The lack of 5 year follow-up of all patients is also another limitation of the study.

## ■ CONCLUSION

Although VPS remains the preferred method because of the ease of insertion and the lower frequency of severe complications, VAS is an appropriate alternative in the presence of peritoneal complications, especially in patients with a history of multiple operations. Percutaneous VAS under the guidance of intraoperative fluoroscopy and ultrasound technique provides a safe, effective, and easy procedure for these patients.

## ■ ACKNOWLEDGEMENTS

Preparation for publication of this article is partly supported by the Turkish Neurosurgical Society.

### AUTHORSHIP CONTRIBUTION

Study conception and design: KO, SS

Data collection: KO, SS, UAP, DCY, MA

Analysis and interpretation of results: KO, SS, UAP, KMO

Draft manuscript preparation: KO, SS, NEC

Critical revision of the article: KO, KMO, NEC

Other (study supervision, fundings, materials, etc.): KO, SS

All authors (KO, SS, UAP, DCY, MA, KMO, NEC) reviewed the results and approved the final version of the manuscript.

## ■ REFERENCES

1. Aschoff A, Kremer P, Hashemi B, Kunze S: The scientific history of hydrocephalus and its treatment. *Neurosurg Rev* 22:67-93, 1999
2. Ashker K, Fox JL: Percutaneous technique for insertion of an atrial catheter for CSF shunting. Technical note. *J Neurosurg* 55:488-490, 1981
3. Badhiwala JH, Kulkarni AV: Ventricular shunting procedures. In: Winn HR (ed), Youmans & Winn Neurological Surgery, 8<sup>th</sup> edn. Philadelphia: Elsevier, 2022:1714-1728
4. Boockvar JA, Loudon W, Sutton LN: Development of the Spitz-Holter valve in Philadelphia. *J Neurosurg* 95:145-147, 2001

5. Clark DJ, Chakraborty A, Roebuck DJ, Thompson DN: Ultrasound guided placement of the distal catheter in paediatric ventriculoatrial shunts-an appraisal of efficacy and complications. *Childs Nerv Syst* 32:1219-1225, 2016
6. de Aquino HB, Carelli EF, Borges Neto AG, Pereira CU: Nonfunctional abdominal complications of the distal catheter on the treatment of hydrocephalus: An inflammatory hypothesis? Experience with six cases. *Childs Nerv Syst* 22:1225-1230, 2006
7. Ellegaard L, Mogensen S, Juhler M: Ultrasound-guided percutaneous placement of ventriculoatrial shunts. *Childs Nerv Syst* 23:857-862, 2007
8. Ghritlaharey RK, Budhwani KS, Shrivastava DK, Gupta G, Kushwaha AS, Chanchlani R, Nanda M: Trans-anal protrusion of ventriculo-peritoneal shunt catheter with silent bowel perforation: Report of ten cases in children. *Pediatr Surg Int* 23:575-580, 2007
9. Hauser T, Auer C, Ludwiczek J, Senker W, Rauch PR, Kargl S, Gruber A: Treatment options for scrotal migration of ventriculoperitoneal shunts: Case illustration and systematic review of 48 cases. *Oper Neurosurg (Hagerstown)* 21:87-93, 2021
10. Isaacs AM, Krahn D, Walker AM, Hurdle H, Hamilton MG: Transesophageal echocardiography-guided ventriculoatrial shunt insertion. *Oper Neurosurg (Hagerstown)* 19:25-31, 2020
11. Jones RF, Currie BG, Kwok BC: Ventriculopleural shunts for hydrocephalus: A useful alternative. *Neurosurgery* 23:753-755, 1988
12. Kahle KT, Kulkarni AV, Limbrick DD Jr, Warf BC: Hydrocephalus in children. *Lancet* 387:788-799, 2016
13. Kariyattil R, Steinbok P, Singhal A, Cochrane DD: Ascites and abdominal pseudocysts following ventriculoperitoneal shunt surgery: variations of the same theme. *J Neurosurg* 106:350-353, 2007
14. Kubota M, Sakata Y, Saeki N, Yamaura A, Ogawa M: A case of shunt nephritis diagnosed 17 years after ventriculoatrial shunt implantation. *Clin Neurol Neurosurg* 103:245-246, 2001
15. Lam CH, Villemure JG: Comparison between ventriculoatrial and ventriculoperitoneal shunting in the adult population. *Br J Neurosurg* 11:43-48, 1997
16. Machinis TG, Fountas KN, Hudson J, Robinson JS, Troup EC: Accurate placement of the distal end of a ventriculoatrial shunt with the aid of real-time transesophageal echocardiography. Technical note. *J Neurosurg* 105:153-156, 2006
17. McCracken JA, Bahl A, McMullan J: Percutaneous ultrasound-guided insertion of ventriculo-atrial shunts. *Br J Neurosurg* 30:411-413, 2016
18. Metellus P, Hsu W, Kharkar S, Kapoor S, Scott W, Rigamonti D: Accuracy of percutaneous placement of a ventriculoatrial shunt under ultrasonography guidance: A retrospective study at a single institution. *J Neurosurg* 110:867-870, 2009
19. Nulsen FE, Spitz EB: Treatment of hydrocephalus by direct shunt from ventricle to jugular vein. *Surg Forum* 399-403, 1951
20. Oktay K, Erkoç YS, Ethemoglu KB, Olguner SK, Sarac ME: Spontaneous extrusion of ventriculoperitoneal shunt catheter through the right lumbar region: A case report and review of the literature. *Pediatr Neurosurg* 50:336-338, 2015
21. Pancucci G, Plaza-Ramirez E, Driller C, Miranda-Lloret P, Botella-Asunción C: Laparoscopy-assisted placement of a ventriculobiliary shunt: A technical note. *Childs Nerv Syst* 35:1397-1400, 2019
22. Persson EK, Anderson S, Wiklund LM, Uvebrant P: Hydrocephalus in children born in 1999-2002: Epidemiology, outcome and ophthalmological findings. *Childs Nerv Syst* 23:1111-1118, 2007
23. Pradini-Santos L, Craven CL, Watkins LD, Toma AK: Ventriculoatrial shunt catheter tip migration causing tricuspid regurgitation: Case report and review of the literature. *World Neurosurg* 136:83-89, 2020
24. Pudenz RH: The ventriculo-atrial shunt. *J Neurosurg* 25:602-608, 1966
25. Rainov N, Schobess A, Heidecke V, Burkert W: Abdominal CSF pseudocysts in patients with ventriculo-peritoneal shunts. Report of fourteen cases and review of the literature. *Acta Neurochir (Wien)* 127:73-78, 1994
26. Rymarczuk GN, Keating RF, Coughlin DJ, Felbaum D, Myseros JS, Oluigbo C, Yadav B, Sharma K, Magge SN: A comparison of ventriculoperitoneal and ventriculoatrial shunts in a population of 544 consecutive pediatric patients. *Neurosurgery* 87:80-85, 2020
27. Seldinger SI: Catheter replacement of the needle in percutaneous arteriography; a new technique. *Acta Radiol* 39:368-376, 1953
28. Sheth SA, McGirt M, Woodworth G, Wang P, Rigamonti D: Ultrasound guidance for distal insertion of ventriculo-atrial shunt catheters: Technical note. *Neurol Res* 31:280-282, 2009
29. Torkildsen A: A follow-up study 14 to 20 years after ventriculocisternostomy. *Acta Psychiatr Scand* 35:113-121, 1960
30. Udayakumaran S, Kumar S: Should not we be using aspirin in patients with a ventriculoatrial shunt? Borrowing a leaf from other specialties: A case for surrogate evidence. *Childs Nerv Syst* 37:1137-1142, 2021
31. Verma A, Mohan S, Gupta A: Ventriculo-peritoneal shunts can cause liver injury, juxta and intrahepatic pseudocysts: Imaging findings and review of literature. *Clin Neurol Neurosurg* 114(4):389-391, 2012
32. Vernet O, Campiche R, de Tribolet N: Long-term results after ventriculo-atrial shunting in children. *Childs Nerv Syst* 11:176-179, 1995
33. West CG: Ventriculovesical shunt. Technical note. *J Neurosurg* 53:858-860, 1980
34. Wu D, Guan Z, Xiao L, Li D: Thrombosis associated with ventriculoatrial shunts. *Neurosurg Rev* 45:1111-1122, 2022
35. Yilmaz MB, Egemen E, Tonge M, Kaymaz M: Transoral protrusion of a peritoneal catheter due to gastric perforation 10 years after a ventriculoperitoneal shunting: Case report and review of the literature. *Turk Neurosurg* 23:285-288, 2013