



Surgical Management of Symptomatic T8 Vertebral Hemangioma: Case Report and Review of the Literature

Semptomatik T8 Vertebral Hemanjiomun Cerrahi Tedavisi: Olgu Sunumu ve Literatür Derlemesi

Bulent TUCER¹, Mehmet Ali EKICI², Ahmet MENKU¹, Rahmi Kemal KOC¹, Bulent GUCLU²

¹Erciyes University, Faculty of Medicine, Department of Neurosurgery, Kayseri, Turkey

²Sevket Yılmaz Training and Research Hospital, Department of Neurosurgery, Bursa, Turkey

Corresponding Author: Mehmet Ali EKICI / E-mail: mehmetali.ekici@gmail.com

ABSTRACT

Vertebral hemangiomas are benign vascular lesions of the vertebral column; only 0.9-1.2% of all vertebral hemangiomas cause spinal cord compression. We report a 34-year-old female who was admitted to the neurosurgery clinic with a history of back pain, poor quality of life and easy fatigability for 1.5 years. Her medical history revealed a fall from a height of 2 meters 1.5 years ago. Neurology examination revealed bilateral hypoesthesia below the T8 level and hyperactive deep tendon reflexes in her left leg. Computed tomography scan of the thoracic spine showed T8 vertebral hemangioma, and magnetic resonance imaging showed a T8 hemangioma compressing the spinal cord. Surgical intervention was planned and T8 total laminectomy was performed. The tumor extending into the anterior spinal cord was resected, and T8 vertebroplasty with short segment posterior stabilization and fusion was performed. We aimed to present a new treatment approach for symptomatic vertebral hemangiomas and reviewed the relevant literature.

KEYWORDS: Vertebral hemangioma, Posterior stabilization, Vertebroplasty, Total laminectomy

ÖZ

Vertebral hemanjiomlar vertebral kolonun iyi huylu vasküler tümörleridir; vertebral hemanjiomların yalnızca %0,9-1,2'si spinal kord kompresyonuna neden olur. Beyin cerrahisi kliniğine 1,5 yıllık bel ağrısı, düşük hayat kalitesi, kolay yorulma şikayetiyle başvuran 34 yaşında bir bayan hasta takdim ediyoruz. Hastanın medikal hikayesinden 1,5 sene önce 2 metre yükseklikten düştüğü öğrenildi. Hastanın nörolojik muayenesinde bilateral T8 seviyesi altında hipostezi ve sol bacakta derin tendon reflekslerinde artış saptandı. Torakal omurganın bilgisayarlı tomografi görüntülemesi T8 vertebral hemanjiom gösterdi, manyetik rözanans görüntülemesi T8 hemanjiomunun spinal kordu komprese ettiğini gösterdi. Hastaya cerrahi müdahale planlandı ve T8 total laminektomi yapıldı. Anterior spinal korda uzanan tümör çıkarıldı, T8 vertebroplasti, kısa segment posterior stabilizasyon ve füzyon yapıldı. Biz semptomatik hemanjiomların yeni bir tedavi yaklaşımını sunmak istedik ve ilgili literatürü derledik.

ANAHTAR SÖZCÜKLER: Vertebral hemanjiom, Posterior stabilizasyon, Vertebroplasti, Total laminektomi

INTRODUCTION

Hemangiomas are one of the most common vertebral neoplasms. They are usually asymptomatic and discovered incidentally on radiographs acquired for other reasons (3, 15). The overall incidence in the general population is estimated to be between 9% and 12% (9, 10). They may sometimes cause pain that can be related to an osseous expansion or a pathological fracture, and neurological deficits that are caused by compression of the neural elements. Treatment is conservative for patients whose primary complaint is mild to moderate pain, whereas neurological deficits and intractable pain are indications for surgical and nonsurgical intervention. These include decompression, short segment posterior stabilization and fusion, corpectomy with strut grafting, vertebroplasty, intralesional ethanol injection, intraarterial

embolization and radiotherapy (1,2, 4, 5, 12, 14, 16, 18, 19). We report a 34-year-old female who had T8 hemangioma and back pain for the last 1.5 years and was treated by T8 total laminectomy, removal of tumor extending into the anterior spinal cord, T8 vertebroplasty and short segment posterior stabilization and fusion. We aimed to present a new treatment approach for symptomatic vertebral hemangiomas and reviewed the relevant literature.

CASE REPORT

A 34-year-old female was admitted to the neurosurgery clinic with a history of back pain, poor quality of life and easy fatigability for the last 1.5 years. Her medical history revealed a fall from a height of 2 meters 1.5 years ago. Her symptoms had developed and worsened over time. The physical

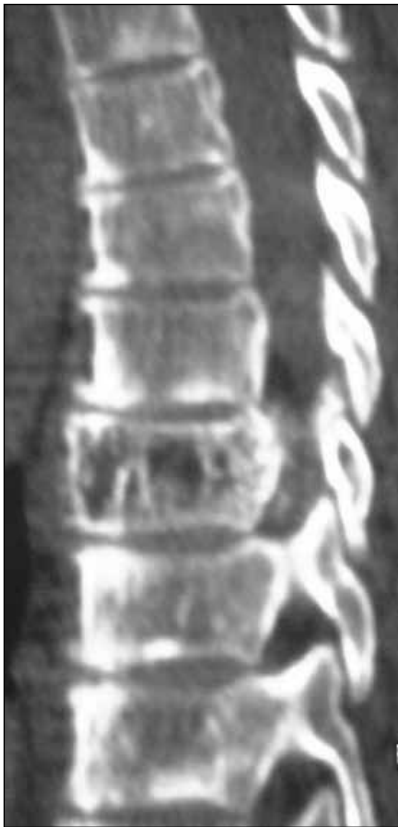

Figure 1: Computed tomography of thoracic spine showing T8 vertebral hemangioma.

examination was unremarkable. The neurology examination revealed bilateral hypoesthesia below the T8 level, and hyperactive deep tendon reflexes in her left leg. Computed tomography of the thoracic spine showed a T8 vertebral hemangioma (Figure 1). T1-weighted magnetic resonance imaging revealed a T8 hemangioma compressing the spinal cord (Figure 2A,B). Spinal angiography was performed to evaluate the blood supply of the hemangioma and showed that it was supplied by the anterior spinal artery (Figure 3). Surgical intervention was planned and T8 total laminectomy was performed. The tumor extending into the anterior spinal cord was resected, and T8 vertebroplasty with short segment posterior stabilization and fusion was performed (Figure 4A,B). The patient was discharged on the 5th postoperative day and had no neurological deficit.

DISCUSSION

Vertebral hemangiomas are benign vascular lesions of the bone and can be cavernous, capillary, or mixed. Only a small percentage of vertebral hemangiomas progress to cord compression. No standard therapy exists for symptomatic vertebral hemangiomas. However, immediate surgical intervention before the symptoms become irreversible is necessary in cases with acute compressive myelopathy. Several surgical options are currently available for the management of symptomatic vertebral hemangiomas. They include surgical decompression, short segment posterior stabilization and

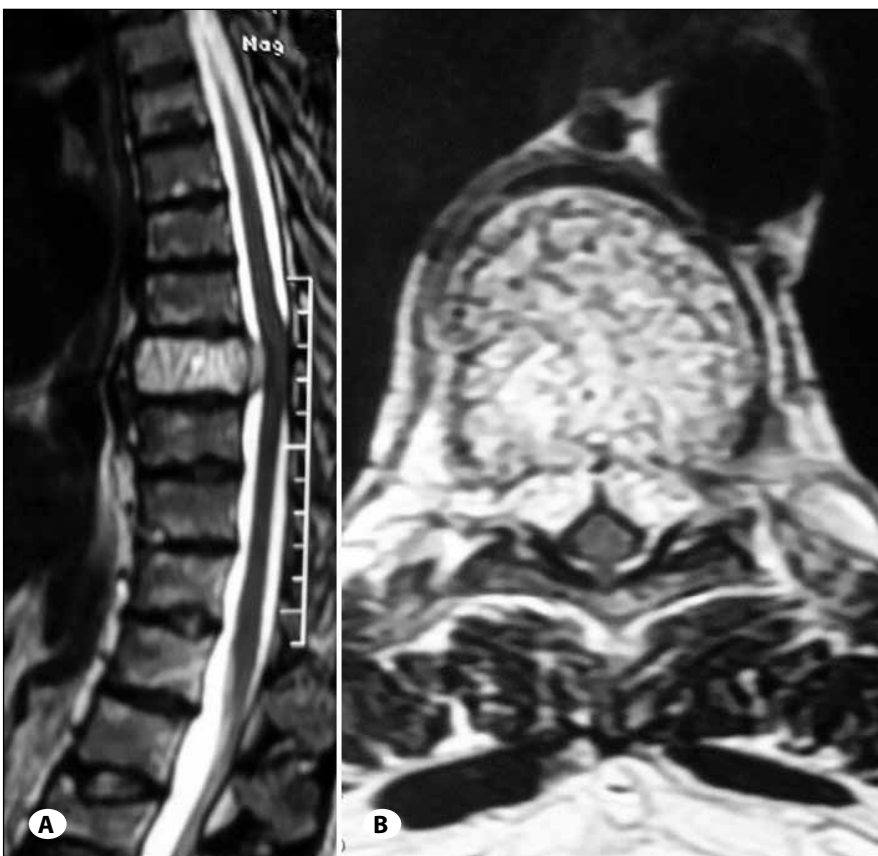


Figure 2: A) Magnetic resonance imaging of thoracic spine (sagittal view) with contrast showing T8 hemangioma compressing the anterior spinal cord. B) Magnetic resonance imaging of thoracic spine (axial view) showing T8 hemangioma encasing the spinal cord.

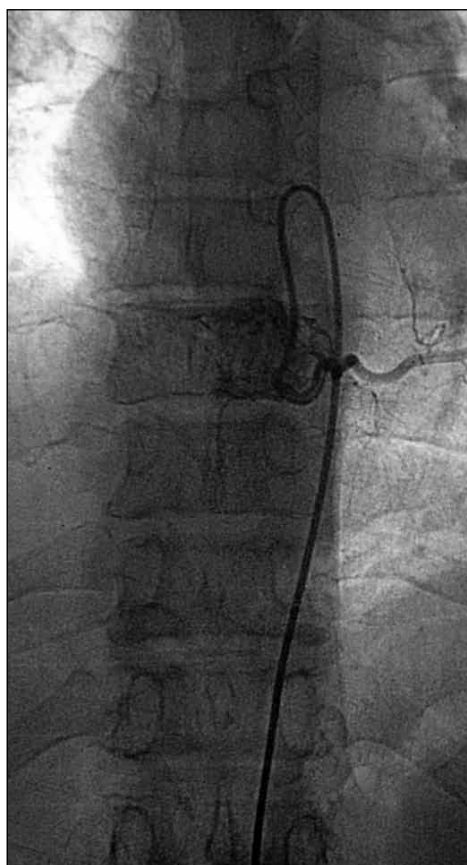


Figure 3: Spinal DSA showing remarkable vascular stain of T8 hemangioma.

fusion, and corpectomy with strut grafting. Surgery has some risks and dangers even when performed by highly skilled surgeons. Some mortality has been reported in the literature due to exsanguination during attempts to remove large soft tissue tumors in the ventral part of the vertebral body. Invasive but non-surgical modalities are also used as the tumor is highly vascular and the surgical approach is very risky. Invasive options of treatment for vertebral hemangiomas are injection of vertebroplasty cement, injection of absolute alcohol or methyl methacrylate, intraarterial embolization and radiotherapy. Some combined approaches have also been used to treat vertebral hemangiomas (1,2, 4, 5, 12, 14, 16, 18, 19).

Cotten et al. (6) performed laminectomy and excision of epidural hemangioma in combination with preoperative embolization and injection of methyl methacrylate, without using any instrumentation. Heiss et al. (11) reported a vertebral hemangioma treated by percutaneous CT-guided injection of absolute alcohol. Following vertebral injection of absolute alcohol, intralesional thrombosis and destruction of the endothelium occurs. Injection of ethanol devascularizes the soft-tissue component of the hemangioma so the lesion shrinks and sclerosis occurs, decompressing the cord and nerve roots. Singh et al. combined intraoperative absolute alcohol with surgical decompression of the cord and short segment instrumented fixation for single-level vertebral hemangiomas with epidural soft tissue compression of the

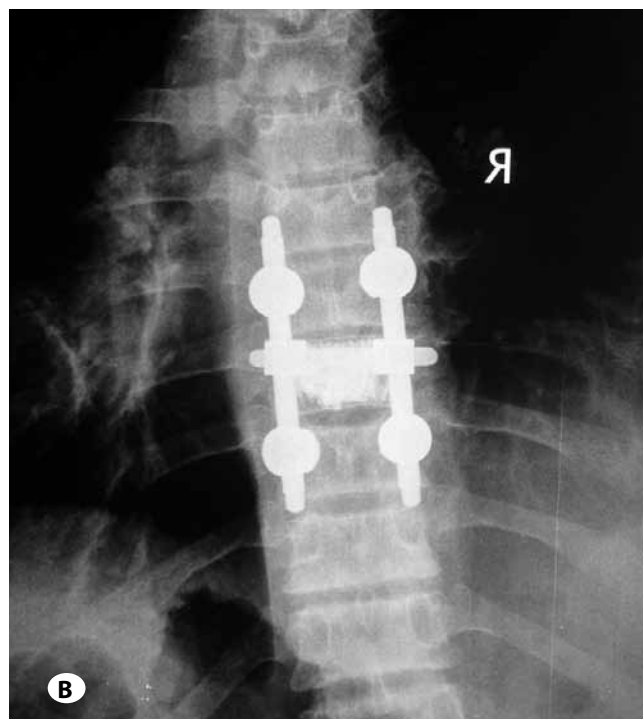
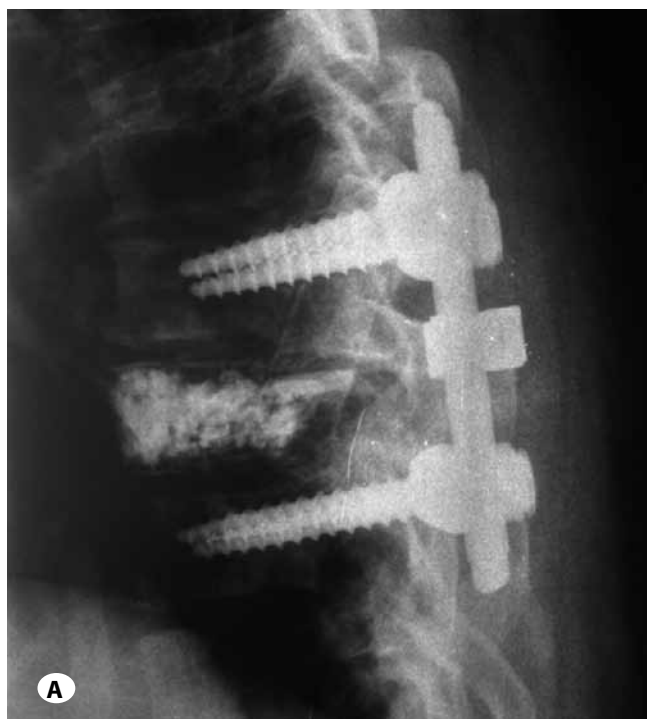

Figure 4: A) Postoperative x-ray spine of the thoracic region showing vertebroplasty and short segment posterior stabilization and fusion. B) Postoperative x-ray spine of the thoracic region showing vertebroplasty and short segment posterior stabilization and fusion.

cord. This technique provided the advantage of reducing the complications of ethanol by providing operative visualization, allowed immediate recovery due to surgical decompression and prevented pathological fractures (19). Niemeyer et al. (17) reported Brown-Sequard syndrome after intralesional injection of absolute alcohol into a vertebral hemangioma and concluded that intralesional alcohol injection could not be considered a safe technique for management of vertebral hemangiomas with spinal cord compression. Bradycardia and/or hypotension have also been reported during ablation of symptomatic vertebral hemangiomas with absolute alcohol (20).

Vertebral hemangiomas are generally well vascularized, and transarterial embolization may be required to facilitate surgery and decrease blood loss (9). Acosta et al. (1) performed transarterial embolization followed by laminectomy and concluded that it is a safe and effective procedure for the treatment of cord compression by vertebral hemangioma causing stenosis, without instability or deformity. They also performed transarterial embolization followed by vertebrectomy and reconstruction to treat cord compression from extraosseous tumor extension.

Percutaneous vertebroplasty is also used to treat painful hemangiomas of the thoracic and lumbar spine without neurological compromise. However, cement leakage may occur after vertebroplasty and more complicated surgery may be needed to remove any cement that has leaked (7). When there is no pathological fracture or neurological deficit and the hemangioma is located in the vertebral body away from the spinal canal, the risk of cement leakage is minimal. Due to the mechanical-thermal effects of the cement, there is a minimal risk of bleeding and the destruction of hemangioma occurs even if the tumor is not completely filled with cement. Patients tolerate the procedure well and the pain symptoms disappear quickly after surgery (4). Vertebroplasty can also be performed preoperatively to make decompression surgery easier because it reduces the risk of hemorrhage (13).

Faria et al. (8) reported complete or almost complete disappearance of the symptoms in seventy-seven percent of symptomatic vertebral hemangiomas after radiotherapy. Yang et al. reported that irradiation could be chosen as the primary treatment of vertebral hemangioma without preceding surgical decompression for patients with a severe compression syndrome of the spinal cord (21). Miszczyk et al. (16) reported analgesic effect of radiotherapy for painful vertebral hemangiomas and related this effect to the applied total dose and fraction dose.

In the present case we performed T8 total laminectomy, followed by resection of the tumor extending into the anterior spinal canal and compressing the spinal cord. Vertebroplasty was performed by entering the pedicles of T8, followed by short segment posterior stabilization and fusion. The patient was discharged on the 5th postoperative day and had no neurological deficit. We did not perform transarterial embolization or injection of absolute alcohol as we believe

that vertebroplasty is as effective as these procedures. We also aimed to strengthen the vertebrae, and performed short segment posterior stabilization and fusion. We think that the approach presented here can be used to treat single-level vertebral hemangiomas.

CONCLUSION

We performed a combination of total laminectomy, removal of tumor extending into the anterior spinal canal, T8 vertebroplasty and short segment posterior stabilization and fusion in a patient with symptomatic T8 hemangioma. The result has proven to be satisfactory during long-term follow-up. We think that the approach presented here can be used to treat single-level vertebral hemangiomas.

REFERENCES

1. Acosta FL Jr, Dowd CF, Chin C, Tihan T, Ames CP, Weinstein PR: Current treatment strategies and outcomes in the management of symptomatic vertebral hemangiomas. *Neurosurgery* 58: 287-295, 2006
2. Acosta FL Jr, Sanai N, Chi JH, Dowd CF, Chin C, Tihan T, et al: Comprehensive management of symptomatic and aggressive vertebral hemangiomas. *Neurosurg Clin N Am* 19:17-29, 2008
3. Blankstein A, Spiegelmann R, Shacked I, Schinder E, Chechick A: Hemangioma of the thoracic spine involving multiple adjacent levels: Case report. *Paraplegia* 26:186-191, 1988
4. Boschi V, Pogorelić Z, Gulan G, Perko Z, Grandić L, Radonić V: Management of cement vertebroplasty in the treatment of vertebral hemangioma. *Scand J Surg* 100:120-124, 2011
5. Bremnes RM, Hauge HN, Sagsveen R: Radiotherapy in the treatment of symptomatic vertebral hemangiomas: Technical case report. *Neurosurgery* 39:1054-1058, 1996
6. Cotten A, Deramond H, Cortet B, Lejeune JP, Leclerc X, Chastanet P, et al: Preoperative percutaneous injection of methyl methacrylate and N-butyl cyanoacrylate in vertebral hemangiomas. *AJNR Am J Neuroradiol* 17:137-142, 1996
7. Evangelopoulos DS, Kontovazenitis P, Kokkinis K, Glynos M, Korres DS, Sapkas G: Cement leakage in a symptomatic vertebral hemangioma: A case report and review of the literature. *Cases J* 2:7148, 2009
8. Faria SL, Schlupp WR, Chiminazzo H Jr: Radiotherapy in the treatment of vertebral hemangiomas. *Int J Radiat Oncol Biol Phys* 11:387-390, 1985
9. Fox MW, Onofrio BM: The natural history and management of symptomatic and asymptomatic vertebral hemangiomas. *J Neurosurg* 78:36-45, 1993
10. Healy M, Herz DA, Pearl L: Spinal hemangiomas. *Neurosurgery* 13:689-691, 1983
11. Heiss JD, Doppman JL, Oldfield EH: Brief report: Relief of spinal cord compression from vertebral hemangioma by intralesional injection of absolute ethanol. *N Engl J Med* 331:508-511, 1994
12. Hemmy DC, McGee DM, Armbrust FH, Larson SJ: Resection of a vertebral hemangioma after preoperative embolization. Case report. *J Neurosurg* 47:282-285, 1977

13. Ide C, Gangi A, Rimmelin A, Beaujeux R, Maitrot D, Buchheit F, et al: Vertebral haemangiomas with spinal cord compression: The place of preoperative percutaneous vertebroplasty with methyl methacrylate. *Neuroradiology* 38:585-589, 1996
14. Jayakumar PN, Vasudev MK, Srikanth SG: Symptomatic vertebral hemangioma: Endovascular treatment of 12 patients. *Spinal Cord* 35:624-628, 1997
15. Lang EF Jr, Peserico L: Neurologic and surgical aspects of vertebral hemangiomas. *Surg Clin N Am* 40:817-823, 1960
16. Miszczyk L, Tukiendorf A: Radiotherapy of painful vertebral hemangiomas: The single center retrospective analysis of 137 cases. *Int J Radiation Oncology Biol Phys.* 82:173-180, 2012
17. Niemeyer T, McClellan J, Webb J, Jaspan T, Ramli N: Brown-Sequard syndrome after management of vertebral hemangioma with intralesional alcohol. A case report. *Spine* 24: 1845-1847, 1999
18. Shinozaki M, Morita A, Kamijo K, Seichi A, Saito N, Kirino T: Symptomatic T2 vertebral hemangioma in a pregnant woman treated by one stage combination surgery; posterior stabilization and anterior subtotal tumor resection. Case report. *Neurol Med Chir (Tokyo)* 50:674-677, 2010
19. Singh P, Mishra NK, Dash HH, Thyalling RK, Sharma BS, Sarkar C, et al: Treatment of vertebral hemangiomas with absolute alcohol (ethanol) embolization, cord decompression, and single level instrumentation: A pilot study. *Neurosurgery* 68:78-84, 2011
20. Yadav N, Prabhakar H, Singh GP, Bindra A, Ali Z, Bithal PK: Acute hemodynamic instability during alcohol ablation of symptomatic vertebral hemangioma: A prospective study. *J Clin Neurosci* 17:810-811, 2010
21. Yang ZY, Zhang LJ, Chen ZX, Hu HY: Hemangioma of the vertebral column. A report on twenty-three patients with special reference to functional recovery after radiation therapy. *Acta Radiol Oncol* 24:129-132, 1985