



A Spinal Dermoid Cyst with Spontaneous Rupture into the Syrinx Cavity: A Case Report

Kendiliğinden Sirinks Kavitesi İçine Açılmış Spinal Dermoid Kist: Bir Olgu Sunumu

Kerem Mazhar OZSOY¹, Ali Ihsan OKTEN¹, Ali ARSLAN¹, Ebru GUZEL², Aslan GUZEL¹, Ahmet CENNET³

¹Adana Research and Training Hospital, Department of Neurosurgery, Adana, Turkey

²Adana Research and Training Hospital, Department of Radiology, Adana, Turkey

³Adana Research and Training Hospital, Department of Pathology, Adana, Turkey

Corresponding Author: Kerem Mazhar OZSOY / E-mail: mazhartac95@hotmail.com

ABSTRACT

Dermoid cysts are rare benign congenital tumors comprising 1.1 % of the spinal tumors, with lumbosacral region and cauda equina being the common sites. Many cranial cases with spillage of cyst contents into the subarachnoid space have been reported. We report an extremely unusual case of symptomatic spinal dermoid cyst that ruptured into the syrinx cavity. The gold standard treatment is complete resection of both cyst wall and content in dermoid cysts. However, there is no consensus for the treatment of the syrinx cavity. Observation of similar cases would give us more information about treatment options and the progression of these lesions.

KEYWORDS: Dermoid cyst, Spinal tumor, Syrinx cavity

ÖZ

Dermoid kistler nadir, iyi huylu sıklıkla lumbosakral ve kauda equina bölgelerinde görülen, spinal tümörlerin %1,1'ini oluşturan konjenital tümörlerdir. Kist içeriğinin subaraknoid mesafeye yayılması literatürde kraniyal olgularda oldukça sık karşılaşılr. Biz oldukça nadir görülen sirinks kavitesine açılmış semptomatik bir spinal dermoid olgusunu sunduk. Dermoid kistlerde altın standart tedavi, kist duvarının ve içeriğinin çıkartılmasıdır fakat sirinks kavitesinin tedavisi ile ilgili bir fikir birliği yoktur. Benzer olguların incelenmesi bize bu olguların tedavi seçenekleri ve ilerleyişleri hakkında bilgi verecektir.

ANAHTAR SÖZCÜKLER: Dermoid kist, Spinal tümör, Sirinks kavitesi

INTRODUCTION

Dermoids are benign entities arising as a result of dysembryogenesis during the gastrulation phase of development. The onset is usually insidious or due to mass lesion but sometimes there are acute meningitic complaints or increased intracranial pressure as a result of cyst rupture and spillage of the irritative contents into the subarachnoid space. Fatty droplets within the ventricular system and subarachnoid space have been reported in many cases, but fat particles in the dilated central spinal canal were reported in only a few cases and are unexpected (1,2,6). Fatty contents within the syrinx cavity may be a sign of an underlying dermoid or epidermoid tumor and a whole spine and cranial magnetic resonance imaging (MRI) should be performed in such cases.

CASE REPORT

A 30-year-old male presented with a 6-month history of progressive weakness in his legs and upper extremity numbness for 3 months. His pain perception and temperature sensation were severely disturbed. Examination demonstrated 3/5 lower extremities and 4/5 upper extremities muscle weakness.

Deep tendon reflexes were hyperactive. Whole spine MRI examination showed a slightly lobulated, contoured, heterogeneous tumor mass with hyperintense regions within on T-1W images and rostral extension of the fat droplets through the long segment of the syrinx cavity (Figure 1, 2). Cranial MRI was normal.

A laminoplasty was performed from thoracic 12 to lumbar 2. Capsulated collection of squamous debris and a well-formed hair tumor were removed. T1 laminoplasty was performed through a small midline syringotomy to remove fat droplets within the syrinx cavity. Histological examination confirmed the diagnosis of dermoid cyst (Figure 3). Steroids were administered and the patient recovered well with decreased syrinx cavity size on control MRI (Figure 4).

DISCUSSION

Dermoid cysts occur predominantly in the lumbosacral region, involving the cauda equina and conus medullaris (5, 7).

Congenital intradural dermoid cysts represent a developmental malformation, with the defect in gastrulation affecting

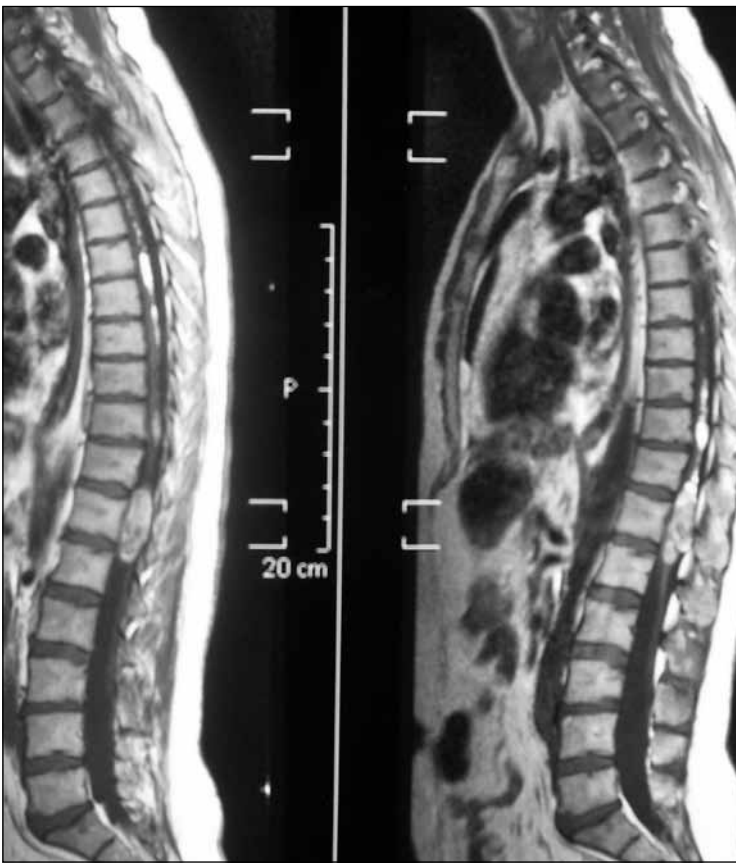


Figure 1: Sagittal whole spine non-contrast T-1 MR images showing a lobulated conus medullaris mass with hyperintense fat content in the enlarged syrinx cavity.

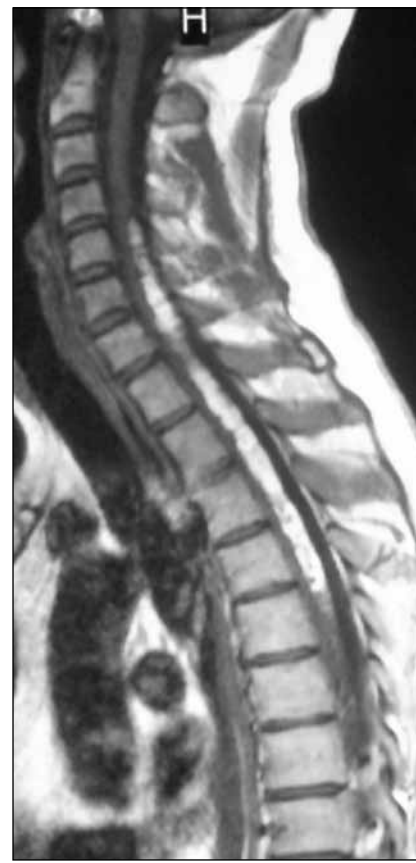

Figure 2: Sagittal T-1 MR images showed a huge syrinx cavity with hyperintense fat content from C-4 to T-5.

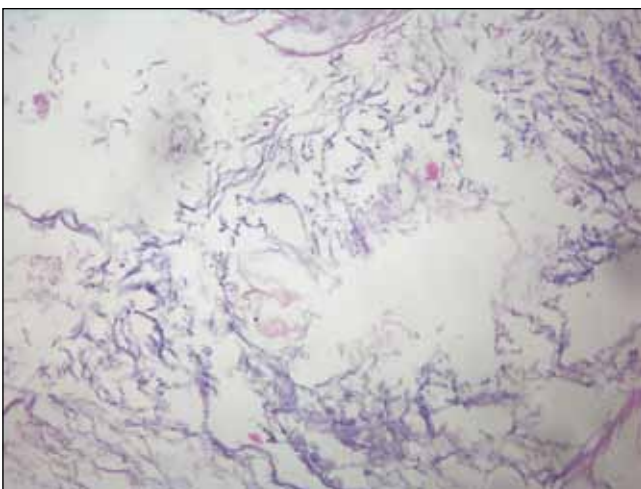


Figure 3: Photomicrograph showing desquamated squamous epithelium and keratinous debris. Hematoxylin and eosin stain, magnification x200.

the surface ectoderm and causing a secondary disruption of neural tube closure (5, 3). Dermoids contain elements of the dermis such as hair and hair follicles and apocrine, sebaceous,

or sweat glands. Although these lesions exist at birth, symptoms may not develop until adulthood because of their slow growth (8).

Syringomyelia is a cystic cavitation of the spinal cord. The pathogenesis of syringomyelia has traditionally been unclear but there are numerous hypotheses to rule out syrinx formation. A terminal syringomyelia may occur due to a mass lesion in the cauda equina region. However, an extensive syrinx cavity due to a cauda equina lesion is unexpected.

Much has been written and said about the risk of chemical meningitis associated with intraoperative spillage of cyst contents or preoperative cyst rupture. This has also been reported as the radiographic finding of small fat globules in the subarachnoid and intraventricular spaces (4). With the same mechanism, fatty droplets in the central canal may form an inflammatory process in ependymal cells that undergo sclerotic changes. Due to obstruction of the central canal, a syrinx develops.

An extensive symptomatic syrinx cavity was also a huge problem in our case. We believe removing the fatty particles within the syrinx cavity will help recovery. We therefore added a small syringotomy to the treatment to remove fatty particles within the syrinx cavity.

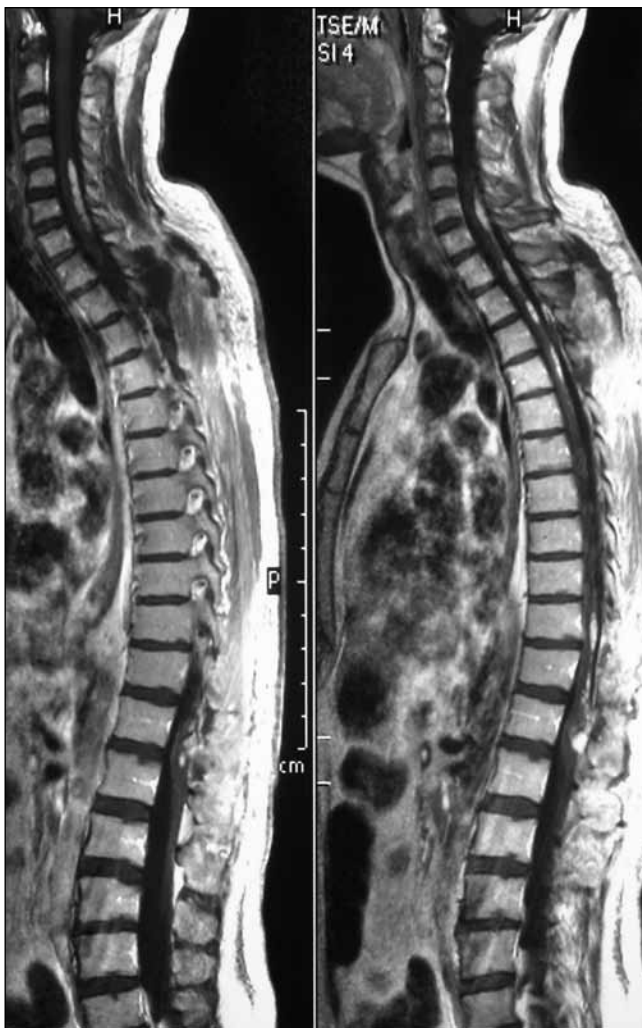

Figure 4: Early post-operative gadolinium-enhanced sagittal T-1 MR images showed resolution of the syrinx cavity and fatty contents and post-operative enhancement in the removed area of the conus medullaris mass lesion.

Treatment of dermoid cysts is primarily surgical and there is no current role for radiotherapy or chemotherapy in the treatment of these tumors. Steroids are useful in the treatment of meningitis (8).

REFERENCES

1. Barsi P, Kenez J, Varallyay G, Gergely L: Unusual origin of free subarachnoid fat drops: A ruptured spinal dermoid tumor. *Neuroradiology* 34:343-344, 1992
2. Calabro F, Capellini C, Jinkins JR: Rupture of spinal dermoid tumors with spread of fatty droplets in the cerebrospinal fluid pathways. *Neuroradiology* 42:572-579, 2000
3. Dias M, Walker M: The embryogenesis of complex dysraphic malformations: A disorder of gastrulation? *Pediatr Neurosurg* 18:229-253, 1992
4. Gormley W, Tomocek F, Qureshi N, Malik GM: Craniocerebral epidermoid and dermoid tumors: A review of 32 cases. *Acta Neurochir (Wien)* 128:1115-1121, 1994
5. Graham DV, Tampieri D, Villemure JG: Intramedullary dermoid tumor diagnosed with the assistance of MRI. *Neurosurgery* 23:765-767, 1998
6. Karadag D, Karagulle AT, Erden I: MR imaging of a ruptured intraspinal dermoid tumor with fat droplets in the central spinal canal. *Australas Radiol* 46:444-446, 2002
7. Kumar S, Gulati DR, Mann KS: Intraspinal dermoids. *Neurochirurgia* 20:105-108, 1977
8. Winn HR: Epidermoids, dermoids, and neuroenteric cysts. In Saunders WB (ed), *Youmans Neurological Surgery*, 5 th ed, Philadelphia: Pennsylvania, 2004: 1224-1226