



Surgical Treatment in Sacral Fractures and Traumatic Spinopelvic Instabilities

Sakrum Fraktürleri ve Travmatik Spinopelvik İnstabilitelerde Cerrahi Tedavi

Sedat DALBAYRAK¹, Onur YAMAN², Murat AYTEN¹, Mesut YILMAZ¹, Ali Fahir OZER³

¹Neurospinal Academy, Department of Neurosurgery, Istanbul, Turkey

²Tepecik Education and Research Hospital, Department of Neurosurgery, Izmir, Turkey

³Koc University, School of Medicine, Department of Neurosurgery, Istanbul, Turkey

Corresponding Author: Onur YAMAN / E-mail: dronuryaman@yahoo.com

ABSTRACT

AIM: Sacral fractures are generally seen together with pelvic ring fractures. They can also develop in isolated form rarely. Instability is observed in these fractures in rates reaching 30%.

MATERIAL and METHODS: Spinopelvic stabilization was applied to 10 cases with pelvic fractures together with sacral fractures and spinopelvic instability. Two cases were treated with adductive screws extending from the iliac wing to the sacrum, 5 cases with standard lumboiliac instruments and 3 cases were treated with iliac wing plates that are our own design. The cases were evaluated according demographic data, VAS, ASIA and Oswestry scores and the types of the trauma and fracture.

RESULTS: Six cases had unilateral sacroiliac instability while the instability was bilateral in 4 cases. Follow-up periods range between 6 and 91 months. Preoperative VAS was 8.4, Oswestry mean value was 91.2, postoperative late VAS was 2.2, and Oswestry was 24.4.

CONCLUSION: Serious spinopelvic instability can be talked of in sacral fractures accompanied by pelvic fractures, particularly when the anterior and posterior integrity of the pelvic ring is interrupted together. An aggressive stabilization and fixation must be performed without delay.

KEYWORDS: Sacral fracture, Spinopelvic instability, Pelvic fracture, Iliac plates

ÖZ

AMAÇ: Sakrum kırıkları genellikle pelvik halka kırıkları ile beraber görülür. Nadiren de izole olarak gelişebilir. Bu kırıklarda %30'a varan oranlarda instabilite gözlenmektedir.

YÖNTEM ve GEREÇLER: Sakrum kırıkları ile birlikte pelvik kırıkları da bulunan, spinopelvik instabilite 10 olguya spinopelvik stabilizasyon uygulandı. 2 olgu iliak kanattan sakruma yaklaşımcı vidalarla, 5 olgu standart lumboiliak enstrümanlarla, 3 olgu ise kendi dizayn ettiğimiz iliak kanat plakları ile stabilize edildi. Olgular demografik veriler, VAS, ASIA ve Oswestry skorları, travma ve kırık tiplerine göre değerlendirildi.

BULGULAR: 6 olguda tek taraflı, 4 olguda iki taraflı sakroiliak instabilite mevcuttu. Takip süreleri 6 – 91 aydır. Preoperatif VAS 8,4, Oswestry 91,2 ortalama değerleri, postop geç dönemde VAS 2,2, Oswestry 24,4 olarak değerlendirildi.

SONUÇ: Tüm omurga yükünü pelvise aktaran sakrumun, omurganın mekanik stabilitesinin sağlanmasındaki rolü göz önüne alındığında, sakrum ve pelvik travmalı hastaların değerlendirilmesi sırasında titizlik gösterilmesi önemlidir. Özellikle pelvik halkanın ön ve arka bütünlüğünün birlikte bozulduğu pelvis kırıkları ile birlikte olan sakral kırıklarda ciddi spinopelvik instabilite söz konusudur. Sakrumun kaudal, iliak kanatların kranyal migrasyonu ile ciddi pelvik dengesizlik, ayakta durma ve yürüme problemleri görülebilir. Agresif bir stabilizasyon ve füzyon yapmak, bunu da geç kalmadan yapmak gerekir.

ANAHTAR SÖZCÜKLER: Sakrum fraktürü, Spinopelvik instabilite, Pelvis fraktürü, İliak plaklar

INTRODUCTION

Sacral fractures are generally seen with pelvic ring fractures. Although the actual incidence is not known, it is estimated as 30%. In the untreated cases or cases not treated appropriately, persistent pain and reducing of motility are seen together with problems of gait and neurologic deficits can be seen (5,10,16).

Since sacral fractures are caused by high-energy traumas most of the time, other accompanying injuries must be sought. A

thorough physical examination including also neurologic and radiologic evaluations is required to determine the treatment modality. Computerized tomography of the sacrum can provide important information about the fracture pattern. Surgical intervention as a combination of neural decompression and stabilization is frequently indicated in patients with neurologic deficits and lumbosacral instability. Satisfaction of the patients after the surgical intervention has not been definitely documented; however, neurological improvement has been found following the timely intervention (11).

Sacral fracture accompanies 45% of all the pelvic fractures. Less than five percent of the sacral fractures are isolated injuries. They mostly occur with direct impact or falling on the sacrum (2). Neurologic injuries accompany 25% of the sacral fractures. Thirty percent of all the sacral fractures are diagnosed in the late period. When the anatomic importance of the sacrum as the bony ring of the pelvis and its role in the mechanic stability is considered, meticulousness in the evaluation of the patients with pelvic trauma is essential (4,15). When the literature is reviewed, it is seen that the injury mechanism resulting in sacral fractures are typically high-energy mechanisms. Sacral fractures are frequently missed at the initial presentation. A high index of suspicion and targeted examination are recommended with these reasons, because delayed diagnosis mostly cause poor outcome. Thoracolumbar fractures can also be present in patients with known sacral fractures (10,14).

Sacral fractures have been classified by Denis et al. (4). This classification divides sacrum to 3 regions according to the neural foramina (Figure 1). Fractures of the first region are in the lateral of the neural foramen, fractures of the second region pass through the foramina, and fractures of the third region involve the spinal canal. Fractures of the first region are the most frequent fractures and are together with the

deficits of the sciatic nerve or with L5 nerve radix in 6% of the cases. Fractures of the second region is the second most frequent pattern and L5, S1 and S2 radix lesions are present in 28% of the unilateral injuries. Fractures of the third region are the type with the most neurologic deficits and 60% of the patients are symptomatic. Intestinal, bladder and sexual dysfunction develops in 76% of the patients with third region fractures and neurologic symptoms. Differentiating between the upper and lower transverse fractures is important as regards treatment since neurologic injuries are frequent in the third region injuries. The lower transverse fractures mostly occur in the S4 level and symptomatic. The upper transverse fractures occur in levels higher than the S4 level and the free fragments within the the sacral canal are important (10,16).

MATERIAL and METHOD

Ten cases operated because of sacral fracture and spinopelvic instability were examined retrospectively. Reasons of application, fracture types occurring as a result of the trauma, preoperative and postoperative ASIA neurologic status scale scores, VAS and Oswestry scale scores and clinical conditions are evaluated. Radiologically, preoperative and postoperative changes with computerized tomography, MRI, and plain x-rays were examined.

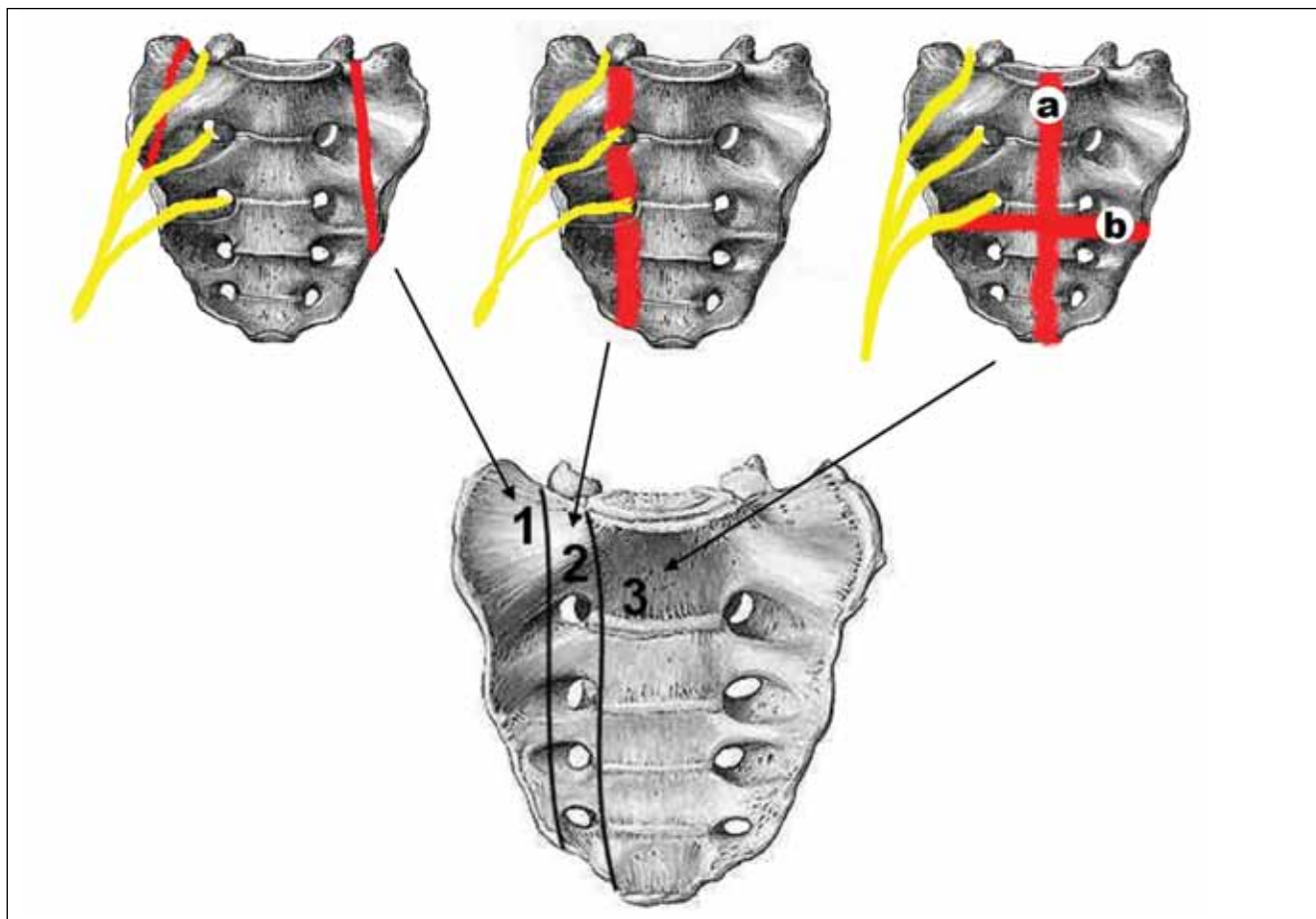


Figure 1: Classification of sacral fractures (4).

Sacral fractures were classified according to Denis sacral fracture classification.

All the patients were operated under general anesthesia in prone position with the accompaniment of biplane scopy and under elective conditions.

RESULTS

Six of the cases are males (60%), and 4 are females (40%). Ages range between 17 and 54 and the mean age is 28.8. The causes of trauma are traffic accident in 5 cases (50%), falling from a height in 4 cases, out of which 2 are suicidal (40%), and falling of a heavy object in one case (Table I).

Sacral fracture types were evaluated according to Denis. There was type 1 in 4 cases, type 2 in 3 cases and type 3 fractures in 2 cases. There was unilateral sacroiliac instability in 6 cases and bilateral sacroiliac instability in 4 cases.

In one case (case 9) there was no fracture in the sacrum. Together with a dissociation fracture in the left iliac wing, there was dissociation in the sacroiliac joints bilaterally and sacroiliac dislocation accompanied by the caudal displacement of the sacrum.

Three cases were operated in the early period (2-10 days), and 7 cases were operated in the late period (21-320 days) (Table II).

As regards complications, postoperative infection developed in one patient with L5-S1 facet joint dislocation and sacral fracture that L4-Sacral stabilization was performed in an attempt to preserve the sacroiliac joint. Infection was successfully treated with medical therapy and hyperbaric oxygen therapy. Later, pseudoarthrosis developed and spinopelvic stabilization was performed in a second operation using iliac wing plates.

Table I: Clinical Evaluation of the Patients and Fracture Types According to the Denis Classification

Case	Age	Sex	Fracture Type	Preop VAS	Postop VAS	Preop Oswestry	Postop Oswestry	Preop ASIA	Postop ASIA	Urine/anal Incontinence
1. YT	34	M	1	8	0	90	10	C	E	-
2. SK	22	F	3	9	2	86	14	A	A	+
3. RB	30	M	3	9	1	94	22	D	E	-
4. NC	27	M	2	9	3	90	18	C	E	+
5. SB	17	F	2	8	2	92	28	C	D	+
6. GA	29	F	1	9	4	96	34	D	E	-
7. NS	18	F	1	9	3	92	20	D	E	-
8. MK	20	M	2	9	2	90	24	E	E	-
9. MT	37	M	-	10	4	94	36	D	D	-
10. GS	54	M	1	8	1	88	16	E	E	-

Table II: Reasons of Trauma of the Cases, Additional Pathologies and the Treatments Applied

Case no	Reasons of Trauma	Operation Day	Surgical Modality Used	Additional Pathologies
Case 1	Falling of a heavy object on the patient	90	Iliosacral screws	Pelvic fracture
Case 2	Falling from a height	45	T11-Iliac stabilization	L1Burst fracture -paraplegic
Case 3	Traffic accident	320	L4-Iliac stabilization	Pelvic fracture
Case 4	Traffic accident	2	L4- Iliac stabilization + decompression	Pelvic fracture
Case 5	Falling from a height	42	L3- Iliac stabilization	Pelvic fracture
Case 6	Traffic accident	5 88	1: L4-sacral stabilization 2. Stabilization with L4-iliac plates	L5-S1 facet interlocking + Pelvic fracture
Case 7	Traffic accident	21	Stabilization with L4-iliac plates	Pelvic fracture
Case 8	Traffic accident	38	Stabilization with L3-Iliac plates	Pelvic fracture
Case 9	Falling from a height	75	Stabilization with L4-iliac plates	Sacroiliac dislocation
Case 10	Falling from a height	10	Iliosacral screws	Dissociation of the symphysis pubis

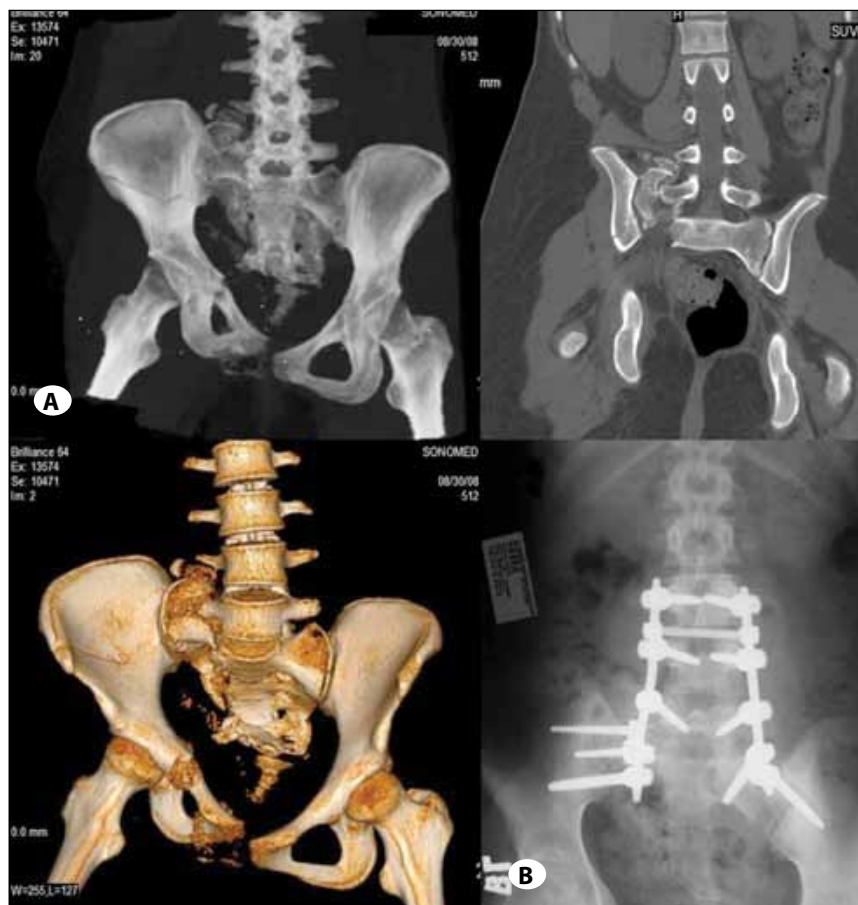


Figure 2: 17-year-old female. Suicide, falling from a height. Denis zone 2 sacral fracture and dislocation, spinopelvic unilateral dissociation together with pelvic fracture on the same side.

A) The patient was operated on day 42. Preoperative traction and intraoperative reduction was tried; however, complete reduction was not possible. Lumboiliac stabilization and fusion was performed. **B)** Postoperative year 2: no complaints, fusion is completed with no deficits.

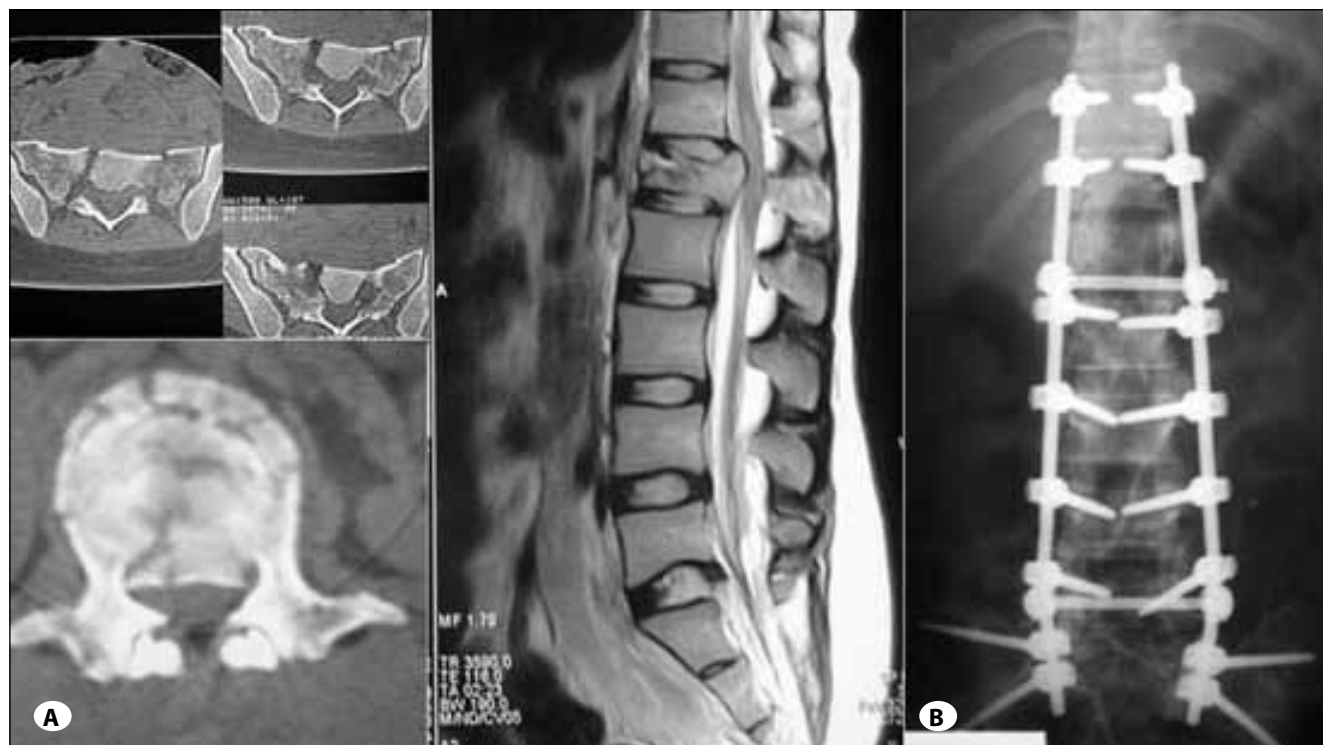

Figure 3: 22-year-old female. Falling from a height. **A)** Denis zone 3 sacral fracture and T12 Burst fracture, paraplegic, ASIA A. **B)** Spinopelvic stabilization and fusion between T10 and iliac wings. Postoperative year 4: ASIA A, fusion is completed.

Five cases were stabilized using standard lumboiliac instruments (Figure 2A,B; 3A,B), 2 cases with adduction screws extending from the iliac wing to sacrum (Figure 4), and 3 cases with iliac wing plates that are our own design (Figure 5A-C). The surgical approaches used are outlined in the Table II.

Follow-up periods range between 6 and 91 months, and the mean period is 39.2 months.

Preoperative mean values of the cases: mean VAS score has been found as 8.4, and the mean Oswestry scale score has been found as 91.2. The mean VAS in the postoperative month 6 was 2.2, and Oswestry was 24.4. The mean surgery period was 245 minutes and the amount of bleeding was 1980 ml.

DISCUSSION

Sacral fractures constitute a series of complex damages including the interruption of the pelvic ring, nerve root damage, cauda equina syndrome, and direct or indirect damages of the spinal segments (11). In general, patients

with a stable pelvis and neurologically stable are best treated with nonsurgical methods. Together with this, outcomes of the nonsurgical methods are not clear. There are several studies comparing the surgical treatments with nonsurgical treatments based on evidences. Surgical treatment indications for sacral fractures include neurologic deficits as the neural compression, fractures with pseudoarthrosis, and widespread posterior lumbosacral deterioration (5). Relative indications for surgery include the patients with multiple injuries to ensure early mobilization with the purpose of facilitating the rehabilitation of the sacral stabilization. Objectives of the surgical sacral stabilization include the stabilization of the fracture, ensuring the lumbosacral balance, improving the neurologic status and reducing all the disabilities. Surgical fixation of the sacral fractures ensures the stability allowing early mobilization, protection of the local neurovascular structures and reduced pelvic pain (3,7,11,18).

In a series with unstable first and second region fractures including 60 patients, Routt et al. showed that delays of

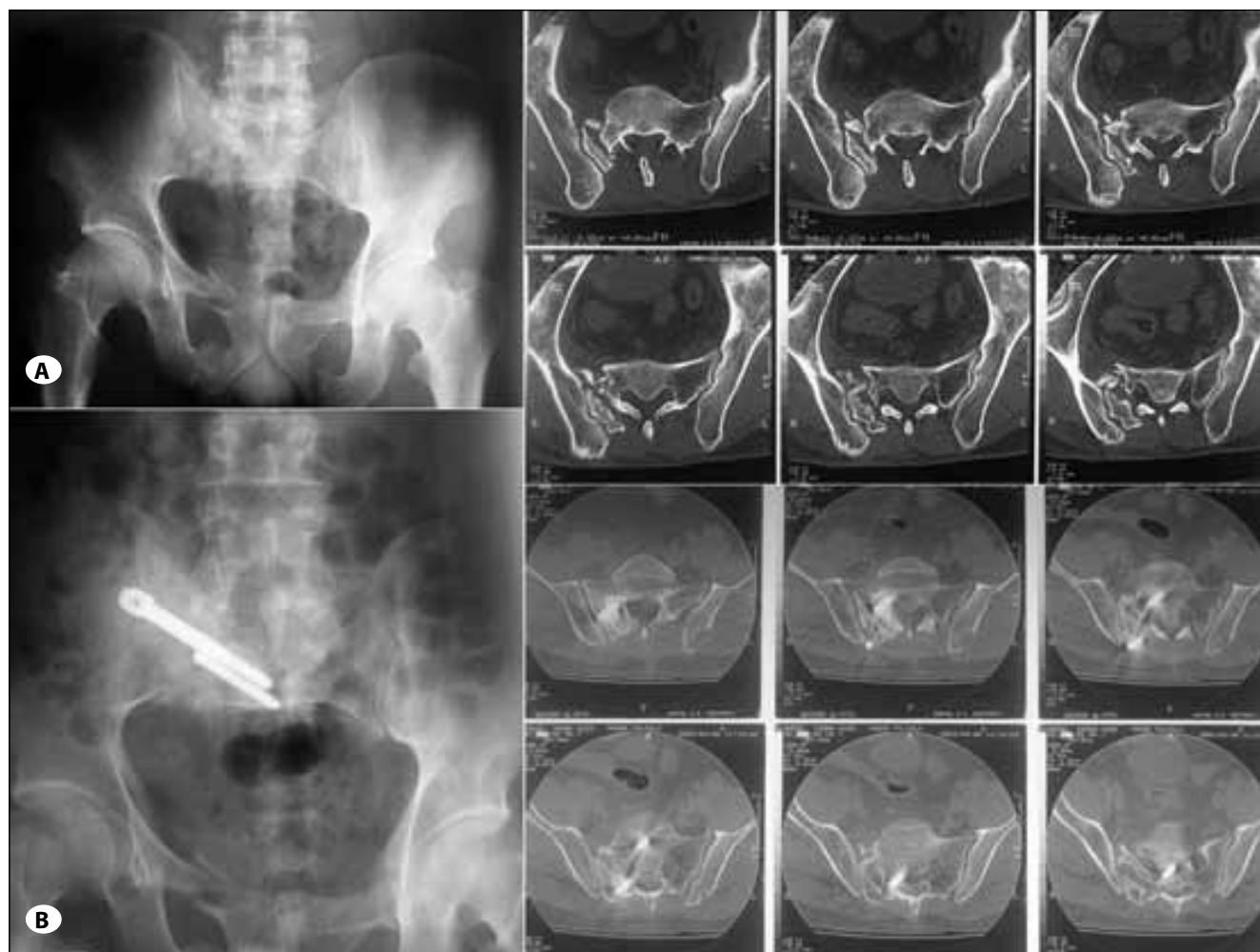


Figure 4: 34-year-old male. Falling of a heavy object on the patient (A) Zone 1 sacral fracture and gait problems because of spinopelvic dissociation. Radicular pain in right L5 root, EHL 3/5, AT 4/5. (B) The patient was operated in the day 90. Following the decompression and traction, sacroiliac stabilization was ensured with two screws from the iliac wing to the sacrum and fusions. Postoperative year five 5, no pain and no deficit, fusions is completed.

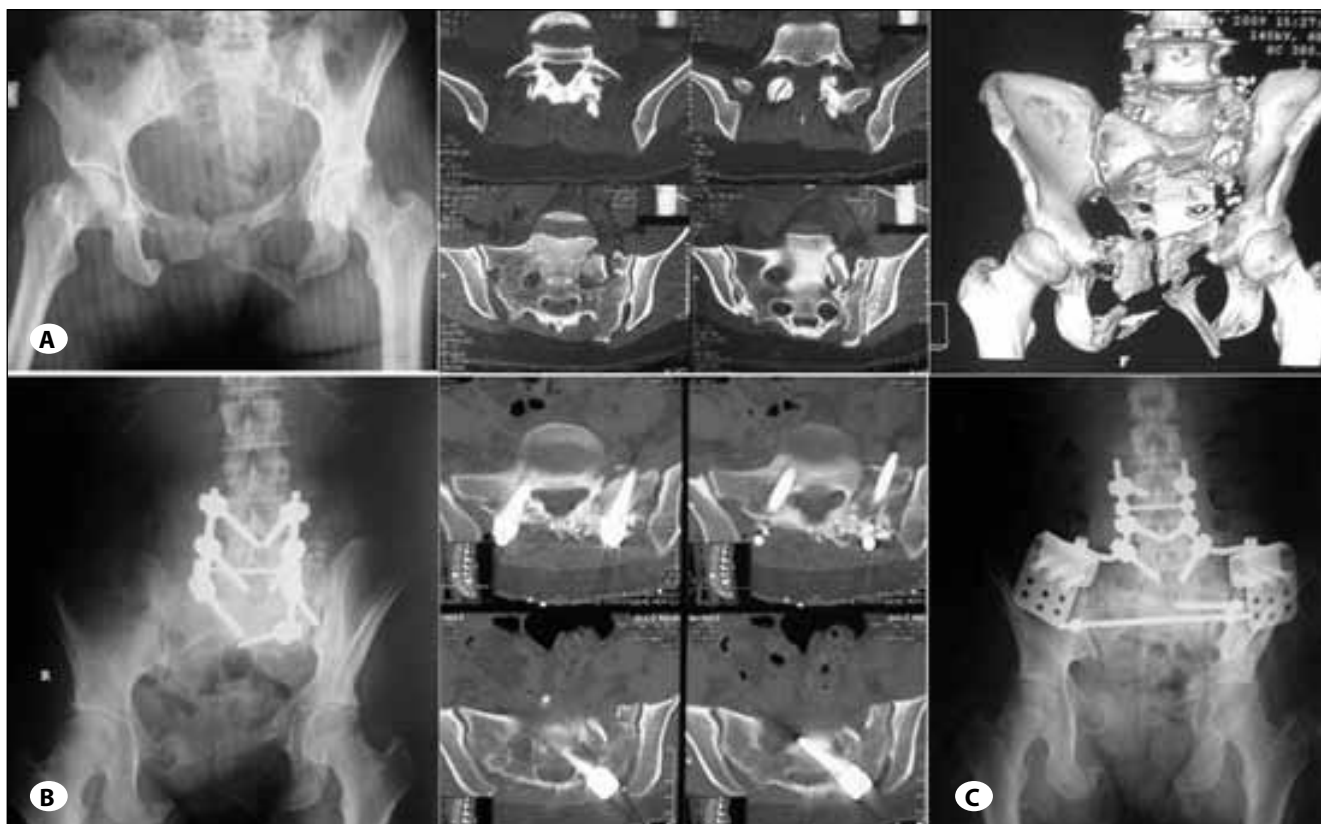

Figure 5: 29-year-old female. In-vehicle traffic accident: **A)** Together with Left L5-S1 facet dislocation, left Zone 1 sacral fracture, fracture and spinopelvic dissociation in the anterior of the pelvic ring bilaterally. **B)** Lumbosacral stabilization in the first operation with L5-S1 facet joint reduction and preserving the sacroiliac joint. Pseudoarthrosis developed in the postoperative period related to infection. **C)** Second operation: debridement and lumbopelvic stabilization using the iliac wing plates. Postoperative year 2: fusion has occurred, no pain and no deficit.

surgery of 5 days or longer were related to poorer closed reduction rates. Denis et al. reported that delays longer than 2 weeks had poorer outcomes in neurologically consistent patients (4,12). Late surgery was performed in 7 of our cases (70%) and this affected the success of the reduction negatively. Importance of early surgery must be stressed in preventing the spinopelvic imbalance.

Neurologic deficits can range between incomplete radicular radiculopathy to complete transection of the cauda equine. The prevalence of transection of roots in transverse sacral fractures is 35% (1,2,10,11). Contusion of the sacral roots can be possible because of the displacement in the fracture line or angulation of the sacral fractures. Sometimes the fracture is decompressive, and some other times, they can be decompressed under traction. Decompression surgery must be performed either directly with the reduction of the fracture or directly through laminectomy or foraminectomy, depending on the features of the fracture and form of the compression. Isolated decompression is not useful in transected or avulsed radix cases. There are no definite surgical indications for the decompression (1,9,15). Together with this, decompression of the sacral nerve roots is more difficult after the healing of the fracture in patients with neurologic deficits

related to sacral fractures because of epineural fibrosis and increased scarring of the sacral canal and foramen (10,16,18). Therefore, neural elements must be decompressed in the early period within 24 to 72 hours to minimize further damage (10,11). Extension of the delay in patients with canal involvement and accompanying neurologic deficit can have negative effects on the neurologic improvement (12). In our study, except for the ASIA A related to T12 Burst fracture in addition to sacral fracture (case 2-Figure 3A,B) and the patient with ASIA D dislocation without fracture (case 9), neurologic deficits improved, and surgical direct or indirect decompression ensured this.

Fountain et al. showed that patients with neurologic damage and displaced transverse sacral fractures benefit from the decompression performed with posterior approach. Progressive neurologic improvement was found in 5 patients out of 6 with neurogenic bladder and transverse sacral fractures in the period of 4 to 6 months following the decompression. The actual result of the surgical decompression is not clear in this 80% improvement reported. Patient show a tendency towards improvement; however this being a result of the decompression or the natural course is not known (5).

Stabilization of sacral fractures is frequently applied together with decompression. Decompression alone can cause increase of instability (6,7). There are two major segments in the sacral fractures causing spino-pelvic instability. Dissociation of the spine and sacral fragment of the pelvis from the pelvis and the peripheral sacral fragment (spino-pelvic dissociation) accompanies the picture (12). Stabilization methods for the sacral fractures include anterior pelvic fixation, sacroiliac screwing, direct sacral fixation and lumbopelvic fixation with the purpose of repairing the stability of the lumbosacral joint (3,7,8,9,13). The decision for which sacral stabilization option will be used depends not only on the biomechanical requirements and degree of the fracture, but also on the tolerance of the soft tissues. The most stable construct includes longitudinal rods and lumbar pedicle screws united with transverse connectors to facilitate the reduction of the fracture and early ambulation of the patient without any support (7,8,12,15,16). In cases with complete interruption of the integrity of the pelvic anterior ring or in complicated cases, use of the plates that we have developed fixed on the iliac wings (3) in combination with other methods provide a stronger stabilization.

Lumbopelvic fixation is designed to remove the effects of instability. Anchoring the lumbosacral segmental spinal fixation onto the iliac wings will ensure solid fixation on both components of the fracture and will neutralize the forces creating deformation. This fixation method is particularly valuable, because restrictions of the sacral anatomy make the stable fixation with more conventional plate-and-screw constructs more difficult. Use of locking iliac wing plates in transverse sacral fractures have been increasing in the recent years and provides a new tool for stabilization. This technique is a rather effective method in the correction of translation deformities or residual angular deformities in transverse fractures (3).

In the literature review we performed for sacral fractures, it is stated that surgical procedures come in the first place in patients that neurological findings are prominent (1,2,4,12,13,17,18), they followed patients with neurologic complications without surgical intervention and obtained satisfactory results (6,18), current indications were not present to dictate the location of surgical decompression in patients with neurologic complications (6,12,13), there were no definite indications for the surgical or nonsurgical treatments statistically for the patients with neurologic complications (10,13,14), and there can be rewarding neurologic improvements after long-term clinical or radiological follow-up although reduction is not suitable for many patients despite all (1,3). In our study, clinical and radiological results are satisfactory after the mean follow-up period of 39.2 months. Except for the case that pseudoarthrosis developed because of infection (case 6- Figure 5), unproblematic fusion occurred in 9 case (90%). Fusion occurred in the said case also following the second operation. Near-complete improvement was seen in six patients out of eight with neurologic deficits, and neurologic improvement occurred in 75% patients (Table I).

As seen in the literature review, the reason for the lack of definite proven indications for which surgical procedures or medical follow-up would be used in patients with sacral fractures is that it has been proven that the neurological deficits can be improve within the natural course of the sacral fractures with neurologic deficits.

CONCLUSION

We observed the importance of surgery in ensuring the early mobilization of the patient and in preventing any possible painful deformity and pseudoarthrosis in sacral fractures with spinopelvic instability and the importance of a strong spinopelvic fixation that will provide the best biomechanical stability.

REFERENCES

1. Bodkin PA, Choksey MS: Management of a sacral fracture with neurological injury. *J Orthop Sci* 11(5):524-528, 2006
2. Bonin JG: Sacral fractures and injuries to the cauda equina. *J Bone Joint Surg Br* 27:113-127, 1945
3. Dalbayrak S, Yilmaz M, Kaner T, Gokdag M, Yilmaz T, Sasani M, Oktenoglu T, Ozer AF: Lumbosacral stabilization using iliac wings: A new surgical technique. *Spine* 36(10):E673-677, 2011
4. Denis F, Davis S, Comfort T: Sacral fractures: An important problem. Retrospective analysis of 236 cases. *Clin Orthop Relat Res* 227:67-81, 1988
5. Fountain SS, Hamilton RD, Jameson RM: Transverse fractures of the sacrum. A report of six cases. *J Bone Joint Surg Am.* 59(4):486-489, 1977
6. Griffin DR, Starr AJ, Reinert CM, Jones AL, Whitlock S: Vertically unstable pelvic fractures fixed with percutaneous iliosacral screws: does posterior injury pattern predict fixation failure? *J Orthop Trauma* 20(1 Suppl):S30-36; discussion S36, 2006
7. Keel MJ, Benneker LM, Siebenrock KA, Bastian JD: Less invasive lumbopelvic stabilization of posterior pelvic ring instability: Technique and preliminary results. *J Trauma* 71(3):E62-70, 2011
8. Lindahl J: Lumbopelvic fixation for sacral fracture-dislocations. *Suomen Ortopedia ja Traumatologia* 32: 125-127, 2009
9. Lykomitros VA, Papavasiliou KA, Alzeer ZM, Sayegh FE, Kirkos JM, Kapetanios GA: Management of traumatic sacral fractures: A retrospective case-series study and review of the literature. *Injury* 41(3):266-272, 2010
10. Mehta S, Auerbach JD, Born CT, Chin KR: Sacral fractures. *J Am Acad Orthop Surg* 14(12):656-665, 2006
11. Robles LA, Plantillas E: An unusual transverse sacral fracture treated with early decompression. Case report. *J Neurosurg Spine* 5(6):546-549, 2006
12. Routt ML Jr, Simonian PT, Swiontkowski MF: Stabilization of pelvic ring disruptions. *Orthop Clin North Am* 28:369-388, 1997
13. Schildhauer TA, Bellabarba C, Nork SE, Barei DP, Routt ML Jr, Chapman JR: Decompression and lumbopelvic fixation for sacral fracture-dislocations with spino-pelvic dissociation. *J Orthop Trauma* 20(7):447-457, 2006

14. Schmidek HH, Smith DA, Kristiansen TK: Sacral fractures. *Neurosurgery* 15(5):735-746, 1984
15. Vaccaro AR, Kim DH, Brodke DS, Harris M, Chapman JR, Schildhauer T, Routt ML, Sasso RC: Diagnosis and management of sacral spine fractures. *Instr Course Lect* 53:375-385, 2004
16. Vilela MD, Jermani C, Braga BP: Lumbopelvic fixation and sacral decompression for a U-shaped sacral fracture: Case report. *Arq Neuropsiquiatr* 65(3B):865-868, 2007
17. Yi C, Hak DJ: Traumatic spinopelvic dissociation or U-shaped sacral fracture: A review of the literature. *Injury* 43(4):402-408, 2012
18. Zelle BA, Gruen GS, Hunt T, Speth SR: Sacral fractures with neurological injury: Is early decompression beneficial? *Int Orthop* 28(4):244-251, 2004