

Spontaneous Cerebrospinal Fluid Rhinorrhea Associated With Temporal Lobe Meningoencephalocele in the Lateral Sphenoid Sinus in An Adult: Case Report

Lateral Sfenoid Sinüste Temporal Lob Meningoensefaloseline Bağlı Olarak Gelişen Bir Spontan Rinore Olgusu

ABSTRACT

Temporal lobe meningoencephalocele in the lateral sphenoid sinus is an uncommon, and potentially dangerous, pathological condition. Adult patients with meningoencephalocele in the sphenoid sinus often present with spontaneous cerebrospinal fluid rhinorrhea and should be considered for transsphenoidal or transcranial repair. Surgical repair of this fistula is recommended in order to reduce the risk of meningitis. Temporal lobe encephaloceles in the lateral sphenoid sinus have rarely been reported. Careful preoperative evaluation and localization of the sphenoid defect are critical for the selection of the optimal surgical approach for the repair of the skull base defect. Unfortunately, the definite location of the fistula is often difficult to establish. In this report, we present a 42-year-old female who had cerebrospinal fluid (CSF) rhinorrhea without meningitis for three years. We also discuss the relevant medical literature emphasizing the difficulty of making the diagnosis and the treatment approach.

KEY WORDS: Meningitis, meningoencephalocele, sphenoid sinus, spontaneous rhinorrhea

ÖZ

Lateral sfenoid sinus içerisinde temporal lob meningoensefaloseli görülmesi oldukça nadir olmasına karşın, buna bağlı spontan rinore gelişimi olağan bir durumdur. Menenjit gelişimine sebep olması nedeniyle defekt transsfenoidal veya transkraniyal yaklaşımla tamir edilmelidir. Spontan rinore varlığında dikkatli preoperatif değerlendirme yapılmalı ve sfenoid sinüsteki defekt tam olarak ortaya konularak uygun tedavi seçeneği belirlenmelidir. Ancak her zaman defekt yerini bulmak mümkün olmamaktadır. Biz bu çalışmada üç yıldan beri spontan rinoresi olmasına rağmen menenjit geçirmeyen 42 yaşındaki bir kadın olguyu sunduk. Teşhis ve cerrahi tedavi yaklaşımındaki güçlüğü de literatür bilgileri eşliğinde tartışık.

ANAHTAR SÖZCÜKLER: Menenjit, meningoensefalosel, sfenoid sinus, spontan rinore

Ahmet MENKÜ
Bülent TUCER
Ali KURTSOY
İ. Suat ÖKTEM
Cüneyt GÖÇMEZ
Hidayet AKDEMİR

Department of Neurosurgery,
School of Medicine, Erciyes University,
38039, Kayseri, Turkey

Received : 02.06.2003
Accepted : 08.01.2004

Correspondence address:
Ahmet MENKÜ
Department of Neurosurgery
Erciyes University, Medical School
38039 Kayseri / TURKEY
E-mail: menkua@erciyes.edu.tr
Fax : +90 352 4372934

INTRODUCTION

Lateral sphenoid sinus meningoencephalocele is a rare congenital anomaly in adults. A meningoencephalocele usually involves herniation of the frontal lobe tissue through an anterior cranial fossa defect into the ethmoid sinus or nasal cavity. Encephaloceles can also result from temporal lobe herniation into the sphenoid sinus through a middle fossa defect. Within the sphenoid, meningoencephaloceles are thought to occur most commonly in the central or midline aspect of the sinus. They consist of herniation through a sphenoidal bony defect and contain cerebrospinal fluid and neural tissue. Sphenoid sinus meningoencephalocele may cause spontaneous cerebrospinal fluid (CSF) rhinorrhea because of the thickened mucosal lining surrounding the meningoencephalocele sac in the sphenoid sinus. Most present in childhood with repeated bouts of meningitis, although presentation in adulthood with an asymptomatic sphenoid sinus mass has been well documented (1, 3).

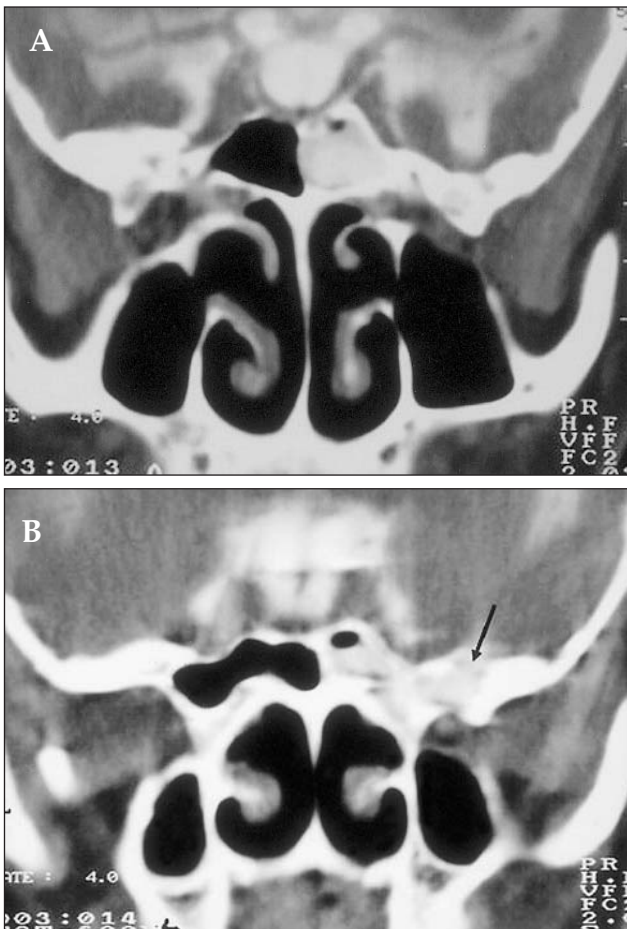


Figure 1A and B. CT cisternography scan shows CSF tracking through the defect (black arrow) in the anterior portion of the lateral wall of the right sphenoid sinus

Careful preoperative evaluation and localization of the sphenoid defect are critical for the selection of the optimal surgical approach for repair of the skull base defect. Unfortunately, the definite location of the fistula is often difficult to establish.

CASE REPORT

A 42-year-old female presented with spontaneous CSF rhinorrhea without meningitis for three years. Neurological examination was normal. She had no history of cranial trauma or surgery. CT cisternography showed a defect in right sphenoid sinus with contrast leakage into the sinus (Figure 1A, B). MR and MR cisternography revealed a defect in the lateral wall of the right sphenoid sinus, with an anteromedial temporosphenoidal encephalocele

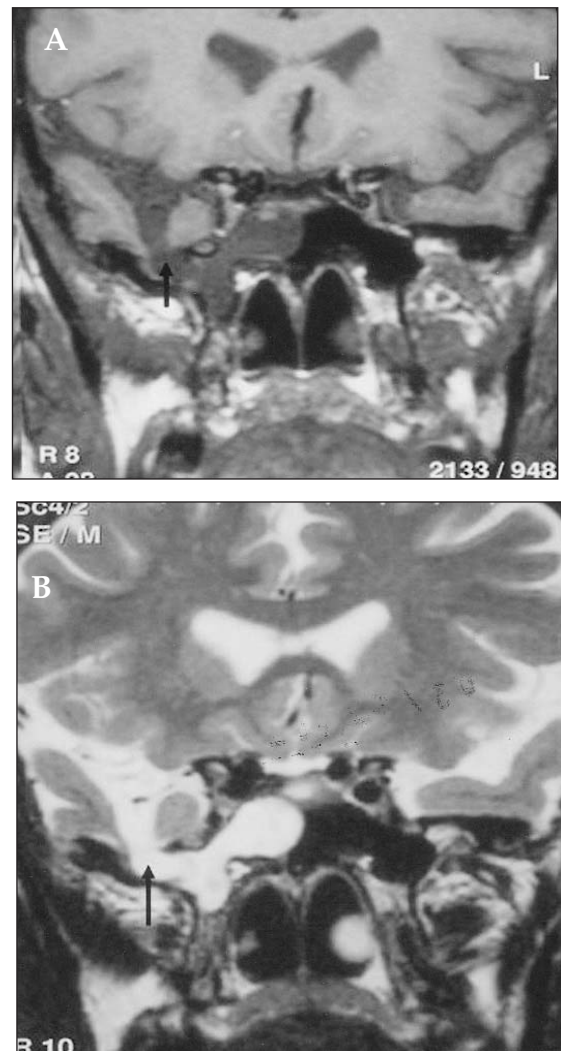


Figure 2 A and B. Coronal T1- (A) and T2- (B) weighted MR images of the brain shows brain tissue herniating through the defect (black arrow) in the anterior portion of the lateral wall of the right sphenoid sinus

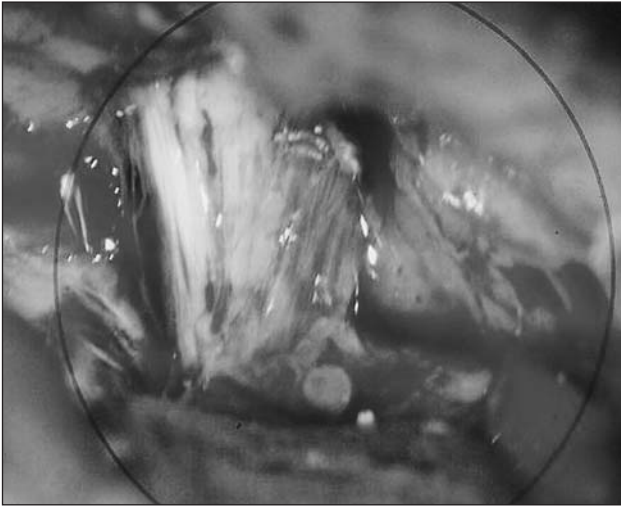


Figure 3. The surgical appearance of the sac of the meningoencephalocele in the anteromedial temporal fossa

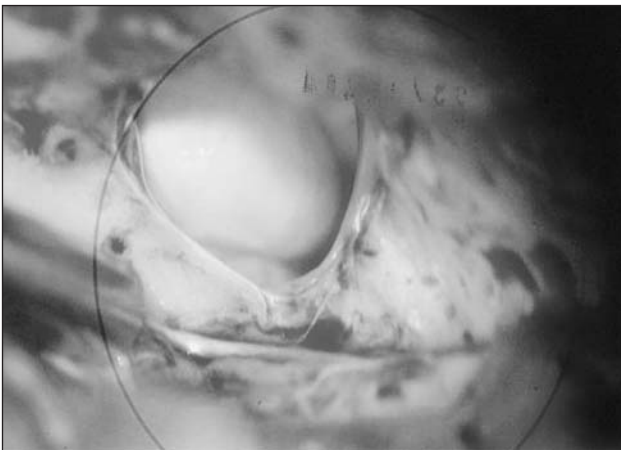


Figure 4. The surgical appearance of the bone defect in the anteromedial temporal fossa after resecting the sac

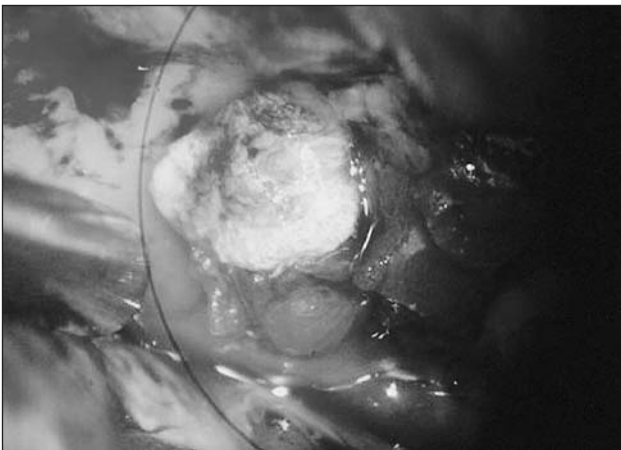


Figure 5. The surgical appearance of the duraplasty and bone flap after repair of the dural and bone defects

associated with contrast leakage into the sinus (Figure 2A, B). The fistula in our case was localized in a lateral recess of the sphenoid sinus. We performed a right pterional craniotomy. The dural and bone defect were seen during surgery (Figure 3, 4) and repaired via the transcranial extradural approach. As the dural defect was plugged with temporalis fascia, muscle and the fibrin glue, the bony defect was closed with a flat piece of inner table of craniotomy flap (Figure 5). The postoperative course was uneventful, and she was discharged seven days postoperatively. No recurrence of rhinorrhea was observed during the follow-up period (1 year).

DISCUSSION

Lateral sphenoid encephaloceles, especially within the lateral aspect of the sphenoid sinus when the sphenoid sinus has pneumatized extensively into the pterygoid recess, are considered exceedingly rare. Temporal lobe encephaloceles in the lateral sphenoid sinus have rarely been reported (2, 5, 6). Careful preoperative evaluation and localization of the sphenoid defect are critical for the selection of the optimal surgical approach for repair of the skull base defect (6). Computerized tomographic and radionuclide cisternography are two commonly used techniques for preoperative identification of the CSF fistula when it cannot be seen clearly with nasal endoscopy (7). The diagnosis is based on the history and the high-resolution brain and skull base CT-scans in conjunction with opaque fluid injection into the subarachnoid space through a lumbar puncture.

The associated temporal encephalocele is amputated or disconnected, and the dehiscent dura and middle cranial fossa floor defect is repaired and packed with autogenous tissue, respectively. The surgical treatment of cerebrospinal fluid rhinorrhea secondary to middle fossa encephalocele associated with lateral extension of the sphenoidal sinus differs from the surgical strategy for a more medial sphenoidal fistulae. A fistula involving a lateral extension of the sphenoid sinus requires a transcranial approach for direct visualization and obliteration of the defect, whereas fistulae involving the central portion of the sinus may be successfully obliterated transsphenoidally (4, 6). The fistula in our case was localized in a lateral recess of the sphenoid sinus. We therefore repaired the dural and temporal bone defect with a transcranial extradural approach.

REFERENCES

1. Abe T, Ludecke DK, Wada A, Matsumoto K: Transsphenoidal cephaloceles in adults: A report of two cases and review of the literature. *Acta Neurochir (Wien)* 142; 397-400, 2000
2. Kumar R, Jenkins A: Spontaneous CSF rhinorrhoea due to temporosphenoidal encephalocele. *Br J Neurosurg* 12; 66-68, 1998
3. Lai SY, Kennedy DW, Bolger WE: Sphenoid encephaloceles: disease management and identification of lesions within the lateral recess of the sphenoid sinus. *Laryngoscope* 112; 1800-1805, 2002
4. Landreneau FE, Mickey B, Coimbra C: Surgical treatment of cerebrospinal fluid fistulae involving lateral extension of the sphenoid sinus. *Neurosurgery* 42; 1101-1104, 1998
5. Law AJ, Lee MA, Knuckey NW: Spontaneous CSF rhinorrhea secondary to a middle cranial fossa defect. *J Clin Neurosci* 6; 411-412, 1999
6. Shetty PG, Shroff MM, Fatterpekar GM, Sahani DV, Kirtane MV: A retrospective analysis of spontaneous sphenoid sinus fistula: MR and CT findings. *AJNR Am J Neuroradiol* 21; 337-342, 2000
7. Sillers MJ, Morgan CE, el Gammal T: Magnetic resonance cisternography and thin coronal computerized tomography in the evaluation of cerebrospinal fluid rhinorrhea. *Am J Rhinol* 11; 387-392, 1997