



# The Analysis of Long-Term Follow-Up Screening in Patients with Surgically Treated Intracranial Aneurysms

## *Cerrahi Tedavi Edilmiş İntrakranial Anevrizmaların Uzun Dönem Takip Sonuçlarının Değerlendirilmesi*

Ethem GOKSU<sup>1</sup>, Emre KORKMAZ<sup>1</sup>, Mahmut AKYUZ<sup>1</sup>, Ozhan OZGUR<sup>2</sup>, Timur SINDEL<sup>2</sup>, Recai TUNCER<sup>1</sup>

<sup>1</sup>Akdeniz University, School of Medicine, Department of Neurosurgery, Antalya, Turkey

<sup>2</sup>Akdeniz University, School of Medicine, Department of Radiology, Antalya, Turkey

Presented in: 27<sup>th</sup> Scientific Congress of the Turkish Neurosurgical Society, 12-16 April 2013, Antalya, Turkey.

Corresponding Author: Ethem GOKSU / E-mail: ethemgoksu@mynet.com

### ABSTRACT

**AIM:** To understand the late anatomical results of surgically treated intracranial aneurysms (IA's) and to investigate the incidence of recurrent, de novo aneurysms, the natural history of residual aneurysms, and the morphological changes in temporarily clipped vascular segments.

**MATERIAL and METHODS:** A total of 117 patients underwent screening with digital subtraction angiography (DSA) or computed tomographic angiography (CTA) in a range of 3 – 13 years. Late angiographies were evaluated in terms of recurrence, change in known residua, the presence of de novo aneurysms and the morphological changes in temporarily clipped vessels. We also analysed the cumulative data including previously published results.

**RESULTS:** In the long-term DSA, three residual aneurysms were observed to be enlarged while four remnants showed no morphological change. In one patient, spontaneous obliteration was seen. No recurrent aneurysm was detected. One de novo aneurysm was observed. We did not find any morphological change in 71 temporarily clipped vascular segments.

**CONCLUSION:** Our data demonstrates that completely occluded aneurysms could remain stable even years later. Most of the small neck residues appeared to remain unchanged or even be thrombosed but they should be carefully followed. The incidence of de novo aneurysms might be expected to be lower.

**KEYWORDS:** Long-term follow-up screening, Recurrent aneurysm, Residual aneurysm, De novo aneurysm

### ÖZ

**AMAÇ:** Cerrahi olarak tedavi edilmiş intrakranial anevrizmaların (İA) geç dönem anatomik sonuçlarını ortaya koymak ayrıca rekürren, de novo anevrizma sıklığını, rezidüel anevrizmaların doğal seyrini ve geçici klip uygulanmış damar segmentlerindeki morfolojik değişiklikleri araştırmak.

**YÖNTEM ve GEREÇLER:** 117 hasta 3-13. yıllar arası, dijital subtraksiyon anjiyografisi (DSA) ya da bilgisayarlı tomografik anjiyografi (BTA) ile incelendi. Geç dönem anjiyografik veriler, rekürrens, bilinen rezidüdeki değişim, de novo anevrizma gelişimi ve geçici kliplene yapılmış damar segmentlerindeki morfolojik değişiklikler açısından değerlendirildi. Bunlar dışında daha önceki yayımlanmış sonuçlarla birlikte tüm veriler analiz edildi.

**BULGULAR:** Uzun dönem anjiyografide üç rezidüel anevrizma genişlemiş izlenirken, 4 tanesinde morfolojik değişim görülmedi. Bir hastada spontan kapanma tespit edildi. Hiçbir olguda rekürren anevrizma izlenmedi. Bir hastada de novo anevrizma bulundu. Geçici kliplene yapılmış 71 damar segmentinde herhangi bir morfolojik değişiklik görülmedi.

**SONUÇ:** Sonuçlarımız göstermektedir ki; tam kapatılmış anevrizmalar yıllarca stabil kalabilmektedir. Çoğu küçük boyun rezidüsünde değişiklik olmadığı hatta kapanabildiği görülmekle birlikte anjiyografik takibi önerilmektedir. Bundan dolayı de novo anevrizma sıklığı daha düşük beklenebilir.

**ANAHTAR SÖZCÜKLER:** Uzun dönem takip taraması, Rekürren anevrizma, Rezidüel anevrizma, De novo anevrizma

### INTRODUCTION

The goal in the management of intracranial aneurysms (IA's) is to obtain safe, complete, and durable obliteration of the aneurysm. Open microsurgery or endovascular procedures have been applied to achieve the optimum results for many

years. Prospective, randomised studies have been conducted to compare the efficacy of treatment modalities in terms of clinical outcome and durability of occlusion (3, 18, 20-22). Late anatomic results of the occluded aneurysms by microsurgery or endovascular procedures might be possible with the follow-

up screening. In addition, a late postprocedure angiography in patients with IA's may demonstrate the incidence of recurrent aneurysms, the fate of residual aneurysms, and incidence of de novo aneurysm formation. We previously published the late angiographic results of 166 aneurysms in 136 patients who had been operated on between 1993 and 1998 (2). In this study, we present the findings of long-term follow-up screening in patients with surgically treated IA's between 1998 and 2006, and also analysed the cumulative data of the previous and current series.

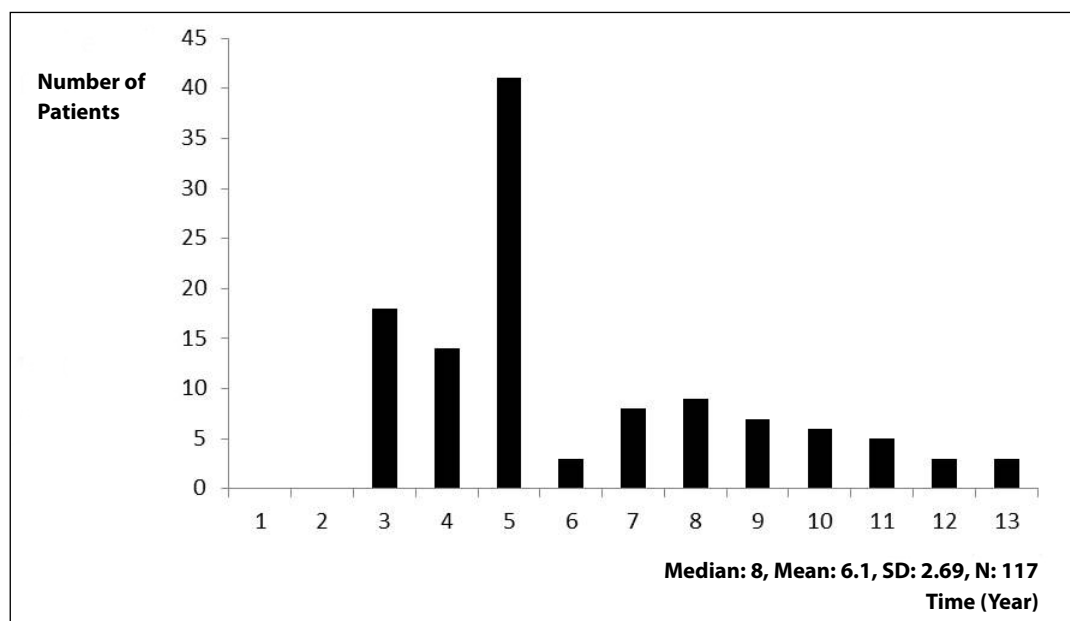
### MATERIAL and METHODS

Between 1998 and 2006, 486 patients had been operated due to IA's. With the exclusion of patients who were lost, not in a suitable condition for the procedure, or who refused the late angiographic study, 117/486 patients could be obtained for follow-up imaging. All patients were operated by the senior author (RT) with standard pterional craniotomy in an elective timing. Digital Subtraction Angiography (DSA) or spiral three-dimensional computed tomographic angiography (3D-CTA) were used as the follow-up procedures. DSA was performed via the femoral route with selective catheterisation of the carotid and vertebral arteries. 3D-CTA was conducted by a multi-helical system (Siemens Somatom Emotion) with a reconstruction index of 512 matrix and one second. In all patients, a complete four vessel DSA was performed in preoperative and early postoperative period. The patients were also informed about the planning of long-term angiographic controls at least three years after surgery. The preoperative neurological condition, and the location, number and size of aneurysms in preoperative angiograms were recorded. In the postoperative early angiography, major vessel occlusions, slipped clips, missed aneurysms and the presence of residual aneurysms were investigated. Late angiographic data were evaluated in terms of recurrence,

change in known residua, the presence of de novo aneurysms and the morphological changes in temporarily clipped vascular segments. Aneurysmal remnants were assessed using the Sindou classification (29). This study protocol was approved by the local Ethics Committee at the Akdeniz University School of Medicine (B.30.2.AKD.0.20.05.05/105).

### RESULTS

A total of 117 cases obtained from a consecutive series of 486 patients surgically treated for IA's were studied. There were 62 females and 55 males (mean age 46 years, range 18-73 years). Long-term follow-up angiograms were performed in a range of 3-13 years (median 8, mean;  $6.1 \pm 2.69$  years) (Figure 1). 99 patients underwent DSA while there remained 18 patients who refused conventional angiography, 3D-CTA was used as a follow-up procedure. 143 aneurysms determined in 117 patients were located at the anterior cerebral artery (ACA) in 58 patients (40%), middle cerebral artery (MCA) in 50 patients (35%), and the internal carotid artery (ICA) in 35 patients (25%). The distribution of aneurysms according to their locations and sizes is presented in Table I. 108 patients presented with subarachnoid hemorrhage (SAH) and further in nine patients, aneurysms were found incidentally. Surgical techniques included microsurgical clipping in 138 patients (96.5%), wrapping in three (2.1%), coagulation in one (0.6%) and parent vessel occlusion in another case (0.6%). On early postoperative angiograms, we determined eight aneurysmal remnants. According to the Sindou classification, four remnants were grade 1 (two aneurysms were situated on the anterior communicating artery; AComA, two others on MCA), four remnants were grade 2 (two aneurysms were located on ICA, one on AComA, and one on posterior communicating artery; PComA). In the long-term DSA, three residual aneurysms were observed to be enlarged while four remnants showed no morphological change. In one patient with grade



**Figure 1:** The distribution of patients according to the time interval between surgery and long-term angiogram.

1 residue, spontaneous obliteration was detected. Table II demonstrates the locations and grades of eight residual aneurysms on early and long-term angiographic study. No recurrent aneurysm was detected. One de novo ICA aneurysm was determined in a patient in whom an AComA aneurysm was previously clipped. We did not find any morphological change in 71 temporarily clipped vascular segments. Table III summarised the cumulative follow-up data of all the patients in the previous and current series.

## DISCUSSION

Aneurysmal SAH is a rather catastrophic event resulting in more than 50% mortality and 25% of survivors also require lifetime care (28). Besides undesirable outcomes following the first attack, the mortality rate among patients with good recovery at one year was found to be twice that of the general population (26). Recurrent, de novo aneurysms and enlargement of untreated aneurysms might be responsible

**Table I:** The Distribution of Aneurysms according to their Locations and Sizes

Aneurysm Location	Distribution of Aneurysms by Size			Total
	< 11 mm	11–25 mm	> 25 mm	
ACA	55	3	-	58
MCA	44	5	1	50
ICA	34	1	-	35
Total	133	9	1	143

**ACA;** Anterior Cerebral Artery, **MCA;** Middle Cerebral Artery, **ICA;** Internal Carotid Artery.

**Table II:** The Locations and Grades of Eight Residual Aneurysms on Early and Long-Term Angiographic Study

Patient no	Location of Residual Aneurysm	Residual Aneurysm Grade (Sindou)	Long-term Follow-up Angiography (Year)	Morphological Change
1	ICA	2	4	-
2	PCoMA	2	7	Enlarged (grade 3)
3	AComA	1	5	Enlarged (grade 2)
4	ICA	2	12	-
5	MCA	1	3	-
6	AComA	1	10	Enlarged (grade 2)
7	AComA	2	6	-
8	MCA	1	8	Spontaneous thrombosis

**ICA;** Internal Carotid Artery, **PCoMA;** Posterior Communicating Artery, **AComA;** Anterior Communicating Artery, **MCA;** Middle Cerebral Artery.

**Table III:** The Cumulative Follow-Up Data of All the Patients in Previous and Current Series

Criteria	Previous Series (1993–1998)			Current Series (1998–2006)			Total
	Enlarged	Unchanged	Spontaneous Thrombosis	Enlarged	Unchanged	Spontaneous Thrombosis	
Number of Patients Surgically Treated for IA	217			486			703
Number of Patients in whom Long-term Angiograms obtained	136			117			253
Morphological Changes in Aneurysmal Residues on Long-term Angiography	1	5	1	3	4	1	15
De novo aneurysms	2			1			3
Recurrent Aneurysm	-			-			-
Temporary Clipped Vascular Segments/ Morphological Change	137/No Morphological Change			71/No Morphological Change			208

**IA;** Intracranial Aneurysm.

for future bleedings in patients with a previous SAH. In a large cohort of patients, the incidence of recurrent SAH after clipping for ruptured IA's was reported as 3.2% in a mean follow-up of eight years (35). Therefore, aneurysmal SAH patients should be carefully followed in their lifetimes to prevent the risk factors and potential complications.

Routine use of early and long-term postoperative angiography is needed to determine the real incidence of residual, recurrent, and de novo aneurysms after clipping for IA's. Aneurysmal remnants can be expected at a rate of 3.8% to 21%, even after surgery by experienced surgeons (1, 6, 14, 16, 17, 29). Mostly, a part of the base could be left intentionally because of wall morphology or to prevent any branch occlusion. In addition, ruptured, broad-based, posterior circulation and large/giant aneurysms were reported to be more prone to incomplete closure (6, 14). Many of the small neck residues are known to remain stable and even be thrombosed. Nevertheless, a small number have been noted to enlarge and rupture with an annual risk of 0.5% (6). In our follow-up series, four of 15 residual aneurysms (27%) were observed to be enlarged while nine remnants (60%) remained unchanged. In two patients (13%) with grade 1 residue, spontaneous obliteration was detected. No recurrent bleeding occurred in our cases. Except two cases in the previous series, all aneurysms were located on the anterior circulation. In addition, most of them were small and did not have complex morphology. Because of these reasons, the incidence of remnants appeared to be lower than the given results in the literature.

The risk of aneurysm recurrence after complete clipping was assumed to be close to zero. However, David et al. reported the frequency of aneurysm recurrence after complete clipping as 0.5% per year (6). In another study by Tsutsumi et al., cumulative risk of recurrence was found as 10% at nine years (32). Difficulty to detect the small remnants on postoperative angiograms, presence of unhealthy neighbouring vessel structure, fragility of the vascular wall along the clip edge and effect of hemodynamic stress could explain the regrowth of the aneurysm (6, 10). In our cumulative series, of the 253 clipped aneurysms, 238 (94%) were clipped without evidence of residua on postoperative angiography. Late follow-up angiography demonstrated a slipped clip in one patient and two spontaneous obliterations in two cases with grade 1 residue. No recurrent aneurysm was detected. Our data

revealed the long-term efficacy of clip ligation with a 95% permanent obliteration rate.

The patients who have a SAH from a ruptured IA have an ongoing risk of developing new aneurysms. In previous studies, the incidence of de novo aneurysms has been reported as between 0.8 and 2.3% per year (6, 12, 32, 36, 13, 15, 37). The careful evaluation of preoperative and early postoperative angiograms is essential to determine the incidence of de novo aneurysms. Van der Schaff et al. stated that only one third of new detected aneurysms on follow-up screening were de novo and the other two thirds were missed at the time of initial hemorrhage (34). We determined three de novo aneurysms with a cumulative rate of 1.2% in our 253 patients. In the literature, there are not many comprehensive studies examining the early and late angiographic results of surgically treated aneurysms. The summary of three follow-up series including our study is presented in Table IV.

Of the four aneurysms that were not appropriate for clip application, wrapping was performed in three and coagulation in one subject. There was no recurrent bleeding in these cases. On the follow-up screening, none of the wrapped aneurysms displayed any morphological change and no refilling was detected in the coagulated aneurysm. Deshmukh et al. presented the largest series including long-term results of unclippable wrapped aneurysms (8). During the follow-up period, one patient experienced SAH and no aneurysm changed in size or configuration.

In our cumulative series, 208 temporarily clipped vascular segments were evaluated in terms of irregularity, dilatation, stenosis or occlusion in early and late angiographic views. We did not find any morphological change in these vascular segments. Except one study by Charbel et al. in which thrombosis was determined in two temporary clip applied vascular segments on postoperative angiography, there is no indicative data of angiographic observations in the literature (4).

Since the metallic clip artifacts can lead to limitations in the assessment of aneurysmal residues, noninvasive imaging techniques have not reached the accuracy of DSA (7, 9, 24, 31, 33). Therefore, DSA is still the gold standard follow-up procedure in cases with clipped aneurysms. However, CTA has continued to improve with recent technology, newly

**Table IV:** The Summary of Three Follow-Up Series Including Ours

Author, Year	Number of Patients /Aneurysms on Follow-up Screening	Mean Follow-up Time (Year)	Recurrent Aneurysms (%)	Growth of Residual Aneurysms (%)	De Novo Aneurysms (%)
David et al., 1999	102/167	4.4	2 (1.5%)	5/12 (42%)	8 (6%)
Tsutsumi et al., 2001	112/140	9.3	3 (2.4%)	1/14 (7.1%)	9 (8%)
Goksu et al., 2013 (current study)	253/309	5.1	-	4/15 (27%)	3 (1.2%)

designed protocols and postprocessing algorithms (11). In our current series, 3D-CTA was used as a diagnostic tool in 18 patients who refused conventional angiography. No recurrent or de novo aneurysms were detected on follow-up screening by 3D-CTA. Images were found to be satisfying in relation to the clip configuration and parent vessel. Indocyanine green video angiography (ICG-VA) has recently been popularised in intraoperative evaluation of vessel patency and aneurysm obliteration. The use of this simple and safe technique has gradually been increased in cerebrovascular surgery to replace the postoperative angiography (5, 23, 30).

The importance of the postoperative follow-up angiography was better understood when an alternative method gained a role in the treatment of IA's. Endovascular coil embolisation of ruptured IA's has been widely accepted since 2002 with the results of the ISAT (International Subarachnoid Aneurysm Trial). The aim of the trial was to compare the safety and efficacy of endovascular procedure with microsurgical clipping in patients with IA's. In the first report, the risk of further bleeding at one year from the treated aneurysm was found to be more frequent with endovascular method than microsurgery (20). Therefore, the investigators emphasized the necessity of annual angiographic follow-up to evaluate the risk of late rebleeding. In the second report of ISAT, complete angiographic occlusion rates were presented as 66% in the endovascular treatment group and 82% in the microsurgical clipping group one year after treatment (21). The third report demonstrated the higher frequency of late retreatment rates among endovascular treatment patients. The importance of late angiographic follow-up to detect aneurysm recurrence was also emphasized in this report (3). The follow-up results for a mean of nine years were published in 2009 (22). This final report demonstrated the increased risk of rebleeding from a coiled aneurysm compared with a clipped aneurysm although the number of recurrent bleeding episodes was very small in both treatment groups. At the conclusion of the ISAT, coil embolisation appeared to be more advantageous than clip ligation regarding death and severe disability at one year, and clip occlusion had better long-term efficacy in order to prevent recurrent bleeding and to result a better long-term outcome especially in patients younger than 40 years of age (19). Recently, The Barrow Ruptured Aneurysm Trial (BRAT) reported the initial results (18). According to this trial, endovascular treatment resulted in fewer poor clinical outcomes after one year of follow-up but a substantial number of aneurysms assigned to the coil treatment crossed over to surgical clipping with the reasons of surgery required hematoma or anatomical features. It was also emphasized that a single treatment modality could not be available for all the aneurysms. Recent innovations in endovascular techniques are still continuing to offer new treatment alternatives for IA's. Long-term follow-up results of flow-diverting devices demonstrated a successful occlusion rates with low morbidity and mortality rates (25, 27). Today, the management of IA's necessitates a multidisciplinary team

approach. Every subject should be evaluated according to the clinical condition, aneurysm location and morphology.

In conclusion, our comprehensive series demonstrates that clip ligation is highly sufficient to achieve a permanent occlusion, and completely occluded aneurysms remain stable even years later. The real incidence of de novo aneurysms might be expected to be lower than supposed. Most of the small neck residues appear to remain unchanged or even be thrombosed. Follow-up screening should particularly be recommended to patients with incompletely occluded aneurysms.

## REFERENCES

1. Akyuz M, Cetin A, Boztug N, Kazan S, Tuncer R: Effects of the temporary clipping in aneurysm surgery on the remnant. *Acta Neurochir (Wien)* 144:129-136, 2002
2. Akyuz M, Tuncer R, Yilmaz S, Sindel T: Angiographic follow-up after surgical treatment of intracranial aneurysms. *Acta Neurochir (Wien)* 146(3):245-250, 2004
3. Campi A, Ramzi N, Molyneux AJ, Summers PE, Kerr RS, Sneade M, et al: Retreatment of ruptured cerebral aneurysms in patients randomized by coiling or clipping in the International Subarachnoid Aneurysm Trial (ISAT). *Stroke* 38(5):1538-1544, 2007
4. Charbel FT, Ausman JI, Diaz FG, Malik GM, Dujovny M, Sanders J: Temporary clipping in aneurysm surgery: Technique and results. *Surg Neurol* 36:83-90, 1991
5. Dashti R, Laakso A, Niemelä M, Porras M, Hernesniemi J: Microscope integrated indocyanine green video-angiography in cerebrovascular surgery. *Acta Neurochir Suppl* 109:247-250, 2011
6. David CA, Vshteh AG, Spetzler RF, Lemole M, Lawton MT, Partowi S: Late angiographic follow-up review of surgically treated aneurysms. *J Neurosurg* 91:396-401, 1999
7. Dehdashti AR, Binaghi S, Uske A, Regli L: Comparison of multislice computerized tomography angiography and digital subtraction angiography in the postoperative evaluation of patients with clipped aneurysms. *J Neurosurg* 104:395-403, 2006
8. Deshmukh VR, Kakarla UK, Figueiredo EG, Zabramski JM, Spetzler RF: Long-term clinical and angiographic follow-up of unclippable wrapped intracranial aneurysms. *Neurosurgery* 58(3):434-442, 2006
9. Fahrendorf DM, Goericke SL, Oezkan N, Breyer T, Hussain S, Sandalcioğlu EI, et al: The value of dual-energy CTA for control of surgically clipped aneurysms. *Eur Radiol* 21:2193-2201, 2011
10. Feuerberg I, Lindquist C, Lindquist M, Steiner L: Natural history of postoperative aneurysm rests. *J Neurosurg* 66: 30-34, 1987
11. Göllitz P, Struffert T, Ganslandt O, Saake M, Lücking H, Rösch J, et al: Optimized angiographic computed tomography with intravenous contrast injection: An alternative to conventional angiography in the follow-up of clipped aneurysms? *J Neurosurg* 117(1):29-36, 2012



12. Juvela S, Porras M, Heiskanen O: Natural history of unruptured intracranial aneurysms: A long-term follow-up study. *J Neurosurg* 79:174–182, 1993
13. Kemp WJ 3rd, Fulkerson DH, Payner TD, Leipzig TJ, Horner TG, Palmer EL, et al: Risk of hemorrhage from de novo cerebral aneurysms. *J Neurosurg* 118(1):58–62, 2013
14. Kivisaari RP, Porras M, Ohman J, Siironen J, Ishii K, Hernesniemi J: Routine cerebral angiography after surgery for saccular aneurysms: Is it worth it? *Neurosurgery* 55:1015–1024, 2004
15. Koroknay-Pál P, Niemelä M, Lehto H, Kivisaari R, Numminen J, Laakso A, et al: De novo and recurrent aneurysms in pediatric patients with cerebral aneurysms. *Stroke* 44(5):1436–1439, 2013
16. Le Roux PD, Elliot JP, Eskridge JM, Cohen W, Winn HR: Risks and benefits of diagnostic angiography after aneurysm surgery: A retrospective analysis of 597 studies. *Neurosurgery* 42:1248–1255, 1998
17. McDonald RL, Wallace MC, Kestle JRW: Role of angiography following aneurysm surgery. *J Neurosurg* 79:826–832, 1993
18. McDougall CG, Spetzler RF, Zabramski JM, Partovi S, Hills NK, Nakaji P, et al: The barrow ruptured aneurysm trial. *J Neurosurg* 116(1):135–144, 2012
19. Mitchell P, Kerr R, Mendelow AD, Molyneux A: Could late rebleeding overturn the superiority of cranial aneurysm coil embolization over clip ligation seen in the International Subarachnoid Aneurysm Trial? *J Neurosurg* 108(3):437–442, 2008
20. Molyneux A, Kerr R, Stratton I, Sandercock P, Clarke M, Shrimpton J, et al: International Subarachnoid Aneurysm Trial (ISAT) of neurosurgical clipping versus endovascular coiling in 2143 patients with ruptured intracranial aneurysms: A randomised trial. *Lancet* 360(9342):1267–1274, 2002
21. Molyneux AJ, Kerr RS, Yu LM, Clarke M, Sneade M, Yarnold JA, et al: International subarachnoid aneurysm trial (ISAT) of neurosurgical clipping versus endovascular coiling in 2143 patients with ruptured intracranial aneurysms: A randomised comparison of effects on survival, dependency, seizures, rebleeding, subgroups, and aneurysm occlusion. *Lancet* 366(9488):809–817, 2005
22. Molyneux AJ, Kerr RS, Birks J, Ramzi N, Yarnold J, Sneade M, et al: ISAT Collaborators. Risk of recurrent subarachnoid haemorrhage, death, or dependence and standardised mortality ratios after clipping or coiling of an intracranial aneurysm in the International Subarachnoid Aneurysm Trial (ISAT): Long-term follow-up. *Lancet Neurol* 8(5):427–433, 2009
23. Ozgiray E, Aktüre E, Patel N, Baggott C, Bozkurt M, Niemann D, et al: How reliable and accurate is indocyanine green video angiography in the evaluation of aneurysm obliteration? *Clin Neurol Neurosurg* 115(7):870–878, 2013
24. Pechlivanis I, Koenen D, Engelhardt M, Scholz M, Koenig M, Heuser L, et al: Computed tomographic angiography in the evaluation of clip placement for intracranial aneurysm. *Acta Neurochir (Wien)* 150:669–676, 2008
25. Piano M, Valvassori L, Quilici L, Pero G, Boccardi E: Midterm and long-term follow-up of cerebral aneurysms treated with flow diverter devices: A single-center experience. *J Neurosurg* 118(2):408–416, 2013
26. Ronkainen A, Niskanen M, Rinne J, Koivisto T, Hernesniemi J, Vapalahti M: Evidence for excess mortality after treated subarachnoid haemorrhage. *Stroke* 32:2850–2853, 2001
27. Saatci I, Yavuz K, Ozer C, Geyik S, Cekirge HS: Treatment of intracranial aneurysms using the pipeline flow-diverter embolization device: A single-center experience with long-term follow-up results. *AJNR Am J Neuroradiol* 33(8):1436–1446, 2012
28. Schievink WI, Schaid DJ, Michels VV, Piepgras DG: Familial aneurysmal subarachnoid hemorrhage: A community-based study. *J Neurosurg* 83:426–429, 1995
29. Sindou M, Acevedo JC, Turjman F: Aneurysmal remnants after microsurgical clipping: Classification and results from a prospective angiographic study (in a consecutive series of 305 operated intracranial aneurysms). *Acta Neurochir (Wien)* 140:1153–1159, 1998
30. Snyder LA, Spetzler RF: Current indications for indocyanine green angiography. *World Neurosurg* 76(5):405–406, 2011
31. Thines L, Dehdashti AR, Howard P, Da Costa L, Wallace MC, Willinsky RA, et al: Postoperative assessment of clipped aneurysms with 64-slice computerized tomography angiography. *Neurosurgery* 67:844–854, 2010
32. Tsutsumi K, Ueki K, Morita A, Usui M, Kirino T: Risk of aneurysm recurrence in patients with clipped cerebral aneurysms: Results of long-term follow-up angiography. *Stroke* 32(5):1191–1194, 2001
33. Uysal E, Ozel A, Erturk SM, Kirdar O, Basak M: Comparison of multislice computed tomography angiography and digital subtraction angiography in the detection of residual or recurrent aneurysm after surgical clipping with titanium clips. *Acta Neurochir (Wien)* 151:131–135, 2009
34. van der Schaaf IC, Velthuis BK, Wermer MJ, Majoie C, Witkamp T, de Kort G, et al: ASTRA Study Group. New detected aneurysms on follow-up screening in patients with previously clipped intracranial aneurysms: Comparison with DSA or CTA at the time of SAH. *Stroke* 36(8):1753–1758, 2005
35. Wermer MJ, Greebe P, Algra A, Rinkel G: Incidence of recurrent subarachnoid haemorrhage after clipping for ruptured intracranial aneurysms. *Stroke* 36:2394–2399, 2005
36. Wermer MJ, van der Schaaf IC, Velthuis BK, Algra A, Buskens E, Rinkel GJ: ASTRA Study Group. Follow-up screening after subarachnoid haemorrhage: Frequency and determinants of new aneurysms and enlargement of existing aneurysms. *Brain* 128:2421–2429, 2005
37. Zali A, Khoshnood RJ, Zarghi A: De novo aneurysms in long-term follow-up computed tomographic angiography of patients with clipped intracranial aneurysms. *World Neurosurg* 82(5):722–725, 2014