



# Intraoperative Neurophysiological Evidence of Hydrogen Peroxide-Induced Stroke in Insular Tumor Surgery

## *İnsüla Tümörü Cerrahisinde Hidrojen Peroksitle İndüklenen İnmenin İntraoperatif Nörofizyolojik Bulguları*

Alba LEÓN JORBA<sup>1</sup>, Miguel LÓPEZ CUIÑA<sup>1</sup>, Alessandro PRINCIPE<sup>1</sup>, Gloria VILLALBA MARTÍNEZ<sup>2</sup>

<sup>1</sup>Parc de Salut Mar, Department of Neurology, Barcelona, Spain

<sup>2</sup>Parc de Salut Mar, Department of Neurosurgery, Barcelona, Spain

**Presented in:** XVI Congress of the Societat Catalana de Neurologia. Vic. March 15-16 2012 and II Congress of the Sociedad Española de Monitorización Intraoperatoria. Tenerife. April 27-28 2012

**Corresponding Author:** Alba Leon JORBA / E-mail: 99449@parcdesalutmar.cat

### ABSTRACT

Hydrogen peroxide (H<sub>2</sub>O<sub>2</sub>) is commonly used as a haemostatic agent in all type of surgeries. Some adverse effects have been described related to its use. However, only very few cases are published in the literature of a stroke associated with the application of this agent directly to the brain. We present the case of a patient operated on for a right insular tumor with the assistance of intraoperative neurophysiological monitoring who developed a postoperative severe hemiparesis caused by a stroke in left middle cerebral artery territory due to the irrigation with H<sub>2</sub>O<sub>2</sub>. Based on this case, we recommend avoiding the H<sub>2</sub>O<sub>2</sub> irrigation for hemostasis in surgery for brain tumors when vascular structures are exposed.

**KEYWORDS:** Brain tumors, Hemostasis, Hydrogen peroxide, Intraoperative neurophysiological monitoring, Stroke

### ÖZ

Hidrojen peroksit (H<sub>2</sub>O<sub>2</sub>) tüm cerrahi tiplerinde bir hemostatik ajan olarak kullanılır. Kullanımıyla ilişkili bazı yan etkiler tanımlanmıştır. Ancak literatürde bu ajanın doğrudan beyine uygulanmasıyla ilişkili inmenin bulunduğu sadece birkaç olgu mevcuttur. İntraoperatif nörofizyolojik monitörizasyon eşliğinde sağ insüla tümörü için ameliyat edilen bir olguda H<sub>2</sub>O<sub>2</sub> ile irrigasyon nedeniyle sol middle serebral arter sulama bölgesinde inme sonucunda postoperatif şiddetli hemiparezi gelişmesini sunuyoruz. Bu olgu temelinde beyin tümörleri için cerrahi sırasında vasküler yapılar ortaya konulduğunda hemostaz için H<sub>2</sub>O<sub>2</sub> irrigasyonunun kullanılmasından kaçınmayı öneriyoruz.

**ANAHTAR SÖZCÜKLER:** Beyin tümörleri, Hemostaz, Hidrojen peroksit, İntraoperatif nörofizyolojik izleme, İnme

### INTRODUCTION

Hydrogen peroxide (H<sub>2</sub>O<sub>2</sub>) is widely used as a haemostatic agent in neurosurgery. Although its mechanism of action is unknown, several hypotheses have been proposed, among which are vasoconstriction, platelet aggregation, thrombus formation and small blood vessel occlusion due to micro bubbles (4, 5). Although complications have been reported (3, 8), there are only few descriptions of a stroke after brain irrigation with H<sub>2</sub>O<sub>2</sub>. Despite those reports, H<sub>2</sub>O<sub>2</sub> usage has not decreased among neurosurgeons.

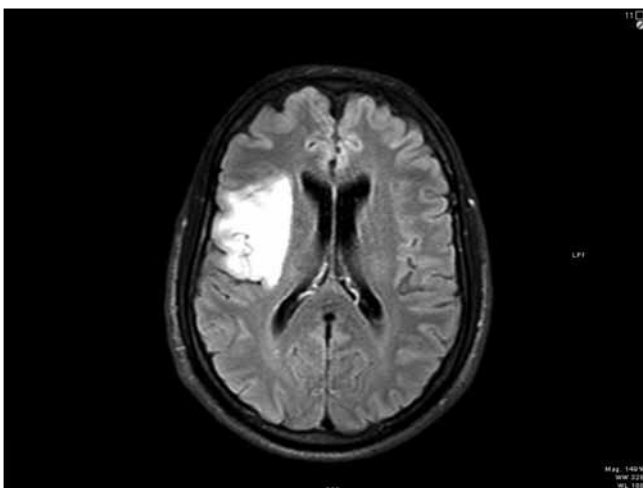
Insular tumor surgery has been debated for years, due to its unfavorable anatomical conditions that imply a high risk of neurological impairment. However, several reports show that lesions localized in the insula can be resected with acceptable complication rates and outcomes (2, 14).

The main cause of a motor deficit after insular tumor surgery is ischemia caused by the occlusion of the lenticulostriate perforating arteries (7). Damage to corticospinal tract may ensue anytime during the resection and even after the end of the anesthesia (13). For these kind of lesions, intraoperative neurophysiological monitoring (INM) is a valid method of detecting and preventing potential neurological deficits, thus maximizing the extent of the resection and allowing a better outcome (9).

We describe the case of a patient with a right insular low-grade glioma operated with the assistance of INM. The subject developed postoperative hemiplegia caused by an occlusion of left middle cerebral artery (MCA) perforators after the irrigation with H<sub>2</sub>O<sub>2</sub>.

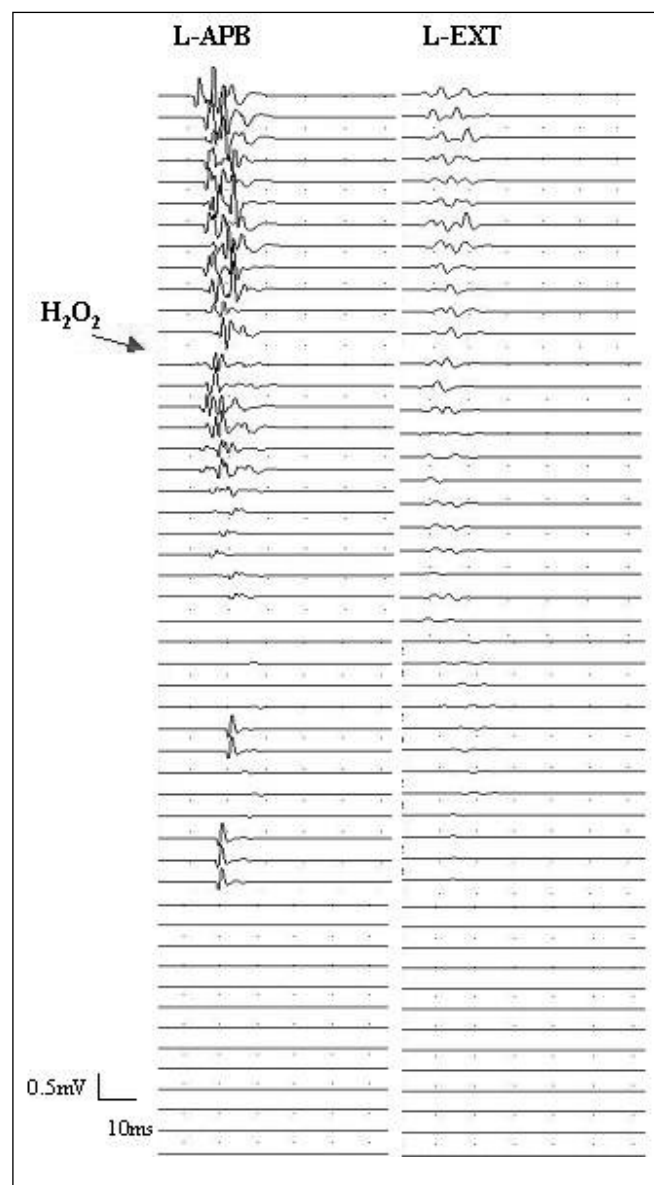
## CASE REPORT

A 51-year-old man presented with simple partial seizures. On admission, the patient's neurological examination was unremarkable. Magnetic resonance imaging (MRI) showed a right insular tumor graded 3B in the Yasargil Classification consistent with a low-grade glioma (Figure 1). A right fronto-temporal craniotomy was performed under total intravenous anesthesia. Bilateral somatosensory evoked potentials (SEPs) after posterior tibial nerve and median nerve stimulation, and motor evoked potentials (MEPs) after transcranial electrical stimulation (MEPtc) were performed throughout the surgery. Pairs of subcutaneous needles were inserted in the abductor pollicis brevis (APB), extensor comunis, tibialis anterior and abductor hallucis longus (AHL) bilaterally for muscle recordings. After opening the dura, a 6x1 grid electrode was placed over the cortex and continuous direct motor cortical stimulation was performed. Dissection of the sylvian fissure (trans-sylvian approach) was used to achieve middle cerebral artery exposure, then its M1 and M2 segments and the perforators were dissected from the tumor. The tumor was removed by utilizing an ultrasonic aspirator. Tumoral frontal and temporal opercula were subpially removed. A monopolar stimulator was used for continuous subcortical mapping. The resection was stopped when a threshold of 6 mA was found for the MEPs of the left upper extremity. During tumor resection, only mild transient changes in MEPs were observed allowing the continuation of the intervention until the resection was apparently complete. Minor bleeding of the deep surgical field was managed with haemostatic fibrin (surgicel®) (Ethicon, Johnson and Johnson). Finally, a piece of cotton irrigated with 2% H<sub>2</sub>O<sub>2</sub> solution was left in the surgical bed. A few seconds later, the left MEPs from upper and lower extremities and the left median SEPs progressively abated. Although the cotton was removed and blood pressure increased, irrigation with saline and local infusion of papaverine was done, the



**Figure 1:** Axial fluid-attenuated inversion recovery (FLAIR) image showing the lesion located in the right insula, frontal and temporal opercula consistent with a low-grade glioma.

recordings did not change. The dura closure was watertight, and the bone flap was fixed with craneofix® (Aesculap). At closing, there was a very poor response in the left AHL and still no response in the left upper extremity (Figure 2). The patient woke up with a complete right hemispheric syndrome, including apraxia of eyelid opening, right oculocephalic deviation, left homonymous hemianopsia, left hemiplegia, left anesthesia and anosognosia. A postoperative MRI (24 hours after surgery) showed a complete tumor resection and an acute stroke in superficial and deep regions of the MCA (Figure 3, 4). A decrease in collateral vascularization with



**Figure 2:** Motor evoked potentials (MEPs) recorded in abductor pollicis brevis (L-APB) and extensor digitorum comunis (L-EXT) after direct cortical stimulation with an intensity of 13 mA. The arrow indicates the placement of the cotton with H<sub>2</sub>O<sub>2</sub>. Immediately after, a severe and progressive decrease of amplitude of MEPs is observed.

permeability of M1 and M2 segments of MCA was noted with magnetic resonance angiography (MRA). Six months later the patient was not able to walk on his own and had monoplegia of the upper left extremity. Only twelve months after the event we observed an improvement of the impairment, with mild paresis of the leg that allowed the subject to ambulate independently.

### DISCUSSION

Insular tumor surgery is very complex due to its vascular relationship. The goal of this type of surgery is not only the largest resection possible for oncological control, but also the best tailored one for preserving the functionality and avoiding catastrophic neurological impairments. Sanaï

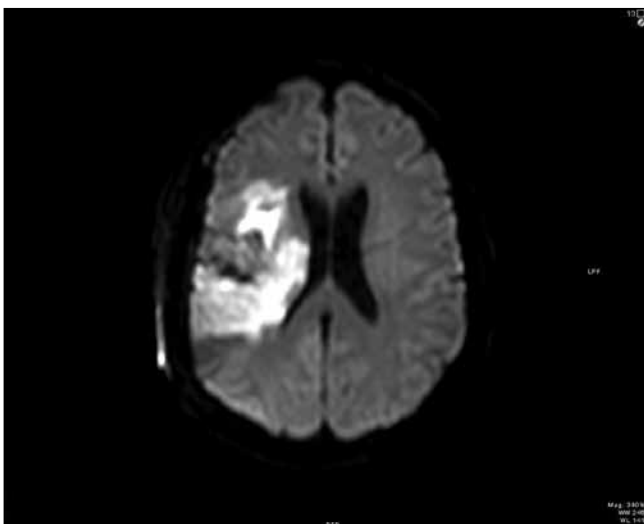
and colleagues analyzed patients with low and high-grade gliomas and found that those resected over 90% had a 5-year survival rate of 100%, whereas those with lesions resected less than 90% had a 5-year survival rate of 84%. The same significant difference was found for patients with high-grade gliomas (10). They concluded that the extent of resection was a significant predictor of overall survival after surgery of insular low and high-grade glioma.

One of the main risks of insular surgery is vascular injury. The resection of the most medial part of the insula may result in damage to perforating vessels and subcortical ischemia. Damage of long perforating vessels supplying the corona radiata and the internal capsule causes postoperative motor deficits (7, 15). Despite this, retrospective data and also some prospective analyses support the feasibility of resections of insular low-grade gliomas by experienced surgeons. The potential benefits of a tumor resection need to be balanced against the risk of incurring a new postoperative deficit (10, 11).

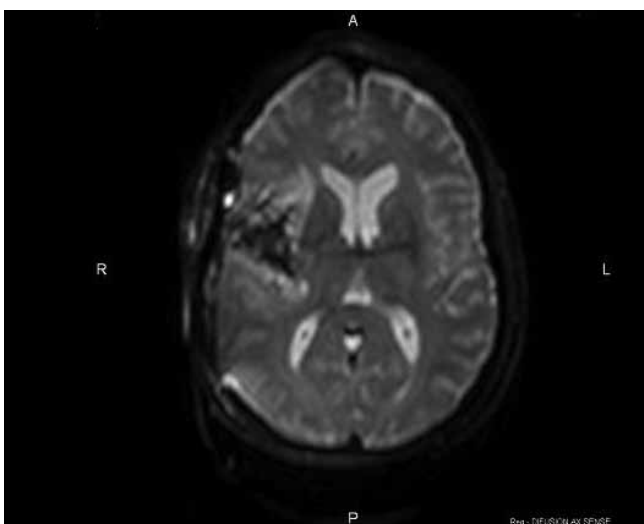
In the neurosurgical field,  $H_2O_2$  is mainly used as a haemostatic agent, although some complications have been described in relation to its use. Some adverse effects as air-embolism, pneumoencephalus and trigeminal cardiac reflex have been reported (1, 4, 8, 12). Mut and colleagues reported a case with a  $H_2O_2$ -induced stroke. They observed multiple bubbles within the lumen of the vessels after the exposure to  $H_2O_2$  in a patient. Later, they performed an animal experimental study and found signs of both local and deep diffusion of  $H_2O_2$  through brain parenchyma that ensued in gas embolism, vasoconstriction, platelet aggregation and vascular occlusion (5). There are very few cases of stroke described after the application of  $H_2O_2$  to the brain parenchyma and the agent is still used for hemostasis in many centers.

In our case, the most probable cause of ischemic damage was the summation of local mechanisms on the site of  $H_2O_2$  application that lead to superficial parenchyma infarction, and distal mechanisms owing to diffusion of  $H_2O_2$ , affecting deep perforating vessels and other small caliber arteries in a similar manner, while large caliber MCA was un-affected. This sequence could explain the postoperative stroke in our patient and also the significant changes in MEPs and SEPs observed only a few seconds after irrigation with  $H_2O_2$ , while no major changes were detected after the complete resection of the tumor, or during the coagulation, excluding another possible mechanism of stroke. Moreover, the MRA showed a decrease in collateral vascularization from M1 and M2 segments, while the MCA caliber was unaltered, thus suggesting that the infarct was due to occlusion of small caliber arteries.

MEPs loss in supratentorial surgery is related to a postoperative motor deficit (13) and indicates a motor cortical or subcortical lesion, while SEP changes are very sensitive for detecting cortical perfusion disorders. In our case, the initial decrease of MEP pointed to an involvement of the lenticulostriate arteries. The following SEP deterioration on the other hand heralded as well a cortical implication. At the end of surgery,



**Figure 3:** Postoperative axial diffusion-weighted image (DWI) showing an acute infarction involving superficial (insular) and deep (lateral lenticulostriate) branches of the right middle cerebral artery.



**Figure 4:** Postoperative axial T2-diffusion image showing a complete tumor resection.

we found an absence of the hand motor response and very low amplitude of the foot response, suggesting a poor long-term functional outcome (6, 7).

To date, all reports of H<sub>2</sub>O<sub>2</sub>-induced strokes are limited to describing the radiological and clinical findings of a stroke after a surgery where H<sub>2</sub>O<sub>2</sub> was utilized and was supposedly, the culprit. Here we bridge the gap, providing neurophysiological proof that the H<sub>2</sub>O<sub>2</sub> instillation provoked the tissue damage in our patient given that the temporal gap between intraoperative neurophysiological changes and the irrigation with H<sub>2</sub>O<sub>2</sub>, once the tumor resection and bipolar coagulation was already finished, is only of few seconds. Furthermore, the stroke occurred in absence of any another possible inducing cause.

The INM changes prompted a quick start of maneuvers aimed at reversing the injury. These measures may have changed the final postoperative outcome of the patient. We conclude that INM can be a very useful tool to detect even the most unlikely mechanisms of neural injury during brain surgery, and to aid neurosurgeons to change the surgical strategy. Finally, we recommend being cautious or even avoiding the application of H<sub>2</sub>O<sub>2</sub> for hemostasis during cranial tumor resection when vascular structures are exposed.

#### REFERENCES

1. Dubey PK, Singh AK: Venous oxygen embolism due to hydrogen peroxide irrigation during posterior fossa surgery. *J Neurosurg Anesthesiol* 12(1): 54-56, 2000
2. Duffau H: A personal consecutive series of surgically treated 51 cases of insular WHO grade II glioma: Advances and limitations. *J Neurosurg* 110(4): 696-708, 2009
3. García-Velasco P, García C, Parramon F, Villalonga A, Beltrán de Heredia B: Gas embolism secondary to intraoperative use of hydrogen peroxide. *Rev Esp Anesthesiol Reanim* 44(3): 124-126, 1997
4. Mesiwala A, Farrell L, Santiago P, Ghatan S, Silbergeld DL: The effects of hydrogen peroxide on brain tumors. *Surg Neurol* 59: 398-407, 2003
5. Mut M, Yemisci M, GURSOY-OZDEMIR Y, TURE U: Hydrogen peroxide-induced stroke: Elucidation of the mechanism in vivo. *J Neurosurg* 110(1): 94-100, 2009
6. Neuloh G, Pechstein U, Schramm J: Motor tract monitoring during insular glioma surgery. *J Neurosurgery* 106: 582-592, 2007
7. Neuloh G, Simon M, Schramm J: Stroke prevention during surgery for deep-seated gliomas. *Neurophysiol Clin* 37: 383-389, 2007
8. Patankar PS, Joshi SS, Choudhari KA: Air-embolism and cerebral ischaemia following epidural hydrogen peroxide irrigation in a closed lumbar cavity. *Br J Neurosurg* 28(4):556-558, 2014
9. Sala F, Lanteri P: Brain surgery in motor areas: The invaluable assistance of intraoperative neurophysiological monitoring. *J Neurosurg Sci* 47(2): 79-88, 2003
10. Sanai N, Polley MY, Berger MS: Insular glioma resection: Assessment of patient morbidity, survival, and tumor progression. *J Neurosurg* 112(1): 1-9, 2010
11. Simon M, Neuloh G, Von Lehe M, Meyer B, Schramm J: Insular gliomas: The case for surgical management. *J Neurosurg* 110(4): 685-695, 2009
12. Spiriev T, Prabhakar H, Sandu N, Tzekov C, Kondoff S, Laleva L, Schaller B: Use of hydrogen peroxide in neurosurgery: Case series of cardiovascular complications *JRSM Short Rep* 3(1): 6, 2012
13. Szelényi A, Hattingen E, Weidauer S, Seifert V, Ziemann U: Intraoperative motor evoked potential alteration in intracranial tumor surgery and its relation to signal alteration in postoperative magnetic resonance imaging. *Neurosurgery* 67(2): 302-313, 2010
14. Ture U, Yasargil DC, Al-Mefty O, Yasargil MG: Topographic anatomy of the insular region. *J Neurosurg* 90(4):720-733, 1999
15. Yasargil MG, von Ammon K, Cavazos E, Doczi T, Reeves JD, Roth P: Tumors of the limbic and paralimbic systems. *Acta Neurochir (Wien)* 118(1-2): 40-52, 1992