



DOI: 10.5137/1019-5149.JTN.16488-15.1

Received: 01.11.2015 / Accepted: 13.04.2016

Published Online: 11.08.2016

Original Investigation

Adult Brainstem Gliomas: Retrospective Analysis of 51 Patients

Goran TASIC^{1,2}, Nikola REPAC¹, Igor NIKOLIC^{1,2}, Vojislav BOGOSAVLJEVIC^{1,2}, Vuk SCEPANOVIC¹, Aleksandar JANICIJEVIC¹, Aleksandra ERIC-NIKOLIC³, Lukas RASULIC^{1,2}

¹Clinical Center of Serbia, Clinic for Neurosurgery, Belgrade, Serbia

²University of Belgrade, Medical Faculty, Belgrade, Serbia

³National Cancer Research Center, Belgrade, Serbia

ABSTRACT

AIM: Brainstem gliomas (BSG) constitute less than 2% of brain tumors in adults. Therapeutic options are limited and BSG are associated with a high morbidity and mortality.

MATERIAL and METHODS: We reviewed the records of 51 patients with BSG treated at the Institute of Neurosurgery, Clinical Center of Serbia in Belgrade between 1998 and 2012. We recorded demographic and clinical variables as well as radiological findings and survival.

RESULTS: Of the 51 patients, 62.7% were male and 37.3% were female. The mean age was 30.6±19.3 years. High grade glioma (Astrocytoma grade III and IV) was most common at the age of 38.2±17.9 years ($t=481$, $p=0.017$) while low grade glioma (Astrocytoma grade I and II) was common in younger age as 25.4±17.4 years ($X^2=4.013$; $p=0.045$), with localization in the pons ($X^2=5.299$; $p=0.021$) and exophytic presentation ($X^2=3.862$; $p=0.049$). Ataxia, as initial symptom, was a predictor of poor outcome (HR:5.546, $p=0.012$).

CONCLUSION: Due to its specific localization, BSG present a major challenge for neurosurgery, because of the necessity of safe approach for radical resection. Histological verification of BSG determines the need for additional therapeutic procedures such as radiotherapy and chemotherapy. Benefit from correct diagnosis is reflected in the avoidance of potentially adverse effects of treatment.

KEYWORDS: Adult, Brainstem, Glioma, Histology, Survival

INTRODUCTION

Tumors of the central nervous system are present in about 2% compared to all malignant tumors of the human population. They represent the leading cause of death from malignant tumors in children population and fourth in the adult population (21). In the period before computed tomography (CT) and magnetic resonance imaging (MRI), all brainstem gliomas (BSG) were considered a pathological entity with a poor prognosis. Matson emphasized that regardless of

the specific pathology all BSG must be considered malignant because their localization itself is inoperable (23). These tumors are most often localized in pons, often with infiltration in other regions of the brainstem (16). They characteristically present with multiple cranial nerve deficits, ataxia and long tract dysfunction (5,6,10). The simplest classification of BSG is into two groups as focal and diffuse (4,8). More complex grading system defined subtypes of tumors of the brainstem, according to localization, the presence of hydrocephalus and hemorrhage and growth model (5,7,11,13).



Corresponding author: Lukas RASULIC

E-mail: lukas.rasulic@gmail.com

■ MATERIAL and METHODS

This is a retrospective study. We present the results of 51 patients with brainstem tumors that were treated at the Institute of Neurosurgery, Clinical Center of Serbia in the period from 1.01.1998 until 31.12.2012. The analysis included gender, age at the time of symptom onset, duration of symptoms before diagnosis, initial symptoms and signs, radiological findings - intensities of the signals, the presence of necrosis and contrast staining, the extent of surgical resection and survival. All the patients were subjected to the MRI during preoperative diagnosis. The data were analyzed with SPSS 13.0 software package. The survival period is shown by Kaplan-Meier's curve.

■ RESULTS

Thirty-two patients (62.7%) were male and 19 patients (37.3%) were female, average age of the patients was 30.6 ± 19.3 years with a median age of 29 and a minimum of 3 years and maximum 70 years. The average duration of symptoms prior to admission was 6.2 ± 6.5 months with a median of 3 months. The minimum duration was 0.5 months, while the maximum duration was 36 months. The most common initial symptoms were hemiparesis (68.6%) and VIIth nerve palsy (35.3%) while the least common was hemiplegia (9.8%) (Table I).

The most common clinical signs were pyramidal deficit (58.8%), VIIth nerve paralysis (56.9%), papilledema of the optic nerve (43.1%), affection of the lower group of cranial nerves (35.3%), while the rarest clinical manifestations were trigeminal motor dysfunction and nystagmus (9.8%) (Table II).

The CT and MRI have been performed in all patients. Most patients had lesions located in pons (54.9%) and pontomedullary part (23.5%), with contrast staining (15.7%) at the periphery (27.5%) and exophytic component (70.59%).

Forty-eight (94.1%) patients were operated. In 39 cases (76.5%), the scope of operation was to reduce of tumor mass (Table III). Initially after admission, ventriculoperitoneal shunt has been inserted in 12 patients because of the presence of hydrocephalus. Two of the patients underwent ventriculoperitoneal shunt insertion after the operation because of the development of hydrocephalus that had not been detected before the operation. The tumors with surface presentation on the ground of the fourth ventricle, tumors with exophytic component and distinctly restricted tumors were operated. The unclearly restricted tumors were also operated because of the histological verification of tumor ($n=7$, 13.7%). All patients were operated in half-seated position, with standard sub-occipital craniectomy for the access to the ground of IVth ventricle using telovelar approach. In cases in which there was no presentation on the surface and/or the exophytic portion of the tumor, we used a safe incision of the ground of IVth ventricle within supra- or infrafacial triangle. For the tumor located in the mesencephalon, we used the subtemporal approach.

Histological type astrocytoma grade I-II was predominant in younger patients, located in the pons with an exophytic component (Table IV).

Nine patients (17.6%) died during the follow-up period. Seven patients died within the first two months after the operation. Three patients died because of intrahospital infection with the clostridia. In two patients, there was development of edema and infarction in the pons. One patient died because of the development of pulmonary embolism five days after the operation. In one patient, there was development of acute renal failure five weeks after the operation. The eighth patient died during the fifth month after the operation due to the development of the meningitis because of the skin necrosis above the pump of the ventriculoperitoneal shunt. The ninth patient died during the 36th month after the operation because

Table I: Initial Symptoms of the Patients

	n	%
Diplopia	9	17.6
Difficulty swallowing	9	17.6
Facial nerve palsy	18	35.3
Other cranial nerves	3	5.9
Ataxia	8	15.7
Hemiparesis	35	68.6
Hemiplegia	5	9.8

Table II: Initial Signs of the Patients

	n	%
n.III	12	23.5
n.V	5	9.8
n.VI	13	25.5
n.VII	29	56.9
n.VIII	5	9.8
n.IX and n.X	18	35.3
Nystagmus	5	9.8
Pyramidal tract findings	30	58.8
Papilledema	22	43.1

Table III: Type of Surgical Treatment

	n	%
No surgery	3	5.9
Biopsy	7	13.7
Tumor reduction	39	76.5
Radical resection	2	3.9
Total	51	100

of the diffuse infiltration of the brainstem with the tumor (initial histological findings were diffuse astrocytoma grade III) and postoperative radiotherapy was performed. The six-month survival, as well as one-year and two-year amounted to 84.3%, while the three-year survival was 81.5% (Figure 1 - Kaplan-Meier). Patients with fatal outcome dominantly had ataxia, as initial symptom (HR:5.546, p = 0.012) (Figure 2).

A radiotherapy protocol was used in 28 patients – where the volume at the operation meant biopsy – 7 patients (4 Astrocytoma grade III and 3 Astrocytoma grade IV), in 19 (48.7%) patients where the volume at the operation meant reduction – (6 Astrocytoma grade II and 13 Astrocytoma grade III) and in two of the three patients who have not been surgically treated with good general condition (Karnofsky Index=80) and based on the MRI it was estimated that there was diffuse tumor of the brainstem.

■ DISCUSSION

Gliomas make up 40-60% of all primary brain tumors (14,19). BSG make up 1% of all brain tumors of adults and 10% of all brain tumors pediatric ages. Initial presentation of these tumors is represented by two peaks of incidence at 4-13 years and the fourth decade of life (9,15,30). Supratentorial brain gliomas have a better prognosis in children than in adults, except glioma localized in the area of the brainstem where survival in children is significantly shorter than in adults (1,3,22,27).

MRI has unquestionable value in the topo-anatomic diagnostic of the brainstem tumors. The intensity of the contrast counting and the ability of the spectroscopic analysis in the great extent predict histological type of tumor. However, results of the numerous authors show that counting tumor with contrast absolutely is not a sign of malignancy and bad outcome (12,15,18,19,30). Confirmation of specifics BSG lies in the

Table IV: Histological Diagnosis Based on Age, Pons Location and Exophytic Component

	Histological diagnosis (Glioma)		Test results
	Grade I and II	Grade III and IV	
Age (years)	25.4±17.4	38.2±17.9	t=-2.481; p=0.017
<18	13 (43.3%)	3 (15.8%)	X ² =4.013; p=0.045
18+	17 (56.7%)	16 (84.2%)	
Pons location	18 (78.26%)	5 (31.74%)	X ² =5.299; p=0.021
Exophytic component	25 (69.44%)	11 (30.56%)	X ² =3.862; p=0.049

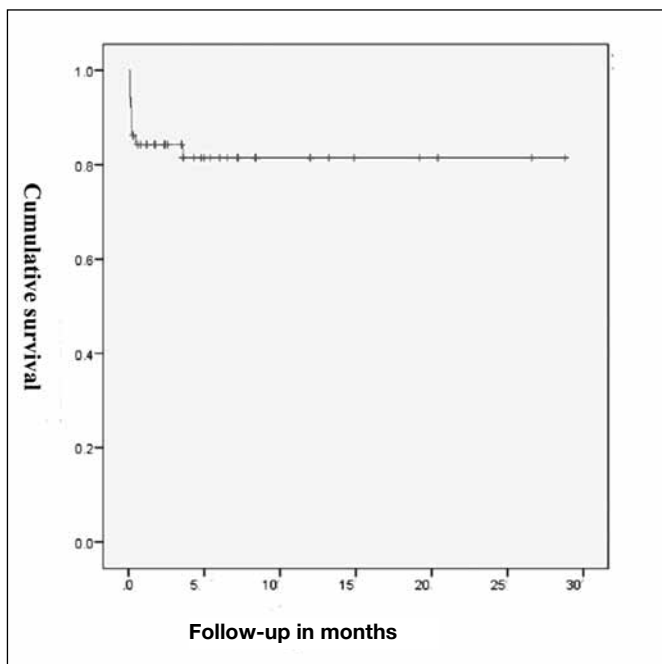


Figure 1: Cumulative survival during the follow-up period.

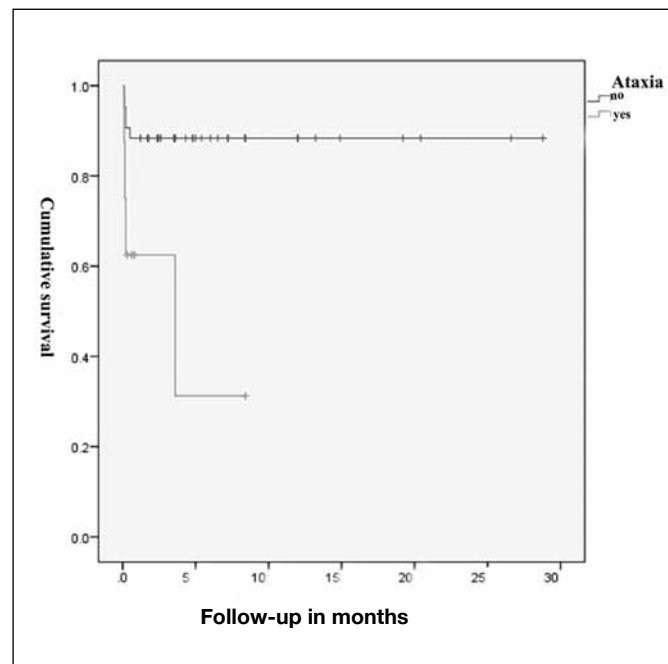


Figure 2: Cumulative survival of patients with or without ataxia during follow-up period.

fact that diffuse BSG rarely stain with contrast (8,9,28). The short time interval between the occurrence of symptoms and the diagnosis, the presence of intra-tumoral necrosis and histologic verification of high grade BSG are predictors of shorter survival period (15,25,28,30). In our series (51 patients), the average duration of symptoms before hospital admission was 6.2 ± 6.5 months with a median of 3 months. The minimum duration was 0.5 months, while the maximum duration was 36 months. The most common initial symptom was hemiparesis (68.6%) and VIIth nerve palsy (35.3%) while the least common were hemiplegia (9.8%). In patients ($n=9$, 17.6%) with a fatal outcome, the dominating symptom was ataxia (HR:5.546, $p=0.012$). Age below 40 years, duration of symptoms longer than 3 months before diagnosis, Karnofsky score above 70, the absence of necrosis and discoloration with contrast to the MRI imaging and a low grade tumor type are indicators of long time survival of patients with BSG (27). Surgical standard implies more radically removal of the tumor without additional neurological deficit (14,19). In our series, 48 patients were operated (94.1%). In 39 cases (76.5%), the extent of operation was to the level of reduction. The histological verification of tumors of the brainstem is difficult due to small quantities or unrepresentative part of taken tissue, especially in the case of stereotactic biopsy, so the need for a correct histological diagnosis imposes direct surgery as the method of choice (2,20,25,30). Hundsberger et al. (17) shows a series of 21 patients with BSG who initially presented by ataxia, paresis of oculomotor nerve, instability when walking and hemiparesis. Patients with malignant gliomas were older (48 years), and the average survival time was 5.8 months compared to the group of patients with gliomas with lower grade of malignancy (34 years) in which the average survival was 24.1 month (17). In our series of 51 patients, 62.7% were male and 37.3% were female, mean age was 30.6 ± 19.3 years. At the age 38.2 ± 17.9 years, the most common tumor was high grade type of glioma ($p=0.017$). While low grade histological type was dominant in younger age 25.4 ± 17.4 years ($p=0.045$), with localization in the pons ($p=0.021$) and exophytic component ($p=0.049$). The protocol of treatment of malignant BSG as includes in addition to radical resection and radiation therapy in the application of a single dose of 2 Gy to a range of 50-55 Gy (24,26,29). In our series, a radiotherapy protocol was conducted in 28 patients, all in which the extent of operation included biopsy, in 19 patients in which the extent of operation included reduction (48.7%), and in 2 out of 3 patients who did not undergo surgical treatment. Nine patients (17.6%) had a lethal outcome during the follow-up period. Seven patients died in the first two months, while the eighth patient died five months after surgery, and the ninth patient died 36 months after surgery. The six-month survival, as well as one-year and two-year amounted to 84.3%, while the three-year survival was 81.5%. Ruben et al. emphasizes that chemotherapy after radiation increases the risk of radio-necrosis five times (26).

■ CONCLUSION

Even though the tumors of the brainstem are heterogeneous in growth model and localization, precise neuroradiological

diagnosis is essential for surgical planning in order to prevent additional neurological deficits. Precise histological verification enables prediction of growth model and determines the protocol for their further treatment. Diffuse BSG does not “respect” the anatomical barrier (nucleus of cranial nerves and nerve pathways) and has a predominantly high degree of malignancy. Low grade BSG in adults have focal growth, so that surgical reduction of the tumor mass without radical surgery to the healthy tissue, enables long lasting survival without the need for adjuvant oncology protocol and without additional neurological deficit.

■ REFERENCES

1. Ahmed KA, Laack NN, Eckel LJ, Orme NM, Wetjen NM: Histologically proven, low-grade brainstem gliomas in children: 30-year experience with long-term follow-up at Mayo Clinic. *Am J Clin Oncol* 37: 51–56, 2013
2. Albright AL, Packer RJ, Zimmerman R, Rorke LB, Boyett J, Hammond GD: Magnetic resonance scans should replace biopsies for the diagnosis of diffuse brain stem gliomas: A report from the Children's Cancer Group. *Neurosurgery* 33:1026–1030, 1993
3. Babu R, Kranz PG, Karikari IO, Friedman AH, Adamson C: Clinical characteristics and treatment of malignant brainstem gliomas in elderly patients. *J Clin Neurosci* 20:1382–1386, 2013
4. Barkovich AJ, Krischer J, Kun LE, Packer R, Zimmermann RA, Freeman CR, Wara WM, Albright L, Allen JC, Hoffman HJ: Brain stem gliomas: A classification system based on magnetic resonance imaging. *Pediatr Neurosurg* 16: 73–83, 1990
5. Beltramello A, Lombardo MC, Masotto B, Bricolo A: Imaging of brain stem tumors. *Oper Tech Neurosurg* 3:87–105, 2000
6. Bricolo A: Surgical management of intrinsic brain stem gliomas. *Oper Tech Neurosurg* 3:137–154, 2000
7. Choux M, Lena G, Do L: Brain stem tumors. In: Choux M, Di Rocco C, Hockley A (eds), *Pediatr Neurosurg*. New York: Churchill Livingstone, 2000: 471–491
8. Dellaretti M, Touzet G, Reyns N, Dubois F, Gusmao S, Pereira JL, Blond S: Correlation between magnetic resonance imaging findings and histological diagnosis of intrinsic brainstem lesions in adults. *Neuro-Oncology* 14:381–385, 2012
9. Donaldson SS, Laningham F, Fisher PG: Advances toward an understanding of brainstem gliomas. *J Clin Oncol* 24:1266–1272, 2006
10. Epstein FJ, Farmer JP: Brainstem glioma growth patterns. *J Neurosurg* 78: 408–412, 1993
11. Epstein FJ, Ozek M: The plated bayonet: A new instrument to facilitate surgery for intra-axial neoplasms of the spinal cord and brain stem. Technical note. *J Neurosurg* 78:505–507, 1993
12. Farmer JP, Montes JL, Freeman CR, Meagher-Villemure K, Bond MC, O'Gorman AM: Brainstem gliomas. A 10-year institutional review. *Pediatr Neurosurg* 34: 206–214, 2001

13. Fischbein NJ, Prados MD, Wara W, Russo C, Edwards MS, Barkovich AJ: Radiological classification of brain stem tumors: Correlation of magnetic resonance imaging appearance with clinical outcome. *Pediatr Neurosurg* 24:9–23, 1996
14. Grimm SA, Chamberlain MC: Brainstem glioma: A review. *Curr Neurol Neurosci Rep* 13:346, 2013
15. Guillamo JS, Monjour A, Taillandier L, Devaux B, Varlet P, Haie-Meder C, Defer GL, Maison P, Mazeron JJ, Cornu P, Delattre JY; Association des Neuro-Oncologues d'Expression Française (ANOCEF): Brainstem gliomas in adults: Prognostic factors and classification. *Brain* 124:2528–2539, 2001
16. Helton KJ, Weeks JK, Phillips NS, Zou P, Kun LE, Khan RB, Gajjar A, Fouladi M, Broniscer A, Boop F, Li CS, Ogg RJ: Diffusion tensor imaging of brainstem tumors: Axonal degeneration of motor and sensory tracts. *J Neurosurg Pediatrics* 1: 270–276, 2008
17. Hundsberger T, Tonder M, Hottinger A, Brügge D, Roelcke U, Putora PM, Stupp R, Weller M: Clinical management and outcome of histologically verified adult brainstem gliomas in Switzerland: A retrospective analysis of 21 patients. *J Neurooncol* 118: 321–328, 2014
18. Jallo G: Brainstem gliomas. *Childs Nerv Syst* 22:1–2, 2006
19. Jallo GI, Biser-Rohrbaugh A, Freed D: Brainstem gliomas. *Childs Nerv Syst* 20:143–153, 2004
20. Kickingereeder P, Willeit P, Simon T, Ruge MI: Diagnostic value and safety of stereotactic biopsy for brainstem tumors: A systematic review and meta-analysis of 1480 cases. *Neurosurgery* 72:873–888, 2013
21. Kleihues P, Louis DN, Scheithauer BW, Rorke LB, Reifenberger G, Burger PC, Cavenee WK: The WHO classification of tumors of the nervous system. *J Neuropathol Exp Neurol* 61:215–225, 2002
22. Laigle-Donadey F, Doz F, Delattre JY: Brainstem gliomas in children and adults. *Curr Opin Oncol* 20:662–667, 2008
23. Matson D: Tumors of the posterior fossa. In: Matson DD, Ingraham FD (ed). *Neurosurgery of Infancy and Childhood*. 2nd ed. Springfield (IL): Charles C. Thomas, 1969: 469–477
24. Mayo C, Yorke E, Merchant TE: Radiation associated brainstem injury. *Int J Radiat Oncol Biol Phys* 76:S36–S41, 2010
25. Reyes-Botero G, Mokhtari K, Martin-Duverneuil N, Delattre JY, Laigle-Donadey F: Adult brainstem gliomas. *Oncologist* 17:388–397, 2012
26. Ruben JD, Dally M, Bailey M, Smith R, McLean CA, Fedele P: Cerebral radiation necrosis: Incidence, outcomes, and risk factors with emphasis on radiation parameters and chemotherapy. *Int J Radiat Oncol Biol Phys* 65:499–508, 2006
27. Salmaggi A, Fariselli L, Milanese I, Lamperti E, Silvani A, Bizzi A, Maccagnano E, Trevisan E, Laguzzi E, Ruda R, Boiardi A, Soffietti R: Natural history and management of brainstem gliomas in adults: A retrospective Italian study. *J Neurol* 255:171–177, 2008
28. Santosh Kesari S, Kim RS, Markos V, Drappatz J, Wen, Pruitt AA: Prognostic factors in adult brainstem gliomas: A multicenter, retrospective analysis of 101 cases. *J Neurooncol* 88:175–183, 2008
29. Sharma MS, Kondziolka D, Khan A, Kano H, Niranjan A, Flickinger JC, Lunsford LD: Radiation tolerance limits of the brainstem. *Neurosurgery* 63:728–732, 2008
30. Ueoka DI, Nogueira J, Campos JC, Maranhao FP, Ferman S, Lima MA: Brainstem gliomas: Retrospective analysis of 86 patients. *J Neurol Sci* 281:20–23, 2009