



DOI: 10.5137/1019-5149.JTN.16871-15.0

Received: 26.12.2015 / Accepted: 16.02.2016

Published Online: 08.08.2016

Original Investigation

Morphometric Analysis of Lumbar Disc Space in the Turkish Population and Safe Discectomy Distance in Lumbar Disc Surgery

Veysel ANTAR¹, Oguz BARAN¹, Bilal KELTEN², Ibrahim Burak ATCI¹, Hakan YILMAZ³, Salim KATAR¹, Adem YILMAZ⁴

¹Istanbul Research and Training Hospital, Neurosurgery Clinic, Istanbul, Turkey

²Maltepe University, Department of Neurosurgery, Istanbul, Turkey

³Ataturk State Hospital, Neurosurgery Clinic, Duzce, Turkey

⁴Sisli Hamidiye Etfal Research and Training Hospital, Neurosurgery Clinic, Istanbul, Turkey

ABSTRACT

AIM: Lumbar discectomy is a common surgical intervention in neurosurgical practice. Iatrogenic vascular injury during this surgery is a rare, but serious complication. In this study, our aim was to review the average safe depth of discectomy for both sexes.

MATERIAL and METHODS: This study involved a total of 56 patients between 21 and 79 years old (28 male and 28 female) who had no surgical pathology as documented by lumbar magnetic resonance imaging study. Measurements at L3-4, L4-5, and L5-S1 were performed for both sexes as follows: 1st measurement, from the furthest lateral part of the dura to the end of the disc (right-left); 2nd measurement, the anteroposterior length of the cross-section passing through the midline of the disc; 3rd measurement; from the furthest lateral part of the dura to the furthest lateral part of the disc (right-left); 4th measurement, the length from right to left of the cross-section passing through the midline of the disc.

RESULTS: Measurement 1 at L3-4, L4-5, and L5-S1, this value was estimated to be 35.9 and 36.7 mm, 35.9 and 36.9, and 34 and 34.9 mm in the right and left sides respectively, for female subjects. The corresponding values for males were 41.4 and 42.1, 40.6 and 40.9, and 37.4 and 37.7 mm at L3-4, L4-5, and L5-S1, respectively. Measurement 3 in L3-4, L4-5, and L5-S1 disc spaces on the right and left sides in female subjects were 14.8 and 16.3 mm, 15.7 and 17.2 mm, and 14.9 and 17.1 mm, respectively, with corresponding figures of 18.6 and 19.5, 19.7 and 20.6, and 18.2 and 18.6 mm among male participants. Measurement 2 and 4 in females for L3-4, L4-5, and L5-S1 were 38.4 and 52.3 mm, 38.9 and 53.4 mm, and 37 and 51.8 mm, respectively. The corresponding figures for males were 43.2 and 57.6 mm, 43.2 and 58.9 mm, and 40.1 and 56.7 mm, respectively.

CONCLUSION: Determination of the safe discectomy depth in both males and females, as well as the use of marking disc punches to indicate the safe margins may help clinicians to avoid this unwanted complication.

KEYWORDS: Lumbar disc surgery, Vascular injury, Intestinal injury, Safe discectomy distance



Corresponding author: Veysel ANTAR

E-mail: veyselantar@hotmail.com

■ INTRODUCTION

Lumbar discectomy is a common surgical intervention in neurosurgical practice. Iatrogenic vascular injury during this type of surgery is a rare, but serious complication associated with high reported mortality rates, i.e. >50%, that may lead to diffuse retroperitoneal hemorrhage. While limited discectomy is performed in a certain proportion of patients undergoing surgery due to lumbar disc herniation, aggressive discectomy may have to be carried out in those subjects who require interbody fusion (1,5). Thus, a sound knowledge on the average dimensions of intervertebral spaces as well as the depth and limit values is essential on the part of all neurosurgeons who perform spinal surgery (7).

Our aim was to review the average safe depth of discectomy for both sexes.

■ MATERIAL and METHODS

This study involved 56 patients between 21 and 79 years old (28 male and 28 female) who attended to the neurosurgery outpatient unit between June 2015 and July 2015 and who had no surgical pathology as documented by lumbar magnetic resonance imaging (MRI) study. The lumbar MRI imaging studies were performed using the standard imaging acquisition technique with a GA 1.5 Tesla MRI device (General Electrics, 2010, USA) at Istanbul Research and Training Hospital. The measurements were performed in the axial plane in T2 sequences (T2W) with free medical imaging software (OsiriX Medical Image software; www.osirix-viewer.com). The intervertebral disc spaces of L3-4, L4-5, and L5-S1 were initially identified in the sagittal cross-sections, and the axial plane passing through the midline in the intervertebral disc space was used for the measurements under the guidance of sagittal views. All measurements were performed by the same operator. Initially, a total of four measurements were performed at the axial plane in lumbar MRI images, in an effort to determine the safe disc distance that should be taken into consideration during a discectomy. Measurements at L3-4, L4-5, and L5-S1 were performed for both sexes as follows:

1st measurement, from the furthest lateral part of the dura to the end of the disc (right-left),

2nd measurement, the anteroposterior length of the cross-section passing through the midline of the disc,

3rd measurement; from the furthest lateral part of the dura to the furthest lateral part of the disc (right-left),

4th measurement, the length from right to left of the cross-section passing through the midline of the disc (Figure 1).

A comparison with regard to gender, age, height, and body mass index (BMI) values were performed for each of the measurements and average values were calculated to determine any gender differences with regard to safe discectomy distance.

Statistical Analyses

For statistical analyses, NCSS (Number Cruncher Statistical

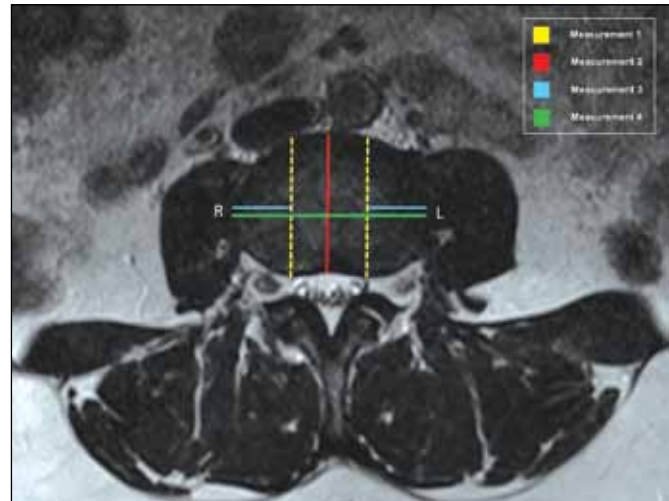


Figure 1: Measurements of lumbar disc are shown on the axial T2W MRI scan.

System) 2007 and PASS (Power Analysis and Sample Size) 2008 Statistical Software (Utah, USA) were utilized. In addition to descriptive statistics (mean, standard deviation, median, frequency, ratio, minimum, maximum), the Box Plot approach was used for determining the reference ranges for the variables. Pearson Correlation Analysis was performed for the assessment of the association between variables. Significance was tested at $p < 0.01$ and $p < 0.05$.

■ RESULTS

This study was undertaken by participation of 56 subjects (28 male, 28 female) between 21 and 79 years old (mean: 45.52 ± 15.04 years) who underwent a lumbar MRI study at the Department of Neurosurgery, Istanbul Research and Training Hospital between June 2015 and July 2015. The average height of study participants was 169.07 ± 6.96 cm (range: 158–184 cm), and the average weight was 75.05 ± 10.46 kg (range: 58–110 kg), with an average BMI of 26.24 ± 3.10 kg/m² (range: 20.28–34.89 kg/m²) (Table I).

The distance from the furthest lateral dura to the anterior longitudinal ligament on the same line was measured (**Measurement 1**) at L3-4, L4-5, and L5-S1 spaces in both sexes (anterior safe distance). At L3-4, L4-5, and L5-S1, this value was estimated to be 35.9 and 36.7 mm, 35.9 and 36.9, and 34 and 34.9 mm in the right and left sides respectively, for female subjects. The corresponding values for males were 41.4 and 42.1, 40.6 and 40.9, and 37.4 and 37.7 mm at L3-4, L4-5, and L5-S1, respectively.

The distance between the furthest lateral part of dura to the furthest lateral end of the disc was measured (**Measurement 3**) at L3-4, L4-5, and L5-S1 spaces (lateral safe disc distance). This value in L3-4, L4-5, and L5-S1 disc spaces on the right and left sides in female subjects were 14.8 and 16.3 mm, 15.7 and 17.2 mm, and 14.9 and 17.1 mm, respectively, with corresponding figures of 18.6 and 19.5, 19.7 and 20.6, and 18.2 and 18.6 mm among male participants.

In both female and male subjects, the length in anteroposterior and right-to-left directions were measured (**Measurements 2 and 4**) for the cross-sections passing through the midline of the disc (intervertebral disc dimensions). The anteroposterior and right-to-left measurement in females for L3-4, L4-5, and L5-S1 were 38.4 and 52.3 mm, 38.9 and 53.4 mm, and 37 and 51.8 mm, respectively. The corresponding figures for males were 43.2 and 57.6 mm, 43.2 and 58.9 mm, and 40.1 and 56.7 mm, respectively (Table II).

Table I: Demographic Characteristics of Study Participants

		Min-Max	Mean±SD
Age (years)		21-79	45.52±15.04
Height (cm)		158-184	169.07±6.96
Weight (kg)		58-110	75.05±10.46
BMI (kg/m ²)		20.28-34.89	26.24±3.10
		n	%
Gender	Female	28	50.0
	Male	28	50.0

The estimations regarding safe discectomy depth based on the distance between the furthest lateral part of dura and the anterior ligament, and from the furthest lateral part of the dura to the lateral part of the disc suggested that the depth of discectomy was on average 5 mm shorter than males. Also, in discectomies involving lateral angulation at the disc space from the furthest lateral part of dura, there was a significant reduction in the safe disc distance, suggesting the need for additional caution in discectomies with lateral angulation and that there was an average distance of 17 mm available for this approach.

Table III shows the reference values (lowest and highest measurements) for L3-4, L4-5, and L5-S1 disc spaces in both sexes.

With respect to age, a significant increase only in the anteroposterior and right-to-left dimensions of L3-4 space was noted for both sexes, while no such significant associations with age could be detected at other intervertebral disc spaces (Table IV).

Height and safe disc distance dimensions had no significant associations in males, while among females, a statistically significant reduction in disc dimension and safe disc distance was found at L5-S1 among females (p<0.05) (Table V).

Table II: Measurements (mm) at L3-L4, L4-L5 and L5-S1 according to Gender

		Measurement 1		Measurement 2	Measurement 3		Measurement 4	
		Right	Left		Right	Left	From right to left	
Female	L3-L4	Min-Max	28.28-44.16	27.33-43.54	31.33-47.00	9.06-19.87	10.79-21.47	42.47-62.02
		Mean±SD	35.99±4.38	36.77±4.14	38.47±4.18	14.89±2.73	16.36±2.42	52.32±4.73
		Median	35.88	37.06	37.85	15.285	16.42	52.125
	L4-L5	Min - Max	28.55-47.25	29.59-46.78	32.33-46.76	9.40-22.91	11.84-23.38	43.46-62.43
		Mean±SD	35.97±4.01	36.91±3.71	38.93±3.60	15.76±2.97	17.28±2.49	53.43±4.55
		Median	35.655	36.685	38.13	15.595	17.065	53.445
	L5-S1	Min - Max	28.20-39.34	27.32-39.56	31.95-42.13	9.75-18.99	11.84-22.92	42.58-61.49
		Mean±SD	34.01±3.13	34.97±3.25	37.02±3.04	14.99±2.60	17.15±3.10	51.88±5.55
		Median	33.77	34.825	36.995	15.71	16.74	51.805
Male	L3-L4	Min - Max	36.46-51.85	36.26-49.78	37.42-52.33	13.92-23.60	14.67-26.26	50.01-67.36
		Mean±SD	41.41±3.56	42.12±3.26	43.28±3.40	18.69±2.16	19.52±2.19	57.65±3.63
		Median	40.37	41.455	42.58	18.51	19.825	57.285
	L4-L5	Min - Max	35.23-47.14	34.97-47.30	38.52-49.43	14.83-22.87	16.40-29.93	53.29-65.64
		Mean±SD	40.60±2.80	40.98±2.97	43.23±2.85	19.72±2.04	20.60±2.90	58.94±3.46
		Median	40.46	41.735	43.60	20.095	20.09	59.25
	L5-S1	Min - Max	32.14-45.32	32.47-44.23	35.17-48.29	13.30-22.61	15.07-24.44	48.82-71.43
		Mean±SD	37.44±2.93	37.72±3.06	40.10±3.40	18.20±2.13	18.68±2.25	56.72±5.22
		Median	36.945	37.645	39.975	18.015	18.115	55.66

Table III: Reference Ranges at L3-L4, L4-L5 and L5-S1 Spaces according to Gender

			Measurement 1		Measurement 2	Measurement 3		Measurement 4
			Right	Left		Right	Left	
Female	L3-L4	Lowest Value	24.67	25.43	27.61	6.35	10.98	43.63
		Highest Value	48.79	48.21	48.87	22.89	21.21	62.22
	L4-L5	Lowest Value	27.59	28.90	30.43	6.03	10.14	43.04
		Highest Value	44.59	45.84	47.78	25.50	24.21	64.28
	L5-S1	Lowest Value	24.86	24.84	27.94	5.59	6.46	34.20
		Highest Value	44.36	45.79	46.44	23.89	28.09	69.96
Male	L3-L4	Lowest Value	33.83	34.80	38.11	14.37	14.15	49.77
		Highest Value	48.56	49.09	47.50	23.16	24.38	65.56
	L4-L5	Lowest Value	32.52	32.66	35.01	15.52	14.86	47.61
		Highest Value	48.29	48.82	51.07	24.57	25.83	70.27
	L5-S1	Lowest Value	27.61	29.74	30.57	13.38	12.42	47.22
		Highest Value	47.49	46.08	48.43	23.09	24.66	64.86

Table IV: The Association Between Age and Measurements at L3-L4, L4-L5 and L5-S1 Cross-Sections for Both Sexes

Age			Female		Male	
			r	p	r	p
L3-L4	1 st Measurement	Right	0.459	0.014*	0.581	0.001**
		Left	0.435	0.021*	0.568	0.002**
	2 nd Measurement	Right	0.412	0.029*	0.549	0.002**
		Left	0.521	0.004**	0.070	0.724
	3 rd Measurement	Right	0.384	0.043*	0.226	0.249
		Left	0.606	0.001**	0.447	0.017*
L4-L5	1 st Measurement	Right	0.224	0.251	0.436	0.020*
		Left	0.270	0.165	0.285	0.141
	2 nd Measurement	Right	0.316	0.101	0.365	0.056
		Left	0.318	0.099	0.109	0.582
	3 rd Measurement	Right	0.344	0.073	0.213	0.277
		Left	0.397	0.036*	0.411	0.030*
L5-S1	1 st Measurement	Right	0.231	0.237	0.344	0.073
		Left	0.201	0.305	0.279	0.151
	2 nd Measurement	Right	0.115	0.559	0.304	0.116
		Left	0.341	0.076	0.285	0.141
	3 rd Measurement	Right	0.260	0.182	0.234	0.231
		Left	0.314	0.103	0.208	0.288

r= Pearson correlation coefficient, *p<0.05, **p<0.01.

BMI had no significant associations with safe disc space measurements in males. However, in females, increasing BMI values were associated with significantly increased L3-4 and L5-S1 spaces ($p < 0.05$) (Table VI).

■ DISCUSSION

Almost 1 to 3% of patients, seeking medical assistance due to severe low back and lower extremity pain, undergo surgery. While limited anatomical removal of certain tissues may suffice in some cases depending on the characteristics of the herniated disc, discectomy may be required within the intervertebral space when PLL rupture is large enough or a PLL incision is made in protruded discs.

Although rare, iatrogenic vascular injury occurring during lumbar disc surgery represents a complication with high mortality which has been reported to occur in 0.01 to 0.05% of the cases (5,15). From a clinical viewpoint, the associated vascular injury may vary from massive hemorrhage to the occurrence of arteriovenous fistula and pseudoaneurysms (9,11,13), with a mortality exceeding 50%. In patients with such vascular injury, early identification and management may reduce mortality (2,7,8,15). The most common sites at which

such injuries occur during disc surgery are L4-5 and L5-S1. The major iliac vessels originating after that level are more commonly involved in such injuries. The vascular structure with highest risk of injury is represented by the left common iliac artery, owing to its close adjacency with the L4-5 intervertebral disc space and owing to its medial course (4,7,8, 10,12).

Annulus fibrosus and ALL have a role in the prevention of vascular injury through blocking the entry of surgical equipment into the anterior compartment. However, a number of factors including the degeneration of the annulus fibrosis and anterior longitudinal ligament, advanced discopathy, vertebral abnormalities, adhesion of the anterior longitudinal ligament and intervertebral disc, previous disc surgery, aggressive exploration, and complex patient positioning may pose a significantly greater risk of major vascular injury (3,6, 10).

However, in patients requiring repeat lumbar disc surgery, further facetectomy from the end of the facet joint toward the lateral side may allow execution of a surgical technique from the lateral side of the disc without cleansing the fibrotic tissue. When bleeding occurs during such a procedure, anatomical

Table V: The Association Between Height and L3-L4, L4-L5 And L5-S1 Measurements in Both Sexes

Height			Female		Male		
			r	p	r	p	
L3-L4	1 st Measurement	Right	-0.291	0.133	0.199	0.311	
		Left	-0.390	0.040*	0.069	0.725	
	2 nd Measurement		-0.360	0.060	0.018	0.927	
	3 rd Measurement	Right	-0.354	0.064	0.214	0.275	
		Left	-0.469	0.012*	0.022	0.912	
	4 th Measurement		-0.416	0.028*	0.154	0.435	
	L4-L5	1 st Measurement	Right	-0.335	0.082	0.036	0.855
			Left	-0.311	0.108	0.069	0.727
2 nd Measurement			-0.408	0.031*	0.070	0.722	
3 rd Measurement		Right	-0.324	0.093	-0.198	0.314	
		Left	-0.489	0.008**	0.008	0.969	
4 th Measurement			-0.357	0.062	-0.089	0.654	
L5-S1		1 st Measurement	Right	-0.384	0.044*	-0.080	0.684
			Left	-0.559	0.002**	-0.081	0.681
	2 nd Measurement		-0.501	0.007**	-0.060	0.763	
	3 rd Measurement	Right	-0.320	0.096	0.069	0.728	
		Left	-0.343	0.074	0.110	0.578	
	4 th Measurement		-0.392	0.039*	0.123	0.533	

r = Pearson correlation coefficient, * $p < 0.05$, ** $p < 0.01$.

Table VI: The Association Between L3-L4, L4-L5 And L5-S1 Measurements and BMI in Both Sexes

BMI			Female		Male	
			r	p	r	p
L3-L4	1 st Measurement	Right	0.369	0.053	0.041	0.837
		Left	0.439	0.019*	0.038	0.850
	2 nd Measurement		0.415	0.028*	0.107	0.588
	3 rd Measurement	Right	0.240	0.219	0.121	0.539
		Left	0.383	0.044*	0.272	0.162
4 th Measurement		0.409	0.031*	0.128	0.516	
L4-L5	1 st Measurement	Right	0.187	0.341	-0.294	0.129
		Left	0.195	0.320	-0.258	0.185
	2 nd Measurement		0.349	0.069	-0.400	0.035*
	3 rd Measurement	Right	0.084	0.673	0.009	0.965
		Left	0.166	0.398	-0.187	0.339
4 th Measurement		0.252	0.196	-0.300	0.121	
L5-S1	1 st Measurement	Right	0.420	0.026*	-0.298	0.123
		Left	0.474	0.011*	-0.287	0.138
	2 nd Measurement		0.411	0.030*	-0.303	0.116
	3 rd Measurement	Right	0.323	0.094	-0.091	0.646
		Left	0.306	0.114	-0.259	0.183
4 th Measurement		0.472	0.011*	-0.348	0.070	

r= Pearson correlation coefficient, *p<0.05, **p<0.01.

landmarks may be obscured due to the presence of fibrotic tissues, complicating the estimation of the anatomical depth. Further lateral manipulation of the disc punch in the reverse direction may lead to an excessively increased risk of potential vascular injury.

The first case of vascular injury occurring during lumbar disc surgery was published by Linton and White, where an arteriovenous fistula forming between the right iliac artery and inferior vena cava was described (4,14). The original description of intestinal injury as a complication of disc surgery was published by Harbison (7). Generally, these cases have been reported to occur following inappropriate advancement of the forceps used for disc surgery toward the retroperitoneal area anterior to the anterior longitudinal ligament in addition to inappropriate surgical maneuvers in that area.

In 1963, Goodkin et al. proposed the use of lateral lumbar x-rays to estimate the depth of the disc space, assuming that forceps marked according to depth calculations would be effective in reducing such complications. Recently, several authors have also recommended the use of preoperative radiographs to evaluate the disc spaces, because loops, currently utilized in disc surgery, may also be misleading for

the surgeon since they tend to overestimate the depth of the space (2,7).

Although preoperative neuroimaging studies are important for the evaluation of annular fibers and ALL, neurosurgeons performing spinal surgery should also be well informed on the volume and limits of the lumbar inter-vertebral disc spaces in question, since while limited discectomy suffices for some patients, others undergoing interbody fusion require aggressive discectomy. In this study, our objective was to establish the distance to discectomy site of the major vascular structures relevant to the 3 intervertebral disc spaces on which discectomy is most commonly performed, using data based on imaging studies.

■ CONCLUSION

A good knowledge on safe discectomy depth in the lumbar spine is essential for all surgeons performing spinal surgery. Being aware of the fact that the safe discectomy depth is smaller in females than in males, and that anatomical variations are more common in major arterial and venous structures coursing just anterior to L4-5 space may help reduce the risk of fatal complications occurring during this type of surgery.

Determination of the safe discectomy depth in both males and females as well as use of marking disc forceps to indicate the safe margins may help clinicians avoid this unwanted complication.

■ REFERENCES

1. Bierdrager E, Van Rooij WJ, Sluzewski M: Emergency stenting to control massive bleeding of injured iliac artery following lumbar disc surgery. *Neuroradiology* 46(5):404-406, 2004
2. Dosoglu M, Is M, Pehlivan M, Yildiz KH: Nightmare of lumbar disc surgery: Iliac artery injury. *Clin Neurol Neurosurg* 108: 174-177, 2006
3. Duz B, Kaplan M, Gunay C, Ustunsoz B, Ugurel MS: Iliocaval arteriovenous fistula following lumbar disc surgery: Endovascular treatment with a stent-graft. *Turk Neurosurg* 18: 245-248, 2008
4. Erkut B, Unlu Y, Kaygin MA, Colak A, Erdem AF: Iatrogenic vascular injury during to lumbar disc surgery. *Acta Neurochir (Wien)* 149: 511-516, 2007
5. Ertan A, Oz H, Birgen N, Hancı M, Turan N: Spinal cerrahi girişimlere bağlı ortaya çıkan damar yaralanmalarında anestezi uzmanının rolü. *Adli Tıp Derg* 20(3): 24-28, 2006 (In Turkish)
6. Fruhwirth J, Koch G, Aman W, Hauser H, Flaschka G: Vascular complications of lumbar disc surgery. *Acta Neurochir (Wien)* 138: 912-916, 1996
7. Goodkin R, Laska LL: Vascular and visceral injuries associated with lumbar disc surgery: Medicolegal implications. *Surg Neurol* 49(4): 358-370, 1998
8. Papadoulas S, Konstantinou D, Kourea HP, Kritikos N, Haftouras N, Tsolakis JA: Vascular injury complicating lumbar disc surgery. A systematic review. *Eur J Vasc Endovasc Surg* 24: 189-195, 2002
9. Pillet JC, Pillet MC, Braesco J, Thomas E, Bezon E, Mondine PH, Barra JA, Pillet J: Vascular complications of lumbar disc surgery. Report of two cases and review of the literature on 122 cases. *J Mal Vasc* 20(3): 219-223, 1995
10. Prabhakar H, Bithal PK, Dash M, Chaturvedi A: Rupture of aorta and inferior vena cava during lumbar disc surgery. *Acta Neurochir (Wien)* 147: 327-329, 2005
11. Quigley TM, Stoney RJ: Arteriovenous fistulas following lumbar laminectomy: The anatomy defined. *J Vasc Surg* 2(6): 828-833, 1985
12. Sadhasivam S, Kaynar M: Iatrogenic arteriovenous fistula during lumbar microdiscectomy. *Anesth Analg* 99: 1815-1817, 2004
13. Wildförster U: Intraoperative complications in lumbar intervertebral disk operations. Cooperative study of the spinal study group of the German Society of Neurosurgery. *Neurochirurgia (Stuttg)* 34(2): 53-56, 1991
14. Yildiz R, Oztas M, Sahin MA, Yagci G: Abdominal aortic injury due to lumbar disc surgery: A case report. *Ulus Cerrahi Derg* 29(4): 192-196, 2013
15. Yu HP, Hseu SS, Sung CS, Cheng HC, Yien HW: Abdominal vascular injury during lumbar disc surgery. *Zhonghua Yi Xue Za Zhi (Taipei)* 64(11): 649-654, 2001