



DOI: 10.5137/1019-5149.JTN.18331-16.2

Received: 04.06.2016 / Accepted: 14.10.2016

Published Online: 21.11.2016

Original Investigation

Supraorbital Keyhole Microsurgical Fenestration of Symptomatic Temporal Arachnoid Cysts in Children: Advantages and Limitations

Sherif ELKHESHIN, Ahmed SOLIMAN

Tanta University Hospital, Department of Neurosurgery, Tanta, Egypt

ABSTRACT

AIM: To investigate the impact of endoscope-assisted microsurgical fenestration on temporal arachnoid cysts, and to determine the advantages and limitations of the technique.

MATERIAL and METHODS: Twenty-five children with symptomatic temporal arachnoid cysts were operated via eyebrow supraorbital keyhole microsurgical fenestration targeting the medial cyst wall. Preoperative magnetic resonance imaging (MRI) of the brain was done for all patients.

RESULTS: Preoperative clinical presentation of the patients included headache (80%), nausea & vomiting (64%), drug resistant epilepsy (52%), macrocephaly (12%) papilledema (28%), motor weakness in the form of right-sided hemiparesis (12%) and cranial nerve palsy. Postoperative complete subsidence of headache was noted in 50%, while 20% remained unchanged. Drug resistant epilepsy improved in 69% of the patients. Postoperative MRI showed initial decrease in cyst volume as early as 3 months, only in a range of 5-12% volume reduction, and the late follow-up done at 6 and 18 months continued to show further reduction reported to be significant ($p < 0.001$). Transient subgaleal cerebrospinal fluid (CSF) collection was the most common complication (20%). Only 1 patient experienced CSF leak mandating cysto-peritoneal shunting.

CONCLUSION: Eyebrow supraorbital keyhole microsurgical fenestration for temporal arachnoid cysts can be performed with a fairly low risk of complications and yields a favorable improvement in clinical and neuroimaging outcomes.

KEYWORDS: Endoscopy, Keyhole Supraorbital, Eyebrow, Arachnoid cyst, Middle fossa

INTRODUCTION

Arachnoid cysts are developmental lesions accounting for 1% of intracranial space-occupying lesions. They contain fluid similar to cerebrospinal fluid (CSF) with a wall composed of arachnoid cells. More than half of these cysts develop in the middle cranial fossa (11).

Based on morphological appearance in neuroimaging, arachnoid cysts are classified according to Galassi into 3 types. These include (type I) cysts that are small, fusiform, within the confines of the anterior part of middle cranial fossa; (type II) cysts that exert mass effect on the temporal lobe not

exceeding the Sylvian fissure; and (type III) cysts that hugely fill the whole middle cranial fossa, and exert a mass effect on both frontal and parietal lobes (8,9).

Although many are discovered accidentally, they may cause symptoms related to a mass effect. Middle fossa arachnoid cysts may cause headaches, papilledema, macrocrania, seizures, cognitive impairment, cranial nerve palsy and motor deficits (14).

The treatment of intracranial arachnoid cysts is a matter of debate. A recent prospective study conducted on 76 adults with symptomatic arachnoid cysts treated surgically through



Corresponding author: Sherif ELKHESHIN

E-mail: sherif_elkhesin@yahoo.com

microsurgical fenestration reported significant improvement in the patients' quality of life correlated to improvement of headache and dizziness (16). Patients with temporal arachnoid cysts have a significant post-surgical fenestration improvement in their subjective preoperative dizziness (26). Surgical options for symptomatic patients include cysto-peritoneal shunt (1-3,24,27,29), microsurgical fenestration (6,7,12,17,19,20,21,27) and pure endoscopic fenestration (4,5,10,13,28). Each of these surgical options has relative advantages and possible drawbacks.

Supraorbital subfrontal approach through an eyebrow skin incision (including arachnoid cyst fenestration) was used by Perneczky as early as 1985. The advances in microneurosurgical techniques, endoscopic instruments and precise preoperative planning using recent neuroimaging facilities enable neurosurgeons to approach deeply seated lesions through small tailored corridors (20).

Through eyebrow supraorbital mini-craniotomy, we targeted fenestration of medial cyst wall into nearby interpeduncular and prepontine cisterns which we consistently confirmed by further endoscopic inspection. The advantages and limitations of the technique are thereby evaluated.

■ MATERIAL and METHODS

This retrospective study includes twenty-five children of symptomatic temporal arachnoid cysts operated via endoscope-assisted supraorbital keyhole microsurgical fenestration, in Tanta University Hospitals from October 2010 to October 2014. The preoperative clinical data and postoperative rate of clinical remission and cyst volume changes in magnetic resonance imaging (MRI) were evaluated.

Surgical Procedure

Patients were operated with the head elevated to enhance venous drainage; the head was reflected backwards to augment gravity-assisted brain retraction. The skin incision was limited to the eyebrow starting from just lateral to the supraorbital notch. In two children younger than 2 years, a skin incision about 6 cm was made behind the hairline. Orbicularis oculi was pushed downwards and the frontalis muscle was incised in the same line as the skin incision. The pericranium was incised starting from the anterior end of the linea temporalis following retraction of the upper edge of the skin incision using fish hooks.

A small D-shaped 2.5 by 1.5 cm craniotomy was performed in the supraorbital area. The inner lip of the orbital rim and orbital prominences were drilled out, and the dura was opened in a C-shaped fashion and reflected inferiorly. Following gentle retraction of the frontal lobe, CSF was aspirated till identification of the ipsilateral optic nerve and carotid artery where arachnoid membranes in between were violated. Lilliequist's membrane was fenestrated through the optico-carotid window and widely opened. The medial cyst wall was widely fenestrated creating free communication between the cyst and prepontine cistern. Inspection of the cyst wall and prepontine cistern was further assessed using a Karl Storz® 0

and 30 degrees Lenscope (Figure 1A-F). The dura was closed watertight and the bone flap re-positioned and fixed using lactic acid absorbable mini-plates.

The outcome was both clinically and radiologically verified. The mean follow-up period was 24 months (range=6–60 months). An improvement in epilepsy was defined as a decrease in anti-convulsant dosage or an improvement in refractory seizures without changes in medication. Routine follow-up MRI images were obtained regularly at 3, 6 and 18 months postoperatively with measurement of cyst volume in mL (Figure 1G, H). Other outcome measures included the need for additional operations or any postoperative complication.

Data Analysis

Data were analyzed using both Microsoft Excel (Microsoft, Redmond, Washington) and Graphpad Prism Version 6 (GraphPad Software Inc., La Jolla, California, USA). One-way analysis of variance (one-way ANOVA) was used to evaluate differences in cyst volume. The significance value was set to 0.05.

■ RESULTS

Twenty-five patients with symptomatic temporal arachnoid cysts were operated upon in our university hospital. Thirteen patients had Galassi type II and 12 patients had Galassi type III temporal arachnoid cyst. The patients' age ranged from 1 year up to 14 years at the time of surgery (Mean=6.68 years). The follow-up period ranged from 18 to 67 months. The sex distribution was almost equal with 13 male and 12 female patients. Left-sided location was predominant and reported in 16 patients. Clinical presentation included medication non-remediable headache (80%), nausea & vomiting (64%), drug-resistant epilepsy (52%), macrocephaly (12%), papilledema (28%), motor weakness in the form of right-sided hemiparesis (12%), and cranial nerve palsy (8%), oculomotor and abducens nerve palsy each reported in one patient (Table I). Complete resolution of preoperative presentation was noted in motor weakness, cranial nerve palsies and papilledema. Nausea and vomiting also resolved in all cases except one patient with early postoperative clinical and radiological failure mandating shunt insertion. Complete subsidence of headache was noted in 50%, while 20% remained unchanged. Drug resistant epilepsy improved in 69% of patients reported as either decrease or remission in both frequency and intensity of attacks without changing medications.

Radiological Results

Postoperative MRI showed initial decrease in cyst volume as early as 3 months following surgery. Although this was only in a range of 5-12% volume reduction, the late follow-up done at 6 and 18 months continued to show further reduction reported to be significant. The preoperative cyst volume ranged from 35 to 115 mL with a mean of 66 mL. At 6 months following surgery, a substantial decrease in mean cyst volume was reported reaching down to 38.2 mL ($p<0.001$). With later MRI scheduled 18 months postoperatively, further considerable diminution of mean cyst volume reaching 24.9 mL (ranged from

Table I: Clinical Presentations and Rate of Postoperative Resolution

Clinical presentations	Frequency	%	Resolved	Improved	Unchanged
Headache	20	80	10	6	4
Nausea & Vomiting	16	64	15	0	1
Drug resistant Epilepsy	13	52	0	9	4
Macrocephaly	3	12	0	0	3
Papilledema	7	28	6	0	1
Motor weakness	3	12	2	1	0
Cranial nerve palsy	2	8	2	0	0

Table II: Postoperative Complications

Post-operative complications	No. of patients	%
Subgaleal CSF collection	5	20
CSF leakage	1	4
Seizure	1	4

CSF: Cerebrospinal fluid.

11-55 mL) has been established. Compared to preoperative volume, this was noticed as a significant reduction ($p < 0.001$) (Figure 2). Despite this sequential decrease of cyst volume in time interval, we did not report complete cyst effacement in any patient even with later follow-up exceeding 18 months.

Complications

In this series, transient subgaleal CSF collection was the most common complication (20%) (Table II). This resolved within 2 weeks following surgery with medical treatment and bandage. CSF leakage was reported in one patient who showed clinical and radiological signs of failure necessitating cysto-peritoneal shunting. Postoperative *de novo* seizure was reported in one patient controlled with medical mono-therapy.

DISCUSSION

The best surgical management of intracranial arachnoid cysts remains controversial. The advent in neuroimaging modalities led to accidental discovery of arachnoid cysts. Asymptomatic lesions are mainly conservatively managed. Most authors agree that symptoms of intracranial hypertension, treatment-resistant seizures, and focal neurological deficits are clinical criteria warranting surgical treatment (6).

Surgical interventions are varied and include endoscopic fenestration, microsurgical fenestration and cyst shunting. Cysto-peritoneal CSF diversion using a shunt is a surgical treatment modality with high success rate in terms of clinical and radiological outcome. However the long-term reliability is largely affected by possibility of infection or the need for repeated shunt revision. Arai et al. (2), in a study of 77 middle fossa arachnoid cysts and all treated by cysto-peritoneal shunt, reported a revision rate of 10.4% which is one of the

lowest among various series. They reported only one shunt infection. To avoid shunt malfunction, they preceded proximal catheter placement with outer membranectomy. They believe that an outer membrane detaches easily from the dura mater, which may cause plugging of the shunt tube. With long periods of follow-up, Zhang et al. (29) reported a shunt revision rate of 26%. Furthermore they reported symptoms of increased intracranial pressure with a shunt malfunction and nearly obliterated cyst in 13% of patients. This was considered typical shunt dependence with difficulty re-inserting the proximal catheter during revision mandating ventriculo-peritoneal shunt insertion in the majority of this group. Alexiou et al. (1) reported a need of revision in the cysto-peritoneal shunt group (67 patients) in 39% of the patients. Presence of an arachnoid cyst with an associated subdural hygroma or hematoma makes shunting not an optimum maneuver due to possible intracranial hypotension resulting from over-shunting with subsequent aggravation of subdural collection (22).

Silav et al., in their study of 16 children with symptomatic middle fossa arachnoid cysts, validated their preferred combined approach of subtemporal micro-craniotomy with microsurgical fenestration and cysto-peritoneal shunt during the same operation. Starting with microsurgery, stereoscopic observation gives the surgeon excellent depth perception, improving the safety of sharp cyst wall dissection. They believe that further insertion of a cysto-peritoneal shunt increased overall clinical and radiological success, with 18.75% shunt dysfunction rate, lower than many reported literature rate of cystoperitoneal shunt alone (23).

Li et al. studied thirteen patients with shunt dependency syndrome after previous cysto-peritoneal shunting in 358 children with temporal arachnoid cysts. Although the incidence of shunt dependency was very low, it could be a not easily curable complication. Intracranial pressure monitoring may confirm the diagnosis when no neuroimaging signs denote shunt dependency (15).

The endoscopic approach is generally a safe procedure. Despite the slowly increasing number of studies favoring endoscopic fenestration of temporal arachnoid cysts, it has some limitations. These include the difficulty in bi-manipulations using endoscopic instruments, and the need to work along the trajectory of the endoscope. Other limitations are the

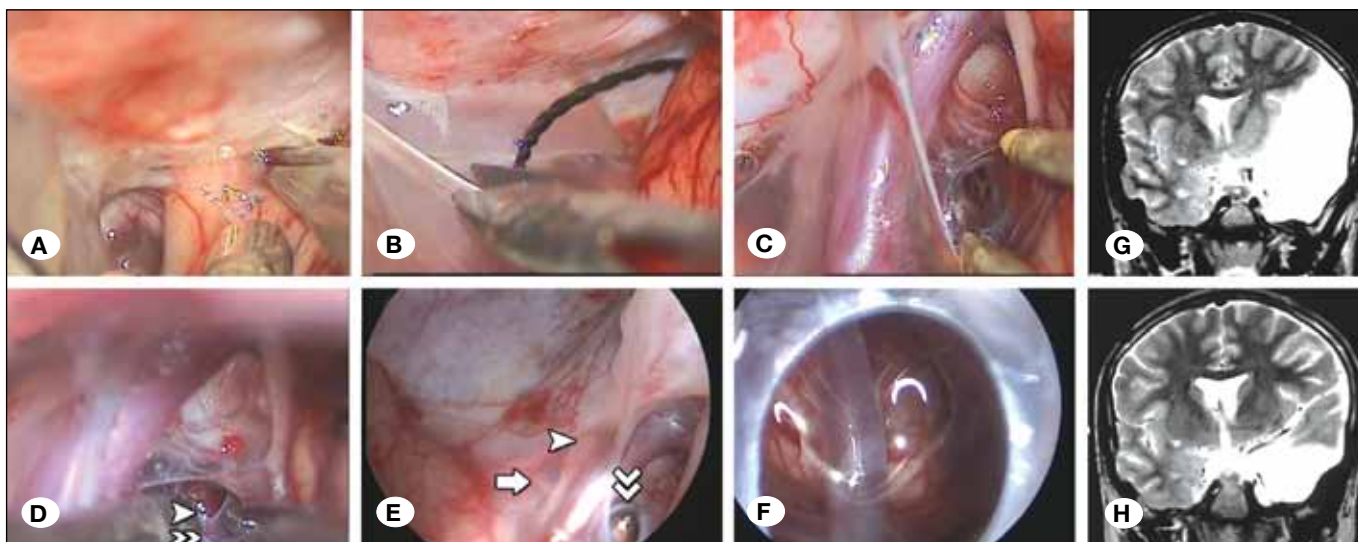


Figure 1: **A)** Intraoperative image showing dissection of arachnoid membranes around the left optic nerve. **B)** Opening of medial cyst wall by microscissors. **C)** Blunt bipolar dissection of arachnoid membranes in the optico-carotid triangle. **D)** Cutting of both the mesencephalic leaflet (double arrow head) and diencephalic leaflet (single arrow head) of Lilliequist's membrane. **E)** Endoscopic inspection within the cyst cavity showing the fenestrum in the optico-carotid triangle (double arrow head), third nerve (single arrow head) and sixth nerve (full arrow). **F)** Close-up endoscopic inspection of the fenestrum ensuring no further membranes covering the basilar artery in the prepontine cistern. **G)** Preoperative coronal T2 image of the same patient showing Galassi type II cyst. **H)** Postoperative image 18 months later with significant cyst volume reduction.

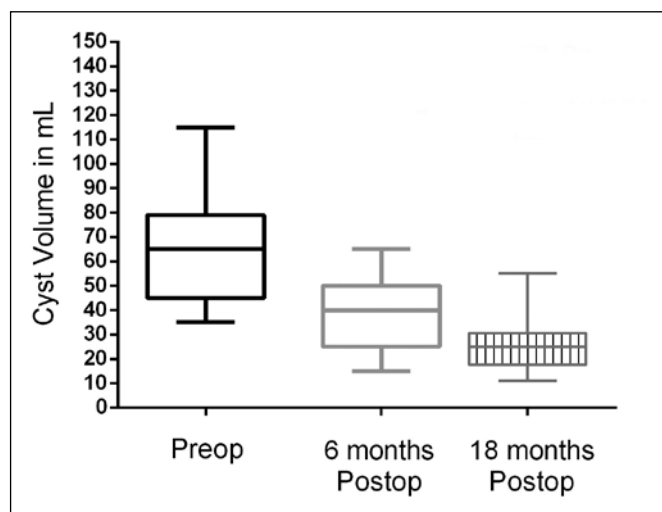


Figure 2: Pre-operative, 6 and 18 months postoperative volumes of all patients. A significant reduction of cyst volumes is observed.

tough cyst medial wall that may resist a blunt fenestration and the need to open several arachnoid membranes necessitating a change to angulated scopes (5). Karabagli and Etus (13), in their study of 20 patients who were successfully operated by pure endoscopic fenestration, reported some technical difficulties. The main concern is the presence of multiple membranes nearby the neurovascular structures requiring a complete learning curve before considering pure endoscopic fenestration as the first line. They recommended at least two fenestration sites to guarantee long-term reliability.

Couvreur et al. presented one of the largest pure endoscopic fenestration series of 34 patients with a temporal arachnoid cyst, reporting a clinical improvement rate of 76.4%. The best clinical remission was observed in symptoms of intracranial hypertension, acute neurological deficit, and macrocrania. Repeated endoscopic fenestration was necessary in 3 cases, where closure of the previous stoma was confirmed in all cases. Only one patient required late cysto-peritoneal shunt to control recurrent symptoms (4).

Xu et al., in their study of 26 patients of mixed age 16 children, evaluated the efficacy of endoscopic fenestration of temporal arachnoid cysts. The procedure was successful in their entire study group with reduction in both cyst size and at least one of the preoperative symptoms (28).

Microsurgical fenestration is one of the most preferred surgical options to treat symptomatic temporal arachnoid cysts. This has been explored by Tamburrini et al. in 2008 who published the results of a questionnaire administered to 60 pediatric neurosurgical centers regarding the preferred surgical option to treat a child with large temporal arachnoid cyst. Craniotomy and arachnoid cyst marsupialization represented the preferred surgical option (66.6%), while 28.8% of the participants suggested pure or assisted endoscopic cyst marsupialization as the primary surgical procedure. Cyst shunting was suggested by only three centers (25).

Okano and Ogiwara investigated 28 patients with middle fossa arachnoid cysts who were treated by temporal craniotomy and microsurgical fenestration. A remission in preoperative symptoms was noticed in 19 (90.5%) of 21 patients with symptomatic cysts. The cysts reduced in size in all cases and

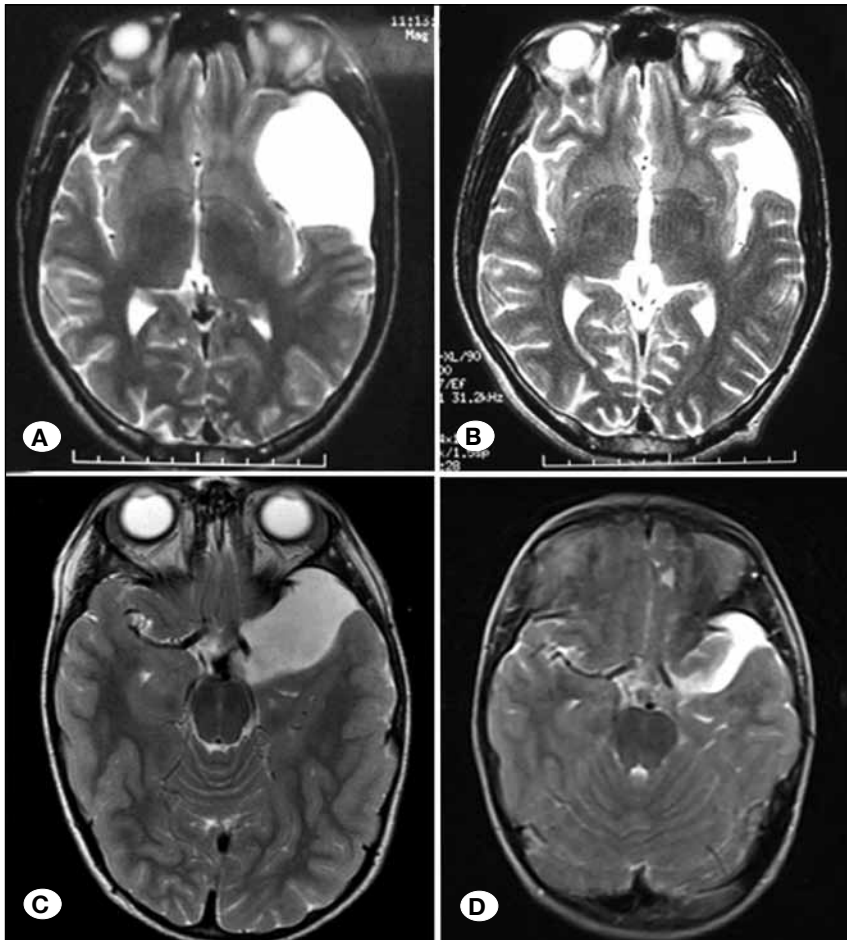


Figure 3: **A)** Preoperative T2 weighted axial image of 16 years old boy with Galassi type III left temporal arachnoid cyst. **B)** 6-month postoperative image of the same patient showing marked decrease in cyst volume. **C)** Preoperative T2-weighted axial image of a 6-year-old boy with Galassi type II left temporal arachnoid cyst. **D)** 18-month postoperative image of the same patient with reduced cyst volume.

were totally obliterated in three cases (11 %, 3/28). Subdural hygroma was identified in 23 cases (82.1 %) at the immediate postoperative period (17).

Ozgun et al. presented a comprehensive detailed description of the technique of microsurgical keyhole middle fossa arachnoid cyst fenestration. They concluded that long-term success is essentially correlated with establishing free communication of CSF to the basal cisterns (18).

In this study, we relied upon microscopic cyst fenestration through eyebrow supraorbital mini-craniotomy, assisted with endoscopic inspection in intimate proximity of both cyst wall and nearby interpenduncular and prepontine cisterns. The combined strengths of endoscopic view, microsurgical bimanual handling of arachnoid membrane layers and a mini-craniotomy are all advantages of minimal invasiveness. This allows direct access to the frequently tough medial cyst wall allowing wide fenestration using microscopic instruments, avoiding addressing the outer cyst wall which might contribute to subdural hygroma formation. This medial cyst wall is frequently associated with arachnoid membranes close to the optico-carotid window that may render endoscopic fenestration into the nearby cistern untargeted. The ultimate advantage of microsurgery is the easy access to arachnoid corridors allowing dissection/fenestration both medial

and lateral to the carotid artery. The limitations of a small craniotomy are overcome by endoscope assistance to provide in depth visualization and panoramic views not obtainable by the viewing angles of the surgical microscope.

We reported some limitations of supra-orbital endoscope assisted microsurgical fenestrations. The incision over the eyebrow is not feasible in infants less than 2 years, which requires longer incision behind the hairline yet with the same small mini-craniotomy (in 2 patients). Furthermore, the approach is not optimum with a largely pneumatized frontal air sinus.

Clinical Outcome

Patients in this study showed considerable improvement in preoperative clinical symptoms following microsurgical fenestration. Complete resolution was noted in motor weakness, cranial nerve palsies and papilledema. Nausea and vomiting were also resolved in all cases, except one patient with early postoperative clinical and radiological failure mandating shunt insertion. Complete resolution of headache was noted in 50% and drug resistant epilepsy improved in 69% of patients.

Schulz et al. (22), in a study of 24 patients treated by endoscopic or microsurgical fenestration, reported complete

resolution of cranial nerve palsy, papilledema and nausea and vomiting. They also reported 50% resolution in patients presenting with headache. In their study of 50 pediatric patients treated by microsurgical fenestration, Levy et al. (14) had a different concept in evaluating postoperative improvement. They categorized postoperative improvement into “improved, not improved and worsened” and reported improvement of motor weakness and cranial nerve palsy in 100% of patients. Headache improved in 67% of patients, while papilledema improved in 50% of their study.

Karabagli and Etus (13), in study of 20 children treated by endoscopic fenestration, had 100% resolution of the preoperative headache, motor deficits, and normalization of skull growth in patients with macrocrania. In children presenting with seizure, 50% became seizure free with reduced or ceased antiepileptic therapy, and 25% showed a significant reduction in seizure frequency.

Radiological Outcome

In our series, we observed a minimal initial decrease in cyst volume as early as 3 months, followed by further reduction at 6 and 18 months postoperatively. Despite this reduction in size, none of the patients showed complete cyst obliteration (Figure 3A-D).

Schulz et al. (22) reported reduction of Sylvian arachnoid cyst volume of more than 10%, achieved in 83.3% of all patients. The median volume of cyst was significantly reduced from 83.5 mL preoperatively, to 45.5 mL then 29.0 mL at 3.5 months and 15 months respectively. Karabagli and Etus (13), in their study of 20 patients, reported 55.5% reduction in cyst size in 18 patients in whom endoscopic fenestration succeeded. In their data, the decision on the reduction in cyst size was based on postoperative neuroimaging studies that had been performed at least 3 months following the procedure. They considered resolution of symptoms as the most reliable means to assess outcome.

Complications

We have reported some complications in our series but none of them was permanent. We could overcome the initial failure of surgery in one patient complicated by CSF leakage by insertion of a cysto-peritoneal shunt. Transient subgaleal CSF collection was reported in 20% of patients, and no tense collection was observed in any patient. Those patients were adequately controlled by diuretics and bandage, without further surgical intervention. Fortunately, subdural hygroma, which was reported in most of the other series of endoscopic or microsurgical fenestration, was not reported in our study.

Schulz et al. (22) had 6 endoscopic fenestrations (25%) in patients who presented with non-ruptured Sylvian arachnoid cyst. A small subdural hygroma was seen following fenestration at their initial postoperative MRI. The second follow-up MRI demonstrated complete resolution of the hygroma in five children and one reduced hygroma size.

Karabagli and Etus (13), in their study group of 20 patients reported one minor complication in a patient who had an asymptomatic postoperative hygroma that resolved spontane-

ously. Couvreur et al. (4) had a complication rate of 29.4%. Transient oculomotor nerve palsy, seen in 4 patients (11.8%), was explained by the compression effect of a Fogarty balloon catheter inflation. In 3 patients (8.8%), subdural hygroma occurred within 3 weeks after surgery. None of them required surgical treatment.

Xu et al., in their study of 26 patients, reported few transient complications. These included oculomotor nerve palsy in three patients (11%) and subdural hygroma in only one patient (28).

Levy et al. (14), in a larger pediatric study group (50 patients), reported pseudomeningocele as the most common complication (10%). CSF leakage occurred in 3 patients. Three patients (6%) developed transient oculomotor nerve palsy; all cases completely resolved within 8 weeks. Postoperative seizures were observed in two patients (4%). Cyst shunting was required for two patients, and lastly two patients developed subdural hygromas.

Okano and Ogiwara, in their study of 28 cases of microsurgical fenestration, reported a high rate of early postoperative hygroma in 23 patients (82.1%). Hygroma disappeared in 19 patients (83%) and reduced in size in 3 patients (13%) in the long-term follow-up. One patient (4%) required an additional subdural-peritoneal shunt (17).

CONCLUSION

Eye-brow supraorbital keyhole microsurgical fenestration for temporal arachnoid cysts can be performed with a fairly low risk of complications and yields favorable improvement in clinical and neuroimaging outcomes. This allows direct access to the frequently tough medial cyst wall, avoiding separation of the outer cyst wall which might contribute to subdural hygroma formation. The limitations are infants younger than 2 years, and older patients with a largely pneumatized frontal air sinus.

REFERENCES

- Alexiou GA, Varela M, Sfakianos G, Prodromou N: Shunting for the treatment of arachnoid cysts in children. *Neurosurgery* 67:1632-1636; discussion 1636, 2010
- Arai H, Sato K, Wachi A, Okuda O, Takeda N: Arachnoid cysts of the middle cranial fossa: Experience with 77 patients who were treated with cystoperitoneal shunting. *Neurosurgery* 39:1108-1113, 1996
- Ciricillo S, Cogen P, Harsh GR IV, Edwards M: Intracranial arachnoid cysts in children: A comparison of the effects of fenestration and shunting. *J Neurosurg* 74:230-235, 1991
- Couvreur T, Hallaert G, Van Der Heggen T, Baert E, Dewaele F, Kalala Okito JP, Vanhauwaert D, Deruytter M, Van Roost D, Caemaert J: Endoscopic treatment of temporal arachnoid cysts in 34 patients. *World Neurosurg* 84(3):734-740, 2015
- Di Rocco F, R James S, Roujeau T, Puget S, Sainte-Rose C, Zerah M: Limits of endoscopic treatment of sylvian arachnoid cysts in children. *Childs Nerv Syst* 26(2):155-162, 2010
- Duz B, Kaya S, Daneyemez M, Gonul E: Surgical management strategies of intracranial arachnoid cysts: A single institution experience of 75 cases. *Turk Neurosurg* 22(5):591-598, 2012

7. Fewel M, Levy M, McComb J: Surgical treatment of 95 children with 102 intracranial arachnoid cysts. *Pediatr Neurosurg* 25:165–173, 1996
8. Galassi E, Gaist G, Giuliani G, Pozzati E: Arachnoid cysts of the middle cranial fossa: Experience with 77 cases treated surgically. *Acta Neurochir Suppl* 42:201-204, 1988
9. Galassi E, Tognetti F, Gaist G, Fagioli L, Frank F, Frank G: CT scan and metrizamide CT cisternography in arachnoid cysts of the middle cranial fossa: Classification and pathophysiological aspects. *Surg Neurol* 17:363-369, 1982
10. Hopf NJ, Perneczky A: Endoscopic neurosurgery and endoscope-assisted microneurosurgery for the treatment of intracranial cysts. *Neurosurgery* 43(6):1330-1336, 1998
11. Kabil MS, Shahinian HK: Fully endoscopic supraorbital resection of congenital middle cranial fossa arachnoid cysts: Report of 2 cases. *Pediatr Neurosurg* 43(4):316-322, 2007
12. Kang J, Lee K, Lee I, Jeun S, Son B, Jung C, Park Y, Lee S: Shunt-independent surgical treatment of middle fossa arachnoid cysts in children. *Childs Nerv Syst* 16:111–116, 2000
13. Karabagli H, Etus V: Success of pure neuroendoscopic technique in the treatment of sylvian arachnoid cysts in children. *Childs Nerv Syst* 28(3):445-452, 2012
14. Levy ML, Wang M, Aryan HE, Yoo K, Meltzer H: Microsurgical keyhole approach for middle fossa arachnoid cyst fenestration. *Neurosurgery* 53(5):1138-1144; discussion 1144-1145, 2003
15. Li C, Yin L, Jiang T, Ma Z, Jia G: Shunt dependency syndrome after cystoperitoneal shunting of arachnoid cysts. *Childs Nerv Syst* 30(3):471-476, 2014
16. Mørkve SH, Helland CA, Amus J, Lund-Johansen M, Wester KG: Surgical decompression of arachnoid cysts leads to improved quality of life: A prospective study. *Neurosurgery* 78(5):613-625, 2016
17. Okano A, Ogiwara H: The effectiveness of microsurgical fenestration for middle fossa arachnoid cysts in children. *Childs Nerv Syst* 32(1):153-158, 2016
18. Ozgur BM, Aryan HE, Levy ML: Microsurgical keyhole middle fossa arachnoid cyst fenestration. *J Clin Neurosci* 12(7):804-846, 2005
19. Raffel C, McComb J: To shunt or to fenestrate: Which is the best surgical treatment for arachnoid cysts in pediatric patients? *Neurosurgery* 23:338-342, 1988
20. Reisch R, Perneczky A: Ten-years experience with the supraorbital subfrontal approach through an eyebrow skin incision. *Neurosurgery* 57(4 Suppl):242-255, 2005
21. Sato H, Sato N, Katayama S, Tamaki N, Matsumoto S: Effective shunt independent treatment for primary middle fossa arachnoid cyst. *Childs Nerv Syst* 7:375-381, 1991
22. Schulz M, Kimura T, Akiyama O, Shimoji K, Spors B, Miyajima M, Thomale UW: Endoscopic and microsurgical treatment of sylvian fissure arachnoid cysts-clinical and radiological outcome. *World Neurosurg* 84(2):327-336, 2015
23. Silav G, Sari R, Bolukbasi FH, Altas M, Isik N, Elmaci I: Microsurgical fenestration and cystoperitoneal shunt through preauricular subtemporal keyhole craniotomy for the treatment of symptomatic middle fossa arachnoid cysts in children. *Childs Nerv Syst* 31(1):87-93, 2015
24. Stein S: Intracranial developmental cysts in children: Treatment by cystoperitoneal shunting. *Neurosurgery* 8:647–651, 1981
25. Tamburrini G, Dal Fabbro M, Di Rocco C: Sylvian fissure arachnoid cysts: A survey on their diagnostic workout and practical management. *Childs Nerv Syst* 24(5):593-604, 2008
26. Tunes C, Flønes I, Helland C, Wilhelmsen K, Goplen F, Wester KG: Pre- and post-operative dizziness and postural instability in temporal arachnoid cyst patients. *Acta Neurol Scand* 129(5):335-342, 2014
27. Von Wild K: Arachnoid cysts of the middle cranial fossa. *Neurochirurgia (Stuttg)* 35:177–182, 1992
28. Xu S, Wang Y, Luo Q, Jiang J, Zhong C: Endoscopic fenestration of twenty-six patients with middle fossa arachnoid cyst. *J Craniofac Surg* 27(4):973-975, 2016
29. Zhang B, Zhang Y, Ma Z: Long-term results of cystoperitoneal shunt placement for the treatment of arachnoid cysts in children. *J Neurosurg Pediatr* 10:302-305, 2012