



# Comparative Analysis of Using Bone Graft, Hydroxyapatite Coralline (Biocoral®) and Porous Polyethylene (Medpor®) Implants for Cranioplasty in a Rat Model of Cranial Bone Defect

Ayhan OKUMUS<sup>1\*</sup>, Erdem GUVEN<sup>1\*\*</sup>, Ismail ERMIS<sup>1</sup>, Vakur OLGAC<sup>2</sup>, Atilla ARINCI<sup>1</sup>, Metin Erer<sup>1\*\*\*</sup>

<sup>1</sup>Istanbul University Istanbul Faculty of Medicine, Department of Plastic Surgery, Istanbul, Turkey

<sup>2</sup>Istanbul University Oncology Institute, Division of Tumor Pathology, Istanbul, Turkey

**Corresponding author:** Ayhan OKUMUS ✉ ayhan@ayhanokumus.com.tr

## ABSTRACT

**AIM:** To compare the efficacy of bone graft, hydroxyapatite coralline (Biocoral®), and porous polyethylene (Medpor®) implants for cranioplasty in a rat model of cranial bone defects.

**MATERIAL and METHODS:** Two parietal bone defects were created in each of 16 male Sprague–Dawley rats. One was repaired with a bone graft using bone removed from the contralateral defect, and the other was filled with either Medpor® or Biocoral® (each n=8, with the repair on the left in four and the right in the other four). The rats were sacrificed at either 4 or 8 weeks, and implant stability, volumetric changes, and histological parameters were compared between the three materials.

**RESULTS:** At 8 weeks, scores for bone formation ( $p=0.003$ ), healing of the defects ( $p=0.008$ ), and material resorption ( $p=0.010$ ) were higher for the bone grafts than for Biocoral® and Medpor®, whereas the fibrosis scores were significantly higher for Medpor® and Biocoral® than for the bone grafts ( $p=0.004$ ). The other parameters were similar between the three materials at 8 weeks, except for significantly higher inflammatory cell infiltration with Medpor® than with Biocoral® and bone grafts ( $p=0.005$ ).

**CONCLUSION:** Implant stability scores were similar for the three implant materials. However, there was better bone formation and healing of the defects with bone grafts, a lower risk of resorption and greater fibrosis induction with Medpor® and Biocoral®, and less volumetric reduction with Medpor®.

**KEYWORDS:** Cranioplasty, Bone graft, Medpor®, Biocoral®, Implant stability, Rats

## INTRODUCTION

Cranioplasty is considered to be necessary for patients who have undergone decompressive craniectomy; it enables the normalization of cerebrospinal fluid and cerebral blood flow, facilitates neurological improvement, and brings aesthetic benefits (1,3,7,24). The current gold standard for bone regeneration is considered to be autologous bone grafts because of their osteogenic potential, osteoinductivity, osteoconductivity, and low cost (15,33,45). However, as well

as donor site limitations and morbidity, major drawbacks of autogenous bone grafts include their propensity for resorption and risk of infection (5,8,13,16,24,39). To address these problems, various porous alloplastic grafting biomaterials have been extensively studied for their potential utility as alternative cranioplasty materials. These include hydroxyapatite cement, titanium, polymethylmethacrylate, and porous polyethylene implants (8,22,23). However, no material has been found that meets all the criteria considered ideal for repairing a bone de-

Ayhan OKUMUS  : 0000-0002-2238-8398  
Erdem GUVEN  : 0000-0002-7608-6088  
Ismail ERMIS  : 0000-0002-7786-7337

Vakur OLGAC  : 0000-0003-0497-0314  
Atilla ARINCI  : 0000-0002-3255-0184  
Metin ERER  : 0000-0002-8100-3072

fect: that it is biologically inert, non-resorbable, non-antigenic, stable, radiolucent, sufficiently hard, aesthetically pleasing, and cost-effective, with a low infection rate (24,29,31,32).

Coralline hydroxyapatite (Biocoral®) is hydroxyapatite bone cement with a chemical composition similar to that of natural bone (2,12,36,37,41). It is a synthetic porous biomaterial and a composite scaffold with an outer hydroxyapatite layer and an inner coralline core (19). It is highly resorbable and osteoconductive, and it has been shown to enable new bone formation (6,17,18,20,38). Porous polyethylene (Medpor®) is a type of plastic commonly used in cranioplasty; it has high resistance and pores 150–250 µm in diameter, which are ideal for fibro-osseous tissue growth (9,11,22,35). Biocoral® and Medpor® are frequently used in maxillofacial surgery; however, their use for cranioplasty surgery has received less research attention than more popular cranioplasty materials such as polymethyl methacrylate, which has been extensively studied, especially in comparison to the use of autogenous grafts.

Most craniofacial defects are traumatic in etiology, and a trauma large enough to necessitate cranioplasty may also involve defects that require maxillofacial reconstruction. Thus, an investigation of whether materials used for maxillofacial reconstruction (such as Medpor®, Biocoral®, and autogenous grafts) are effective for cranioplasty operations might identify a single material suitable for addressing craniofacial trauma. The aim of this study, therefore, was to compare the efficacy of bone graft, hydroxyapatite coralline (Biocoral®), and porous polyethylene (Medpor®) implants for cranioplasty in a rat model of cranial bone defects. Efficacy was measured in terms of implant stability, volumetric changes, and histological outcomes.

## ■ MATERIAL and METHODS

### Animals

Sixteen male Sprague–Dawley rats (300–350 g) were kept in a light- and temperature-controlled room with a 12-hour light–dark cycle, at a temperature of  $22.0 \pm 0.5$  °C and relative humidity of  $45.0\% \pm 10.0\%$ . The animals were fed standard rat pellets and provided with water ad libitum. The study was approved by the Scientific and Ethics Committee of Istanbul University Istanbul Faculty of Medicine Experimental Animals Research and Application Centre.

### Study Protocol

The rats were randomly allocated into two groups (each  $n=8$ ). Two parietal bone defects were created in all the rats as described in the following section; one was filled with the bone graft removed from the contralateral defect, and the other was filled, according to the group, with either Medpor® or Biocoral®. These were applied to the left defect in four animals and the right defect in the other four. Thus, the final analysis included 32 unilateral parietal bone defects repaired with bone graft ( $n=16$ ; 8 left, 8 right), Medpor® ( $n=8$ ; 4 left, 4 right), or Biocoral® ( $n=8$ ; 4 left, 4 right).

The rats were sacrificed by cervical dislocation under sodium pentothal anesthesia (intraperitoneal injection, 120 mg/kg),

half at 4 weeks after the repair and the rest at 8 weeks. The cranium of each rat was removed for examination. Cranial tissue samples were collected for comparative histological analyses of bone formation, healing of the defects, material resorption, inflammation (cell infiltration), and fibrosis.

### Cranial Bone Defect Model

To create the cranial bone defects, the rats were anesthetized with 200 mg/kg ketamine (Ketalar® flacon; Pfizer Inc., Istanbul, Turkey) and 10 mg/kg xylazine (Rompun® flacon; Bayer Inc., Germany), administered intramuscularly. The procedures were performed under sterile conditions. A midline skin incision was made along the midsagittal suture. The skin and underlying tissues were retracted bilaterally using non-sharp scissors. The periosteum was separated using a periosteal elevator to expose the extent of the parietal bones. A critically sized circular bone defect (0.5 cm in diameter, full thickness) (10) was formed on the left and right parietal bones with a high-speed drill, with continuous saline irrigation to remove the bone debris (Figure 1A). A 0.4-cm diameter, full thickness circular bone graft was prepared for each rat and used for the parietal bone defect on the contralateral side, and a 0.4-cm diameter circular Medpor® or Biocoral® implant was placed on the parietal bone defect on the ipsilateral side to the bone graft preparation (Figure 1B, C). After the placement of the cranioplasty materials, the periosteum and skin were closed separately. The rats were examined for infection, hematoma, and wound dehiscence.

### Histological Analysis

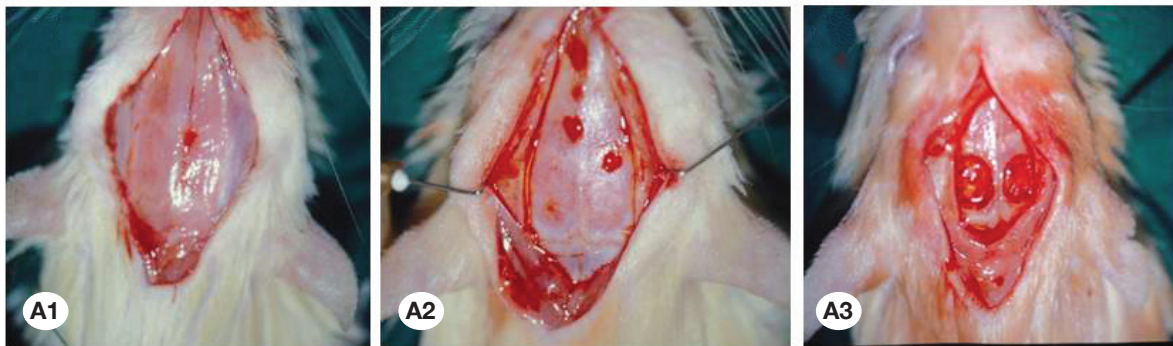
The tissue samples for histological analysis were fixed in 10% buffered formalin and embedded in paraffin for serial sectioning. Longitudinal sections 3–5 µm thick were stained with hematoxylin and eosin and evaluated for inflammatory cell infiltration, fibrosis, bone formation, healing of the defect, and material resorption in the tissue using a light microscope (ECLIPSE 80i; Nikon, Japan; 200× magnification). Scoring, using digital photographs and an imaging analysis program (analysis Five; Olympus, Tokyo, Japan), was based on the percentage area per augmentation field, as follows: 1%–30% (+), 31%–60% (++) , 61%–80% (+++) , and >80% (++++).

### Implant Characteristics

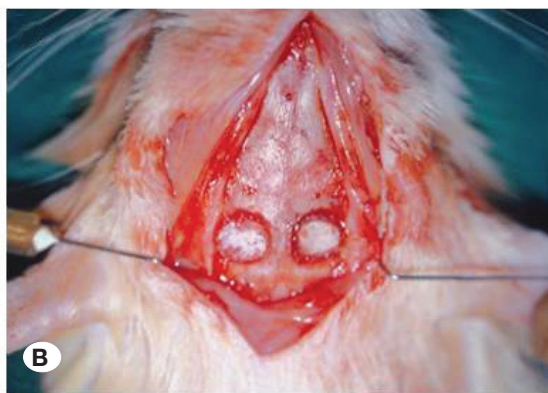
Implant stability was evaluated according to criteria based on primary osseointegration (mechanical attachment to the cortical bone) and secondary osseointegration (bone regeneration and remodeling) (42). It was graded from I to IV, as follows: I, implant attached to the bone and integrated, immobile; II, fibrous union, almost mobile or partially mobile; III, no connection between the implant and the bone, mobile; and IV, no implant detected during the autopsy. A volumetric analysis was performed by comparing the pre- vs. post-procedure volumes of cranioplasty materials.

### Statistical Analysis

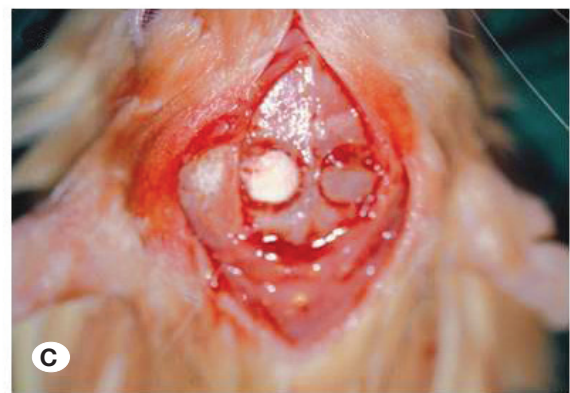The statistical analysis was performed using IBM SPSS Statistics for Windows, version 22.0 (IBM Corp., Armonk, NY). Pearson's chi-square ( $\chi^2$ ) test was used for comparisons of categorical data, and the Kruskal–Wallis test was used for the



Formation of bilateral critical size defect on parietal bones



Medpor (left) and bone graft (right)



Biocoral (left) and bone graft (right)

**Figure 1:** The surgical procedure. **A)** Creation of bilateral critical size defects on parietal bones, including lateralization of the skin and subcutaneous tissues via a midline incision (**A1**), exposure of the parietal bones via periosteum dissection (**A2**), and formation of the critical size defects in the parietal bones (**A3**). **B)** Placement of the cranioplasty materials Medpor® (left) and bone graft (right). **C)** Placement of cranioplasty materials Biocoral® (left) and bone graft (right).

analysis of parametric variables. Data are expressed as the median (range) or as number (percentage), as appropriate. A  $p$ -value  $<0.05$  was considered statistically significant.

## RESULTS

### Stability

Grade I implant stability (i.e., integrated and immobile) for the Medpor®, Biocoral®, and bone graft implants was observed in 75.0%, 75.0%, and 62.5% of bone defects, respectively, at 4 weeks and in 100.0%, 100.0%, and 87.5% of bone defects at 8 weeks. There was no significant difference in implant stability between the three materials (Table I).

### Volumetric Analysis

There was no change between the preoperative and postoperative volume of the Medpor® implants. The volume of the Biocoral® implants decreased, and those of the bone grafts decreased to an even greater extent. Thus, the volumetric analysis showed the best results with Medpor®, followed by Biocoral® and then bone grafts.

### Histological Assessment

The postoperative healing was uneventful in all animals. One rat experienced an infection, but there were no other complications such as hematoma or wound dehiscence throughout the entire study period. At 4 weeks, the histological assessment showed significantly higher scores for all parameters except fibrosis for the bone grafts than for the Biocoral® and Medpor® implants (with  $p$ -values in the range 0.003–0.024). At 8 weeks, the scores for bone grafts were significantly higher only for bone formation ( $p=0.003$ ), healing of the defect ( $p=0.008$ ), and material resorption ( $p=0.010$ ). At 8 weeks, Medpor® was associated with significantly higher inflammatory cell infiltration scores than those for Biocoral® and bone grafts ( $p=0.005$ ), and fibrosis scores were significantly higher for Medpor® and Biocoral® than for the bone grafts ( $p=0.004$ ). With the exception of inflammatory cell infiltration at 8 weeks, the Medpor® and Biocoral® groups were similar for all the parameters (Table II, Figures 2–4).

### Microbiological Evaluation

One of the rats sacrificed at 8 weeks with a right-sided Medpor®

**Table I:** Implant Stability Scores in Unilateral Bone Defects (n=32)

	4 <sup>th</sup> week			8 <sup>th</sup> week		
	Medpor (n=4)	Biocoral (n=4)	Bone graft (n=8)	Medpor (n=4)	Biocoral (n=4)	Bone graft (n=8)
<b>Implant stability, n(%)</b>						
I (integrated-immobile)	3 (75.0)	3 (75.0)	5 (62.5)	4 (100.0)	4 (100.0)	7 (87.5)
II (fibrous union- partially mobile)	1 (25.0)	1 (25.0)	3 (37.5)	0 (0.0)	0 (0.0)	0 (0.0)
III (mobile)	0 (0.0)	0 (0.0)	0 (0.0)	0 (0.0)	0 (0.0)	0 (0.0)
IV (no implant)	0 (0.0)	0 (0.0)	0 (0.0)	0 (0.0)	0 (0.0)	1 (12.5)
p value		0.865			0.587	

Pearson Chi-Square test.

**Table II:** Histological Analysis Findings

Parameters	4 <sup>th</sup> week			8 <sup>th</sup> week		
	Median (min-max)			Median (min-max)		
Bone formation	Bone graft 2 (2-3)	Biocoral 1 (1-2)	Medpor 1 (1-2)	Bone graft 4 (3-4)	Biocoral 2 (2-3)	Medpor 2 (2-3)
	<b>p=0.009</b>			<b>p=0.003</b>		
Healing of defect	Bone graft 2.5 (2-3)	Biocoral 1.5 (1-2)	Medpor 1.5 (1-2)	Bone graft 4 (3-4)	Biocoral 2.5 (2-3)	Medpor 2 (2-3)
	<b>p=0.024</b>			<b>p=0.008</b>		
Material resorption	Bone graft 3 (2-3)	Biocoral 1 (0-2)	Medpor 0.5 (0-1)	Bone graft 2 (1-3)	Medpor 1 (0-2)	Biocoral 0.5 (0-1)
	<b>p=0.003</b>			<b>p=0.010</b>		
Inflammatory cell infiltration	Bone graft 3 (2-4)	Biocoral 2 (1-2)	Medpor 1.5 (1-2)	Medpor 3 (3-4)	Biocoral 2 (1-2)	Bone graft 2 (1-2)
	<b>p=0.010</b>			<b>p=0.005</b>		
Fibrosis	Bone graft 3 (2-3)	Biocoral 2 (1-2)	Medpor 1.5 (1-3)	Medpor 3.5 (3-4)	Biocoral 3 (2-4)	Bone graft 2 (1-2)
	<b>p=0.067</b>			<b>p=0.004</b>		

Kruskal Wallis test.

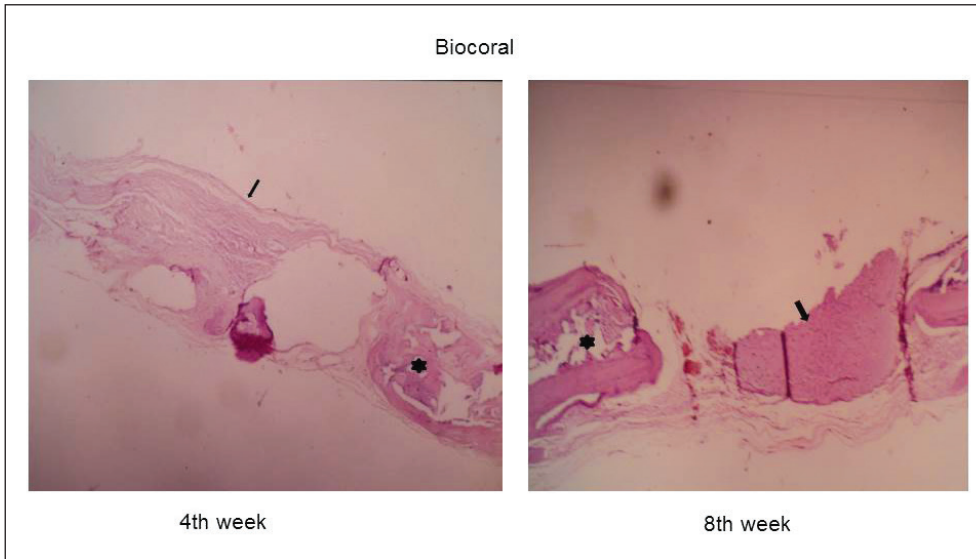
implant experienced an infection with purulent characteristics and a positive culture for *Staphylococcus aureus* growth in an aerobic feeding environment. This growth was limited to both the bone graft and the Medpor® placement areas, so it was considered to have been acquired intra operatively. In this rat, no bone graft was detected and the Medpor® implant was completely mobile.

## DISCUSSION

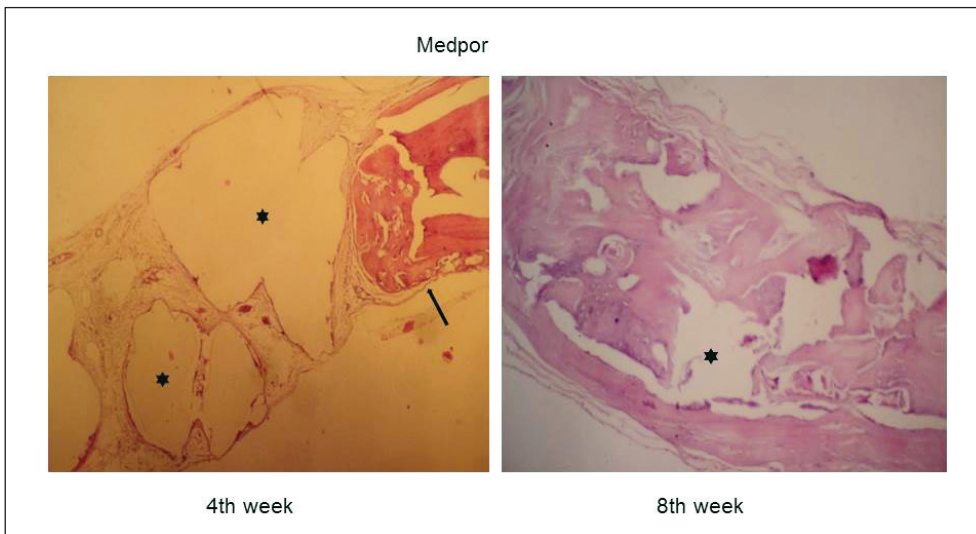
This study compared the efficacy of using Medpor®, Biocoral®, and bone graft implants for cranioplasty in a rat model of cranial bone defects. The results showed better bone formation

and healing of defects for bone grafts as compared with the other implant materials, although there was lower fibrosis induction and a higher risk of material resorption. Compared to the other implant materials, Medpor® was associated with higher inflammatory cell infiltration scores and less volumetric reduction.

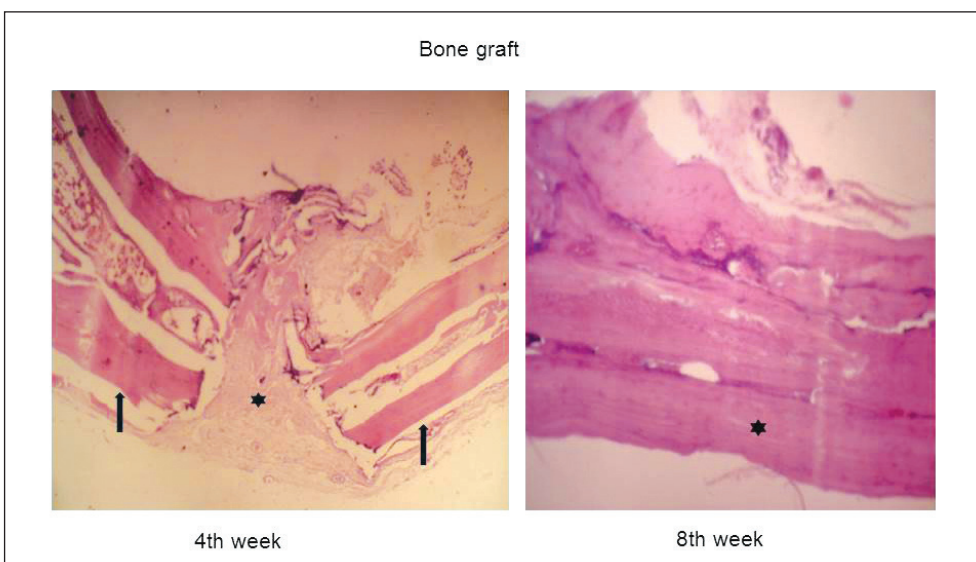
Bone grafts showed the highest risk of resorption and postoperative volume reduction in our study. This finding was consistent with reports that there-implantation of autologous skull bone is challenging because of its propensity for resorption and its inability to tolerate physiologic loading (24). This is important given that the skull bone itself has a higher



**Figure 2:** Histological findings for the parietal bone defects repaired with Biocoral®. At 4 weeks, new bone trabeculae were developing from the host bone (asterisk) toward the defect area within the fiber-rich connective tissue (arrow). At 8 weeks, the lamellar bone tissue (asterisk) filled almost half of the defect area, along with fibrous tissue (arrow) formed by young mesenchymal cells in the other defect areas (Hematoxylin and Eosin; ×100).



**Figure 3:** Histological findings for the parietal bone defects repaired with Medpor®. At 4 weeks, graft particles were observed in the fiber-rich loose connective tissue (asterisks), and there was new bone formation (arrow) starting from the host epiphyses. At 8 weeks, the residual graft material (asterisk) in the defect area was surrounded by new bone formation (Hematoxylin and Eosin; ×100).



**Figure 4:** Histological findings for the parietal bone defects repaired with bone grafts. At 4 weeks, lamellar bone tissue (arrows) filled two-thirds of the defect area, with active connective tissue (asterisk) observed in the central small area. At 8 weeks, lamellar bone tissue (asterisk) filled the entire defect area (Hematoxylin and Eosin; ×100).

propensity for resorption than other parts of the body, which increases the likelihood of the need for repeat surgery when it is used as an implant in cranioplasty (24).

The Medpor® cranioplasty implants showed favorable outcomes for volumetric change, risk of resorption, and the induction of fibrosis. This was consistent with experimental studies that demonstrated that porous high-density polyethylene implants permitted the ingrowth of fibro-osseous tissue in one month, which is important for improved tissue strength and reducing the risk of infection (9,11,22,25,35). Medpor® is a non-antigenic, non-resorbable, and biologically inert material strong enough to enable protection (26). It is considered to be an excellent restorative material for cranial reconstruction in neurosurgery and maxillofacial surgery, with good cosmetic results and low complication rates (22,25,30,44). However, bone graft was the material associated with the most favorable scores for bone formation and healing of defects in our experimental model. This provides further support for autologous cranioplasty after decompressive craniectomy being the gold standard approach in clinical practice. Bone grafts have the ability to reincorporate into the skull (osseointegration), the allow growth of the skull, and they show alower risk of rejection (22).

Biocoral® is a porous biocompatible substitute for bone grafts. When used in animal models, it has been reported to be readily incorporated and gradually replaced by bone through the creation of a framework structure for osteoprogenitor cells, as well as improving regeneration and the healing process (6,8,14,17,18,38). Animal studies have shown that Biocoral® has both osteoinductive and osteoconductive properties (12,21,34,36), and hydroxyapatite compounds have been reported to have the potential for post-fracture self-repair (41).

Biocoral® was not found to be superior to Medpor® in any of parameters studied in the present study, and all three implant materials achieved similar implant stability. The use of porous nano-hydroxyapatite/coral blocks coated with rhVEGF165 in critical-size alveolar bone defects in vivo has been shown to promote neovascularization at the early stage of bone healing, but without enhancing bone formation (8). In addition, hydroxyapatite cements have been reported to be associated with the risk of early fragility; this is due to pulsations of the underlying intradural contents, which interfere with the crystallization of the cement, resulting in micro fragmentation and alloplast fracture (22,27,41). Notably, porous ceramic implants composed of hydroxyapatite on calcium carbonate have also been shown to degrade more rapidly in bone defects than in soft tissue (40). However, it should be noted that whereas early animal model studies of porous polyethylene suggested that the porosity of the material allowed bone ingrowth (osteoconduction) (4,28), more recent in vivo studies have confirmed soft tissue growth with Medpor® implants but have failed to demonstrate the presence of bony ingrowth (22,43).

Two limitations to this study should be considered. First, the small number of animals may have prevented the implant stability scores from achieving statistical significance. Second, although craniomaxillofacial utility was the primary criterion in

the selection of materials in this study, the lack of investigation of materials more commonly used for cranioplasty (such as methacrylate) limited the findings that could be achieved.

## ■ CONCLUSION

This comparison of the utility of different implant materials for cranioplasty in a rat cranial bone defect model showed similar implant stability scores for the three implant materials investigated; however, there was better bone formation and healing of the defects with bone grafts, a lower risk of resorption and higher fibrosis induction with both Medpor® and Biocoral®, and the least volumetric reduction with Medpor®. Future clinical studies are needed to establish which restorative material might serve as a potential biological material for cranial reconstruction in neurosurgery, improving bone regeneration with good cosmetic results and low complication rates.

## ■ ACKNOWLEDGEMENTS

The current addresses for the authors with asterisk(s) are as follows:

\*Private Aesthetic Plastic and Reconstructive Surgery Office, Bursa, Turkey

\*\*Private Aesthetic Plastic and Reconstructive Surgery Office, Istanbul, Turkey

\*\*\*Retired Senior Faculty Member of Istanbul University Istanbul Faculty of Medicine, Istanbul, Turkey

## ■ REFERENCES

1. Aarabi B, Hesdorffer DC, Ahn ES, Aresco C, Scalea TM, Eisenberg HM: Outcome following decompressive craniectomy for malignant swelling due to severe head injury. *J Neurosurg* 104:469-479, 2006
2. Baker SB, Weinzweig J, Kirschner RE, Bartlett SP: Applications of a new carbonated calcium phosphate bone cement: Early experience in pediatric and adult craniofacial reconstruction. *Plast Reconstr Surg* 109:1789-1796, 2002
3. Bullock MR, Chesnut R, Ghajar J, Gordon D, Hartl R, Newell DW, Servadei F, Walters BC, Wilberger J; Surgical Management of Traumatic Brain Injury Author Group: Surgical management of traumatic parenchymal lesions. *Neurosurgery* 58 Suppl 3:S25-S46, 2006
4. Cestero HJ Jr, Salyer KE, Toranto IR: Bone growth into porous carbon, polyethylene, and polypropylene prostheses. *J Biomed Mater Res* 9:1-7, 1975
5. Chengy K, Weng H, Yang JT, Lee MH, Wang TC, Chang CN: Factor affecting graft cranioplasty. *J Clin Neurosci* 15:1115-1119, 2008
6. Christmas NJ, Van Quill K, Murray TG, Gordon CD, Garonzik S, Tse D, Johnson T, Schiffman J, O'Brien JM: Evaluation of efficacy and complications: Primary pediatric orbital implants after enucleation. *Arch Ophthalmol* 118:503-506, 2000
7. Citardi MJ, Friedman CD: Nonvascularized autogenous bone grafts for craniofacial skeletal augmentation and replacement. *Otolaryngol Clin North Am* 27:891-910, 1994

8. Du B, Liu W, Deng Y, Li S, Liu X, Gao Y, Zhou L: Angiogenesis and bone regeneration of porous nano-hydroxyapatite/coralline blocks coated with rhVEGF165 in critical-size alveolar bone defects in vivo. *Int J Nanomedicine* 10:2555-2565, 2015
9. Duman H, Deveci M, Uygur F, Sengezer M: Reconstruction of contour and anterior wall defects of frontal bone with a porous polyethylene implant. *J Craniomaxillofac Surg* 27:298-301, 1999
10. Eldesoqi K, Henrich D, El-Kady AM, Arbid MS, Abd El-Hady BM, Marzi I, Seebach C: Safety evaluation of a bioglass-poly-lactic acid composite scaffold seeded with progenitor cells in a rat skull critical-size bone defect. *PLoS One* 9: e87642, 2014
11. Frodel JL, Lee S: The use of high-density polyethylene implants in facial deformities. *Arch Otolaryngol Head Neck Surg* 124:1219-1223, 1998
12. Goshima J, Goldberh VM, Caplan AL: The Origin of bone form in composite grafts of porous calcium phosphate ceramic loaded with marrow cells. *Clin Otrhop Relat Res* 269:274-283, 1991
13. Greenwald AS, Boden SD, Goldberg VM, Khan Y, Laurencin CT, Rosier RN: Bone graft substitutes: Facts, fictions and applications. *J Bone Joint Surg Am* 83 Suppl 2, Pt 2:98-103, 2001
14. Holmes RE, Mooney V, Bucholz R, Tencer A: A coralline hydroxyapatite bone graft substitute. *Clin Orthob* 188:252, 1984
15. Inoda H, Yamamoto G, Hattori T: rh-BMP2-induced ectopic bone for grafting critical size defects: a preliminary histological evaluation in rat calvariae. *Int J Oral Maxillofac Surg* 36:39-44, 2007
16. Iwama T, Yamada J, Imai S, Shinoda J, Funakoshi T, Sakai N: The use of frozen autogenous bone flaps in delayed cranioplasty revisited. *Neurosurgery* 52:591-596, 2003
17. Jordan DR, Bawazeer A: Experience with 120 synthetic hydroxyapatite implants (FCI3). *Ophthal Plast Reconstr Surg* 3:184-190, 2001
18. Jordan DR, Klapper S: A new titanium peg system for use in hydroxyapatite orbital implants. *Ophthal Plast Reconstr Surg* 16:5:380-387, 2000
19. Koeter S, Tigchelaar SJ, Farla P, Driessen L, van Kampen A, Buma P: Coralline hydroxyapatite is a suitable bone graft substitute in an intra-articular goat defect model. *J Biomed Mater Res B Appl Biomater* 90:116-122, 2009
20. Koo KT, Polimeni G, Qahash M, Kim CK, Wikesjo UM: Periodontal repair in dogs: Guided tissue regeneration enhances bone formation in sites implanted with a coral-derived calcium carbonate biomaterial. *J Clin Periodontol* 32:104-110, 2005
21. Kurashina K, Kurita H, Wu Q, Ohtsuka A, Kobayashi H: Ectopic osteogenesis with biphasic ceramics of hydroxyapatite and tricalcium phosphate in rabbits. *Biomaterials* 23:407-412, 2002
22. Lam S, Kuether J, Fong A, Reid R: Cranioplasty for large-sized calvarial defects in the pediatric population: A review. *Craniomaxillofac Trauma Reconstr* 8:159-170, 2015
23. Lee BS, Min KS, Lee MS, Kim YG, Kim DH: Comparison with subcutaneous abdominal preservation and cryoconservation using autologous bone flap after decompressive craniectomy. *Korean J Neurotrauma* 8:21-25, 2012
24. Lee SH, Yoo CJ, Lee U, Park CW, Lee SG, Kim WK: Resorption of autogenous bone graft in cranioplasty: Resorption and reintegration failure. *Korean J Neurotrauma* 10:10-14, 2014
25. Lin AY, Kinsella CR Jr, Rottgers SA, Smith DM, Grunwaldt LJ, Cooper GM, Losee JE: Custom porous polyethylene implants for large-scale pediatric skull reconstruction: Early outcomes. *J Craniofac Surg* 23:67-70, 2012
26. Liu JK, Gottfried ON, Cole CD, Dougherty WR, Couldwell WT: Porous polyethylene implant for cranioplasty and skull base reconstruction. *Neurosurg Focus* 16:ECP1, 2004
27. Losee JE, Karmacharya J, Gannon FH, Slemp AE, Ong G, Hunenko O, Gorden AD, Bartlett SP, Kirschner RE: Reconstruction of the immature craniofacial skeleton with a carbonated calcium phosphate bone cement: Interaction with bioresorbable mesh. *J Craniofac Surg* 14:117-124, 2003
28. Maas CS, Merwin GE, Wilson J, Frey MD, Maves MD: Comparison of biomaterials for facial bone augmentation. *Arch Otolaryngol Head Neck Surg* 116:551-556, 1990
29. Manley GT: Introduction: Decompressive craniectomy for trauma and cerebrovascular disease. *Neurosurg Focus* 26: E1, 2009
30. Marlier B, Kleiber JC, Bannwarth M, Theret E, Eap C, Litre CF: Reconstruction of cranioplasty using medpor porous polyethylene implant. *Neurochirurgie* 63:468-472, 2017
31. Matsuno A, Tanaka H, Iwamuro H, Takanashi S, Miyawaki S, Nakashima M, Nakaguchi H, Nagashima T: Analyses of the factors influencing bone graft infection after delayed cranioplasty. *Acta Neurochir (Wien)* 148:535-540, 2006
32. Miyake H, Ohta T, Tanaka H: A new technique for cranioplasty with L-shaped titanium plates and combination ceramic implants composed of hydroxiapatite and tricalcium phosphate (ceratite). *Neurosurgery* 46:414-418, 2000
33. Mokbel N, Bou SC, Matni G, Naaman N: Healing patterns of critical size bony defects in rat following bone graft. *Oral Maxillofac Surg* 12:73-78, 2008
34. Nagahara K, Isogai M, Shibata KI, Meenaghan MA: Osteogenesis of hydroxyapatite and tricalcium phosphate used as a bone substitute. *Int J Oral Maxillofac Implant* 7:72-79, 1992
35. Niechajev I: Facial reconstruction using porous high-density polyethylene (medpor): Long-term results. *Aesthet Plast Surg* 36:917-927, 2012
36. Ohgushi H, Goldberg VM, Caplan AI: Repair of bone defects with marrow cells and porous ceramic: Experiments in rats. *Acta Orthop Scand* 60:334-339, 1989
37. Oonishi H, Iwaki Y, Kin N, Kushitani S, Murata N, Wakitani S, Imoto K: Hydroxyapatite in revision of total hip replacements with massive acetabular defects: 4- to 10-year clinical results. *J Bone Jt Surg* 79: 87-92, 1997
38. Papacharalambous SK, Anastasoff KI: Natural coral skeleton used as onlay graft for contour augmentation of the face. A preliminary report. *Int J Oral and Maxillofac Surg* 22:260-264, 1993

39. Piitulainen JM, Kauko T, Aitasalo KM, Vuorinen V, Vallittu PK, Posti JP: Outcomes of cranioplasty with synthetic materials and autologous bone grafts. *World Neurosurg* 83:708-714, 2015
40. Pollick S, Shors EC, Holmes RE, Kraut RA: Bone formation and implant degradation of coralline porous ceramics placed in bone and ectopic sites. *J Oral Maxillofac Surg* 53:915-922, 1995
41. Stefini R, Esposito G, Zanotti B, Iaccarino C, Fontanella MM, Servadei F: Use of "custom made" porous hydroxyapatite implants for cranioplasty: Postoperative analysis of complications in 1549 patients. *Surg Neurol Int* 4:12, 2013
42. Swami V, Vijayaraghavan V, Swami V: Current trends to measure implant stability. *J Indian Prosthodont Soc* 16:124-130, 2016
43. Tark WH, Yoon IS, Rah DK, Park BY, Kim YO: Osteoconductivity of porous polyethylene in human skull. *J Craniofac Surg* 23:78-80, 2012
44. Wang JC, Wei L, Xu J, Liu JF, Gui L: Clinical outcome of cranioplasty with high-density porous polyethylene. *J Craniofac Surg* 23:1404-1406, 2012
45. Yazdi FK, Mostaghni E, Moghadam SA, Faghihi S, Monabati A, Amid R: A comparison of the healing capabilities of various grafting materials in critical-size defects in guinea pig calvaria. *Int J Oral Maxillofac Implants* 28:1370-1376, 2013