



Radiation-Induced Meningiomas: A Series of Four Consecutive Patients and a Review of Literature

Anas ABDALLAH¹, Hasan Burak GUNDUZ², Murad ASILTURK², Ozden Erhan SOFUOGLU², Bilge BILGIC³, Erhan EMEL², Betül GULER ABDALLAH⁴

¹Bezmialem Vakif University, Department of Neurosurgery, Istanbul, Turkey

²Bakirkoy Research and Training Hospital for Neurology Neurosurgery, and Psychiatry, Department of Neurosurgery, Istanbul, Turkey

³Istanbul University, Faculty of Medicine, Department of Pathology, Istanbul, Turkey

⁴Bakirkoy Research and Training Hospital for Neurology Neurosurgery, and Psychiatry, Department of Neurology-Intensive Care Unit, Istanbul, Turkey

Corresponding author: Anas ABDALLAH ✉ abdallahanas@hotmail.com

ABSTRACT

AIM: To assess the clinical outcomes of treatment for radiation-induced meningiomas.

MATERIAL and METHODS: Medical records were retrospectively reviewed for all cranial meningioma cases that were diagnosed and/or underwent surgery at our hospital from 2009 to 2016. All radiation-associated meningioma patients constituted the core sample for this study.

RESULTS: This series included one female and three male patients, with a mean age of 47.3 ± 16.3 years. The mean preoperative course was <3 months. The most common symptom was headache (100%) and three patients had alopecia and thin scalp skin. The mean of the age at which they underwent radiotherapy was 18.5 ± 13.7 years. The mean latency period was 19.2 ± 7.4 years. Initial malignancies included two patients with desmoplastic medulloblastomas (13-year-old female, 65 Gy), (11-year-old male, 54 Gy) and a patient with grade II oligodendroglioma treated with 30 Gy. A male patient received low-dose radiotherapy for chronic otitis at 10 years old. Histopathological examinations revealed the following: 1) fibroblastic-grade I, Ki-67 2%–3%, 25.5 years latency; cerebellopontine angle, 2) atypical meningioma grade II, Ki-67 8%, 21 years, frontal; and 3) transitional grade I, Ki-67 3%–4%, 11 years, frontal. The fourth patient had three radiation-induced meningiomas and 27 radiation-induced cavernomas, and was treated using a gamma knife. The mean follow-up period was 34.8 ± 39.4 months. One patient had rhinorrhea and another experienced a cerebrospinal fluid fistula. Both underwent an additional operation. The former died because of meningitis on postoperative day 31.

CONCLUSION: Most radiation-induced meningiomas are low-grade, but they have a high trend of recurrence. Close follow-up and yearly magnetic resonance imaging would minimize the morbidity rate. To reduce fatal complications, surgery should be planned in conjunction with plastic surgeons.

KEYWORDS: Desmoplastic medulloblastoma, Oligodendroglioma, Radiation-induced meningioma, Radiation-induced cavernoma, Radiotherapy

ABBREVIATIONS: **ADC:** Apparent diffusion coefficient, **ALL:** Acute lymphoblastic leukemia, **ANOVA:** Analysis of variance, **ChT:** Chemotherapy, **cm:** Centimeter, **CNS:** Central nervous system, **CPA:** Cerebellopontine angle, **CSF:** Cerebrospinal fluid, **CT:** Computed tomography, **ER:** Emergency department, **FLAIR:** Fluid-attenuated inversion recovery, **Gy:** Gray (100 rad), **GTR:** Gross-total resection, **HD:** High dose, **HE:** Hematoxylin and Eosin, **HPF:** High power field, **Ki-67:** proliferation labeling index, **LD:** Low dose, **MD:** Intermediate dose, **MRI:** Magnetic Resonance Imaging, **OR:** Odd ratio, **p:** Probability value, **RIC:** Radiation-induced cavernous hemangioma, **RIM:** Radiation-induced meningioma, **RIN:** Radiation-induced neoplasm, **RTP:** Radiotherapy, **SAH:** Subarachnoid hemorrhage, **SWI:** Susceptibility-weighted imaging, **WHO:** World Health Organization.

Anas ABDALLAH  : 0000-0003-3600-089X

Hasan Burak GUNDUZ  : 0000-0003-0020-7928

Murad ASILTURK  : 0000-0002-9782-0624

Ozden Erhan SOFUOGLU  : 0000-0001-7560-7331

Bilge BILGIC  : 0000-0001-9231-1743

Erhan EMEL  : 0000-0002-0584-9164

Betül GULER ABDALLAH  : 0000-0003-0937-831X

■ INTRODUCTION

Except for malignant hematologic tumors, which regress with chemotherapy and radiotherapy, most malignant tumors in children are aggressive. These aggressive tumors are generally treated with complete resection followed by adjuvant radiation therapy (RTP). The long-term side effects of neural tissue irradiation include multiple neurological side effects and induce new central nervous system (CNS) neoplasms (14). Reports describe the development of multiple tumor types after curative cranial radiotherapy, including cavernomas, meningiomas, sarcomas, glial tumors, astrocytomas, clear-cell carcinoma of the kidney, squamous carcinoma, papillary urothelial carcinoma in the bladder, and schwannomas. However, radiation-induced meningioma (RIM) is the most common brain neoplasm caused by ionizing radiation (2,51), probably because most patients with RTP-treated malignant intracranial processes rarely survive long enough to develop a secondary malignancy. Although RIM are more common in adult patients than in children, as confirmed in our exhaustive literature review, most authors suggest that pediatric RIMs are more aggressive, have higher rates of recurrence, and present with unusual histological findings (2,9).

Although the description of RIM is not standardized, the most common diagnostic criterion is a meningioma occurring within a previously radiated field after a defined latency period (63). The clinical behavior of RIMs differs from that of primary meningiomas (9,21); they are more aggressive, tend to recur, and also tend to form multiple tumors. To date, hundreds of radiation-induced neoplasms (RIN) have been reported. However, there is no well-established standard for follow-up surveillance for patients receiving radiotherapy. It is proven that there is a relationship between low-dose radiation and a long latency period (12,63). Genetic predisposition and additional chemotherapy are also thought to play important roles in reducing the latency periods of RIN.

According to the literature, children with medulloblastoma or acute lymphoblastic leukemia (ALL), treated with radiotherapy after surgery, are more sensitive to the development of RIMs than children with other types of malignant tumors (45,58,63,64). This study evaluates the outcomes of surgical and stereotactic radiosurgical treatment in four consecutive cases of RIMs and presents a review of the relevant literature.

■ MATERIAL and METHODS

Design of the Study

This retrospective study was approved by the medical ethics committee of our hospital (decision number 576/2015). Written informed consent was obtained from the patients and their first-degree relatives for the publication of their cases and accompanying images.

Our Experience and Criteria for RIMs

Medical records were retrospectively reviewed to identify all cases of cranial meningiomas (n=389) diagnosed and/or surgically treated in the Department of Neurosurgery of our

hospital between 2009 and 2016. The core sample for this study comprised all RIM patients (n=4). Tumors identified as RIMs in our study met the following criteria:

- 1) They occurred in the RTP field.
- 2) They were not present prior to irradiation as confirmed by magnetic resonance imaging (MRI) at the initial diagnosis prior to surgery and RTP.
- 3) There was a delay of >5 years from the time of treatment to the appearance of the tumor.
- 4) The induced lesion was histologically distinct from the originally irradiated tumor (three tumors that developed after RTP for anaplastic and atypical meningiomas were excluded from this study),
- 5) The patient did not have a genetic disease such as neurofibromatosis type II or Gorlin's syndrome, or a condition predisposing them to secondary malignancies (8,21,63).

Patient characteristics, clinical presentation, primary malignancies, radiation doses, latency periods, histopathological findings, and surgical outcomes are shown in Table I.

Selection of Articles and Literature Review

Two of our authors (AA and BGA) conducted a systematic literature search for "radiation-induced meningioma", "radiation-associated meningioma", and "secondary neoplasms after radiation therapy" in the PUBMED, MEDLINE, and GOOGLE SCHOLAR databases up to April 1, 2017. The search terms included "radiation-induced meningioma" and any of the following terms: "meningioma," "radiotherapy-induced," "secondary neoplasms after radiation therapy," and "radiation-induced."

We obtained the full text of all the articles that were potentially eligible for inclusion in our review (n=276), and 34 articles were excluded due to duplication. The references listed in all potentially eligible articles were inspected to identify other eligible articles. Table II (Available only in online version) lists 242 articles. However, not all these references were original studies. We utilized reviews to minimize the number of references in this article, per the journal's requirements. Review articles that did not report original data were excluded, although their references were checked for other eligible articles. This review only included original articles written in English. There were no limitations on the publication date.

Patient characteristics, such as patient age and sex at diagnosis, primary lesion, latency period from RTP to secondary meningioma diagnosis, total radiation dosage and chemotherapy for the primary tumor, histopathology of the primary brain tumor and secondary meningioma, location, therapy, and follow-up periods after secondary meningioma, are presented in Table II (Available only in online version).

Statistical Analysis

All data are expressed as the mean±standard deviation with the range shown in parentheses. After a review of all RIM patients reported in the literature, differences between groups

Table 1: Baseline Clinical Characteristics, Clinical Presentation, Latency Periods, RTP dose at Cranial and Outcomes of Treatment in Three Operated RIMs and One Patient With Multiple RIMs and Multiple RICs Who Was Treated Using Stereotactic Radiosurgery

Case	Clinical Presentation	Age (years)/ Sex	Location	Primary Disease/ Latency period (years)	RTP Dose (Gy)	Surgical Approach; Postoperative Course; Pathology	Survival after Surgery
1	Headache, unsteady gait, nausea and vomiting of 3 months.	38/F	Right CPA	Desmoplastic medulloblastoma/ 25.5	65	GTR; discharged on PO 3 rd day; recovered without complications; fibroblastic meningioma WHO grade I; on her PO 38 th month-visit no recurrence was detected.	Alive; 38 mns
2	Swelling in the right anterior frontal region of three months; Headache, nausea and vomiting of 1 month and seizure.	32/M	Right frontal	Desmoplastic medulloblastoma/ 21	54	GTR; discharged on PO 10 th day; recovered; atypical meningioma WHO grade II; on PO 4 th month repair operation for subcutaneous CSF fistula; on PO 6 th month he received adjunct RTP; on his PO 89 th month-visit no recurrence was detected.	Alive; 89 mns
3	Seizure and headache in the same day.	50/M	Right frontal	Oligodendroglioma WHO grade II/ 11	30	GTR; on PO 2 nd day, rhinorrhea (+). Even the lumbar drainage system was set up, rhinorrhea did not stop. Repair operation had done. On PO20 th day, the patient experienced meningitis and deterioration of his neurological status. On his PO 31 st , the patient had lost; transitional meningioma WHO grade I.	Dead; 31 days
4	Severe headache, unsteady gait, dysarthria, nausea and vomiting, impairment of his consciousness of a few hours (presented to ER with SAH).	69/M	Right temporal (n=2) and parasagittal/ left frontal (1) and multiple RICs (n=27)	Otitis Media/ 59	Low dose (unknown)	Stereotactic radiosurgery (the patient received 16 Gy for three RIMs and one ruptured cerebellar cavernoma); discharged in the same day; No biopsy had performed. On his 9 th month-visit tumors were stable, no progression. After physical therapy patient is walking without supporting. The patient was observed 8 days for SAH.	Alive; 11 mns

GTR: Gross Total Resection, **mns:** months, **F:** Female, **M:** Male, **PO:** Postoperative, **RTP:** Radiotherapy, **RIMs:** Radiation-induced meningiomas, **RICs:** Radiation-induced cavernous angiomas, **ER:** Emergency department of neurosurgery, **SAH:** Subarachnoid hemorrhage.

were assessed by a one-way analysis of variance (ANOVA) using the SPSS 21.0 statistical package. Significance in the multivariate model was determined using a p value of <0.05 , and trend-level effects were defined as $p=0.05-0.10$. All p values were presented with an odds ratio (OR).

RESULTS

This series included one female (25%) and three male patients (75%) between the ages of 32 and 69 years, with a mean age of 47.3 ± 16.3 years. The baseline clinical characteristics, location, treatment, outcomes, and complications of treatment for all cases are shown in Table I. The most common symptom was headache (100%), which was followed by nausea and vomiting (75%). The mean preoperative course was less than 3 months (range=1 day–3 months) with two patients presenting on the same day after the occurrence of the seizure, the third was referred with headache and an unsteady gait of 3 months. However, the fourth patient was asymptomatic despite three RIMs. This patient presented with a subarachnoid hemorrhage (SAH) related to cavernoma ruptures. The most common symptom was headache (100%). The most common location was frontal ($n=3$), and three patients had alopecia and thin scalp skin. The mean age of exposure to radiotherapy was 18.5 ± 13.7 (10-39) years. The mean latency period was 19.2 ± 7.4 (11-59) years. The initial malignancies included two desmoplastic medulloblastomas in a 13-year-old female and an 11-year-old male treated with 65 and 54 Gy, respectively, and one grade II oligodendroglioma in a 39-year-old male treated with 30 Gy. The fourth patient, a 10-year-old male, received low-dose RTP for chronic otitis. Histopathological examinations of the first three patients revealed the following;

- 1) fibroblastic-grade I in the right cerebellopontine angle (CPA), Ki-67 2%–3%, with a latency period of 25.5 years,
- 2) right frontal atypical meningioma grade II, Ki-67 8%, 21 year latency,
- 3) right frontal transitional grade I, Ki-67 3%–4%, 11 year latency, respectively.

No biopsy was performed in the fourth patient, who had two right temporal and one left frontal RIM. This patient was treated using stereotactic radiosurgery. The mean follow-up period was 34.8 ± 39.4 months. One patient had rhinorrhea and died due to the involvement of meningitis on postoperative (PO) day 31. Another patient experienced a cerebrospinal fluid (CSF) fistula. Both were treated by plastic surgeons. The average duration of their hospital stay was 11.3 ± 13.7 days. No patient had type 2 neurofibromatosis, chromosomal aberrations, or any genetic disease. RIM cases and series obtained from the literature are shown in Table II (Available only in online version).

Results of Literature Review and Analysis

A review of articles dealing with RIM yielded 242 studies, including ours, with the first case reported by Mann in 1953 (2) to the most recent case reported in April 2017. After excluding duplicate records, genetic studies, papers that did not include individual characteristics and 52 cases diagnosed at autopsy,

we identified 2,126 cases of RIM diagnosed in 1,659 patients. Excluding the 20.3% ($n=318$) RIM patients with no sex reported, 56.2% ($n=754$) of patients were female. To the best of our knowledge, the largest previous survey reported 1,341 RIM patients (Table II) (Available only in online version).

Our review of the literature revealed that the average latency period of RIMs was 26.2 ± 9.3 years (7 months–65 years) (28,40). The rarity of pediatric RIMs (96 cases reported) compared with adult RIMs could be because of the slow-growing nature of meningiomas. The mean latency period was approximately 31.4 ± 8.7 years in adults and 10.0 ± 4.1 years in children (Table II) (Available only in online version), with a tendency for shorter latency periods in patients treated with higher doses and in those who had undergone radiotherapy at younger ages ($p<0.001$). The latency period of RIMs was affected by the use of chemotherapy (12). The mean latency period of patients who received chemotherapy (ChT) and RTP doses of 12 to 46 Gy ($n=205$) was 15.7 ± 6.5 years, whereas that of patients who had received the same dose without chemotherapy was 27.8 ± 10.2 years ($n=261$) ($p<0.038$).

To understand the impact of radiation dose on latency period, we divided the RIM patients into four groups: low dose (LD) (≤ 10 Gy), intermediate dose (MD) (>10 to ≤ 20 Gy), high dose (HD) (>20 to ≤ 40 Gy), and very high-dose (VHD) (≥ 40 Gy) radiation. The latency periods of these groups were 36.0 ± 4.8 , 19.8 ± 9.2 , 22.8 ± 4.2 , and 13.2 ± 6.4 years, respectively ($p=0.022$).

Patients treated using RTP alone (with a negligible dose of radiation) were compared with those treated using RTP and additional ChT, it was found that additional ChT was an independent risk factor associated with an increased risk of recurrence [relative risk (RR)=0.51, OR=0.38, $p<0.0001$] and multiplicity (RR=0.48, OR=0.35, $p<0.0001$).

Meningotheliomatous ($n=184$), transitional ($n=86$), and fibroblastic ($n=78$) are the most common histological subtypes of WHO grade I RIMs. Of the 977 RIM patients with details provided, 161 (147 adults and 14 children) had a recurrence (16.5%). The rate of multiplicity in previously reported RIM patients was up to 16.1% (196 of 1,221).

CASE REPORTS (Table I)

Case 1

A 38-year-old female patient underwent craniectomy to remove a midline vermian mass (Figure 1) that caused unsteady gait, headache, nausea, and vomiting at the age of 13 in the year 1988. Histopathological examinations revealed that the mass was a desmoplastic (nodular) medulloblastoma (Figure 2A, B). She subsequently received curative high-dose craniospinal RTP (50 Gy) of the CNS and a focal boost of 15 Gy for the posterior fossa. The patient tolerated RTP well and had been controlled yearly. After 25.5 years, the patient was referred to our hospital with a 3-month history of headache, unsteady gait, nausea, and vomiting. Excluding the impairment observed on right cerebellar tests, the patient was neurologically intact. She had apparent alopecia and thin scalp skin. MRI revealed

a tumor with isointense signal in the right CPA that consisted of two compartments (Figure 3A, B); the medial compartment did not show contrast enhancement, whereas the lateral compartment in the dura showed moderate homogenous contrast enhancement.

The patient underwent a right suboccipital craniectomy followed by a total resection of the lateral compartment and a biopsy of the suspected radiation-induced fibrotic tissue in the medial compartment. The excised mass was histopathologically diagnosed as a fibroblastic meningioma (WHO grade I) (Figure 4A, B). The Ki-67 index was 2-3% and no necrosis was observed. The mitosis count was low (1/10 high-power field). No pleomorphism was observed. Biopsy of the medial compartment revealed arachnoidal fibrosis. The patient had a complete resolution of symptoms and was discharged on PO day 3. Early PO MRI (Figure 5A-C) revealed

that gross-total resection had been achieved. She has had no recurrence over the last 3 years. Annual controls were recommended.

Case 2

A 32-year-old male underwent craniectomy to remove a midline vermian mass that caused unsteady gait, nausea, and vomiting at the age of 11 in 1987. Histopathological examinations revealed that the mass was a desmoplastic medulloblastoma, and he subsequently received curative high-dose craniospinal RTP (42 Gy) of the CNS and a focal boost of 12 Gy for the posterior fossa. The patient tolerated RTP well and was controlled yearly. After 21 years, the patient, presenting with seizure, headache, nausea, and vomiting, was referred to our hospital. He was neurologically intact. Physical examination revealed swelling in the right anterior frontal

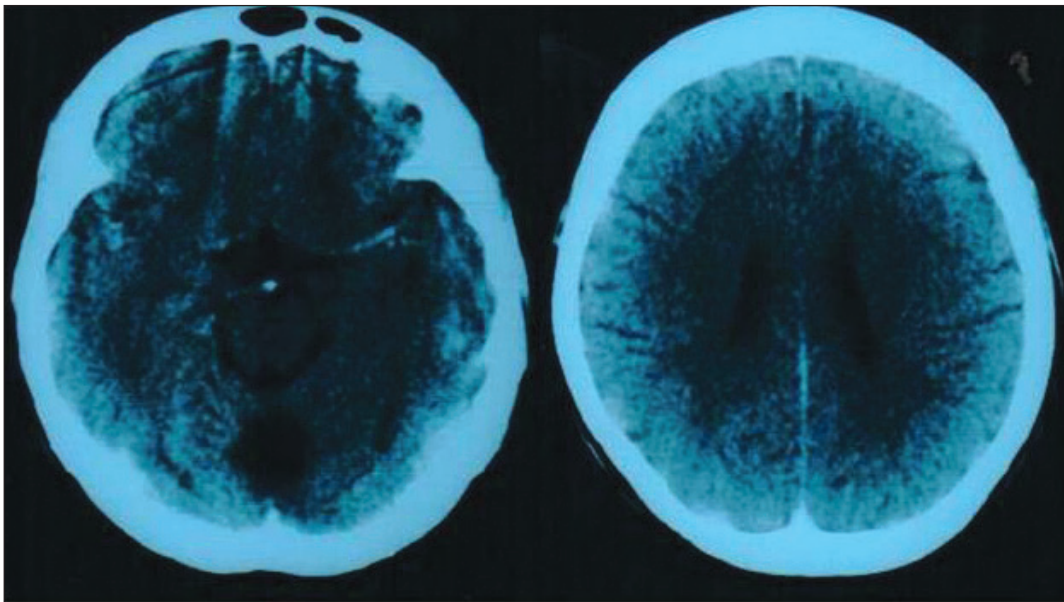


Figure 1: Postoperative computed tomography was performed after the first surgery in 1988. Note the postoperative changes, such as the area of encephalomalacia at the middle line of vermian.

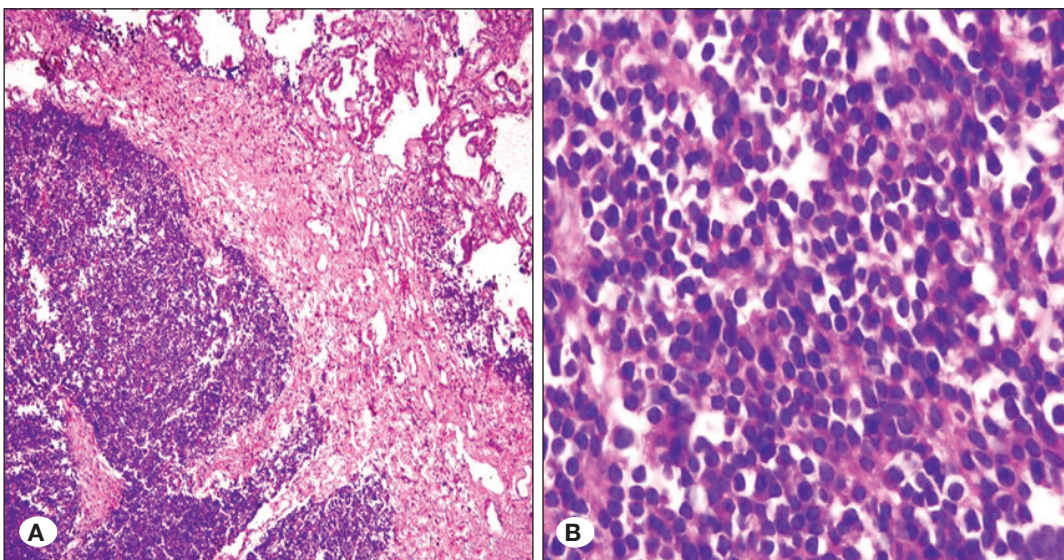


Figure 2: Histopathological findings of tissue from the middle line vermian mass obtained from the patient in 1988 led to the diagnosis of the tumor as a desmoplastic (nodular) medulloblastoma (WHO grade IV). **A)** The choroid plexus is visible at the top right of this image and an infiltration of round tumor cells is visible at the bottom left (HE, $\times 100$). **B)** A malignant round cell tumor at high power (HE, $\times 200$).

region, apparent alopecia, and thin scalp skin. MRI revealed a parasagittal lesion related to the dura, measuring 3×2×2 cm in the right frontal region, and showing homogeneous contrast enhancement (Figure 6).

The patient underwent a right frontal craniotomy followed by a total resection of the lesion, galeal duraplasty, and acrylic cranioplasty. The excised mass was histopathologically diagnosed as an atypical meningothelial meningioma (WHO grade II). The Ki-67 index was 8%. The patient had complete resolution of symptoms and was discharged on PO day 10. Early PO subcutaneous CSF fistula remained up to PO month 4 (Figure 7), when the patient was worrisome. Repair operations were performed two times. The patient received RTP after repairs were completed, and had no recurrence in the following 7 years. Annual controls were recommended.

Case 3

A 50-year-old male patient underwent a right frontal craniotomy to remove a low-grade frontal glial mass that caused seizures and headaches at age of 39 in 1998. Histopathological examination revealed that the mass was a WHO grade II oligodendroglioma. He subsequently received curative high-dose craniospinal RTP (30 Gy) of the cranial region. The patient tolerated RTP well and was controlled yearly. During a control visit in his tenth year, MRI revealed a parasagittal lesion measuring 1.5×2.2×1.9 cm (Figure 8). Surgery was recommended but the patient refused because he had no complaints. The patient was referred to our hospital 11 years after surgery with seizures after severe headache. Excluding a left lower extremity grade 4/5 weakness, the patient was

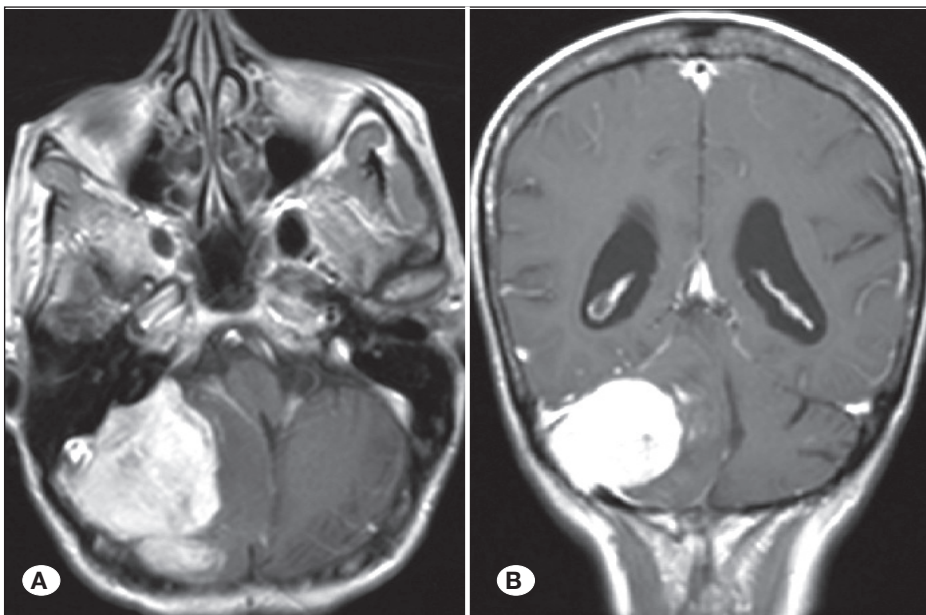


Figure 3: Preoperative magnetic resonance imaging. **A)** Preoperative axial T1-weighted fluid-attenuated inversion recovery (FLAIR) MRI showing a tumor in the right CPA measuring 5.5×7×3 cm. **B)** Preoperative coronal T1-weighted MRI. There are two compartments showing different contrast enhancements. The medial compartment lesion does not show contrast enhancement.

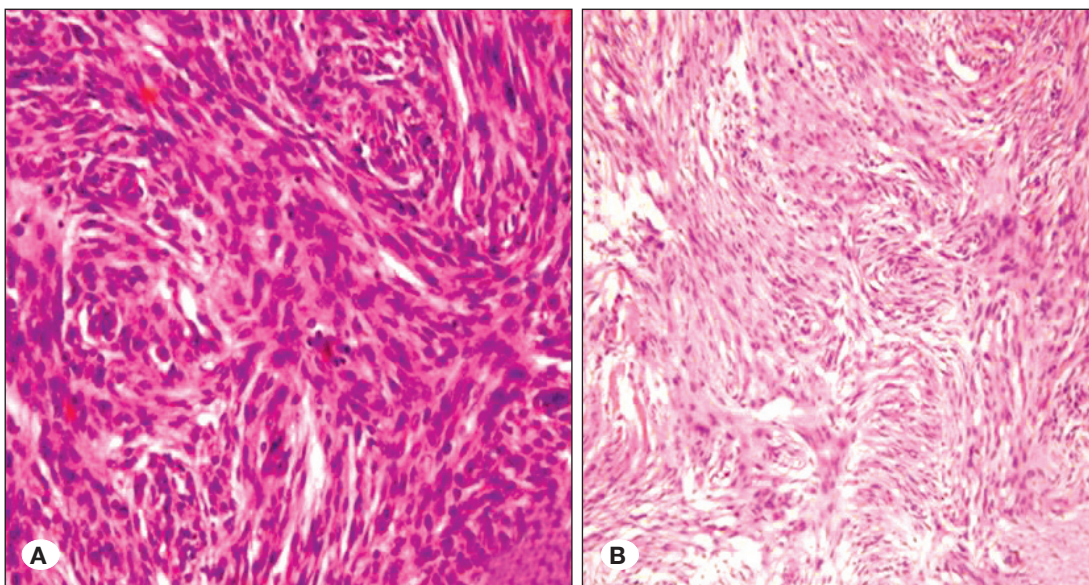


Figure 4A, B: Histopathological findings on tissue from the right CPA meningioma led to the diagnosis of the tumor as a fibroblastic meningioma (WHO grade I) (HE, ×200 in **A** and ×100 in **B**).

unaffected. He had apparent alopecia and thin scalp skin. MRI revealed a right frontal mass that displayed contrast enhancement and measured 5.3×4.8×7.1 cm (Figure 9A, B).

The patient underwent a right frontal craniotomy followed by a total resection of the mass, which extended to the lamina cribrosa and olfactory groove (Figure 10A, B). The excised mass was histopathologically diagnosed as transitional meningioma (WHO grade I). The Ki-67 index was 3–4%. On PO day 2, the patient experienced rhinorrhea that did not stop even after a lumbar drainage system was set up. A repair operation was performed. On PO day 20, the patient experienced meningitis and a deterioration of his neurological status. The patient died on PO day 31.

Case 4

A 69-year-old male patient underwent surgery to remove an

abscess in his right ear at age 10. He subsequently received RTP. The patient could not remember the dosage but assumed that a low dose was prescribed. Except for the deafness in his right ear, he did well until he presented at our ER with severe headache, unsteady gait, dysarthria, nausea, and vomiting, which was followed by a few hours of impaired consciousness. The patient was on medication for hypertension. Cranial computed tomography (CT) and MRI showed diffuse SAH, three meningiomas (two in the right temporal region and a third in the left frontal region), two cavernomas (a ruptured one in the right cerebellum and another in the right basal ganglia), and a hematoma that filled the fourth ventricle (Figure 11A, B). Due to hydrocephalus, the patient was kept under observation for 8 days and was then discharged without surgical intervention. After 3 months, another MRI was performed (Figure 12A-H). Susceptibility-weighted imaging (SWI) revealed 27 cavernous

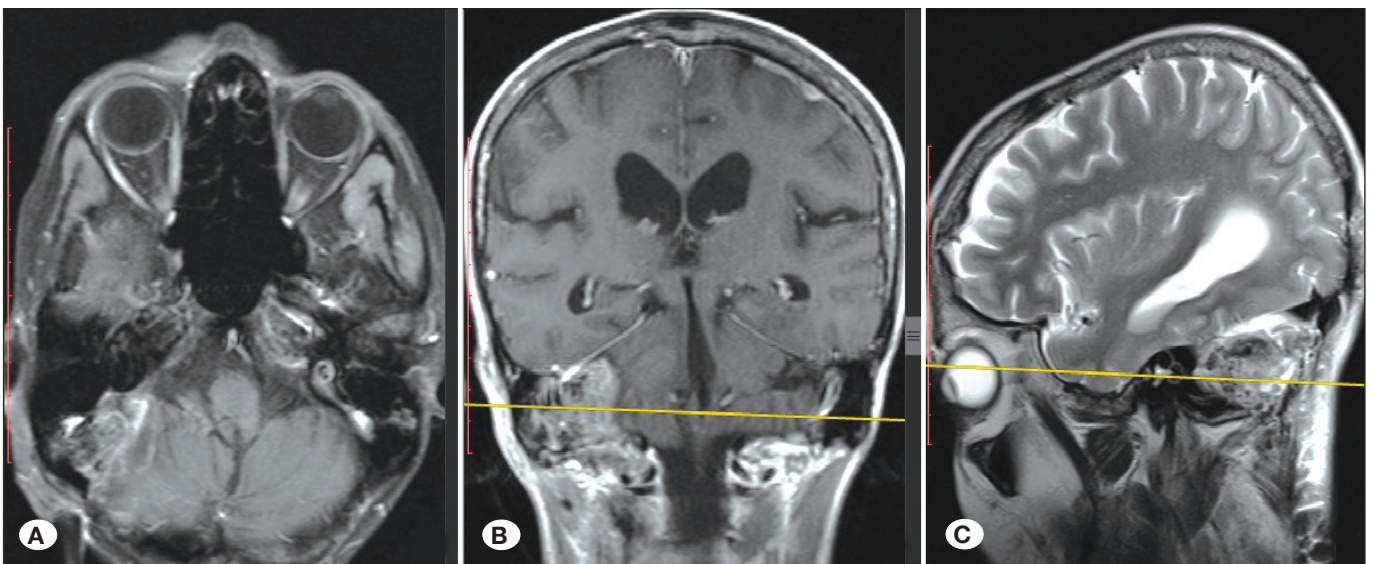


Figure 5: Early postoperative MRI from “Case 1”; **A)** axial T1W, **B)** coronal T1W, and **C)** sagittal sequences.

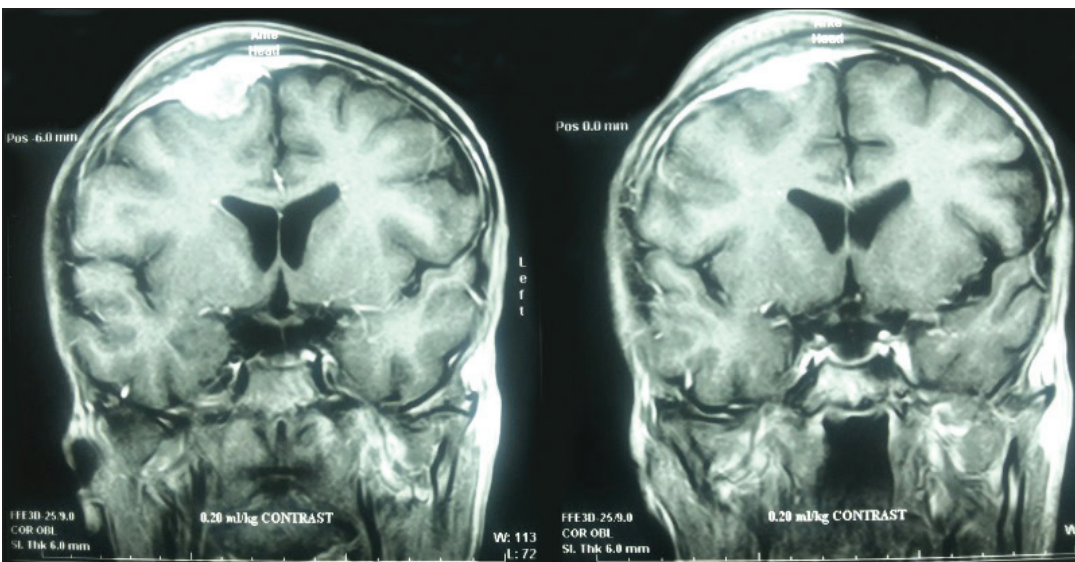


Figure 6: Coronal T1 weighted MRI from “Case 2” showing a parasagittal lesion related to the dura and measuring 3×2×2 cm in the right frontal regions with homogenous contrast enhancement.

angiomas (Figure 12A–E) and three meningiomas (Figure 12F–H). Because of the risks associated with surgery, his family chose treatment with stereotactic radiosurgery. The patient received 16 Gy to treat the ruptured radiation-induced cerebellar cavernoma (RIC) and three RIMs. On his 9 month-visit, the tumors were stable and had not progressed. After physical therapy, the patient was able to walk without support.

DISCUSSION

The long-term side effects of irradiation on neural tissue include visual deterioration, hearing loss, hormonal disturbances, vasculopathy, brain and bone necrosis, atrophy, demyelination, calcification, fatty replacement of bone marrow, and the induction of new CNS neoplasms (54). RIMs usually arise in patients with a history of low-dose RTP to the cranial and

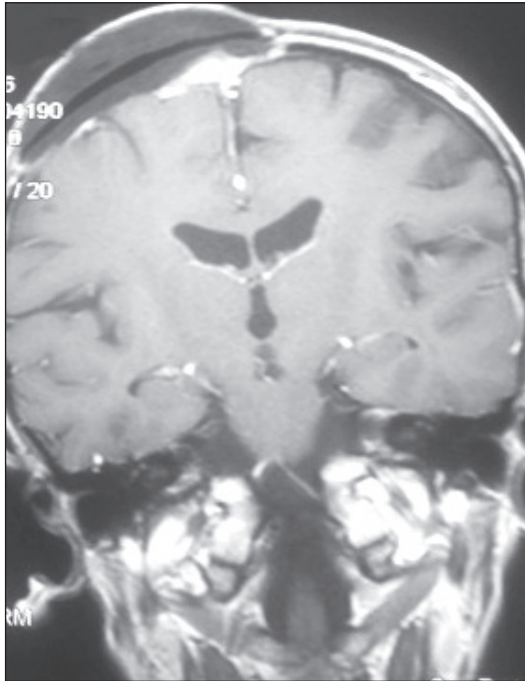


Figure 7: Postoperative month 4. Coronal T1-W MRI from “Case 2” showing that the early postoperative subcutaneous CSF fistula remains.

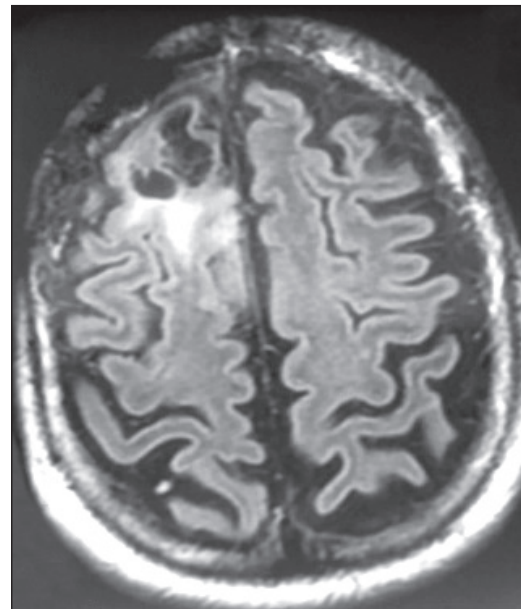


Figure 8: The FLAIR T2-weighted MRI from “Case 3” was performed on his 10-year control visit. MRI shows a right frontal mass measuring 1.5×2.2×1.9 cm. The patient refused surgery because he had no complaints. Note the right frontal craniotomy defect, which was performed for the primary tumor.

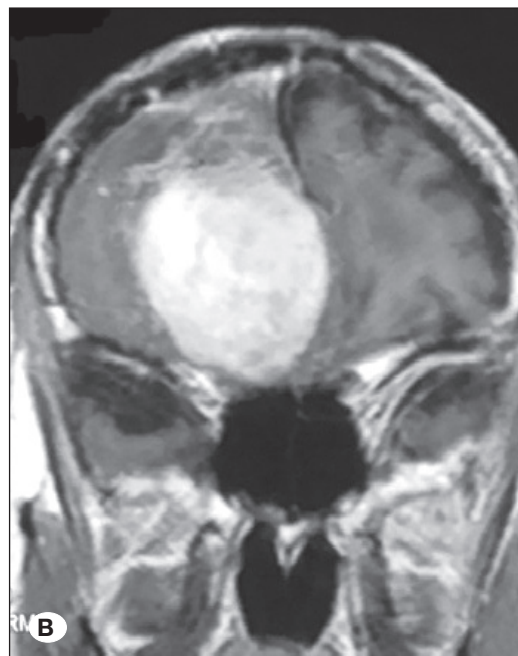
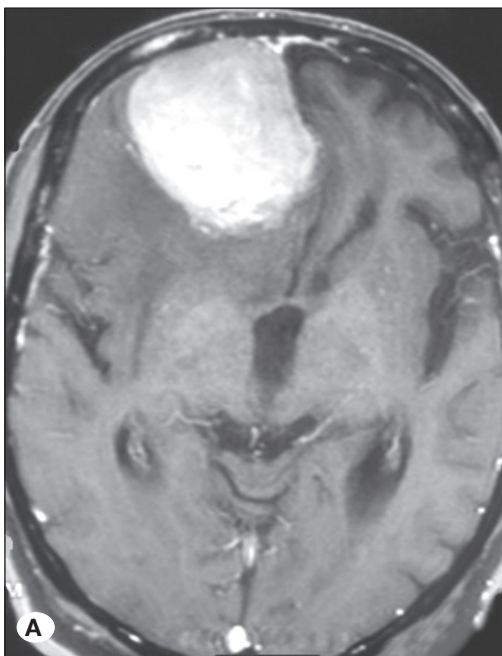


Figure 9: An MRI from “Case 3” revealing a right frontal mass with homogeneous contrast enhancement and measuring 5.3×4.8×7.1 cm. The mass extended into the lamina cribrosa and olfactory groove; **A)** axial T1W and **B)** coronal T1W sequences.

scalp regions for the treatment of benign diseases such as tinea capitis, or high-dose RTP for the treatment of malignant and aggressive intracranial tumors. There is no doubt that radiation-induced injury contributes to the development of meningiomas and other neoplasms. In 1953, Mann et al. first reported RIM. The patient was a 4-year-old girl who received 6,500 Gy after resection of an optic nerve glioma. RIM was diagnosed 5 years later within the RTP field (2).

Shintani et al. reported that aggressiveness or malignancy was uncommon in RIMs among the survivors of the atomic bombing of Hiroshima. Their study suggested that there is no relationship between dose and the aggressiveness and malignancy of RIMs (55). Regardless of the source or dose of radiation, we believe that the meninges, bone, and brain will be affected by exposure to a sufficient dose of radiation.

However, the question of why the spinal cord is unaffected by radiation to the same extent as cranial tissues remains unanswered. This may be because the muscles and body spaces protect other body organs and the spinal cord rather than the calvarial bone. Other studies have revealed that mesodermal tissues are sensitive to oncogenetic stimulants (50), and this agrees with a study which claims that mitotic activity may be induced by as little as 0.35 Gy (62).

Criteria for defining radiation-induced tumors are well reported in the literature. To be considered as a radiation-induced lesion, a tumor must fulfill the following criteria;

- 1) It is in the RTP field.
- 2) It was not present prior to irradiation as determined by MRI at the initial diagnosis, prior to surgery and RTP.

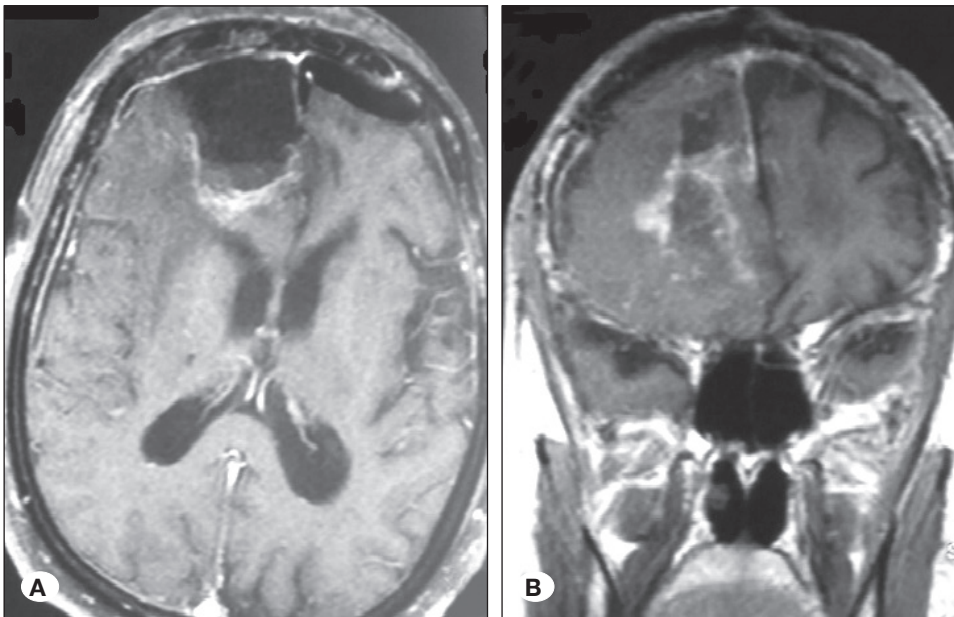


Figure 10: Early postoperative MRI from "Case 3". MRI demonstrating that gross-total resection was performed; **A)** axial T1W and **B)** coronal T1W sequences.

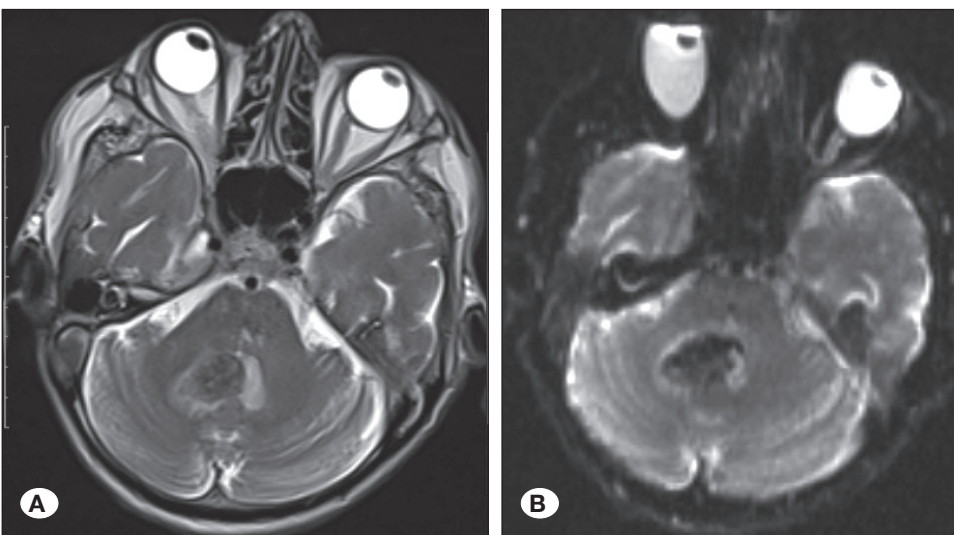


Figure 11: MRI from "Case 4", performed after presentation with SAH, showing a hematoma filling the fourth ventricle and relating to a vascular proliferative lesion in the right cerebellum; **A)** Axial T2-weighted MRI. **B)** Axial diffusion ADC MRI.

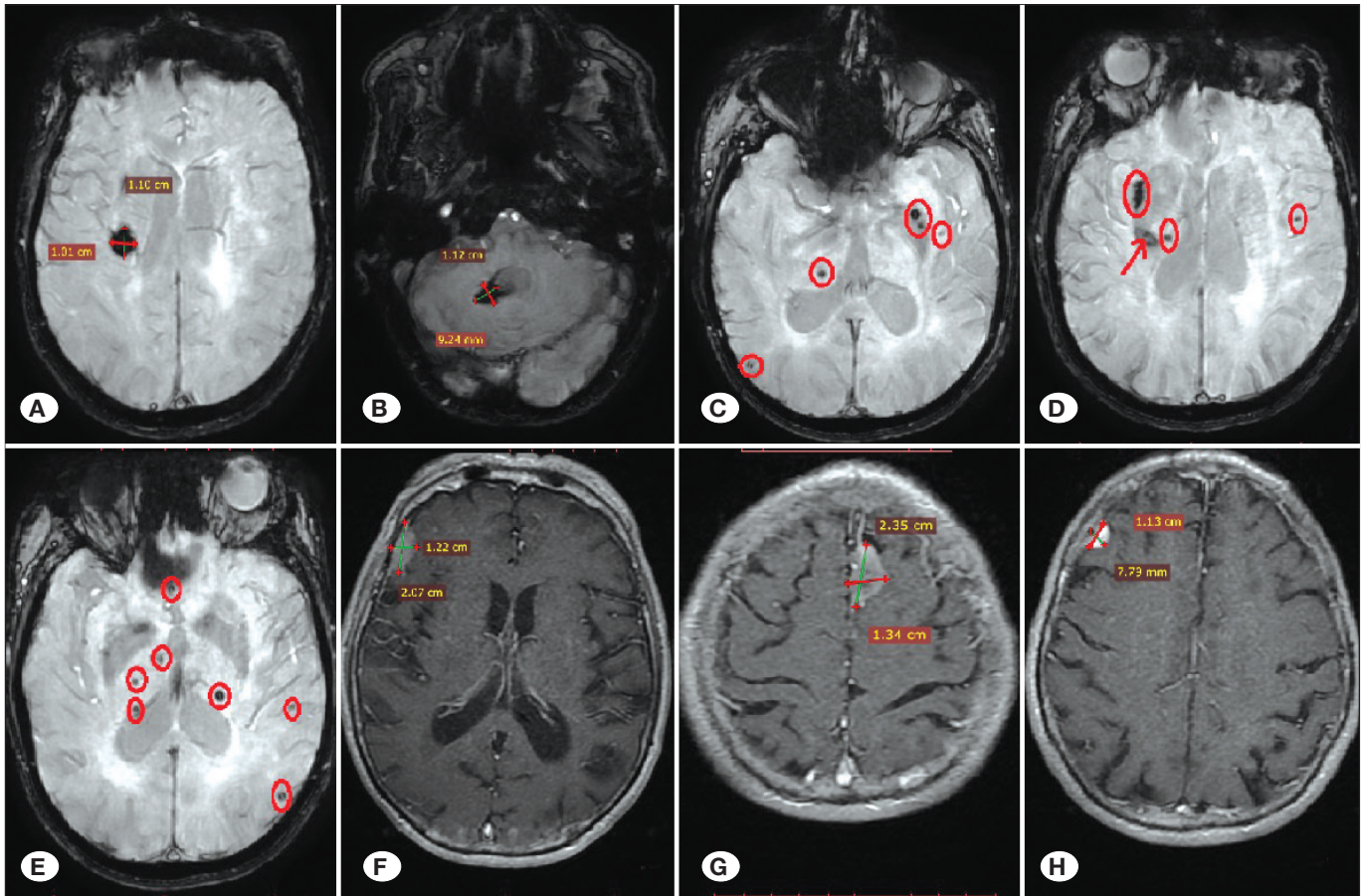


Figure 12: An MRI on 3 months after hemorrhage showing multiple cavernomas and meningiomas. **A)** Axial SWI-MRI showing a cavernoma in the right basal ganglia measuring 1.10 × 1.02 × 1.5 cm. **B)** Axial SWI-MRI showing a ruptured cavernoma in the right cerebellum measuring 0.92×1.02×0.9 cm. **C–E)** Axial sections from an SWI-MRI showing several cavernomas indicated by red circles. Red arrows indicate cavernomas in **(D)**. **F–H)** Axial T1-weighted MRI showing two right temporal masses (**F** and **H**) and a left frontal parasagittal mass (**G**), all of which show homogeneous contrast enhancement and measure 1.22×1.34×1.8 cm, 2.35×1.34×2.2 cm, and 1.13×0.8×1.2 cm, respectively.

- 3) There was a delay of several years from the time of treatment to the appearance of the tumor (e.g., after high-dose RTP for medulloblastoma, latency periods of RIMs for rhinorrhea and subcutaneous CSF fistula. The patient with rhinorrhea was lost after the involvement of meningitis.
- 4) The induced lesion must differ histologically from the originally irradiated tumor.
- 5) The patient does not have a genetic disease such as neurofibromatosis type II or Gorlin's syndrome, or a condition predisposing them to secondary malignancy (8,21,63). In our series, all requirements were met.

The most common findings on physical examination of RIMs are scalp lesions such as alopecia, cutaneous atrophy, cutaneous telangiectasias, and chronic dermatitis. In some patients, calvarial osteomyelitis was present (2,7,15,51,54,64) and three cases presented with alopecia and thin scalp. All patients received high-dose radiation. Scalp lesions complicated surgical approaches to RIMs. In such cases, surgery must be planned with plastic surgeons to avoid

serious complications such as rhinorrhea and CSF fistulas. Follow-up operations were performed on two of our patients for rhinorrhea and subcutaneous CSF fistula. The patient with rhinorrhea was lost after the involvement of meningitis.

Synchronous RIMs and RICs are a rare occurrence with only five papers identified in our review of literature (Table II) (Available only in online version) (5,13,33,42,47). A study by Mack and Wilson first described synchronous RIMs and RICs in three patients, although few details were provided (42). The study defined RICs as vascular malformations. All three patients were females with a history of high-dose radiation (52.5 Gy, 40 Gy, and a non-specified high dose) for optic glioma, ependymoma, and acoustic neuroma, respectively (47). Three other cases were described as multiple RICs accompanied by a single RIM (13,33,47), and one case was described as a ruptured RIC. This case was diagnosed only 7 years after surgery for medulloblastoma, and the patient subsequently received 54 Gy (33).

Keezer and Del Mastro found 85 patients with RICs in the literature, of whom 40% had multiple cavernomas. In this

cohort, 47 patients were males; the mean age at the time of radiation was 10.4 ± 2.0 years, the mean latency period of diagnosis was 10.4 ± 2.0 years, and the mean dose of radiation was 48.5 Gy. Most patients (60%) were incidentally diagnosed. The same study found no significant relationship between the development of multiple RICs and radiation dose, age at irradiation, or latency period (34). Heckl et al. found a correlation between RICs and children younger than 10 years (26). Our fourth case is consistent with this finding. RIMs are typically more common in females, although the difference between sexes may be less distinct than in primary meningiomas (7,9,21,44).

Banerjee et al. confirmed that RIMs only occurred in patients treated with high-dose radiation (≥ 21 Gy) (7). If the time since radiation is taken into account, both patient groups (18–21 Gy vs. ≥ 21 Gy) seemed to be at equal risk for developing meningioma. Neglia et al. reported high relative risk for all brain tumors at doses exceeding 30 Gy, with risk for RIM was the order of 50–100 Gy (45). Although the average latency period in the MD group was shorter, there was no statistically significant difference between the MD and HD groups ($p=0.65$). This was also the case for most patients treated with additional ChT in both groups. A multivariate regression model based on our review of the literature shows that compared with RTP alone at any dose, RTP with additional ChT is independently associated with an increased risk of recurrence (RR=0.51, OR=0.38, $p<0.0001$) and multiplicity (RR=0.48, OR=0.35, $p<0.0001$).

The pathogenesis of high-dose RIMs was initiated by the rapid loss of cellular control mechanisms and a failure of the deoxyribonucleic acid (DNA) repair system, eventually leading to tumor formation (54). Three of our patients underwent high-dose whole CNS RTP at 65, 54, and 30 Gy. However, the mechanism underlying low-dose RIMs includes genetic mutations and is induced by mis-regeneration (a chronic cellular proliferation) caused by a post-radiation phlogistic reaction. Mutations occur in the inhibitory motif near the *c-sis* gene on the long arm of chromosome 22. If this alteration is induced by x-ray, it may activate an oncogene (59).

RIMs differed from primary meningiomas in patient age at presentation. The mean age at presentation was 33.55 years in patients exposed to high-dose radiation and 51.5 years in those exposed to low-dose radiation, whereas primary meningiomas generally arise in the fifth or sixth decade of life (21,49).

There are six distinctive histological features of RIMs: a high degree of cellularity, cellular pleomorphism, numerous bizarre cells, necrotic changes, increased mitosis, and nuclei with pseudo-inclusions (8,63). Results from the histopathological examinations of our series ranged from frequent mitoses, hypercellularity, and focal necrosis to normal features of meningioma. Except for 64 RIM patients that were not surgically treated and 547 RIM patients who did not report histologically-based tumor identification, the most commonly reported RIM was WHO grade I ($n=754$). By histological subtype, the most common WHO grade I RIMs were meningotheliomatous ($n=184$), transitional ($n=86$), and fibroblastic ($n=78$) (14,20,51). Two RIMs in our series were diagnosed as WHO grade I and another was an atypical meningioma.

Among 977 RIM patients with detailed reports, 618 patient reports did not include details on the recurrence and 64 patients were not treated surgically. Among the remaining 161 patients, 16.5% had a recurrence (147 adults and 14 children) (Table II) (Available only in online version), whereas 3–11.4% had a recurrence among those with primary meningiomas (49). The recurrence in the two RIM survivors in our study was not detected until 38 and 89 months after surgery. The previously reported rate of multiplicity in RIM patients was up to 16.1% (196 of 1221) (Table II) (available only in the online version). In our RIM series, one patient had multiple RIMs.

Given the aggressive nature and high rate of recurrence of RIMs, wide resection margins in the involved dura mater are vital. In cases where the tumor involves under- or overlying bone, the osseous portion of the tumor should be radically removed because osseous invasion has been linked to higher rates of tumor recurrence. Surgery may be followed by RTP in patients with RIMs if radical excision cannot be achieved (59–61). The authors recommend bone removal and replacement with acrylic graft if there is a suspicion of osseous invasion. In the third case, resection of all bone, dura, and tumor was performed, followed by galeal duraplasty and acrylic cranioplasty. The patient was treated with adjunct RTP in PO month 6.

■ CONCLUSION

RIM is a late effect of curative RTP. In children with medulloblastoma and adults with oligodendroglioma, RTP is a major component of curative treatments. Therefore, the incidence of RIMs is expected to increase in the future. In such patients, yearly MRI should be performed to scan all fields exposed to RTP. To avoid recurrence, aggressive surgical removal is recommended. To reduce fatal complications such as rhinorrhea, plastic surgeons should be involved in the surgical management plan.

■ REFERENCES

1. Aboukais R, Zairi F, Le Rhun E, Lejeune JP, Devos P, Reyns N: Radiation-associated grade 2 meningiomas: A nine patient-series and review of the literature. *Clin Neurol Neurosurg* 136: 10-14, 2015
2. Al-Mefty O, Topsakal C, Pravdenkova S, Sawyer JR, Harrison MJ: Radiation-induced meningiomas: Clinical, pathological, cytogenetic, and cytogenetic characteristics. *J Neurosurg* 100: 1002-1013, 2004
3. Andrade EMF, Alves RV, Fiore ME, De Araújo AB, Carlos A, Godoy R: Radiation-induced meningiomas: The importance of continued follow up after cranial irradiation. *J Bras Neurochirurg* 21: 245-248, 2010
4. Azab WA, Al-awadi YA, Abdel-Razek MSZ: Radiation-induced meningiomas. *Pan Arab Journal of Neurosurgery* 15:67-71, 2011
5. Baheti AD, Mahore AS, Zade BP, Jalali R: Meningioma and cavernous angioma following childhood radiotherapy. *J Cancer Res Ther* 6:333-335, 2010

6. Balik V, Sarissky M, Lohmann D, Sulla I: Meningioma 40 years after radiation therapy for Retinoblastoma: Genetic and phenotypic analysis, and minireview of literature. *Zentralbl Neurochir* 69: 1-6, 2008
7. Banerjee J, Paakko E, Harila M, Herva R, Tuominen J, Koivula A, Lanning M, Harila-Saari A: Radiation-induced meningiomas: A shadow in the success story of childhood leukemia. *Neuro Oncol* 11: 543-549, 2009
8. Brassesco MS, Valera ET, Neder L, Pezuk JA, Oliveira RS, Scrideli CA, Tone LG: Cytogenetic findings in pediatric radiation-induced atypical meningioma after treatment of medulloblastoma: Case report and review of the literature. *J Neurooncol* 110: 397-402, 2012
9. Caroli E, Russillo M, Ferrante L: Intracranial meningiomas in children: Report of 27 new cases and critical analysis of 440 cases reported in the literature. *J Child Neurol* 21: 31-36, 2006
10. Cernea D, Pruteanu DP, Bogdan V: Malignant meningioma after radiotherapy for tinea capitis in childhood. *Journal of Radiotherapy & Medical Oncology* 27(2): 69-72, 2012
11. Char DH, Shiel MJ: Orbital meningioma after cranial radiation for acute lymphocytic leukemia. *Orbit* 27: 321-323, 2008
12. Chojnacka M, Pedziwiatr K, Skowronska-Gardas A, Perek-Polnik M, Perek D, Olasek P: Second brain tumors following central nervous system radiotherapy in childhood. *Br J Radiol* 87: 20140211, 2014
13. Chourmouzi D, Papadopoulou E, Kontopoulos A, Drevelegas A: Radiation-induced intracranial meningioma and multiple cavernomas. *BMJ Case Rep*: 2013, 2013
14. Chowdhary A, Spence AM, Sales L, Rostomily RC, Rockhill JK, Silbergeld DL: Radiation associated tumors following therapeutic cranial radiation. *Surg Neurol Int* 3: 48, 2012
15. Elbabaa SK, Gokden M, Crawford JR, Kesari S, Saad AG: Radiation-associated meningiomas in children: Clinical, pathological, and cytogenetic characteristics with a critical review of the literature. *J Neurosurg Pediatrics* 10:281-290, 2012
16. Ellyda MN: Radiation-induced meningioma following radiotherapy for pituitary adenoma: A case report. *International Medical Journal Malaysia* 12: 63-66, 2013
17. Felicetti F, Fortunati N, Garbossa D, Biasin E, Ruda R, Daniele D, Arvat E, Corrias A, Fagioli F, Brignardello E: Meningiomas after cranial radiotherapy for childhood cancer: A single institution experience. *J Cancer Res Clin Oncol* 141:1277-1282, 2015
18. Friedman DL, Whitton J, Leisenring W, Mertens AC, Hammond S, Stovall M, Donaldson SS, Meadows AT, Robison LL, Neglia JP: Subsequent neoplasms in 5-year survivors of childhood cancer: The childhood cancer survivor study. *J Natl Cancer Inst* 102: 1083-1095, 2010
19. Galloway TJ, Indelicato DJ, Amdur RJ, Morris CG, Swanson EL, Marcus RB: Analysis of dose at the site of second tumor formation after radiotherapy to the central nervous system. *Int J Radiat Oncol Biol Phys* 82: 90-94, 2012
20. Ghim TT, Seo JJ, O'Brien M, Meacham L, Crocker I, Krawiecki N: Childhood intracranial meningiomas after high-dose irradiation. *Cancer* 71: 4091-4095, 1993
21. Godlewski B, Drummond KJ, Kaye AH: Radiation-induced meningiomas after high-dose cranial irradiation (review). *J Clin Neurosci* 19: 1627-1635, 2012
22. Goshen Y, Stark B, Michowiz S, Feinmesser M, Yaniv I: High incidence of meningioma in cranial irradiated survivors of childhood acute lymphoblastic leukemia. *Pediatr Blood Cancer* 49(3): 294-297, 2007
23. Goto Y, Yamada S, Yamada SM, Nakaguchi H, Hoya K, Murakami M, Yamazaki K, Ishida Y, Matsuno A: Radiation-induced meningiomas in multiple regions, showing rapid recurrence and a high MIB1 labeling index: A case report and review of the literature. *World J Surg Oncol* 12:123, 2014
24. Greene S, Nair N, Ojemann JG, Ellenbogen RG, Avellino AM: Meningiomas in children. *Pediatr Neurosurg* 44: 9-13, 2008
25. Hassaneen W, Prabhu VC, Melian E, Fareed J, Borys E, Iqbal O, Anderson DE: Intracranial radiation-induced meningiomas. *J Neurol Surg B* 76-A003, 2015
26. Heckl S, Aschoff A, Kunze S: Radiation-induced cavernous hemangiomas of the brain: A late effect predominantly in children. *Cancer* 94: 3285-3291, 2002
27. Hijiya NN, Hudson MM, Lensing SS, Zacher M, Onciu M, Behm FG, Razzouk BI, Ribeiro RC, Rubnitz JE, Sandlund JT, Rivera GK, Evans WE, Relling MV, Pui CH: Cumulative incidence of secondary neoplasms as a first event after childhood acute lymphoblastic leukemia. *JAMA* 297: 1207-1215, 2007
28. Hu W, Shen F, Chen G, Shen G, Liu W, Zhou J: Possible involvement of brain tumor stem cells in the emergence of a fast-growing malignant meningioma after surgical resection and radiotherapy of high-grade astrocytoma: Case report and preliminary laboratory investigation. *J Int Med Res* 37:240-246, 2009
29. Innocenti A, Simonetti G, Gaviani P, Botturi A, Lamperti E, Fariselli L, Silvani A: A case of radiation-induced meningiomas. *Neuro Oncol* 16 Suppl 2: 45-46, 2014
30. Jensen AW, Brown PD, Pollock BE, Stafford SL, Link MJ, Garces YI, Foote RL, Gorman DA, Schomberg PJ: Gamma knife radiosurgery of radiation-induced intracranial tumors: Local control, outcomes, and complications. *Int J Radiat Oncol Biol Phys* 62(1): 32-37, 2005
31. Juven Y, Sadetzki S: A possible association between ionizing radiation and pituitary adenoma. *Cancer* 95: 397-403, 2002
32. Kageji T, Sogabe S, Mizobichi Y, Nakajima K, Shinji N, Nakagawa Y: Radiation-induced meningiomas after BNCT in patients with malignant glioma. *Appl Radiat Isot* 106: 256-259, 2015
33. Kamide T, Nakada M, Hayashi Y, Suzuki T, Hayashi Y, Uchiyama N, Kijima T, Hamada JI: Radiation-induced cerebellar high-grade glioma accompanied by meningioma and cavernoma 29 years after the treatment of medulloblastoma: A case report. *J Neurooncol* 100: 299-303, 2010
34. Keezer MR, Del Maestro R: Radiation-induced cavernous hemangiomas: Case report and literature review. *Can J Neurol Sci* 36:303-310, 2009
35. Kim YH, Kim CY: Coexistence of radiation-induced meningiomas and shunt related pneumocephalus in a patient with successfully treated medulloblastoma. *J Korean Neurosurg Soc* 41: 403-407, 2007
36. Kondziolka D, Kano H, Kanaan H, Madhok R, Mathieu D, Flickinger JC, Lunsford LD: Stereotactic radiosurgery for radiation-induced meningiomas. *Neurosurgery* 64:463-469, 2009

37. Kuhn EN, Chan MD, Tatter SB, Ellis TL: Gamma knife stereotactic radiosurgery for radiation-induced meningiomas. *Stereotact Funct Neurosurg* 90: 365-369, 2012
38. Kunert P, Matyja E, Prokopienko M, Marchel A: Radiation-induced tumors of meninges. Report on eight cases and review of the literature. *Neurol Neurochir Pol* 46:542-552, 2012
39. Lee DS, Yu M, Jang HS, Kim YS, Choi BO, Kang YN, Lee YS, Kim DC, Hong YK, Jeun SS, Yoon SC: Radiation-induced brain injury: Retrospective analysis of twelve pathologically proven cases. *J Radiat Oncol* 29:147-155, 2011
40. Lillehei KO, Donson AM, Kleinschmidt-Demasters BK: Radiation-induced meningiomas: Clinical, cytogenetic and microarray features. *Acta Neuropathol* 116: 289-301, 2008
41. Lynch JC, Ferreira LAS, Welling L, Schulz RC: Multiple intracranial meningiomas. *Arq Neuropsiquiatr* 66:702-707, 2008
42. Mack EE, Wilson CB: Meningiomas induced by high-dose cranial irradiation. *J Neurosurg* 79: 28-31, 1993
43. Morgenstern PF, Shah K, Dunkel IJ, Reines AS, Khakoo Y, Rosenblum MK, Gutin P: Meningioma after radiotherapy for malignancy. *J Clin Neurosci* 30: 93-97, 2016
44. Musa BS, Pople IK, Cummins BH: Intracranial meningiomas following irradiation - a growing problem? *Br J Neurosurg* 9: 629-637, 1995
45. Neglia JP, Robison LL, Stovall M, Liu Y, Packer RJ, Hammond S, Yasui Y, Kasper CE, Mertens AC, Donaldson SS, Meadows AT, Inskip PD: New primary neoplasms of the central nervous system in survivors of childhood cancer: A report from the Childhood Cancer Survivor Study. *J Natl Cancer Inst* 98: 1528-1537, 2006
46. Osipov V, Ho KC, Krouwer HG, Meyer G, Shidham VB: Post-radiation dedifferentiation of meningioma into osteosarcoma: Case report. *BMC Cancer* 2: 34, 2002
47. Paramanathan N, Ooi KG, Reeves D, Wilcsek GA: Synchronous radiation-induced orbital meningioma and multiple cavernomas. *Clin Exp Ophthalmol* 38: 414-417, 2010
48. Pistolesi S, Boldrini L, Gisfredi S, De Ieso K, Camacci T, Caniglia M, Lupi G, Pingitore R, Basolo F, Leocata P, Parenti G: Immunohistochemical and molecular study of radiation induced multiple meningiomas with pleural and pulmonary metastasis. *Tumori* 90: 328-332, 2004
49. Prabhu VC, Perry EC, Melian E, Barton K, Guo R, Anderson DE: Intracranial meningiomas in individuals under the age of 30; Analysis of risk factors, histopathology, and recurrence rate. *Neuroscience Discovery* 2:1, 2014
50. Robinson RG: A second brain tumour and irradiation. *J Neurol Neurosurg Psychiatry* 41: 1005-1012, 1978
51. Sadetzki S, Modan B, Chetrit A, Freedman L: An iatrogenic epidemic of benign meningioma. *Am J Epidemiol* 151: 266-272, 2000
52. Sasayama T, Nishihara M, Tanaka K, Mizukawa K, Ehara K, Kanomato N, Kohmura E: Two metachronous tumors induced by radiation therapy: Case report and review of the literature. *J Neurooncol* 88: 315-320, 2008
53. Sattler MGA, Beek APV, Wolffenbuttel BHR, vanden Berg G, Sluiter WJ, Langendijk JA, van den Bergh ACM: The incidence of second tumours and mortality in pituitary adenoma patients treated with postoperative radiotherapy versus surgery alone. *Radiother Oncol* 104: 125-130, 2012
54. Shenoy SN, Munish KG, Raja A: High dose radiation induced meningioma. *Br J Neurosurg* 18: 617-621, 2004
55. Shintani T, Hayakawan N, Hoshi M, Sumida M, Kurisu K, Oki S, Kodama Y, Kajiakawa H, Inai K, Kamada N: High incidence of meningioma among Hiroshima atomic bomb survivors. *J Radiat Res* 40: 49-57, 1999
56. Swanson EL, Amdur RJ, Morris CG, Galloway TJ, Marcus RB, Pincus DW, Smith A: Intracranial ependymomas treated with radiotherapy: Long-term results from a single institution. *J Neurooncol* 102: 451-457, 2011
57. Soffer D, Gomori JM, Siegal T, Shalit MN: Intracranial meningiomas after high-dose irradiation. *Cancer* 63:1514-1519, 1989
58. Taylor AJ, Frobisher C, Ellison DW, Reulen RC, Winter DL, Taylor RE, Stiller CA, Lancashire ER, Tudor ECG, Baggott C, May S, Hawkins MM: Survival after second primary neoplasms of the brain or spinal cord in survivors of childhood cancer: Results from the British Childhood Cancer Survivor Study. *J Clin Oncol* 27: 5781-5787, 2009
59. Tommasi AD, Occhiogrosso M, Tommasi CD, Cimmino A, Sanguedolce F, Vailati G: Radiation-induced intracranial meningiomas: Review of six operated cases. *Neurosurg Rev* 28: 104-114, 2005
60. Tsukamoto H, Yoshinari M, Okamura K, Ishitsuka T, Fujishima M: Meningioma developed 25 years after radiation therapy for Cushing's disease. *Intern Med* 31: 629-632, 1992
61. Vinchon M, Leblond P, Caron S, Delestret I, Baroncini M, Coche B: Radiation-induced tumors in children irradiated for brain tumor: A longitudinal study. *Childs Nerv Syst* 27:445-453, 2011
62. Walter JB, Israel MS: General pathology. Livingstone Churchill, Edinburgh, 681, 1974
63. Yamanaka R, Hayano A, Kanayama T: Radiation-induced meningiomas: An exhaustive review of the literature. *World Neurosurg* 97: 635-644.e8, 2017
64. Yousaf I, Byrnes DP, Choudhari KA: Meningiomas induced by high dose cranial irradiation. *Br J Neurosurg* 17:219-225, 2003

Table II: Reported Cases and Series of Radiation-Induced Meningiomas Obtained from the Literature (According to Our Best Knowledge)

Author; Year	Gender	Number of Pts/Cases	Mean Age(Yrs)	Category	Mean RT Dose (Gy)	Primary Diseases	Mean Latency (Yrs)	Multiplicity Rate (%)	Recurrence Rate (%)	WHO Grade of RIMs
Mann; 1953 (2)	F	1/3	9	Child	65 (VHD)	Optic nerve glioma	6	No	100% (x2)	III
Horanyi; 1965 (57)	F	1/1	7	Child	20 (MD)	Microsporosis	2	No	N/A	III
Pask; 1965 (60)	N/A	1/1	N/A	Adult	44 (VHD)	Pituitary adenoma	1	N/A	N/A	NOS
Feiring; 1968 (57)	F	1/1	30	Adult	LD?	Facial vascular nevus	28	No	No	I
Munk; 1969 (63)	3M: 2F	5/5	45.2	Adults	LD	Tinea capitis (2); Skin diseases of the head (2); Not remembered (1) pts	18 for 3 pts; N.M for 2 pts	No	No	Gr I (4); Mgth (3); Fib (1); No Bx (1)
Gautier-Smith; 1970 (57)	M	1/1	25	Adult	HD (>23)	Cerebellar Astrocytoma	15	N/A	N/A	NOS
Lawrence; 1970 (60)	N/A	1/1	N/A	Adult	HD (>35)	Pituitary adenoma	11	N/A	N/A	NOS
Waterson; 1970 (57)	M	1/3	36	Adult	LD?	Scalp infection	26	100% (+1)	50% (x1)	NOS
Beller; 1972 (63)	10M: 6F	16/19	41.8 22-45	Adults	LD	Tinea capitis (15); NOS (1)	34.3	No	18.8 (3/16)	Gr I: Fib (7); Mgth (4); Mix-ed (3); Psamm (1); NOS (1)
McCormick; 1972 (35)	M	1/1	21.5	Adult	51.8 (VHD)	Medulloblastoma	15	No	N/A	NOS
Schrantz; 1972 (57,59)	N/A	1/1	N/A	Adult	N/A	N/A	N/A	N/A	N/A	III (meningeal sarcoma)
Bogdanowicz; 1974 (57)	2M: 1F	3/3	39.3	Adults	66.6 (VHD); N.M (1)	Medulloblastoma (1); Acromegaly (1); Facial port wine nevus (1)	29.3	No	N/A	I (Psamm)
Modan; 1974 (50)	N/A	4/4	N/A	Adults	LD	Tinea capitis (4)	N/A	N/A	N/A	NOS
Noorwood; 1974 (57)	1M: 1F	2/3	16.8-35	Mixed	29.5 (HD)	Medulloblastoma (1); Optic nerve glioma (1)	15.5; 25	No	50% (x1)	NOS
Stock; 1975 (2)	M	1/1	36	Adult	70 (VHD)	Pituitary Adenoma	17	N/A	N/A	NOS
Tanaka; 1975 (57)	F	1/1	40	Adult	66.6 (VHD)	Oligodendroglioma	23	No	No	NOS
Bryk; 1976 (57)	N/A	6/6	N/A	Adults	LD	Tinea capitis	N/A	N/A	N/A	NOS
Shore; 1976 (57)	N/A	2/2	N/A	Adults	LD	Tinea capitis	19	N/A	N/A	NOS
Velibekov; 1976 (50)	N/A	20/20	N/A	Adults	LD	Tinea capitis	N/A	N/A	N/A	NOS
Waga; 1976 (57)	F	1/1	36	Adult	56 (VHD)	Cranioopharyngioma	13	No	No	Gr I (Fib)
Watts; 1976 (57)	F	1/1	17.1	Child	LD	Port-wine stain	17	No	N/A	NOS; surgery done after 6 yrs
Bojsen-Moller; 1977 (57)	M	1/1	9	Child	43.5 (VHD)	Ependymoma	7.5	No	N/A	III (meningeal sarcoma)

Author; Year	Gender	Number of Pts/Cases	Mean Age(Yrs)	Category	Mean RT Dose (Gy)	Primary Diseases	Mean Latency (Yrs)	Multiplicity Rate (%)	Recurrence Rate (%)	WHO Grade of RIMs
Komaki; 1977 (59)	N/A	1/1	N/A	Adult	N/A	N/A	N/A	N/A	N/A	III (meningeal sarcoma)
Kandel; 1978 (2)	F	1/1	53	Adult	70 (VHD)	Basaloma	10	No	No	I
Katakura; 1978 (2)	F	1/1	12	Child	36.5 (HD)	Ependymoma	9	No	N/A	III
Robinson; 1978 (50)	F	1/1	33	Adult	65 (VHD)	Medulloblastoma	21	No	No	Gr I (Trans)
Frazer; 1979 (2)	F	1/1	44	Adult	87.1(VHD)	Orbital fibrosarcoma	35	No	N.M	Gr I (Angio)
Spallone; 1979 (57)	2M: 1F	3/5	32.5	Adults	1 pt: 15 (MD); 2 pts: LD?	Tinea capitis (2); Facial vascular nevus (1)	24	66.7% (+2)	N.M	NOS
Pantronas; 1980 (2)	F	1/2	32	Adult	20 (MD)	Thyroid carcinoma	21	100% (+1)	No	NOS
Lacono; 1981 (35)	F	1/2	30	Adult	50 (VHD)	Medulloblastoma	27	100% (+1)	No	NOS
Meyrignac; 1981 (2)	F	1/1	54	Adult	53 (VHD)	Pituitary adenoma	20	No	No	NOS
Gomori; 1982 (59)	N/A	30/30	>30	Adults	LD	Tinea capitis (30)	>20	No	No	NOS
Pailas; 1982 (2)	M	1/3	16	Child	80 (VHD)	Pituitary adenoma	10	100% (+2)	No	NOS
Spallone; 1982 (2)	2F	2/2	36.5	Adults	64 (VHD)	Pituitary adenoma (2)	17 (12-22)	No	No	NOS
Yang; 1982 (59)	F	1/1	N.M	Adult	HD?	Pituitary adenoma	N/A	N/A	N/A	III
Gabibov; 1983 (59)	N/A	62/76	N/A	Adults	LD	Various scalp lesions (62)	N/A	23% (+14)	No	NOS
Park; 1983 (35)	M	1/1	15	Child	45 (VHD)	Medulloblastoma	13	No	No	NOS
Soffer; 1983 (51)	20M: 22F	42/54	N/A	Adults	LD	Tinea capitis (42)	36.8	14.3% (+6)	14.3% (+6)	Gr I (48); Gr III (6)
Abramson; 1984 (6)	N/A	1/1	19.5	Adult	30 (HD)	Retinoblastoma [Genetic disease]	19	No	N/A	NOS
Anderson; 1984 (35)	F	1/2	17	Child	43.4 (VHD)	Medulloblastoma	15.2	100% (+1)	No	I (Mgth)
Giaquinto; 1984 (59,63)	2M: 4F	6/7	46.6	Adults	LD	Tinea capitis (6)	36.1	16.7% (+1)	No	Gr I (6); NOS (1)
Iwai; 1984 (2,63)	M	1/1	49	Adult	LD	Scalp vascular nevus	37	No	No	I
Rubinstein; 1984 (2,57,63)	23M: 20F	43/61	5.9; 20; 66; N.M for 40 pts	Mixed	LD (40pt); 15 (MD) [2pt]; 25 (HD) [1pt]	Tinea capitis (40); Astrocytoma (1); ALL (1); T.Capitis+Basal cell carcinoma (1)	38 (5-50)	4.7% (x2)	11.6% (+11; 5 of them x >2 times)	Gr I (40); Gr II (2); Gr III (1) Mgth (26); Fib (8); Trans (5); Angio (4)
Tiberin; 1984 (15)	F	1/3	8.5	Child	24 (HD)	ALL	6.5	No	100% (x2)	III
Kolodny; 1985 (2,63)	F	1/1	45	Adult	67 (VHD)	Prolactinoma	22	No	No	I
Montanera; 1985 (2,63)	2M	2/2	28	Adults	48.8 (VHD)	Suprasellar astrocytoma (1); Ganglioglioma (1)	17.5	No	No	NOS (2)
Okamoto; 1985 (2,63)	1F: 1M	2/2*	32	Adults	55 (VHD); N/A (1pt)	Scalp hemangioma (1); Ventricular astrocytoma (1)	21.5	No	No	Gr I (2); Fib (1); Trans (1)
Potish; 1985 (15,51)	N.M	3/3	27.3	1 Child 2 Adults	NOS	ALL (1); Astrocytoma (1); Third ventricle tumor (1)	17.3	No	No	NOS (3)

Author; Year	Gender	Number of Pts/Cases	Mean Age(Yrs)	Category	Mean RT Dose (Gy)	Primary Diseases	Mean Latency (Yrs)	Multiplicity Rate (%)	Recurrence Rate (%)	WHO Grade of RIMs
Zirkin; 1985 (2)	M	1/1	49	Adult	30+20(VHD) [2 times]	Olfactory esthesioneuroblastoma	33	No	No	I
Draper; 1986 (6)	N.M	1/1	32.5	Adult	30 (HD)	Retinoblastoma [Genetic disease]	31	N.M	N.M	I
Hill; 1986 (2)	M	1/1	41	Adult	60+60(VHD) [2 times]	Sebaceous naevus	30	No	No	Gr I (Mixed)
Kato; 1986 (2)	F	1/1	14	Child	41.7 (VHD)	Third ventricle tumor	10	No	No	I (Trans)
Mariotti; 1986 (2)	M	1/1	32	Adult	65 (VHD)	Cystic Spongioblastoma	26	No	N/A	I
Radiographics; 1986 (20)	M	1/1	16	Child	HD?	Astrocytoma	7	No	No	NOS
Reynier; 1986 (2)	F	3/3	46.3	Adults	50 (VHD)	Suspected stoma breast cancer metastasis (Epithelioma) (1); Medulloblastoma (1); Astrocytoma (1)	23	No	No	NOS (3)
Cantini; 1987 (2)	M	1/1	20	Adult	48 (VHD)	Polar spongioblastoma	12	No	No	I
Kumar; 1987 (35)	1F: 1M	2/2	13-29	Mixed	40 (HD)	Medulloblastoma (2)	17.5	No	N/A	NOS (2)
Ojeda; 1987 (35)	M	1/1	29	Adult	36 (HD)	Medulloblastoma	23	No	N/A	NOS
Shibui; 1987 (6)	M	1/1	14	Child	39.6 (HD)	Retinoblastoma [Genetic disease]	14	No	No	Gr I (Fib)
Balasubramaniam; 1988 (15)	F	1/1	11.5	Child	50 (VHD)	Thalamic glioma	10	No	No	I
Karjalainen; 1988 (6)	F	1/1	48.5	Adult	63 (VHD)	Retinoblastoma [Genetic disease]	47	No	No	II
Kasantikuli; 1988 (60)	M	1/1	36	Adult	47 (VHD)	Pituitary adenoma	8	No	No	NOS
Moss; 1988 (2)	2M: 1F	3/4	13.3	Child	55-80-24 (Mixed)	Medulloblastoma (1); Retinoblastoma [Genetic disease] (1); ALL (1)	9.3	No	33.3% (+1)	Gr I (Mgth); Gr I (1); NOS (2)
Ron; 1988 (51)	N/A	18/18*	N/A	Adults	1.5 (LD)	Tinea capitis (18)	15-50	No	No	Gr I (17); Gr III (2)
Mazurovski; 1989 (59)	N/A	1/1	N/A	Adult	N/A	Cerebellar Astrocytoma	>20	No	No	NOS
Russell; 1989 (2,59)	2F	2/2	33.5	Adults	LD (1); HD (1)	Papilloma (1); Tinea capitis (1)	23.5	No	No	NOS (2)
Soffer; 1989 (57)	3M	3/5	26.8	Mixed	56.7(VHD)	Medulloblastoma (1); Metastatic MPE to brain (ependymoma) (1); Optic neve glioma (1)	15.7	33.3% (+1)	33.3% (x1)	Gr I (3); Trans (1); Angio (1); NOS (1); Gr III (1); No Bx (2)
Sridhar; 1989 (2,63)	F	1/1	N.M	Adult	N.M	Pituitary Adenoma	33	No	No	Gr I (Mgth)
Domenicucci; 1990 (63)	M	1/1**	24	Adult	40 (HD)	Low grade astrocytoma	11	No	No	I
Parent; 1990 (2)	F	1/1	65	Adult	HD?	Pituitary Adenoma	30	No	No	NOS

Author; Year	Gender	Number of Pts/Cases	Mean Age(Yrs)	Category	Mean RT Dose (Gy)	Primary Diseases	Mean Latency (Yrs)	Multiplicity Rate (%)	Recurrence Rate (%)	WHO Grade of RIMs
Partington; 1990 (2)	M	1/1	35	Adult	44.8 (VHD)	Pituitary Adenoma	9	No	No	Gr II (Mgth)
Tashima; 1990 (2)	1M: 1F	2/2	11.7; 55	Mixed	58.5 (VHD) 46 (VHD)	Medulloblastoma (1); Cushing (pituitary adenoma) (1)	11; 28	No	No	Gr I (2) (Mgth; Fib)
Harrison; 1991 (2,63)	2M: 5F	7/15	53.4	Adults	20, 40, 50, 1 pt received HD twice?, 2 pts: LD, 1 pt?	Tinea capitis (2); Fibrous dysplasia presumed sarcoma (1); Prepubertal gigantism (1); Thalamic glioma (1); Keloid (1); Astrocytoma (1)	42.7	28.6% (2x3)	42.9% (+3; one of them x3)	Gr I (4); Gr II (3)
Saleh; 1991 (2)	M	1/1	48	Adult	50 (VHD)	Pineal tumor	30	No	No	Gr I (Fib)
Donovan; 1992 (2,59)	M	1/1	11	Child	38 (HD)	AML	9	N.M	N.M	II
Gracia; 1992 (2)	F	1/1	37	Adult	LD	Cutaneous angioma	30	No	No	Gr I (Trans)
Hope; 1992 (35)	M	1/1	15.3	Child	HD	Medulloblastoma	13	No	No	Gr I (Trans)
Rusyniak; 1992 (2)	M	1/1	24.5	Adult	55 (VHD)	Left pontine glioma	3.5	No	No	I
Tomasina; 1992 (6)	N/A	1/2	N/A	N/A	HD?	Retinoblastoma [Genetic disease]	N/A	100% (+1)	No	Gr I (Fibroend- otheliomatous)
Tsukamoto; 1992 (60)	F	1/1	44	Adult	45 (VHD)	Pituitary adenoma (Cushing)	25	No	No	Gr I (Fib)
Ghim; 1993 (20)	1M: 1F	2/2	15.8	Children	20.5 (MD) 40.9 (VHD)	Thalamic glioma (1); Langerhans cell histiocytosis (1)	9; 14	No	No	Gr I (Mgth) (2)
Mack; 1993 (42)	2M: 8F	10/13	40.32	2 children 8 Adults	40.5 HD-VHD	Medulloblastoma (5); Acoustic neuroma (1); Astrocytoma (1); Chronic otitis (1); Ependymoma (1); Optic glioma (1)	24	30% (+3)	No	Gr I (7); Gr II (1); Gr III (2)
Newton; 1993 (2)	M	1/1	19	Adult	50 (VHD)	Pituitary adenoma	15	No	No	NOS
Pagni; 1993 (2)	F	1/2	56	Adult	49.5 (VHD)	Skin cancer	14	100% (+1)	No	NOS
Zenke; 1993 (2)	M	1/1	31	Adult	HD?	Ependymoma	25	No	No	NOS
Bliss; 1994 (2)	N/A	1/1	N/A	Child	HD	Recurrent pituitary adenoma	1	No	No	I
Darling; 1994 (2)	2F	2/2	17	Children	HD?	ALL (2)	14	No	No	Gr I (1); Gr II (1)
Findlay; 1994 (63)	2F	2/2	22	Adults	24 (HD)	ALL(2)	13.5	No	No	NOS
Kano; 1994 (2)	M	1/1	9	Child	50 (HD)	Craniopharyngioma	2	No	No	II
Matyjia; 1994 (63)	1M: 1F	2/2	28	Adults	HD?	Medulloblastoma (1); Low grade glioma (1)	18	No	No	NOS (2)
Paakko; 1994 (2)	2F	2/2	19.5	Adults	23 (HD)	ALL (2)	16	No	No	Gr I (Mgth) (1); No Bx (1)

Author; Year	Gender	Number of Pts/Cases	Mean Age(Yrs)	Category	Mean RT Dose (Gy)	Primary Diseases	Mean Latency (Yrs)	Multiplicity Rate (%)	Recurrence Rate (%)	WHO Grade of RIMs
Bette; 1995 (63)	F	1/2	68	Adult	LD?	Orthovoltage radiotherapy (scalp lesion)	63	100% (+1)	No	II
Dweik; 1995 (2)	F	1/3	27	Adult	55 (VHD)	Medulloblastoma	12	100% (+1)	100% (x1)	I (Mgth)
Foreman; 1995 (59)	M	1/1	25	Adult	20 (MD)	ALL	19	No	No	III
Kurihara; 1995 (2)	F	1/20	21	Adult	46.9 (VHD)	Subependymoma	20.5	100% (x20)	No	NOS; died
Levin; 1995 (59)	1M: 1F	2/2	43-47	Adult	LD	Tinea capitis (2)	N/A	No	No	I (2)
Musa; 1995 (44)	4M: 6F	10/17	49.7	Adults	HD	CA breast scalp metastasis (1); Orbital lymphoma (1); CNS leukaemia (2); Ependymoma (1); Ventricular tumor (2); Retinoblastoma [Genetic disease] (1); Nasopharyngeal tumor (1); Pituitary adenoma (1)	19.4	10% (+2)	10% (1 pt x5)	Gr I (9); Trans (1), Syncytial (1), NOS (7); Gr III (2)
Stein; 1995 (2)	F	1/2	28	Adult	24 (HD)	ALL	20	No	100% (x1)	II
Kado; 1996 (2)	M	1/1	32	Adult	HD?	Ectopic (left basal ganglia) germinoma	12	No	No	I
Lyons; 1996 (2)	F	1/1	52	Adult	40.7 (VHD)	Pituitary adenoma	25	No	No Bx	No Bx
Sadamori; 1996 (55)	10M: 35F	45/45	48	Adults	VHD?	The explosion of the atomic bomb (Nagasaki)	36	N.M	N.M	N.M
Salvati; 1996 (2)	1M: 1F	2/2**	74	Adults	50 (VHD)	Basaloma (2)	11	No	No	Gr II (2): Atypical Fib (1), Atypical Mgth (1)
Starshak; 1996 (2)	1M: 1F	2/2	9.5	Children	80-95.4 (VHD)	Medulloblastoma (1); Pineoblastoma (1)	2.75	No	No	Gr I (2): Mgth (1), Myxom (1)
Stein; 1996 (63)	2M	2/3	29	Adults	50, 80 (VHD)	Nasopharyngeal Carcinoma (2)	8	No	50% (x1)	Gr I (1) Trans (Recurrent); Gr II (1): Fib
Sznajder; 1996 (2)	2M	2/2	43; 52	Adults	75, 150 (VHD)	Enlarged tonsil (2) [Both of them NF-2 pts; genetic disease]	40; 48	No	No	NOS (2)
Bazin; 1997 (2)	F	1/2	45.1	Adult	HD?	Vascular nevus	45	100% (+1)	No	NOS
Chauvenic; 1997 (63)	F	1/3	47	Adult	100 (VHD)	Cushing Disease (Pituitary adenoma)	30	100% (+2)	No	NOS
Marconi; 1997 (63)	1M: 1F	2/4	37.5	Adults	LD; 47.1 (VHD)	Tinea capitis (1); Astrocytoma (1)	24	50% (+1)	50% (x1)	NOS (2)

Author; Year	Gender	Number of Pts/Cases	Mean Age(Yrs)	Category	Mean RT Dose (Gy)	Primary Diseases	Mean Latency (Yrs)	Multiplicity Rate (%)	Recurrence Rate (%)	WHO Grade of RIMs
O'Malley; 1997 (63)	M	1/2	28	Adult	40 (HD)	Medulloblastoma (1) [The patient had Basal cell nevus syndrome-genetic disease]	26	100% (+1)	No	NOS
Rao; 1997 (2)	M	1/1	43	Adult	67 (VHD)	Pituitary adenoma	16	No	No	NOS
Salvati; 1997 (63)	3M: 7F	10/11**	33.1	Adults	39.8 (HD-VHD)	ALL (4); Medulloblastoma (2); Pituitary adenoma (2); Carcinoma (1); Astrocytoma (1)	14.6	No	10% (x1)	Gr I (6): Fib (4), Mgtth (1), Trans (1); Gr II (4): Fib (2), Mgtth (2)
Svirii; 1997 (59)	F	1/1	N/A	Adult	LD	Benign brain parasellar tumor	15	No	No	I
Duffner; 1998 (63)	N/A	1/1	6	Child	HD	Medulloblastoma	3	N/A	N/A	NOS
Karlsson; 1998 (31)	N.M	20/20	N.M	Adults	17 pts<10 (LD); 3 pts ≥10 (MD)	Skin hemangiomas (20)	34	No	No	NOS
Nishio; 1998 (63)	2M: 3F	5/5	31.5	2 Child+ 3 Adults	1 pt: 24 (HD); 4 pts 51.5 (VHD)	Medulloblastoma (1); ALL (1); Astrocytoma (1); Ependymoma (1); Pituitary adenoma (Cushing) (1)	16.9	No	No	Gr I; Mgtth (3), Fib (2)
Pollak; 1998 (51)	10M: 8F	18/21	58	Adults	LD (17pt); HD (1pt)	Tinea capitis (17); Pituitary adenoma (1)	36.1	16.7% (+3)	Low	Gr I (15); Gr III (6)
Walter; 1998 (63)	3M: 7F	10/11	28.9	Adults	8 pts: 24 (HD); 2 pts: 45.5 (VHD)	ALL (10)	21.1	10% (+1)	No	NOS (10)
Chauvenic; 1999 (63)	N.M	1/1	N.M	Adult	55 (VHD)	Glioma (pt is NF-type 2)	23	No	No	NOS
Deutsch; 1999 (2)	M	1/1	42	Adults	30 (HD)	Hodgkin Lymphoma	27	No	No	I
Daentzer; 1999 (2)	F	1/1	30	Adult	HD?	Ependymoma	20	No	No	I
Melvin; 1999 (63)	M	1/1	54	Adult	HD?	Hodgkin's disease	39	No	No	NOS
Shintanii; 1999 (55)	N.M	68 />68	N.M	Mixed	VHD?	The explosion of the atomic bomb (Hiroshima)	9.4	Yes (N.M)	Yes (N.M)	Gr I (30): Mgtth (15), Fib (6), Trans (4), Psam (2), Angiomatous (2), Hemangioblastic (1); Gr III (2); NOS (36)
Spallone; 1999 (63)	F	1/2	69	Adults	LD	Tinea capitis	61	100% (+1)	No	NOS
Amirjamshidi; 2000 (15)	F	1/1	17	Child	45 (VHD)	Ependymoma	15	No	No	Gr I (Mgtth) C7-T2 spinal
Choi; 2000 (63)	F	1/1	21	Adult	24 (HD)	ALL	18	No	N.M	NOS

Author; Year	Gender	Number of Pts/Cases	Mean Age(Yrs)	Category	Mean RT Dose (Gy)	Primary Diseases	Mean Latency (Yrs)	Multiplicity Rate (%)	Recurrence Rate (%)	WHO Grade of RIMS
Ijiri; 2000 (15)	M	1/1	10	Child	HD	Ependymoma	8	No	N/A	Gr I (Xan)
Shoshani; 2000 (63)	2M: 5F	7/8	49.4	Adults	1.4 (LD)	Tinea capitis (7)	44.3	14.3% (+1)	No	Gr I (5); Mgth (3), secretory (1), Trans (1); Gr II (2): Hem-angiopericy (1)
Strojan; 2000 (63)	3M: 2F	5/11	13.5-42	Mixed	HD	ALL (2); Medulloblastoma (2); NHL (1)	9.5-31.5	40% (in 2 pts)	60% (in 3 pts)	Gr I (6); Trans (3), Mgth (2), Fib (1); Gr II (5); Trans (3), Fib (2)
Boljesikova; 2001 (63)	M	1/2	43	Adult	30 (HD)	Medulloblastoma	36	100% (+1)	No	I
Ghosai; 2001 (63)	M	1/1	26	Adult	56 (VHD)	Medulloblastoma	17	No	No	NOS
Jew; 2001 (63)	5M: 3F	8/14	42	Adults	3 pts: 47.6 (VHD); 1 pt: 30; 4 pts unknown	Ependymoma (1); Astrocytoma (1); ALL (1); Medulloblastoma (1); Acne vulgaris (1); Parotid tm(1); Graves ophthalmopathy (1); Craniopharyngioma (1)	26	12.5% (in 1 pt)	62.5% (in 5 pts)	Gr I (10); Mgth (8), Trans (2); Gr II (3)
Martin; 2001 (63)	F	1/1	36	Adult	HD	Hodgkin Lymphoma	9	No	No	NOS (cervical)
Zattara-Cannoni; 2001 (63)	N.M	6/7	30	Adults	3 pts: LD? 3 pts: HD?	Tinea capitis (2); Optic nerve glioma (1); Astrocytoma grade II (1); Skin angioma (1); Craniophrangioma (1)	30.85	No	16.7% (x1)	Gr I (3); Fib (2), Trans (1); Gr II (3); Atypical Fib
Juven; 2002 (31)	F	1/1	21	Adult	1-2 (LD)	Tinea capitis	18	No	No	NOS
Osipov; 2002 (46)	M	1/1	51	Adult	54 (VHD)	Recurrent pituitary adenoma	10	No	No	III; Died
Preston; 2002 (54)	74F:14M; 28F: 4M (autopsy)	88/88	N.M	Adults	VHD?	The explosion of the atomic bomb (Hiroshima and Nagasaki)	N.M	N.M	N.M	Gr I (84); Gr II (1); Gr III (3)
Sadetzki; 2002 (51)	1.9F: 1M	253/328***	43.6	Adults	N.M (LD?)	Tinea capitis (253)	36.3	11.5% (in 29 pts)	18.2% (in 46 pts)	Gr I (144); Syn (63), Trans(38), Fib (31), Psam (2), Ang (4), mixed (6); Gr III (1); NOS(108)
Santoro; 2002 (63)	M	1/2	48	Adult	41 (VHD)	Pituitary adenoma	30	No	100%	Gr II (atypical); Fib
Jenkinson; 2003 (63)	M	1/1	48	Adult	35 (HD)	Pilocytic astrocytoma	37	No	No	I
Loeffler; 2003 (63)	M	1/1	57	Adult	87 (VHD)	Pituitary adenoma (Acromegaly)	16	No	No	Gr I (Mgth)
Salvati; 2003 (63)	2M: 3F	5/5	40	Adults	30.4; 4 pts: HD, 1 pt: 50 (VHD)	ALL (3); Pituitary adenoma (1); Medulloblastoma (1)	19.4	No	No	NOS (5)

Author; Year	Gender	Number of Pts/Cases	Mean Age(Yrs)	Category	Mean RT Dose (Gy)	Primary Diseases	Mean Latency (Yrs)	Multiplicity Rate (%)	Recurrence Rate (%)	WHO Grade of RIMs
Yousaf; 2003 (64)	2M: 2F	4/5	42.25	Adults	3 pts: 41.9 (VHD); 1 pt HD?	Astrocytoma (2); Medulloblastoma (1); Hodgkin lymphoma (2)	21.25	25% (x1)	No	Gr I (4); Trans (3), Mgth (1); NOS (1)
Aguiar; 2004 (3)	1M: 1F	2/2	55, 18	Adults	VHD?	Low grade astrocytoma, Medulloblastoma	N.M	No	No	NOS
Al-mefty; 2004 (2)	7M: 9F	16/45	38.8	Mixed	HD	ALL (5); Pituitary adenoma (2); NHL (1); Face tm (1); Parotid tm (1); Nasal implant (1); Olfactory neuroblastoma (1); Craniopharyngioma (1); 4th ventr subependymoma (1); Retroauricular tm (1); Hypertrophic tonsil (1)	26.5	31.3% (in 5 pts)	100%	Gr I (10); Mgth (7), Trans (3); Gr II (5); Gr III (1)
Broniscer; 2004 (63)	2M 3F	2/4 3/3	6.6-7.6 13.5; 26.95	Child (2) Child (1); Adults(2)	HD? HD?	Medulloblastoma (2) [1st patient had Basal cell nevus syndrome and 2nd has NF-2 -genetic diseases] Classic medulloblastoma (1); Fibrillary astrocytoma Gr-II (1); Ependymoma (1)	5.7-5.6 12.4; 16.6	100% No	No No	Gr I (2) Gr I (3)
Gosztonyi; 2004 (63)	1M: 4F	5/8	52.5	Adults	LD?	Tinea capitis (microsporias) (5)	43.4	No	60% (in 3 pts)	Gr I (1); Trans; Gr II (4); Trans (2), Fib (1); Rec. Mixed (1)
Kadasheva; 2004 (6)	3F	3/3	31.7	1 Child 2 Adults	45.7(VHD)	Retinoblastoma [Genetic disease] (3)	36.7	No	No	Gr I: Fib (2); Gr II (1)
Kantar; 2004 (63)	M	1/1	16.5	Child	50 (VHD)	Embryonal-type rhabdomyosarcoma	8.5	No	No (progression after NTR)	II (Fib)
Pistolesi; 2004 (48)	M	1/6	34	Adult	52 (VHD)	Carcinoma of the tongue with metastases to lymph nodes and testicular lymphatic lymphoma	13	100%	100%	Gr II (2); Gr III (1); No Bx (3)
Shenoy; 2004 (54)	2M: 1F	3/5	34	1 Child 2 Adults	58.3 (VHD)	Grade II pilocytic astrocytoma (1); Pineal tm (1); (metastasis from choriocarcinoma, Parotid adenocarcinoma) (1)	15.3	33.3% (+1)	33.3% (x1)	II (5)
Ware; 2004 (63)	F	1/1	13	Child	108 (VHD)	Recurrent PNET	9	No	No	II

Author; Year	Gender	Number of Pts/Cases	Mean Age(Yrs)	Category	Mean RT Dose (Gy)	Primary Diseases	Mean Latency (Yrs)	Multiplicity Rate (%)	Recurrence Rate (%)	WHO Grade of RIMs
Campbell; 2005 (63)	F	1/3	18.5	Adult	24 (HD)	Medulloblastoma [The patient had Basal cell nevus syndrome-genetic disease]	17	100% (+2)	No	NOS
Caroli; 2005 (9)	M	1/1	9	Child	25 (HD)	Cutaneous angioma	5	No	No	Gr I (Mgth)
Jensen; 2005 (30)	6M: 10F	16/19	47.5 (27-70)	Adults	24 (HD)	Pituitary tumor (3); Astrocytoma (3); Brain tumors (2); Oligodendroglioma (1); Neuroblastoma (1); Glioma (1); ALL (1); Craniopharyngioma(1); Spindle cell tumor (1); Esthesioneuroblastoma (1); Tinea capitis (1)	32.3	12.5% (x2)	6.25% (x1)	No Bx (12) radiologically: Gr I (13); Bx (6): Gr I (4); Gr II (2)
Kaprelyan; 2005 (63)	F	1/3	63	Adult	80 (VHD)	Basal cell carcinoma	14	100% (+1)	100% (x1)	III
Korenkov; 2005 (63)	M	1/1	26	Adult	24 (HD)	ALL	23	No	No	III
Martinez-lage; 2005 (63)	F	1/2	27	Adult	4.5 (LD)	Benign astrocytoma	22.5	No	100%	I (Mgth)
Matsuda; 2005 (63)	F	1/2	39	Adult	24 (HD)	ALL	27	100%	No	I (Mgth)
Minniti [#] ; 2005 (63)	1M: 5F	6/6	34.7	Adults	45 (VHD)	Pituitary adenoma (6)	20.5	No	No	Gr I (5); Gr III (1)
Tommasi; 2005 (59)	2M: 4F	6/9	57.7	Adults	15 (LD-MD)	Tinea capitis (6)	40.2	33.3% (x2)	No	Gr I (3); Mgth (2), Fib (2); Gr II (2)
Barboza; 2006 (63)	F	1/1	50	Adult	54 (VHD)	Oligodendroglioma	20	No	No	II
Choudary; 2006 (15)	M	1/3	12.3	Child	HD	Medulloblastoma	1.3	100% (+2)	No	II
Hope; 2006 (43)	M	1/1	33	Adult	HD	Medulloblastoma	18	No	No	NOS
Neglia; 2006 (45)	33M: 33F	66/66 [†]	25.5 (12-57)	Mixed	HD?	Leukemia (31); CNS tumors (27); Hodgkin disease (1); NHL (3); Soft tissue sarcoma (3); Bone tumor (1)	17	N/A	N/A	Gr I (13); Gr II (47); Gr III (6)
Sheehan; 2006 (36)	1M: 1F	2/2	22	Adults	53-105 (VHD)	AVM (2): Treated with gamma knife	12.5	No	No Bx	No Surgery applied
Goshen; 2007 (22)	8M: 8F	16/24	28.7	Adults	24 (HD)	ALL and T-cell Lymphoma	21.1	18.75% (x3)	6.2% (x1)	NOS
Hijjiya; 2007 (27)	N.M	16/19	N.M	Adult	HD?	ALL (16)	20.6 (median)	18.75% (x3)	No	NOS
Kawahara; 2007 (63)	M	1/1	23	Adult	18 (MD)	ALL	20	No	No	II
Kim; 2007 (35)	M	1/2	35	Adult	57 (VHD)	Medulloblastoma	21	100% (+1)	No	II (2)

Author; Year	Gender	Number of Pts/Cases	Mean Age(Yrs)	Category	Mean RT Dose (Gy)	Primary Diseases	Mean Latency (Yrs)	Multiplicity Rate (%)	Recurrence Rate (%)	WHO Grade of RIMs
Balik; 2008 (6)	F	1/1	44	Adult	30 (HD)	Retinoblastoma [Genetic disease]	40	No	No	I (Mgth)
Brogman; 2008 (63)	F	1/1	12.8	Child	12 (MD)	ALL	5	No	No	NOS
Char; 2008 (11)	2M	2/4	32.5	Adults	24 (HD)	ALL (2)	29.5	50% (x3)	No	I (3); No surgery (1)
Greene; 2008 (24)	3M: 2F	5/5	16 (11-20)	Mixed (1 adult)	54.6 (VHD) (25-59.4)	ALL (1); Optic glioma (1); Metastatic retinoblastoma [Genetic disease] (1); Anaplastic astrocytoma (1); Medulloblastoma (1)	14 (9-19)	No	No	Gr I (5); Classic (1), Mgth (2), Fib (1), Trans (1)
Lillehei; 2008 (40) ^{***}	6M: 14F	20/45	44.6 (15-78)	Mixed (1 child)	4 pts: LD; 1 pt: 36 (HD); 15 pts: (45-55) (VHD)	ALL (4); Craniopharyngioma (2); Posterior fossa tumor (NOS) (1); Medulloblastoma (1); Scalp hemangioma (2); Otitis media (1); Tinea capitis (1); Pituitary adenoma (1); Optic glioma (1); Astrocytoma (1); Ganglioglioma (1); Oligoastrocitoma (1); NHL (1); Primary brain tm (1); Cerebellar tm (1)	31.1	40% (x4)	25% (x5)	Gr I (9); Mgth (5), Trans (3), Myxoid (1); Gr II (5); Gr III (3); NOS (6)
Lynch; 2008 (41)	M	1/6	50	Adults	LD	Tinea capitis	39	100% (+5)	20%	I (6)
Sasayama; 2008 (52)	M	1/1	23	Adult	30 (HD)	Medulloblastoma	22	No	No	Gr I (Mgth)
Singleton; 2008 (63)	F	1/3	10; 13; 27	Child	HD?	Medulloblastoma	7; 10; 24	100%	No	Gr I (Mgth, Trans); No Bx (1)
Banerjee; 2009 (7)	3M: 8F	11/24	28.5	1 Child; 10 Adults	21-46 (25.1) HD-VHD	ALL (11)	25.1	27.3% (x3)	18.2 (x2)	Gr I (8); Mgth (4), Fib (2), Trans (2); Gr II (1); No Bx (15)
Brassesso; 2009 (8)	M	1/1	14	Child	81.6 (VHD)	Medulloblastoma	12	No	No	Gr II
Hu; 2009 (28)	M	1/2	62	Adult	56 (VHD)	Astrocytoma grade IV (GBM)	7 months	No	100% (x1)	III; Died
Kondziolka; 2009 (36)	9M: 10F	19/24	39.5	1 child; 13 Adults	42.8 (VHD) for 5 pts; NOS (14)	Pituitary adenoma (4); Medulloblastoma (3); Leukemia (2); Astrocytoma (2); Pilocytic astrocytoma (1); Experimental (1); Oligodendroglioma (1); Pineal tm (1); Craniopharyngioma (1); Retinoblastoma [Genetic disease] (1); Rhabdomyosarcoma (1); Hemangioma (1)	29.7	26.3% (x5)	No Bx	Gr I (5); Gr II (2); No Bx (12)
Süslü; 2009 (63)	M	1/1	21	Adult	55 (VHD)	Medulloblastoma	13	No	No	Gr I (Mgth)

Author; Year	Gender	Number of Pts/Cases	Mean Age(Yrs)	Category	Mean RT Dose (Gy)	Primary Diseases	Mean Latency (Yrs)	Multiplicity Rate (%)	Recurrence Rate (%)	WHO Grade of RIMs
Taylor; 2009 (58) ^{###}	67M: 65F	132/144	N/A	19 Child; 113 Adults	6pts: LD; 12pts:MD; 60pts: HD; 28pts:VHD; 26pts: N.M	ALL (40); Various CNS neoplasms (70); Other tms (22) [5 out of them with genetic diseases; 1 high-grade: NF1, 2 low-grade: NF2, 1 low-grade: Gorlin's syndrome; 1 low-grade with tuberous sclerosis]	23.1 (6% of pts > 40); 23.1 for benign; 15.9 for malign	5% (x7)	N.M	Gr I (57); Gr II (7); Gr III (8); NOS (low-grade?) (58); meningiomatosis (NOS) (7)
Andrade; 2010 (3)	1M: 1F	2/3	23.5	Adults	54-108 [81] (VHD)	PNET (2)	18	50%	No	Gr I (2); Mght (2); No Bx (1)
Baheti; 2010 (5)	M	1/1	30	Adult	18 (MD)	ALL	21	No; w/ RIC in Pons	No	I (Trans)
Friedman; 2010 (18)	N/A (equal)	170/170	5-56	Mixed	HD-VHD	ALL (85); AML (2); Other leukemia (3); Astrocytomas (31); Medulloblastoma or PNET (25); Other CNS (12); Soft tissue sarcoma (5); Ewing sarcoma (1); NHL (5); Osteosarcoma (1)	22.7	N/A	N/A	Gr I (46); Gr II (113); Gr III (11)
Kamide; 2010 (39)	M	1/2	34	Adult	54 (VHD)	Medulloblastoma	29	100%; w/ 5 RICs and high-grade glioma	No	No Bx (2)
Paramanathan; 2010 (47)	F	1/1	21	Adult	54 (VHD)	Anaplastic Ependymoma	16	No; w/ RICs (3)	No	I
Azab; 2011 (4)	2F	2/3	17; 45	1 Child; 1 Adult	40, 54 (VHD)	Cerebellar pilocytic astrocytoma, Thalamic low-grade astrocytoma	14; 25	50%	No	Gr I (Mght) (3)
Lee; 2011 (39)	F	2/2	56-65	Adults	24-30 (HD)	Various Primary CNS Malignancies	1; 3.5	No	No	NOS (2)
Swanson; 2011 (56)	F	1/1	27	Adult	50 (VHD)	Intracranial Ependymoma	21	No	No	No Bx
Vinchon; 2011 (61)	10M: 8F	18/28	26.5	Adults	53.3 (VHD)	Medulloblastoma (1); N.M (17)	18.3	%53 (x10: in 10 pts)	N.M	NOS (17); GR III (Meningio-sarcoma) (1)
Yamaguchi; 2011 (63)	F	1/1	34	Adult	HD?	Glioma	23	No	No	Gr I (Mght)
Brassco; 2012 (8)	F	1/1	12	Child	52.6 (VHD)	Medulloblastoma	10	No	No	II (Mght)
Cernea; 2012 (10)	F	1/5	64; 70	Adult	LD	Tinea capitis	56	100%	100%	III
Chowdhary; 2012 (14)	10M: 4F	14/14	35.1	Mixed	41.3 MD-VHD	ALL (4); Astrocytoma (3); Orbit rhabdomyosarcoma (1); Medulloblastoma (1); Optic glioma (2); Scalp Hemangioma (1); Brain stem glioma (1); Intraventricular fibrosarcoma (1)	21.6	N.M	N.M	NOS

Author; Year	Gender	Number of Pts/Cases	Mean Age(Yrs)	Category	Mean RT Dose (Gy)	Primary Diseases	Mean Latency (Yrs)	Multiplicity Rate (%)	Recurrence Rate (%)	WHO Grade of RIMs
Elbaba; 2012 (15)	5M: 4F	9/21	15.2	Children	52 (VHD) (5); 30 (HD) (1); 16.7 (MD) (3)	Medulloblastoma (3); ALL (2); Ependymoma (2); AML (1); Acoustic schwannoma (1)	9.7	55.6% (x5: in 5 pts)	66.7% (in 6pts, 1 of them x2)	Gr I (8); Mgrth (5), Fib (2), Xant (1); Gr II (4); Gr III (1)
Galloway; 2012 (19)	6M: 4F	10/10	31.6	Adults	54.2 (VHD); 3 pts (N.M)	Medulloblastoma (3); ALL (3); Ependymoma (1); Astrocytoma (1); Low grade glioma (1); germ cell tm (1)	23.5	No	No	Gr I (5); Gr II (5)
Godlewski; 2012 (21)	9M: 17F	26/46	38.5	Adults	33.8 (HD-VHD); 1 pt (18)	ALL (7); NHL (3); Ependymoma (3); Astrocytoma (2); Medulloblastoma (2); CNS lymphoma (1); Ganglioneuroblastoma (1); Germinoma (1); Olfactory esthesioneuroblastoma (1); Leukemia (1); Nephroblastoma (1); Optic nerve astrocytoma (1); Pituitary adenoma (1); CNS tumor (NOS) (1)	26.5 (4-47)	38.5% (x10)	15.4% (x4 pts/+6 RIMs)	Gr I (31); Gr II (3); No Bx (3); NOS (3)
Kamoshima; 2012 (63)	F	1/1	20	Adult	50 (VHD)	Germinoma	14	No	No	II
Kaneko; 2012 (63)	M	1/1	22	Adult	N.M	ALL	20	No	No	Gr I (Mgth)
Kuhn; 2012 (37)	5M: 7F	12/24	53.1	Adults	52.9 (VHD) NOS (9)	Astrocytoma (3); Epidermoid carcinoma (1); Medulloblastoma (1); Tinea capitis (1); Lymphoma (1); Scalp hemangioma (1); Oligodendroglioma (1); Neuroblastoma (1); Ependymoma (1); Pituitary tm (1); Pilocytic Astrocytoma (1)	34.8	33.3%	No	Gr I (2); Gr II (4); NOS (6)
Kunert; 2012 (38)	4M: 4F	8/10	42.6	Adults	HD?	Pituitary adenoma (2); Pineal tm (1); Medulloblastoma (1); Thyroid tm (1); Anaplastic astrocytoma (1); Orbita rhabdomyosarcoma (1); Oligodendroglioma (1)	24	No	25% (x2)	Gr I (5); Psam (2), Trans (1), Fib (1), Mixed (1); Gr II (1); Gr III (2)
Sattler; 2012 (53)	1M: 1F	2/2	56.5	Adults	50 (VHD)	Pituitary Adenoma (2)	17	No	No	NOS (2)
Aras; 2013 (63)	M	1/3	13.6	Child	40 (HD)	Retinoblastoma [Genetic disease]	13	100%	100%	II
Chourmouzi; 2013 (13)	M	1/1	29	Adult	N.M	Medulloblastoma	19	No; w/ RICs (15)	No	Gr I (Mixed)
Copeland; 2013 (63)	M	1/1	60	Adult	30 (HD)	Scalp angioma	13	No	No	Gr I (Trans)
Eilyda; 2013 (16)	F	1/1	40	Adult	N.M	Pituitary adenoma	20	No	No	NOS

Author; Year	Gender	Number of Pts/Cases	Mean Age(Yrs)	Category	Mean RT Dose (Gy)	Primary Diseases	Mean Latency (Yrs)	Multiplicity Rate (%)	Recurrence Rate (%)	WHO Grade of RIMs
Johnson; 2013 (63)	F	1/2	71	Adult	HD	Olfactory neuroblastoma	7; 10	100% (+1)	No	II
Kon; 2013 (63)	F	1/1	38	Adult	50 (VHD)	Pituitary adenoma	22	No	No (after 8 yrs GBM)	Gr I (Fib)
You; 2013 (63)	M	1/3	20	Adult	54 (VHD)	Medulloblastoma	17	No	100% (x2)	II
Zhou; 2013 (63)	M	1/1	67	Adult	30 (HD)	Non-functional pituitary adenoma	31	No	No	Gr I (Mgth)
Efendioglu; 2014 (63)	M	1/1	15	Child	25 (MD)	HL	5	No	No	II
Chojnacka; 2014 (12)	N.M	5/6	18.5	Mixed	51 (VHD)	Medulloblastoma (1); Glioma grade IV (1); PNET (1); Ependymoma (2)	13.1	No	20% (x1)	Gr I (3); Gr II (1); Gr III (1)
Claus; 2014 (2)	N/A	22/22 [#]	N/A	Adults	HD	Various brain tumors	N/A	N/A	N/A	N/A
Goto; 2014 (23)	F	1/4	28	Adult	18 (MD)	ALL	25	100% (+3)	33.3% (x1)	Gr II (4)
Innocenti; 2014 (29)	F	1/2	N.M	Adult	HD?	Recurrent ventricular ependymoma	10	100% (+1)	No	I (Trans) (2)
Prabhu; 2014 (49)	3M: 1F	4/9	29.3	Adults	NOS	Nuclear facility meltdown (Chernobyl) (1); Medulloblastoma (1); ALL (2)	23.5	50% (x2)	75% (x3)	Gr I (2); Gr II (2)
Aboukais; 2015 (1)	6M: 3F	9/17	34	Adults	HD, VHD	Leukaemia (5); Lymphoma (1); Astrocytoma (1); Medulloblastoma (1); Cutaneous angioma (1)	23	44.4% (x4)	44.4% (x4)	II (17)
Felicetti; 2015 (17)	N.M	15/24	N.M	Adults	18-54 (MD-VHD)	ALL (8); Medulloblastoma (3); Ependymoma (2); Low grade glioma (1); Germ cell tm (1)	22.15	26.7% (x4)	33.3% (x5)	Gr I (5); Gr II (4); NOS (1); No Bx (5)
Hassaneen; 2015 (25)	5M: 5F	10/16	36.3	Adults	HD?	ALL (5); Medulloblastoma (2); Retinoblastoma [Genetic disease] (1); 2 pts were exposed to accidental environmental radiation following the meltdown of the nuclear reactor in Chernobyl 1986.	28.8	30% (x3)	30% (x3)	Gr I (3); Gr II (5); Gr III (2)
Kageji; 2015 (32)	M	1/2	50	Adult	42 (VHD)	Grade III anaplastic oligo-astrocytoma	14; 24	100% (+1)	No	Gr I (Mgth) (x2)
Scaringi; 2015 (63)	F	1/3	79	Adult	54 (HD)	Choroidal Melanoma	9	100% (+2)	No	Gr III (papillary)

Author; Year	Gender	Number of Pts/Cases	Mean Age(Yrs)	Category	Mean RT Dose (Gy)	Primary Diseases	Mean Latency (Yrs)	Multiplicity Rate (%)	Recurrence Rate (%)	WHO Grade of RIMs
Morgenstern; 2016 (43)	17M: 13F	30/44	34.7 (12.2-57.7)	Mixed	34 (16-60) (MD-VHD)	ALL (10); Medulloblastoma (8); Glioma (5); Retinoblastoma [Genetic disease] (2); Ependymoma (2); Lymphoma (1); Neuroblastoma (1); Sarcoma (1)	26 (8-51)	33.3% (x10)	19% (4 of 21 operated cases)	Gr I (12); Gr II (9); No Bx (9); 8 observed, 1 treated w/RTP
Present study; 2017	3M: 1F	4/6	47.3	Adults	49.7 (1: HD; 2: VHD); 1 Pt LD?	Medulloblastoma (2); Oligodendroglioma (1); Recurrent/chronic otitis (1)	29.6	33.3%; 1 pt w/multiple RICs & RIMs	No	Gr I (2): Fib (1), Trans (1); Gr II (1); No Bx (3)

M: Male; **F:** Female; **N/A:** not available; **N.M:** Not mentioned; **NOS:** not otherwise specified; **Syn:** Syncytial (i.e. meningiomethelomatous); **Trans:** transitional; **Fib:** fibroblastic; **Mgth:** meningiomethelomatous; **LD:** Low radiation dose (≤ 10 Gy); **MD:** Intermediate radiation dose ($>10 - \leq 20$ Gy); **HD:** High radiation dose ($>20 - \leq 40$ Gy); **VHD:** Very high dose (≥ 40 Gy); **? after dose:** Non determined radiation dose. **Gr:** grade; **I:** WHO grade I; **II:** WHO grade II (atypical meningioma); **III:** WHO grade III (anaplastic meningioma); **RIM:** Radiation-induced meningioma; **RIC:** Radiation-induced cavernous angioma; **w/:** With; **ALL:** Acute lymphoblastic leukemia; **AML:** Acute myeloid leukemia; **HL:** Hodgkin's disease/ Hodgkin's lymphoma; **NHL:** Non-Hodgkin's lymphoma; **+**: RIMs number; **x:** Pts number/ recurrence times; **Rec:** recurrent; **Xan:** Xanthomatous; **Myxom:** Myxomatous.

* Okamoto et al. (2,63) reported 3 patients, but one patient of them was reported in Waga, 1976 (57) paper (duplicated patient), therefore, only 2 patients of three considered.

*# Ron et al. (51) reported 4 out of 18 patients were reported by Modan et al.'s study (50).

** Salvati et al. reported 4 paper about RIM; 2 papers in 1996, 1 papers in 1997 and 1 paper in 2003. 1997 study was indicated that one of the reported ten cases was reported before in 1990 by Domenicucci et al. We thought that 1997 study was duplicated three other cases were published in Child's Nerv Syst in 1996. Therefore we did not re-write the same patients to avoid duplications (2,63,64).

*** Sadetzki et al. studied 253 patients with RIMs only 220 patients underwent surgery (the same authors re-studied 150 patients with RIMs genetically in another article, so we did not duplicated their cases) (51).

[†]Al-mefy's 16 cases thought to be duplicated in Claus study (in 1990, Almefty reported one case thought to be re-described in his later study in 2004) (2).

[‡]Minniti et al. in 2005 reported 6 cases, 2 out of them were reported in Brada et al.; 1992.

[§]Lillehei et al. (40) were reported 15 cases which published previously by Kleinschmidt-Demasters et al. in 1995 and 2006 and added new 5 cases (63).

[¶]The radiation doses were given in other study for authors which was published in 2010.

[‡]Friedman et al. (18) reported 170 cases that included 66 cases were reported in Neglia et al. study (45).

Note: These data were obtained from more than 240 references, the references cited in this table were not the original studies, we utilized from the review studies to minimize the references number as possible as the journal allows.