



## Case Report

DOI: 10.5137/1019-5149.JTN.22666-18.3

Received: 29.01.2018

Accepted: 13.06.2018

Published Online: 10.04.2019

# Diagnosis and Treatment of Hemorrhagic Cerebral Paragonimiasis: Three Case Reports and Literature Review

Qisheng WANG<sup>1,2</sup>, Liming HOU<sup>2</sup>, Liang LIU<sup>1\*</sup><sup>1</sup>The Affiliated Hospital of Southwest Medical University, Department of Neurosurgery, Luzhou, China<sup>2</sup>Hejiang City People's Hospital, Department of Neurosurgery, Luzhou, China

Corresponding author: Liang LIU ✉ liulst@163.com

## ABSTRACT

**AIM:** To investigate the clinical manifestations and radiologic characteristics in diagnosing and treating hemorrhagic cerebral paragonimiasis.

**MATERIAL and METHODS:** The study retrospectively analyzed the data of three cases of hemorrhagic paragonimiasis who received treatment in the hospital from January 2014 to March 2017. All three patients were diagnosed with paragonimiasis by positive detection of paragonimiasis antibody. Based on the imaging data, the disease was confirmed as hemorrhagic cerebral paragonimiasis. One of the three patients was treated with oral praziquantel alone, one with praziquantel and thoracentesis, and one with praziquantel in combination with closed thoracic drainage and craniotomy.

**RESULTS:** All the lesions disappeared after computed tomography scan during the follow-up. Two of the three patients had no dyspnea, and one had mild dyspnea.

**CONCLUSION:** Hemorrhagic cerebral paragonimiasis should be diagnosed as early as possible using antibodies against paragonimiasis for patients with unexplained intracerebral hemorrhage, especially young patients with atypical imaging findings and multiple systemic lesions. It is possible to avoid craniotomy and improve the cure rate by the early, full-dose, and sufficient course of anti-parasitic treatment.

**KEYWORDS:** Antibodies, Cerebral hemorrhage, Cerebral paragonimiasis, Neurosurgery, Praziquantel

## INTRODUCTION

Paragonimiasis has been widely reported in East Asia, South Asia, West Africa, and the Americas (1,2,5,16). In China, the disease is distributed mainly in northeastern, northern, and eastern areas, and in Sichuan province (10). Paragonimiasis is less commonly seen nowadays with the improvement in economic and environmental conditions. The intermediate hosts of Paragonimus include water crabs and other wild animals. Paragonimiasis is a parasitic subacute-to-chronic inflammatory disease of the lung in humans. Paragonimiasis rarely affects the nervous system (8).

## MATERIAL and METHODS

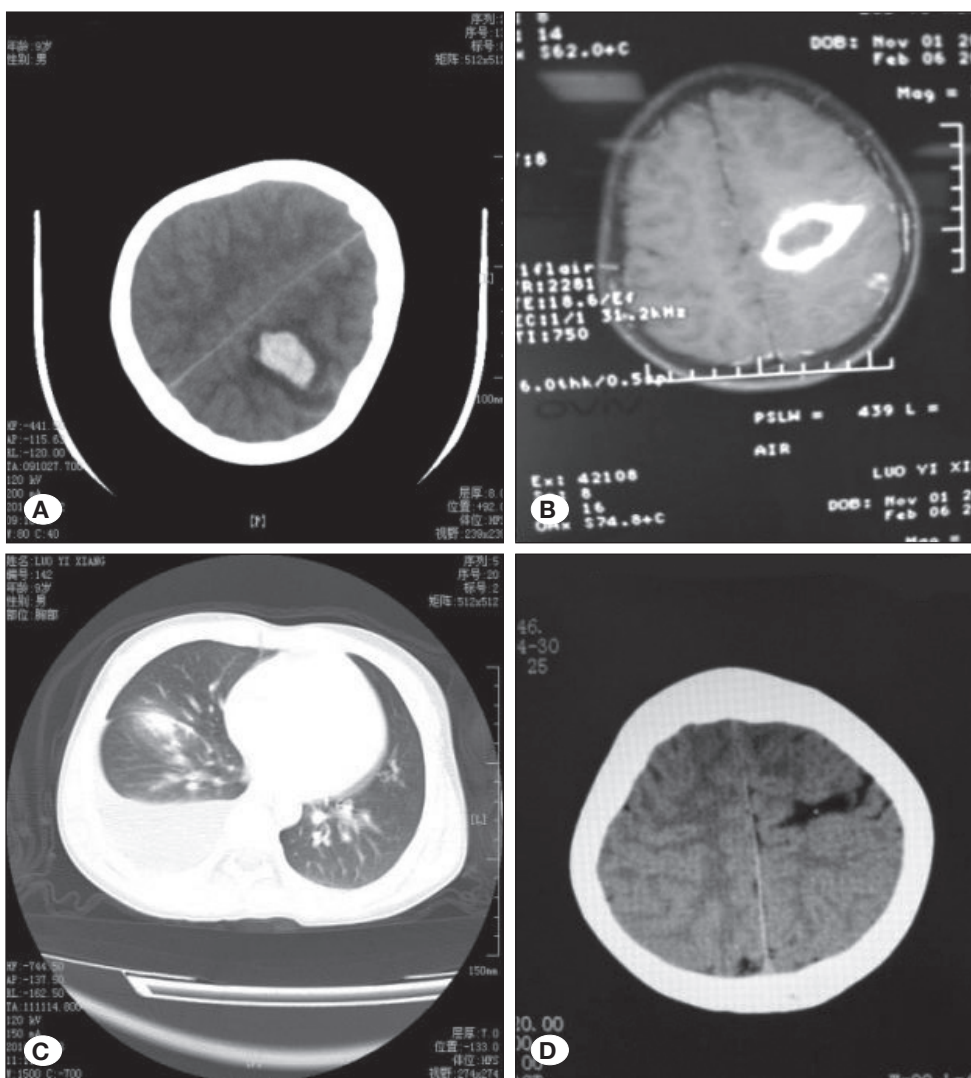
Three patients who were diagnosed with hemorrhagic cerebral

paragonimiasis from January 2014 to March 2017 showed cerebral hemorrhage. The cases were reported as follows.

**Case 1:** A boy aged 12 years 2 months, was hospitalized in January 2014 due to sudden right limb weakness for 12 h. The patient also had dizziness, right limb numbness, and repeated vomiting, with a history of eating raw crabs. The physical examination revealed unconsciousness, slurred speech, negative neck resistance, hypoesthesia of the right limb, muscle strength of 0 degrees, and the left limb with normal muscle strength. The blood test showed an eosinophil count of  $0.45 \times 10^9/L$ . Cerebral computed tomography (CT) (Figure 1A) indicated hemorrhage in the left parietal lobe, and cerebral CT angiography (CTA) did not find any aneurysm or vascular malformation. The magnetic resonance imaging (MRI) (Figure 1B) examination indicated a subacute hematoma in the left

parietal lobe, and chest CT suggested a moderate amount of right pleural effusion (Figure 1C). A chest puncture showed negative results for exudate culturing. The patient condition did not improve after receiving treatment for common intracerebral hemorrhage. The patient was suspected to have a parasitic infection considering the history of eating raw crabs and the combination of multisystem damage. The enzyme-linked immuno sorbent assay (ELISA) showed a positive result for *Paragonimus* immunoglobulin G (IgG) and negative results for other parasites. Thus, the patient was diagnosed with cerebral paragonimiasis and given oral praziquantel (Hongqi Pharmaceutical Co. Ltd. Shenyang, China 25 mg/kg, three times per day) for two courses, with 3 days for each course and 3 days for course interval. The patient was followed up after 1 year. The cerebral CT (Figure 1D) review showed a softened lesion in the left parietal lobe, and ELISA showed negative detection of *Paragonimus*. The muscle strength of the right limb increased to degree 4, and mild neurological dysfunction remained. The patient was capable of self-care.

**Case 2:** A boy aged 8 years 10 months, was hospitalized in November 2016 due to a headache for 4 days. The patient also had nausea, vomiting, and intermittent fever. The result of neurological examination was negative. A routine blood examination showed an eosinophil count of  $1.82 \times 10^9/L$ , and a cerebral CT (Figure 2 A) review suggested a subdural hematoma in the right temporal lobe and subarachnoid hemorrhage. After hospitalization, the patient was given conservative treatment for a common chronic subdural hematoma. However, 10 days later, the patient developed focal epileptic seizures in the left face and upper limbs, accompanied by paralysis symptoms; the muscle strength of the left limb was degree 3. A cerebral CT review identified a subdural hematoma (absorptive change) in the right frontotemporal lobe. Cranial MRI (Figure 2 B) suggested a subacute subdural hematoma in the right temporal lobe, and a blood test showed an increased eosinophil count. When asked, the patient admitted a history of eating raw crabs and was, therefore, considered to have a parasite infection. The ELISA examination of multiple parasites showed a positive result for *Paragonimus* IgG and negative



**Figure 1:** Imaging data of case 1. **A)** Cerebral CT upon hospitalization showed hemorrhage in the left parietal lobe. **B)** Cranial MRI upon hospitalization indicated a subacute hematoma in the left parietal lobe. **C)** Chest CT upon hospitalization showed right pleural effusion. **D)** Cerebral CT review after 1 year suggested that the hematoma was absorbed, and a softened lesion remained.

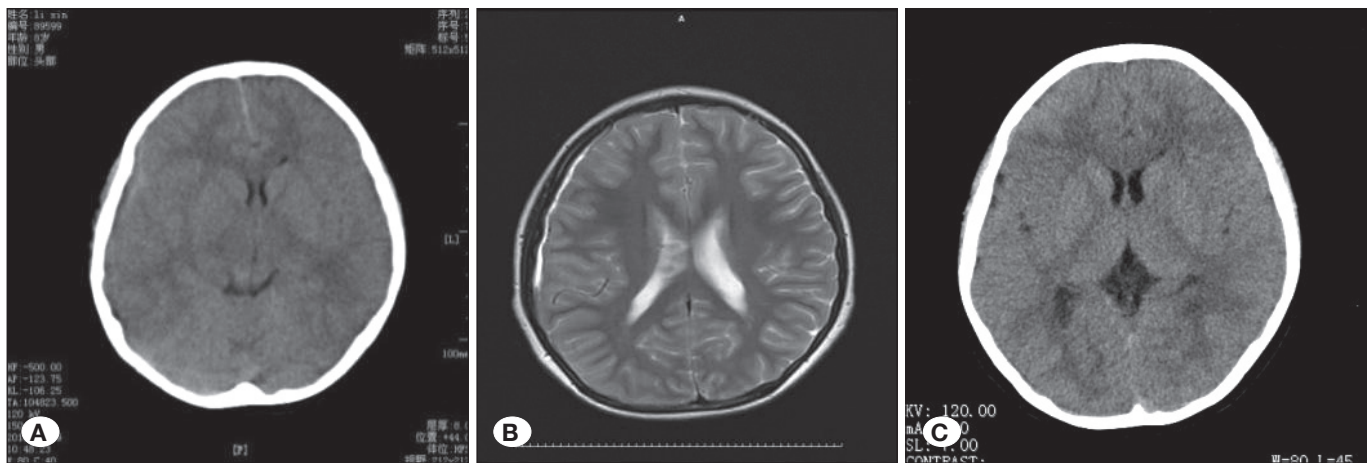
results for others. Therefore, the patient was diagnosed with cerebral paragonimiasis. Praziquantel (Hongqi Pharmaceutical Co. Ltd. Shenyang, China 25 mg/kg, three times per day) was administered orally for two courses, with 3 days for each course and 3 days for course interval. The patient was followed up after 6 months. The clinical symptoms disappeared with no neurological dysfunction. The cerebral CT (Figure 2 C) review showed that the hematoma was absorbed, and ELISA showed negative detection of *Paragonimus*.

**Case 3:** A male aged 23 years, was hospitalized in March 2017 due to dizzy pain for more than 4 days and chest discomfort for 3 days. Whether the patient had a history of drinking stream water or eating raw crabs was unknown. Neurological examinations showed negative results. A routine blood test showed an eosinophil count of  $0.04 \times 10^9/L$ . Cranial and chest CT (Figure 3A, B) indicated right temporo-occipital hemorrhage, which ruptured into brain ventricles. A fracture in the second and third right ribs was suspected, and the patient had a right pneumothorax, with a lung compression of 40% and a low-density shadow in the right anterior lobe of the liver. No vascular malformation was identified by cranial CTA. After hospitalization, the patient was given closed thoracic drainage to remove bloody pleural fluid in the right chest. After 12 days of conservative treatment, cranial CT (Figure 3C) indicated that the right temporo-occipital hematoma was absorbed, and chest CT review indicated that the pneumothorax disappeared. After 15 days, the patient asked for discharge because the symptoms improved, but 15 days later, he was again hospitalized due to repeated fever and aggregated dizzy pain for more than 8 hours. Cranial and chest CT (Figure 3D,E) suggested the following: right occipital parietal lesion; mild infection in the right upper and lower lung lobes (tuberculosis needed to be excluded); and low-density shadow in the right anterior lobe of the liver. Cranial enhanced MRI indicated a subacute late hematoma in the right occipital lobe (Figure 3F). A craniotomy performed considering the significant occupying effect and unclear property of the occupancy revealed jelly-like old hemorrhage.

The hematoma was completely evacuated during the surgery, and a postsurgical examination indicated hemorrhagic necrotic tissue; no eosinophils were identified. The result of tissue culture was negative. After surgery, a cranial CT review showed the complete removal of hematoma (Figure 3G). Parasitic infection could not be excluded considering bleeding and multiple lesions in organs such as brain, lung, and liver. As a result, ELISA suggested that the patient was positive for *Paragonimus* IgG but negative for other parasites. Therefore, the patient was diagnosed with cerebral paragonimiasis. Praziquantel (Hongqi Pharmaceutical Co. Ltd. Shenyang, China 25 mg/kg, three times per day) was administered orally for three courses, with 3 days for each course and 3 days for course interval. The patient was followed up after 1 month, and he did not have neurological dysfunction. The ELISA review after 2 months showed a negative result for *Paragonimus*.

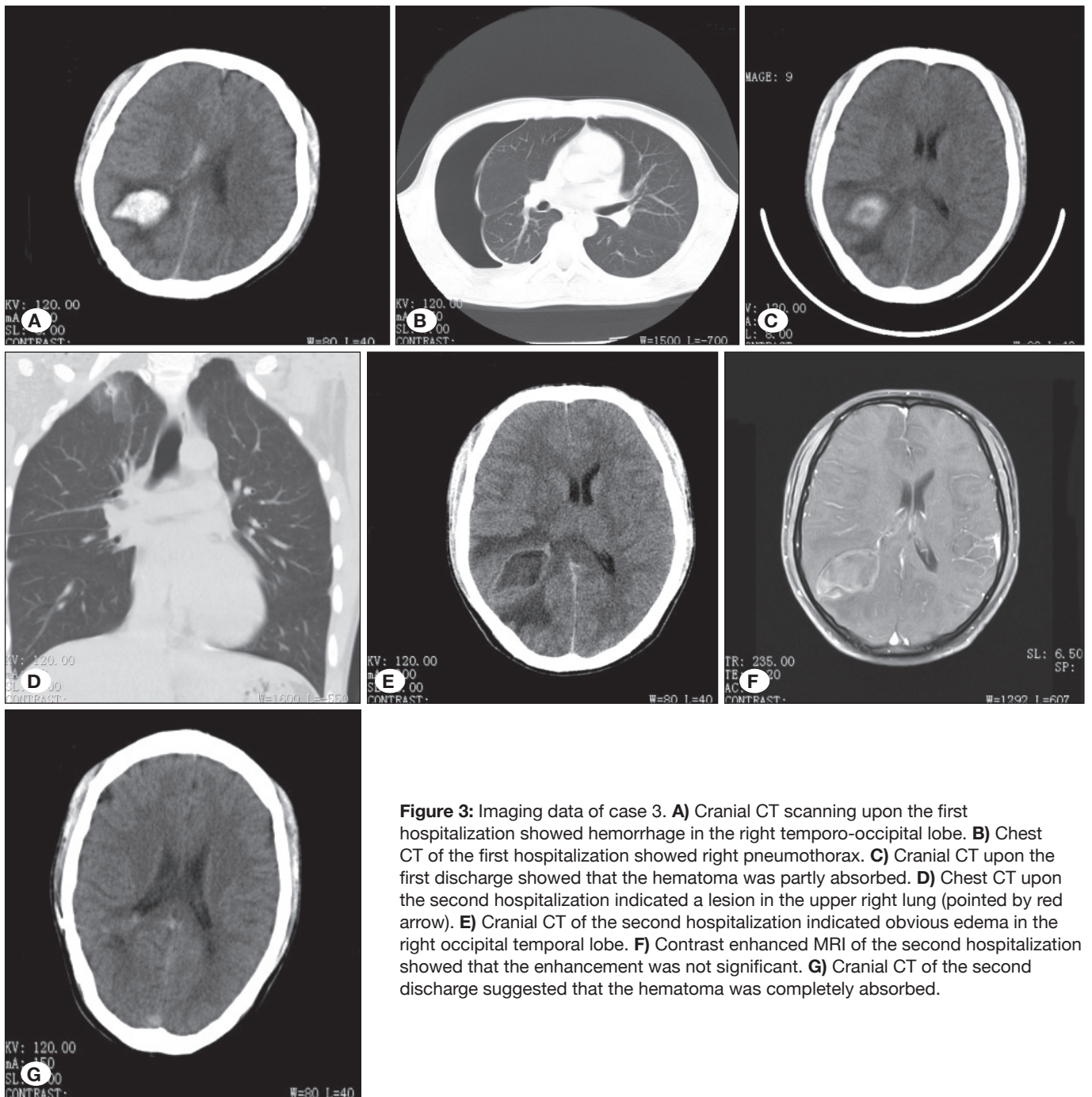
## DISCUSSION

The area of study was an endemic area of *Paragonimus*. People living in villages had a habit of drinking stream water and eating raw crabs. Therefore, the incidence of paragonimiasis was extremely high in the locality. Paragonimiasis has complex clinical manifestations. Of these, the most common is a subcutaneous mass in 60% of the cases. Abdominal and pleural lesions are also encountered, whereas lesions of the neurological system are extremely rare. Indeed, cerebral hemorrhage is a rare form of secondary paragonimiasis, more commonly seen in teenage patients (aged less than 18 years) (4). In this study, two out of three patients were aged less than 18 years, and one was aged more than 18 years. Of these, one had hemiplegia in combination with focal epileptic seizures, one had hemiplegia, and one had a headache in combination with chest discomfort. Two patients also had lung damage, one with pneumothorax and the other with hydrothorax. Both patients developed cerebral hemorrhage of varying degrees and different types, which was uncommon. It is particularly rare for one patient to have a chronic subdural hematoma. In addition, one patient was confirmed with lobar hemorrhage



**Figure 2:** Imaging data of case 2. **A)** Cerebral CT scanning upon hospitalization showed a right temporal subdural hematoma and subarachnoid hemorrhage. **B)** T2W cranial MRI upon hospitalization suggested a subacute subdural hematoma in the right temporal lobe. **C)** Cerebral CT review after 6 months showed that the hematoma was absorbed.





**Figure 3:** Imaging data of case 3. **A)** Cranial CT scanning upon the first hospitalization showed hemorrhage in the right temporo-occipital lobe. **B)** Chest CT of the first hospitalization showed right pneumothorax. **C)** Cranial CT upon the first discharge showed that the hematoma was partly absorbed. **D)** Chest CT upon the second hospitalization indicated a lesion in the upper right lung (pointed by red arrow). **E)** Cranial CT of the second hospitalization indicated obvious edema in the right occipital temporal lobe. **F)** Contrast enhanced MRI of the second hospitalization showed that the enhancement was not significant. **G)** Cranial CT of the second discharge suggested that the hematoma was completely absorbed.

using MRI, one was confirmed with lobar hemorrhage using MRI and surgery, and one was confirmed with subacute subdural hemorrhage using MRI. Two patients with lobar hemorrhage were excluded from vascular malformation using CTA scanning. All three patients were diagnosed with *Paragonimus* infection by positive antibody detection and confirmed with cerebral paragonimiasis in combination with imaging data. Of these, one patient was treated with oral praziquantel alone, one with oral praziquantel + thoracentesis, and one with oral praziquantel + closed thoracic drainage +

craniotomy. During the follow-up, one patient had neurological dysfunction and two did not have. The ELISA review yielded negative results for *Paragonimus* detection for all patients.

*Paragonimiasis* is easily misdiagnosed due to complex manifestations. The diagnosis of this disease depends mainly on epidemiological data, typical symptoms, and laboratory and radiological examinations (7). Chen et al. reported that 60% of children with *paragonimiasis* had a definitive history of eating raw crabs or drinking stream water within 2 years (4). Consistent with Chen's findings, two out of three patients in

the present study had a history of eating raw crabs. Imaging features were also of great importance for clinically diagnosing paragonimiasis. On CT images, the disease manifested as low-density edema, high-density shadow, brain swelling, and increased punctate, funicular, or annular density (9). On MRI images, the disease showed a typical “tunnel-like shape” or “ring-like shape” (15,17). Moreover, in the present study, one patient had an increased eosinophil count, and two did not have. This was inconsistent with the study of Yoshida et al., which suggested that 80% of patients had an increased eosinophil count (16). This might be associated with the low immune response of the body. Paragonimiasis could also be diagnosed by examining eggs of *Paragonimus* in patient’s lesions, pleural fluid, cerebrospinal fluid, or feces. However, the difficulty in sampling and low detection rate limited the use of this method (3,13,17). On the contrary, ELISA was an easy way to detect paragonimiasis antibody IgG4, with sensitivity, specificity, accuracy, and positive and negative predictive values of 100%, 94.6%, 96.2%, 100%, and 88.9%, respectively (14). Since case 1 had multiple-system damage and a history of eating raw crabs and case 2 had an increased eosinophil count and also a history of eating raw crabs, they were diagnosed timely by antibody detection and surgery was avoided. However, case 3 had an unknown history of drinking unboiled water or eating raw crabs; the eosinophil count was normal, and the presence of rib fracture and hemopneumothorax finally resulted in misdiagnosis of “trauma.” Consequently, the patient needed surgery due to lesion enlargement. Thus, *Paragonimus* infection should be considered for patients with unknown reasons of hemorrhage, particularly for young patients with atypical imaging features. Besides, the increased eosinophil count and the history of eating raw crabs or drinking raw water are not reliable indicators of paragonimiasis. Detection of serum antibody of *Paragonimus* should be performed timely to reduce misdiagnosis and prescribe anti-parasitic treatment as early as possible. Also, the ELISA review after treatment would help determine whether paragonimiasis was effectively controlled (12), and health education regarding the ill effects of drinking raw water or eating raw crabs or other wild animals would help reduce the incidence of paragonimiasis significantly (11).

Conservative medical treatment is often used for cerebral paragonimiasis, and oral praziquantel therapy is the first choice. Praziquantel can be given at a dose of 25 mg/kg three times a day and for 2–3 days. The dosage and course of treatment can be modified as appropriate for patients with severe infection (3). Also, patients should have a regular review. If the lesion is absorbed, surgery can be avoided, but if the lesion does not disappear and shows a significant massing effect, it should be surgically removed. Oral praziquantel treatment can prevent lung and brain complications, and reduce the operation rate (6). In this study, one patient was misdiagnosed with a traumatic brain hemorrhage and underwent surgery 1 month later due to the increased number of lesions, edema, and significant occupying effect. Therefore, early diagnosis and anti-parasitic treatment with adequate dose and course can help avoid surgery and increase the patient cure rate.

## REFERENCES

1. Aka NA, Adoubryn K, Rondelaud D, Dreyfuss G: Human paragonimiasis in Africa. *Ann Afr Med* 7(4):153-162,2008
2. Calvopiña M, Romero D, Castañeda B, Hashiguchi Y, Sugiyama H: Current status of *Paragonimus* and paragonimiasis in Ecuador. *Mem Inst Oswaldo Cruz* 109(7):849-855,2014
3. Chai JY: Paragonimiasis. *Handb Clin Neurol* 114:283-296, 2013
4. Chen J, Chen Z, Lin J: Cerebral paragonimiasis: A retrospective analysis of 89 cases. *Clin Neurol Neurosurg* 115(5):546-551, 2013
5. Doanh PN, Horii Y, Nawa Y: *Paragonimus* and paragonimiasis in Vietnam: An update. *Korean J Parasitol* 51(6):621-627, 2013
6. Diaz JH: Paragonimiasis acquired in the United States: Native and nonnative species. *Clin Microbiol Rev* 26(3):493-504, 2013
7. Koh EJ, Kim SK, Wang KC: The return of an old worm: Cerebral paragonimiasis presenting with intracerebral hemorrhage. *J Korean Med Sci* 27(11):1428-1432, 2012
8. Kohli S, Farooq O, Jani RB, Wolfe GI: Cerebral paragonimiasis: An unusual manifestation of a rare parasitic infection. *Pediatr Neurol* 52(3):366-369, 2015
9. Li Q, Qin DM: Application of CT and MRI in the diagnosis of paragonimiasis in brain and spinal cord. *Chinese Journal of Parasitology & Parasitic Diseases* 33(1):19-20, 2015
10. Liu Q, Wei F, Liu W, Yang S, Zhang X: Paragonimiasis: An important food-borne zoonosis in China. *Trends Parasitol* 24(7):318-323, 2008
11. Narain K, Devi KR, Bhattacharya S: Declining prevalence of pulmonary paragonimiasis following treatment & community education in a remote tribal population of Arunachal Pradesh, India. *Indian J Med Res* 141(5):648-652, 2015
12. Saeki S, Horio Y, Hirotsako S: Mucocutaneous manifestations of helminth infections: Nematodes. *Respirol Case Rep* 3(3): 92-94, 2015
13. Singh TS, Sugiyama H, Lepcha C, Khanna SK: Massive pleural effusion due to paragonimiasis: Biochemical, cytological, and parasitological findings. *Indian J Pathol Microbiol* (3):492-494, 2014
14. Wai P, Morakote N, Kong Y, Maleewong W: Evaluation of IgG4 subclass antibody detection by peptide-based ELISA for the diagnosis of human paragonimiasis heterotremata. *Korean J Parasitol* 51(6):763-766, 2013
15. Wang H, Shao B: Imaging manifestations and diagnosis of a case of adult cerebral paragonimiasis with the initial symptom of hemorrhagic stroke. *Int J Clin Exp Med* 8(6):9368-9373, 2015
16. Yoshida A, Hombu A, Horii Y, Maruyama H: Paragonimiasis in Japan: A twelve-year retrospective case review (2001-2012). *Intern Med* 54(2):179-186, 2015
17. Zhang JS, Huan Y, Sun LJ, Zhang GY: MRI features of pediatric cerebral paragonimiasis in the active stage. *J Magn Reson Imaging* 23(4):569-573, 2006