



Lamina Measurements with Computed Tomography for C2 Translaminar Screw Fixation in Pediatric and Adult Cases

Zakir SAKCI¹, Mehmet Resid ONEN², Murat YUCE¹, Safiye Sanem DERELI¹, Sait NADERI³

¹Umraniye Teaching and Research Hospital, Department of Radiology, Istanbul, Turkey

²VM Maltepe Medicalpark Hospital, Department of Neurosurgery, Istanbul, Turkey

³Umraniye Teaching and Research Hospital, Department of Neurosurgery, Istanbul, Turkey

Corresponding author: Mehmet Resid ONEN ✉ mresid@gmail.com

ABSTRACT

AIM: To measure C2-related morphometric parameters in a Turkish population.

MATERIAL and METHODS: The computed tomography (CT) images of three groups (Group 1: paediatric cases aged 1-6 years, Group 2: age 7-16 years, and Group 3: adult cases), who had cervical spine CT were used to measure some morphometric parameters for safe C2 translaminar screw fixation. The measured parameters included thickness, height and length of the C2 lamina on both sides and the C2 lamina-midline angle.

RESULTS: C2 lamina thickness at the thinnest point on the right and left sides was found to be 4.4 ± 0.5 mm and 4.6 ± 0.5 mm in Group 1, 5.3 ± 0.8 mm and 5.6 ± 0.8 mm in Group 2, and 6.8 ± 1.4 mm and 7.0 ± 1.5 mm in Group 3, respectively ($p > 0.05$).

The height of the C2 lamina at the thinnest point on the right and left sides was found to be 5.8 ± 0.8 mm, and 5.8 ± 0.7 mm in Group 1, 10.4 ± 1.4 mm and 10.6 ± 1.4 mm in Group 2, and 10.6 ± 1.8 mm, and 10.7 ± 1.5 mm in Group 3, respectively ($p > 0.05$).

The mean length of the C2 lamina was found to be 20.6 ± 2.4 mm in Group 1, 31.4 ± 4.1 mm in Group 2, and 36.7 ± 3.3 mm in Group 3 ($p < 0.05$). There was no significant difference between Group 2 and Group 3 in respect of mean lamina angle (44° vs 45°) but it was lower in Group 1 (35°).

CONCLUSION: This study revealed the appropriateness of C2 anatomy for safe C2 translaminar screw fixation.

KEYWORDS: C2, C2 translaminar screw fixation, Morphometric analysis

INTRODUCTION

Various techniques have been described in the literature for the treatment of atlantoaxial instability. These techniques include transarticular C1-C2 screwing, C2 pedicle screwing and C1 mass screwing or fixation techniques with hook (5). Although the C2 pedicle screwing technique is strong in terms of fusion success, there is a risk of vertebral artery damage especially in cases with a high-riding vertebral artery (14). Therefore, alternative operative techniques have been proposed. One of the options for axis fixation is C2 translaminar screwing (5). This has been shown to be biome-

chanically similar to other systems (5), but unlike other applications, an important advantage of the operation is that it does not require auxiliary methods such as intraoperative navigation and fluoroscopy, or related work on other anatomic components such as the vertebral foramen, pedicle and pars, and there is no risk of vertebral artery damage. Nevertheless, it remains important for the surgeon to have good knowledge of the C2 lamina structure. Although there is no risk of vertebral artery injury, there is a risk of injury to the spinal cord. The fact that the lamina angles and thicknesses are highly variable from one person to another limits this operation becoming a standard application.

Various published studies have examined the anatomic structure of the C2 lamina. In these studies, parameters such as lamina width, spinolaminar angles, and lamina length have been evaluated using computed tomography (CT) slices (6). Although several studies have reported no significant differences in anatomy, others have shown conflicting results (3-5). In addition to radiological studies, cadaveric measurement studies have also been published (6). In an article reviewing the anatomic evaluation studies of C2 lamina, Chytas et al. reported that there were differences in the values obtained in the studies (4). Therefore, the need for further measurement studies of different populations and age groups was emphasized.

The aim of this study was to present the CT morphometric measurements of C2 laminae in different age groups in the Turkish population.

■ MATERIAL and METHODS

The computed tomography (CT) images of 50 adult cases (28 females, 22 males) and 100 pediatric cases, who had cervical spine CT for subaxial cervical disc herniation, were used to measure some morphometric parameters for safe C2 translaminar screw fixation.

The cases were categorized into 3 groups as Group 1: paediatric cases aged 1-6 years, Group 2: age 7-16 years, and Group 3: adult cases.

The measured parameters included thickness, height and length of the C2 lamina on both sides and the C2 lamina-midline angle. The C2 lamina thickness was measured in 3 segments; segment A: the most lateral part of C2 lamina, segment B: middle segment located between segment A and C, and segment C: the most medial part of C2 beneath the base of the spinous processes. The C2 lamina height was measured in 3 segments, in the same locations as the segments defined for thickness. The length of the C2 lamina was measured on both sides as the distance of the midlaminar line connecting the outermost point of the C2 facet and the outer edge of the contralateral side of the spinous process. Lamina angle was defined as the angle between the midlaminar line and the midline.

Statistical analysis was applied using STATA version 11 software. Student's *t*-test was used to assess the level of statistical significance. A value of $p < 0.05$ was accepted as statistically significant.

■ RESULTS

Group 1 ($n=38$) comprised 20 females and 18 males with a mean age of 19.4 ± 11.3 months (range, 1-6 years). Group 2 ($n=62$) comprised 26 females and 36 males with a mean age of 140.3 ± 22.7 months (range; 7-16 years). Group 3 ($n=50$) comprised 28 females and 22 males with a mean age of 38.5 ± 6.3 years (range; 18-54).

In Group 1, C2 lamina thickness was found to be 6.5 ± 0.9 mm, 4.4 ± 0.5 mm and 5.9 ± 0.6 mm in zones A, B and C on the right side, and 6.4 ± 0.8 mm, 4.6 ± 0.5 mm and 5.9 ± 0.6 mm in zones A, B and C on the left side, respectively ($p > 0.05$).

In Group 2, C2 lamina thickness was found to be 9.3 ± 1.2 mm, 5.3 ± 0.7 mm and 7.6 ± 0.8 mm in zones A, B and C on the right side, and 9.4 ± 1.1 mm, 5.6 ± 0.8 mm and 7.4 ± 0.9 mm in zones A, B and C on the left side, respectively ($p > 0.05$).

In Group 3, C2 lamina thickness was found to be 10.9 ± 1.73 mm, 6.8 ± 1.4 mm and 10.8 ± 2.3 mm in zones A, B and C on the right side, and 11.8 ± 1.6 mm, 7.0 ± 1.5 mm and 10.5 ± 2.1 mm in zones A, B and C on the left side, respectively ($p > 0.05$).

In Group 1, the C2 lamina height was measured as 7.2 ± 0.8 mm, 6.2 ± 1.3 mm, and 5.8 ± 0.8 mm in zones A, B and C on the right side, and as 8.9 ± 2.3 mm, 8.1 ± 2.5 mm, and 7.5 ± 2.3 mm in zones A, B and C on the left side, respectively ($p > 0.05$).

In Group 2, the C2 lamina height was measured as 11.4 ± 1.5 mm, 11.1 ± 1.1 mm and 10.4 ± 1.4 mm in zones A, B and C on the right side, and as 11.4 ± 1.5 mm, 11.1 ± 1.2 mm and 10.6 ± 1.4 mm in zones A, B and C on the left side, respectively ($p > 0.05$).

In Group 3, the C2 lamina height was measured as 13.5 ± 2.4 mm, 10.6 ± 1.8 mm and 12.9 ± 4.7 mm in zones A, B and C on the right side, and as 13.9 ± 2.2 mm, 10.7 ± 1.5 mm and 12.9 ± 2.5 mm in zones A, B and C on the left side, respectively ($p > 0.05$).

In Group 1, the length of the right and left lamina was 20.6 ± 2.4 mm and 20.5 ± 2.4 mm, respectively ($p > 0.05$). Lamina angle was found to be $35.7 \pm 4.6^\circ$ and $36.4 \pm 4.5^\circ$ ($p > 0.05$).

In Group 2, the length of right and left lamina was 31.4 ± 4.1 mm and 31.4 ± 4.3 mm, respectively ($p > 0.05$). Lamina angle was found to be $44.0 \pm 4.6^\circ$ and $44.7 \pm 4.2^\circ$ ($p > 0.05$).

In Group 3, the length of the right and left lamina was 37.3 ± 3.7 mm and 36.7 ± 3.3 mm, respectively ($p > 0.05$). Lamina angle was found to be $45.2 \pm 3.4^\circ$ and $45.6 \pm 3.7^\circ$ ($p > 0.05$).

Statistical Analysis

In Group 3, although the lamina thickness measurements showed a statistically significant difference between males and females, the average thickness was measured as 6.88 ± 1.49 mm at the thinnest point of the lamina for both genders. Even the lowest value was found suitable for laminar screwing. At the thinnest point of the lamina, the mean value was 7.4 ± 1.5 mm and 7.5 ± 1.7 mm on the right and left sides respectively for males, and 6.4 ± 1.3 mm and 6.6 ± 1.1 mm on the right and left sides respectively for females (Table I; Figure 1A).

In Group 1, the thickness of the lamina at the thinnest point was measured as 4.4 ± 0.5 mm and 4.6 ± 0.5 mm on the right and left sides, respectively. In Group 2, it was 5.3 ± 0.8 mm and 5.6 ± 0.8 mm on the right and left sides, respectively.

In Group 3, lamina height was measured as 11.2 ± 2.3 and 10.8 ± 1.7 mm in males, and as 10.3 ± 1.2 mm and 10.6 ± 1.3 mm in females on the right and left sides, respectively ($p < 0.05$). In Group 1, lamina height was measured as 6.2 ± 1.3 mm, and in Group 2 as 11.1 ± 1.1 mm ($p < 0.05$) (Table II).

In Group 3, lamina length was measured as 39.8 ± 3.9 and 39.0 ± 3.0 mm in males, and as 35.6 ± 2.3 mm and $35.1 \pm$

2.5 mm in females on the right and left sides, respectively ($p < 0.05$). It was measured as 20.6 ± 2.4 mm and 20.5 ± 2.4 mm in Group 1, and as 31.4 ± 4.1 mm and 31.4 ± 4.3 mm in Group 2 ($p < 0.05$) (Table III; Figure 1B).

In Group 3, lamina angles on the right and left sides were measured as $45.1 \pm 3.3^\circ$ and $44.9 \pm 3.3^\circ$ in males, and as $45.2 \pm 3.5^\circ$ and $44.9 \pm 3.3^\circ$ in females, respectively ($p < 0.05$). The angle was measured as $35.7 \pm 4.6^\circ$ and $36.4 \pm 4.5^\circ$ in Group 1, and as $44.0 \pm 4.6^\circ$ and $44.7 \pm 4.2^\circ$ in Group 2 ($p < 0.05$) (Table IV; Figure 1C).

In Group 3, the entry distance was measured as 6.8 ± 1.7 mm and 7.0 ± 1.8 mm in males, and as 6.2 ± 1.7 and 6.3 ± 1.4 mm

in females on the right and left sides, respectively ($p < 0.05$). Entry distance was measured as 6.1 ± 1.7 mm in Group 1 and 1.9 ± 0.7 mm in Group 2 ($p < 0.05$) (Table V; Figure 1D).

DISCUSSION

Atlantoaxial stabilization is a fixation method used in the treatment of instability, which can develop due to many pathologies such as trauma, infections and tumors. As the anatomic structure of the atlas and axis vertebrae differs from other vertebrae and because of the close proximity to the vertebral artery and spinal cord, many studies have been conducted on the anatomic measurements and variations of

Table I: Lamina Thickness Measurements of the Groups

Lamina thickness		Group 1	Group 2	Group 3	p
Right	A	6.5 ± 0.9	9.3 ± 1.2	10.9 ± 1.7	$p < 0.05$
	B	4.4 ± 0.5	5.3 ± 0.8	6.8 ± 1.4	$p < 0.05$
	C	5.9 ± 0.6	7.6 ± 1.0	10.8 ± 2.3	$p < 0.05$
Left	A	6.4 ± 0.8	9.4 ± 1.1	11.8 ± 1.6	$p < 0.05$
	B	4.6 ± 0.5	5.6 ± 0.8	7.0 ± 1.5	$p < 0.05$
	C	5.9 ± 0.6	7.4 ± 0.9	10.5 ± 2.1	$p < 0.05$

Table II: Lamina Height Measurements of the Groups

Lamina height		Group 1	Group 2	Group 3	p
Right	A	7.2 ± 0.8	11.4 ± 1.5	13.5 ± 2.4	$p < 0.05$
	B	6.2 ± 1.3	11.1 ± 1.1	10.6 ± 1.8	$p < 0.05$
	C	5.8 ± 0.8	10.4 ± 1.4	12.9 ± 4.7	$p < 0.05$
Left	A	7.3 ± 0.9	11.4 ± 1.5	13.9 ± 2.2	$p < 0.05$
	B	6.2 ± 1.3	11.1 ± 1.2	10.7 ± 1.5	$p < 0.05$
	C	5.8 ± 0.7	10.6 ± 1.4	12.9 ± 2.5	$p < 0.05$

Table III: Lamina Angle Measurements of the Groups

Lamina angle		Group 1	Group 2	Group 3
Right		$35.7 \pm 4.6^\circ$	$44.0 \pm 4.6^\circ$	$45.2 \pm 3.4^\circ$
Left		$36.4 \pm 4.5^\circ$	$44.7 \pm 4.2^\circ$	$45.6 \pm 3.7^\circ$

p value between group 1 and 2: $p < 0.05$
p value between group 1 and 3: $p < 0.05$
p value between group 2 and 3: $p > 0.05$

Table IV: Lamina Length Measurements of the Groups

Lamina length		Group 1	Group 2	Group 3	p
Right		20.6 ± 2.4	31.4 ± 4.1	37.3 ± 3.7	$p < 0.05$
Left		20.5 ± 2.4	31.4 ± 4.3	36.7 ± 3.3	$p < 0.05$

Table V: Lamina Screw Entry point to the Spinous Process Distance Measurements of the Groups

Entry distance	Group 1	Group 2	Group 3
Right	1.9 ± 0.7	6.1 ± 1.7	6.5 ± 1.7
Left	1.9 ± 0.6	6.1 ± 1.8	6.4 ± 1.5

p value between group 1 and 2: $p < 0.05$

p value between group 1 and 3: $p < 0.05$

p value between group 2 and 3: $p > 0.05$

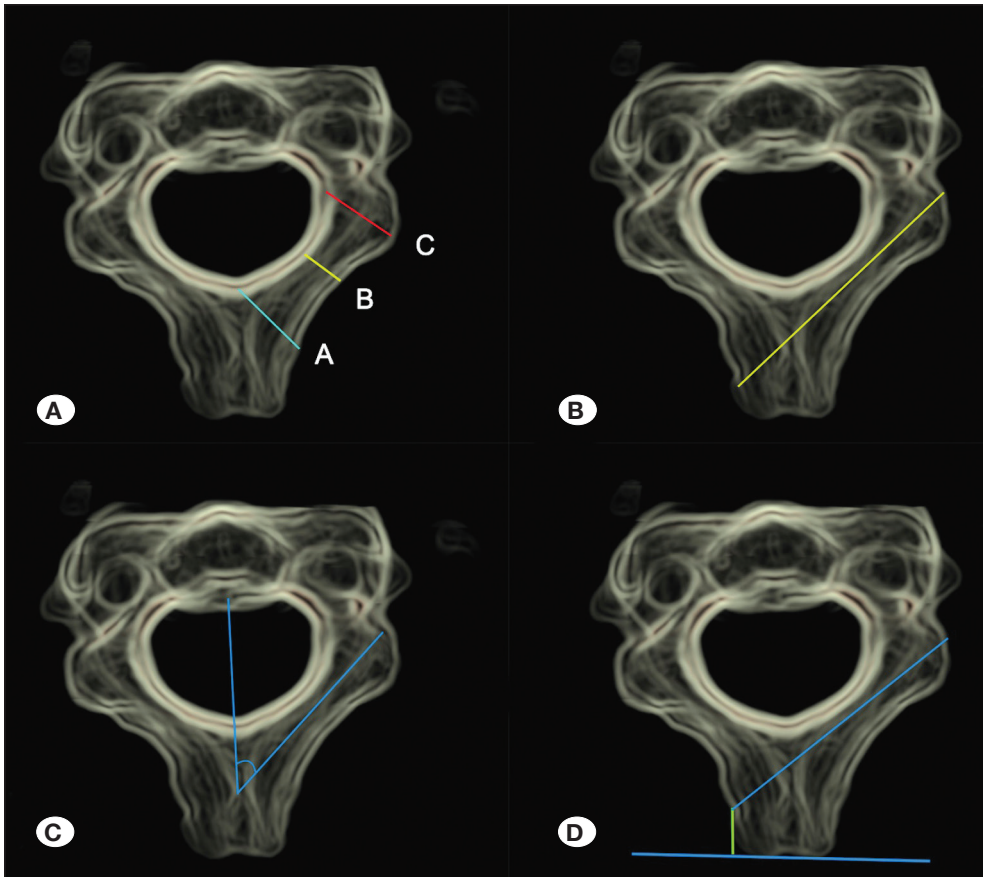


Figure 1: A) Lamina thickness measurements, B) lamina length measurement, C) lamina angle measurement, D) entry point measurement.

these structures (4). Although there is sufficient information about the pedicle anatomy of the C2 vertebra, the fact that there are many variations of the C2 vertebra and the pedicle thickness varies considerably from person to person has led to the search for different instrumentation techniques (3). At this point, C2 laminar screwing is a good alternative. Contrary to popular belief, there has not been shown to be any significant difference in biomechanical adequacy between laminar screwing and pedicle screwing (5,7,8). In a study comparing pedicle screw, traditional laminar screw and bicortical lamina screw, Dou et al. showed that the bicortical lamina screw has the strongest adhesion and there was no significant difference between pedicle screw and conventional laminar screw in this respect (5).

Biomechanical studies related to C2 lamina have been performed on adult vertebrae with ideal measurements, (5,9) but the biomechanical results of the pediatric age group, where the lamina structure is different from that of adults, are unknown.

Lamina thickness and width may be so thin that screwing is not possible in some cases, especially in the pediatric population. In some cases, the lamina screw on one side may have to be combined with the opposite side pedicle screw. Sometimes evaluation may be difficult with traditional two-dimensional CT images. Therefore, in a study by Chern et al. and Kim et al., it was emphasized that the evaluation of laminae on CT images with three-dimensional reconstruction instead of two-dimensional CT images would yield more objective results (3,6). When comparing morphometric cadaveric

measurements with CT measurements, CT evaluation allows more information to be obtained (4). However, biomechanical studies have shown that C2 translaminar screwing is a reliable technique (13).

In a review of C2 lamina studies for translaminar screw placements, Chytas et al. reported that all except two studies were conducted on the Asian population, which in general prevented an objective assessment (4). Therefore, the current study is important in terms of both being a non-Asian study and that all age groups were included. In most previous studies in literature, thickness has been measured from the outer lines of the lamina, and in some, both inner and outer thickness measurements were calculated.

In the largest series to date, of 200 cadavers, Cassinelli et al. calculated the C2 lamina external measurement as 5.77 ± 1.31 mm (2). In many studies this value varies between 5.5 and 6.9 mm (2). In two CT-based studies, Nakanishi et al. and Saetia and Phankongsab and measured internal transverse diameter averages of 4.2 ± 1.2 mm and 3.8 ± 0.1 mm, respectively (10,12). In all of these studies, the lamina measurements were higher in males. In a study by Kim et al., this measurement was mean 5.8 mm in males and 5.4 mm in females (6). Although most of the studies in the literature have been conducted on populations of eastern Asian origin, where the lamina sizes are relatively smaller, it can be concluded that more than 70% of cases are suitable for translaminar screwing (1,6,9,10).

In the current study, lamina thickness measurements were made from three different points on the outer boundaries. The reason for selecting this method was because there was a higher probability of making more objective measurements. It was thought that the evaluation of the inner borders of the lamina, the borders of the cortical bone and the spongy bone, would be more difficult and subjective (Figure 1A-D). A and C were the thickest parts of the lamina and the lowest value in adults was 7.6 mm (average 10.5 mm). At point B, which is the thinnest point of the laminae, it was observed that all adult cases were suitable for 3.5 and 4.0 mm diameter screws. In pediatric cases, it was observed that 50% of the cases aged <6 years did not have sufficient thickness and height for a 3.5 mm screw. Thinner screws with a diameter of 3.0 mm can be applied in these cases. However, the biomechanical sufficiency of screws of this size is not certain. In the pediatric group aged >6 years in the current study, it was observed that laminar screws could be securely placed in 93% of the cases. The lamina thicknesses of only 4 cases were measured at the limit values for a 3.5 mm screw.

In a study of 100 cases, Riesenburger et al. reported that the use of screws up to 28 mm is safe, and in screws over 33 mm, there is a potential risk of vertebral artery damage (11).

In the current study, lamina lengths were seen to vary between 30-45 mm (mean 36 mm) in adults. In pediatric cases, the length varied between 14.5 and 28 mm (mean 20 mm) in the younger group, and between 22 and 38 mm (mean 31.4 mm) in the older group. It was observed that in the first group 16-18 mm screws could be used and in the second group 28 mm long screws, which are also utilized in adults.

Unlike many other studies, it was observed that 100% of the current study adult cases were suitable for translaminar screwing and screws of up to 28 mm could be used safely, supporting the work of Reisenburger. In the pediatric group, preoperative evaluation should be done more carefully in patients under 6 years of age. In the second group, it was concluded that 28 mm screws could be comfortably placed as in adults.

The spinolaminar angle is the angle between the line drawn on the spinous processes parallel to the corpus in the transverse plane and the laminar line (Figure 1A-D). The importance of this angle is that it gives an idea of how laterally the screw should be placed in the transverse plane. When the angle is insufficient, the inner cortex may be penetrated and spinal cord damage may occur or when the angle is excessive, it may cross the outer cortex and cause the screw to come out. Saetia and Phankongsab measured mean laminar angle values as $56.4 \pm 6.7^\circ$ (12). In the current study, laminar angles in the adult group were measured in the average range of $42-44^\circ$. There was no significant difference between right and left laminar angles or between female and male groups. In the pediatric group over 6 years old, the laminar angles were on average 44° and were similar to the adult group. However, in the pediatric group under the age of 6 years, the lamina angles were found to be lower at an average of 36° .

This study also included a different assessment from other studies. The distance between the tip of the spinous process and the ideal point for laminar screwing was measured (Figure 1D). In adults, this value was measured as 6.5 ± 1.73 mm on the right and 6.4 ± 1.5 mm on the left, with no significant difference between males and females. In the pediatric group over 6 years of age, it was measured as 6.1 mm, which was close to the adult group. However, in the group under 6 years, this value was measured as 1.9 mm, and although quite short, it was not statistically significant. In the first group of pediatric cases, the biggest problem that this situation may cause is the feeling of the top of the screw on the skin due to the remaining parts above the end point of spinous process and thin fatty tissue in this age group. However, in the adult group, the distance is sufficient for the screw head to remain below the spinous process, thereby preventing the aforementioned problems even in weak cases.

■ CONCLUSION

C2 translaminar fixation is an important alternative to other screwing methods due to low complication rates and biomechanical adequacy. However, it is important to examine the lamina structure with preoperative CT. The results of this study have shown that translaminar screwing can be performed safely in all cases in adults. In the pediatric group over the age of 6 years, there were mostly seen to be the same features as in the adult anatomy. Contrary to expectations, it was seen that even in cases younger than 6 years old, translaminar screws can be placed in 50% of cases, although the entry point is very short compared to adults, and in some cases this technique is not suitable.

■ REFERENCES

1. Bhatnagar R, Yu WD, Bergin PF, Matteini LE, O'Brien JR: The anatomic suitability of the C2 vertebra for intralaminar and pedicular fixation: A computed tomography study. *Spine J* 10:896-899, 2010
2. Cassinelli EH, Lee M, Skalak A, Ahn NU, Wright NM: Anatomic considerations for the placement of C2 laminar screws. *Spine (Phila Pa 1976)* 31(24):2767-2771, 2006
3. Chern JJ, Chamoun RB, Whitehead WE, Curry DJ, Luerssen TG, Jea A: Computed tomography morphometric analysis for axial and subaxial translaminar screw placement in the pediatric cervical spine. *J Neurosurg Pediatr* 3(2):121-128, 2009
4. Chytas D, Korres DS, Babis GC, Efsthopoulos NE, Papadopoulos EC, Markatos K, Nikolaou VS: Anatomical considerations of C2 lamina for the placement of translaminar screw: A review of the literature. *Eur J Orthop Surg Traumatol* 28(3):343-349, 2018
5. Dou N, Lehrman JN, Newcomb AGUS, Kelly BP: A novel C2 screw trajectory: Preliminary anatomic feasibility and biomechanical comparison. *World Neurosurg* 113:93-100, 2018
6. Kim YJ, Rhee WT, Lee SB, You SH, Lee SY: Computerized tomographic measurements of morphometric parameters of the C2 for the feasibility of laminar screw fixation in Korean population. *Korean Neurosurg Soc* 44(1):15-18, 2008
7. Lehman RA Jr, Dmitriev AE, Helgeson MD, Sasso RC, Kuklo TR, Riew KD: Salvage of C2 pedicle and pars screws using the intralaminar technique: A biomechanical analysis. *Spine (Phila Pa 1976)* 33:960-965, 2008
8. Li L, Liu WF, Jiang HK, Li YP: Biomechanical evaluation of four different posterior screw and rod fixation techniques for the treatment of the odontoid fractures. *Int J Clin Exp Med* 8: 8571-8580, 2015
9. Ma XY, Yin QS, Wu ZH, Xia H, Riew KD, Liu JF: C2 anatomy and dimensions relative to translaminar screw placement in an Asian population. *Spine (Phila Pa 1976)* 35:704-708, 2010
10. Nakanishi K, Tanaka M, Sugimoto Y, Misawa H, Takigawa T, Fujiwara K, Nishida K, Ozaki T: Application of laminar screws to posterior fusion of cervical spine: Measurement of the cervical vertebral arch diameter with a navigation system. *Spine (Phila Pa 1976)* 33(6):620-623, 2008
11. Riesenburger RI, Jones GA, Roguski M, Krishnaney AA: Risk to the vertebral artery during C-2 translaminar screw placement: A thin-cut computerized tomography angiogram-based morphometric analysis: Clinical article. *J Neurosurg Spine* 19(2):217-221, 2013
12. Saetia K, Phankhongsab A: C2 anatomy for translaminar screw placement based on computerized tomographic measurements. *Asian Spine J* 9(2):205-209, 2015
13. Senoglu M, Ozbag D, Gumusalan Y: C2 intralaminar screw placement: A quantitative anatomical and morphometric evaluation. *Turk Neurosurg* 19(3):245-248, 2009
14. Wright NM, Laurusen C: Vertebral artery injury in C1-2 transarticular screw fixation: Results of a survey of the AANS/CNS section on disorders of the spine and peripheral nerves. American Association of neurological surgeons/congress of neurological surgeons. *J Neurosurg* 88:634-640, 1998