



# Microsurgical Clipping of Complex Basilar Bifurcation Aneurysms through Different Approaches: Surgical Techniques and Results

Hongguang WANG<sup>1,2\*</sup>, Yang SUN<sup>1\*</sup>, Yimu FAN<sup>2</sup>, Hongwu ZHANG<sup>1</sup>, Xiaoguang TONG<sup>1,2</sup>

<sup>1</sup>Tianjin Medical University, Clinical College of Neurology, Department of Neurosurgery and Neurorehabilitation, Tianjin, China

<sup>2</sup>Tianjin Huanhu Hospital, Department of Neurosurgery, Tianjin, China

\*Hongguang Wang and Yang Sun are co-authors, with equal contribution to this paper.

**Corresponding author:** Xiaoguang TONG ✉ tongxg@aliyun.com

## ABSTRACT

**AIM:** To explore the surgical approach, technique and clinical effect of treating basilar bifurcation aneurysms.

**MATERIAL and METHODS:** The clinical data of basilar bifurcation aneurysms treated by neuro-microsurgery are retrospectively analyzed in from September 2013 to September 2018. The aneurysms were treated via subtemporal approach and frontotemporal approach. The results were evaluated according to Glasgow Outcome Scores (GOS) and postoperative imaging results.

**RESULTS:** There were 28 aneurysms located at the bifurcation of basilar artery in 27 patients and 1 case had multi-aneurysms. 8 cases underwent via subtemporal approach and 19 via frontotemporal approach. The operation time was 2.8-4.6 hours, the average time were 3.3 hours. The hospitalization time was 3-6 weeks, the average time was 3.8 weeks. Overall, good outcome (GOS score of 4-5) at 6 months was achieved in 77.8% of the living patients. The posterior thalamic perforator artery infarction occurred in 1 cases, and the ventriculoperitoneal shunting was performed in 2 cases due to communicating hydrocephalus. During the following-up period, 25 patients underwent head CTA examination. The CTA showed that all aneurysms were completely clipped, no aneurysm recurrence was found, the blood flow of the parent artery was unobstructed, and 2 patients were lost to follow-up. 13 patients had oculomotor nerve palsy, and all but 3 of them recovered during following-up.

**CONCLUSION:** The satisfactory results were achieved by microsurgical clipping for basilar bifurcation aneurysms. According to the location and projection of aneurysms, personalized treatment is chosen. Trans-frontotemporal approach is the most suitable approach for the treatment of upper basilar bifurcation aneurysms, especially under subarachnoid hemorrhage causing brain swelling conditions.

**KEYWORDS:** Basilar artery aneurysm, Microsurgery, Frontotemporal approach, Subtemporal approach

**ABBREVIATIONS:** **GOS:** Glasgow outcome scores, **CTA:** Computed tomography angiography, **DSA:** Digital subtraction, **SAH:** Spontaneous subarachnoid hemorrhage

## INTRODUCTION

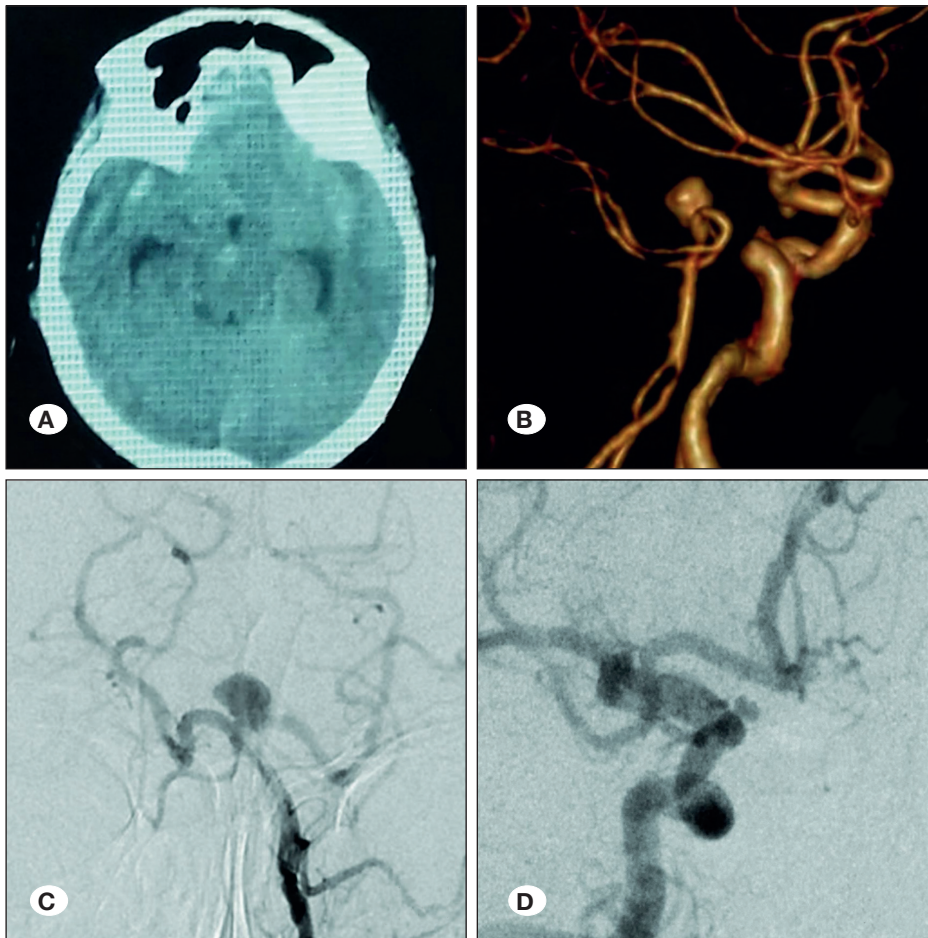
Basilar artery bifurcation aneurysms are intracranial aneurysms in which the basilar artery originates from both branches of the posterior cerebral artery. Surgical treatment is challenging because of their deep location, complex anatomy, abundant perforating vessels, and large and irregular shapes (2). Because of the advancement of interventional techniques, most of these aneurysms can achieve good results through coiling (17,22).

However, microsurgical clipping is still applicable to basilar artery bifurcation aneurysms, especially in complex aneurysms (22). A well-known subtemporal approach by Gonzalez (2) and a frontotemporal approach (the pretemporal transzygomatic transcavernous approach) by Krish (6) have been commonly used by most neurosurgeons to treat basilar artery bifurcation aneurysms. At present, the treatment of this kind of aneurysm is mainly a single approach reported in the literature, and few studies have compared the two approaches according to the characteristics of aneurysms. The aims of the present study were to introduce the experience of individualized selection of surgical approach according to the anatomic relationship and preoperative imaging examination of aneurysms and to compare the indications for the two surgical approaches for this type of aneurysm.

## MATERIAL and METHODS

### Clinical Data

Twenty-seven patients with basilar bifurcation aneurysms admitted to the neurosurgery department of our hospital from September 2013 to September 2018 were enrolled in this study. Among them, 11 were males and 16 were females, ranging in age from 41 to 72 years, with an average age of 56.1 years. The presence of basilar bifurcation aneurysms was confirmed with digital subtraction angiography (DSA) (Figure 1), which found a total of 28 aneurysms (including 1 multiple aneurysm located in the left internal carotid artery ophthalmic segment). The diameters were 2-15 mm, and the parent artery was the basilar artery. All of them were diagnosed with spontaneous subarachnoid hemorrhage (SAH), including 2 cases with intraventricular hematoma. The clinical manifestations were sudden severe headache in 27 cases, meningeal irritation in 27 cases, nausea and vomiting in 24 cases, and visual impairment in 1 case. The Hunt-Hess scale showed grade II aneurysms in 23 cases, grade III in 3 cases and grade IV in 1 case. The Fisher score was estimated for bleeding volume: grade 2 in 4 cases, grade 3 in 20 cases and grade 4 in 3 cases (Table I).



**Figure 1:** The patient (case 21 in Table I) was hospitalized for 2 days due to sudden headache and vomiting. **A)** The preoperative axial CT showed subarachnoid hemorrhage; **B)** the preoperative CTA showed basilar bifurcation aneurysm; **C)** the DSA (posterior anterior) showed basilar bifurcation aneurysm; **D)** the DSA showed the other aneurysm locating in the right ophthalmic segment of the internal carotid.

Table I: Patient Characteristic and Clinical Data

No	Gender/ Age (Year)	Size (mm)	H&H Grade	Fisher grading	Location	Relationship with PCP	Dome projection	Approach	Postoperative complications	Radiological outcomes	GOS (Follow- Up)
1	41/M	4 x 5	II	2	BA	Above	Anterior	FA	None	CO	4
2	51/M	6 x 5	II	3	BA	Above	Anterior	SA	None	CO	4
3	48/F	2 x 3	II	3	BA	Above	Anterior	FA	None	CO	5
4	56/M	6 x 6	II	2	BA	Below	Posterior	SA	None	CO	5
5	61/F	5 x 7	IV	3	BA	Above	Anterior	FA	CN III Palsy	CO	3
6	58/F	6 x 4	II	3	BA	Above	Posterior Inferior	FA	None	CO	4
7	47/M	5 x 8	II	3	BA	Below	Posterior	SA	None	NCO	4
8	58/F	5 x 7	II	3	BA	Above	Anterior	FA	None	CO	4
9	51/F	5 x 9	III	4	BA	Above	Anterior	FA	Hydrocephalus	CO	3
10	63/M	7 x 11	II	3	BA	Above	Anterior	FA	None	CO	4
11	55/F	6 x 8	II	2	BA	Above	Posterior	FA	None	CO	5
12	54/F	3 x 6	II	3	BA	Above	Anterior	FA	None	CO	4
13	47/M	6 x 9	II	3	BA	Below	Posterior Inferior	SA	None	CO	4
14	68/F	4 x 4	II	3	BA	Above	Anterior	FA	Pneumonia	CO	N/A
15	59/M	9 x 10	II	3	BA	Below	Posterior Inferior	SA	CN III Palsy	NCO	4
16	53/F	8 x 11	II	2	BA	Above	Anterior	FA	None	CO	5
17	43/M	9 x 7	II	3	BA	Below	Posterior	SA	None	CO	4
18	66/F	2 x 3	II	3	BA	Above	Anterior	FA	None	CO	5
19	69/F	3 x 5	III	4	BA	Above	Anterior	FA	CN III Palsy Hydrocephalus	CO	3
20	73M	4 x 5	II	3	BA	Above	Anterior	FA	None	CO	N/A
21	59/F	7 x 8 2 x 3	II	3	BA, OA	Above None	Anterior Inferior	FA	None	NCO	5
22	51/F	5 x 5	II	3	BA	Above	Anterior	FA	Pneumonia	CO	4
23	60/F	4 x 6	II	3	BA	Below	Anterior	SA	None	CO	4
24	50/M	9 x 15	II	3	BA	Above	Anterior	FA	None	CO	5
25	72/F	3 x 4	II	3	BA	Below	Posterior	SA	None	CO	5
26	48/M	4 x 6	III	4	BA	Above	Anterior	FA	Thalamic infarct	CO	3
27	52/F	3 x 5	II	3	BA	Above	Anterior	FA	None	CO	4

**HH:** Hunt-Hess, **SAH:** Subarachnoid hemorrhage, **F:** Female, **M:** Male, **BA:** Basilar bifurcation, **OA:** Ophthalmic artery, **FA:** Frontotemporal approach, **SA:** Subtemporal approach, **PCP:** Posterior clinoid process, **CO:** Complete occlusion, **NCO:** Nearly complete occlusion.

## Research Methods

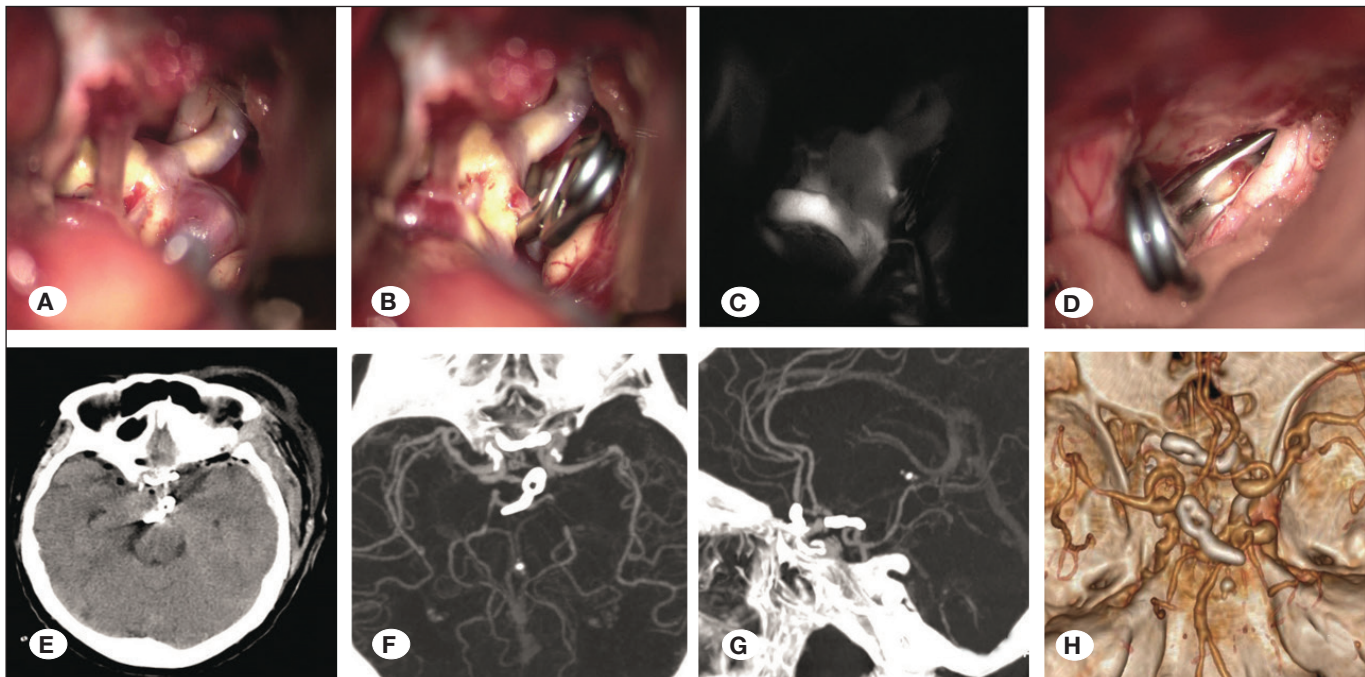
None of the patients were able to receive interventional embolization because of economic and vascular tortuosity. Craniotomy via subtemporal or frontotemporal injection was performed under general anesthesia. The subtemporal approach is suitable for the treatment of low aneurysms with a posterior projection that are slightly higher, flat or lower than the posterior clinoid process. The frontotemporal approach is mainly suitable for upper aneurysms with a forward projection, when the body of the aneurysm is larger and the neck width is wide; and the top of the basilar artery is higher than the posterior clinoid process. All 27 patients received surgical treatment within two weeks after admission.

**Subtemporal approach:** The patient was in the left supine position and underwent lumbar cistern drainage. Right temporal craniotomy was selected with a flat bone window in the middle cranial fossa base. The next steps were to perform lumbar cistern drainage to release cerebrospinal fluid, to enter from the base of the temporal lobe after brain tissue collapse, to cut the tentorium of the cerebellum and to expose the P2 segment of the posterior cerebral artery. Then, the proximal part was separated and revealed, including the bilateral P1 segment, basilar artery and neck of the aneurysm. After satisfactory separation, the aneurysm was clipped. **Transfrontotemporal approach:** The patients were routinely treated in the supine

position and the frontotemporal craniotomy was achieved via an interfascial approach. The relationship between the neck of the aneurysm and the posterior clinoid process was evaluated emphatically. When the neck of the aneurysm was 1.5 cm higher than that of the posterior clinoid process or when the body of the aneurysm was larger, recommendations included removing the zygomatic arch or abrading the lateral orbital wall. After opening the dura mater, the cerebrospinal fluid was fully released by opening the cistern and entering from the internal carotid-oculomotor nerve triangle or the internal carotid-optic nerve triangle. This was separated from the ipsilateral posterior cerebral artery P2 segment to the proximal part. The next step was to expose the ipsilateral posterior cerebral artery P1 segment, the upper basilar artery, the contralateral posterior cerebral artery P1 segment and the P2 segment. Finally, the neck and body of the aneurysm was separated and clipped (Figure 2).

## Evaluation Indicators and Following Up

(1) Clinical indicators were as follows: operative time, hospital stay, postoperative complications and Glasgow Outcome Scale (GOS) score at the 6-month follow-up. GOS scores were as follows: 1 for death; 2 for plant survival with only minimal response (e.g., eyes open with sleep/wake cycle); 3 for severe disability, awakening, disability, daily life requires care; 4 for mild disability, but the patients can live independently and



**Figure 2:** The left frontotemporal approach was used to remove the zygomatic arch, grind the anterior clinoid process, open part of the lateral wall of the cavernous sinus, and clip two aneurysms in one stage. **A)** The lateral and superior walls of the cavernous sinus were opened partly in parallel with the oculomotor nerve to reveal the main basilar artery; **B)** the clipped aneurysms of the basilar artery; **C)** intraoperative indocyanine green angiography showed that the basilar artery and bilateral posterior cerebral arteries were unobstructed and the aneurysms was completely clipped; **D)** the ophthalmic aneurysms of the contralateral internal carotid artery were clamped by the same approach. Postoperative imaging examination. **E)** The postoperative CT showed no intracranial hemorrhage and infarction in important functional areas; **F-H)** the postoperative CTA showed that the basilar aneurysm and the right ophthalmic aneurysm were completely clipped, and the clipped aneurysms did not recur, and parent artery blood flow was unobstructed.

work with protection; 5 for recovery, normal life, without any disability (2). The imaging indicator was a head CTA performed 6 months after the operation.

## RESULTS

The aneurysms of 27 patients were diagnosed as bifurcations of the basilar artery. All aneurysms were ruptured aneurysms. One patient had multiple aneurysms, and another patient had an aneurysm located in the ophthalmic segment of the left internal carotid artery. Among them, 8 patients underwent the subtemporal approach, and 19 patients underwent the frontal approach. All patients underwent surgery smoothly without blood transfusion. The operation time was 2.8-4.6 hours for an average of 3.3 hours, and the length of hospitalization was 3-6 weeks for an average of 3.8 weeks. Postoperative complications included thalamic brainstem ischemia caused by perforator artery ischemia in 1 case. Consciousness and limb movement disturbance occurred in 1 case with tracheotomy due to intrapulmonary infection on the 4th day after the operation. Ventricular drainage was performed because of acute communicating hydrocephalus in 2 cases, and the hydrocephalus was relieved after ventriculoperitoneal shunting. Pneumonia occurred in 2 cases after the operation and was improved with medication. There were no cases of intracranial infection or death. Overall, positive outcomes (GOS score of 4-5) at 6 months were achieved in 77.8% of the living patients. The follow-up period was 6 to 56 months

(mean 28.6 months). During the follow-up period, head CTA was performed in 25 patients at 6 months after the operation. The results showed that the blood flow of the parent artery was smooth, the aneurysms were completely clamped, the clipped aneurysms did not recur, and 2 cases were lost to follow-up (Figure 2). Thirteen patients had oculomotor nerve palsy, and all but 3 of them recovered during follow-up.

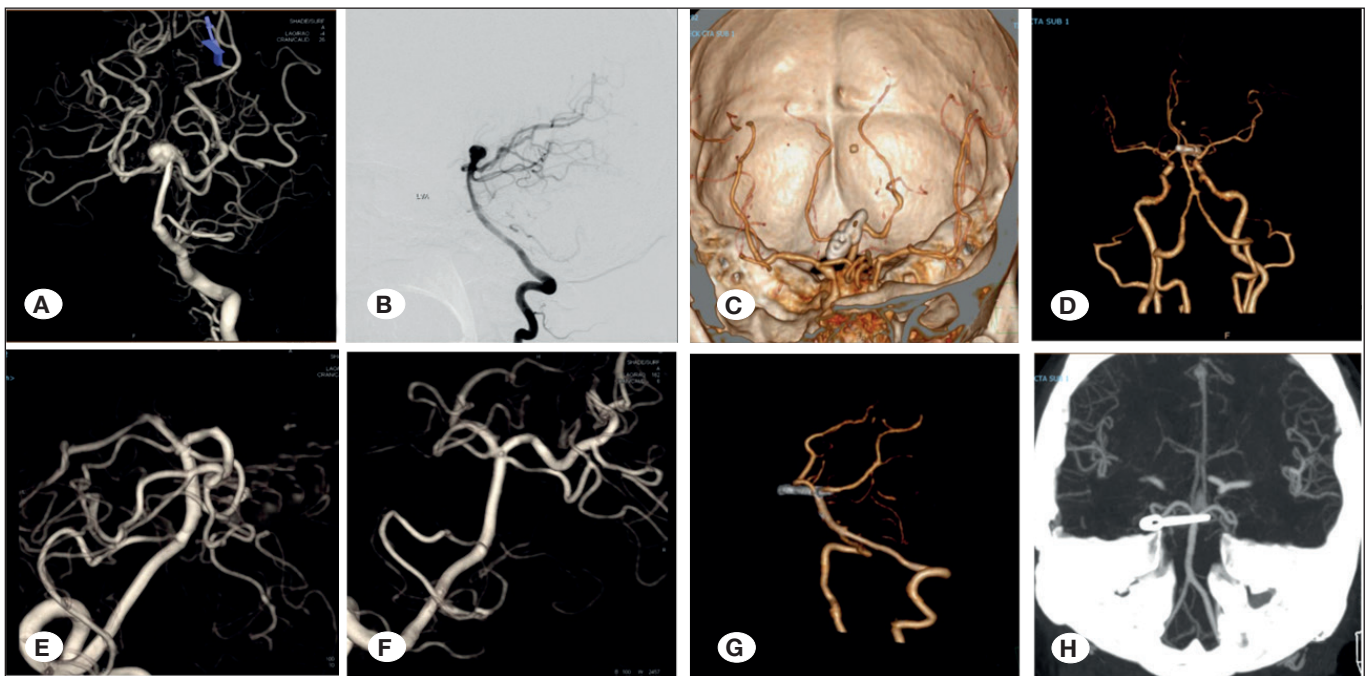
## ILLUSTRATIVE CASES

### Illustrative Case 1

The patient (case 15 in Table I) presented with sudden severe headache. Preoperative CTA and angiography showed diffuse subarachnoid hemorrhage and a 9-mm aneurysm at the basilar bifurcation (Figure 3A, B). We used frontotemporal approach in the operation. We used the frontotemporal approach during the operation. Because of the high location of the aneurysm, the zygomatic arch osteotomy was used. She had no neurologic deficits after operation, and postoperative CTA showed complete obliteration of the aneurysm (Figure 3C, D). A follow-up at 6 months showed that patient's GOS score was 4.

### Illustrative Case 2

The patient (case 25 in Table I) presented with sudden severe headache. Preoperative CTA and angiography showed a 4-mm aneurysm at the basilar bifurcation (Figure 3E, F). We used subtemporal approach in the operation. According



**Figure 3:** A-D) The patient (case 15 in Table I) was hospitalized due to sudden headache. A, B) The preoperative DSA showed basilar bifurcation aneurysm and the diameter of the aneurysm was 9mm. The right frontotemporal approach was used. C, D) The postoperative CTA showed that the basilar aneurysm was completely clipped and parent artery blood flow was unobstructed. E-H) The patient (case 25 in Table I) was hospitalized due to sudden headache and vomiting. E, F) The preoperative DSA showed basilar bifurcation aneurysm and the diameter of the aneurysm was 4mm. The right subtemporal approach was used. G, H) The postoperative CTA showed that the basilar aneurysm was completely clipped and parent artery blood flow was unobstructed.

to the preoperative evaluation, we used the subtemporal approach during the operation. She had no neurologic deficits after operation, and postoperative CTA showed complete obliteration of the aneurysm (Figure 3G, H). A follow-up at 6 months showed that patient's GOS score was 4.

## ■ DISCUSSION

Basilar artery bifurcation aneurysms, also known as basilar tip aneurysms, are a common type of posterior circulation aneurysm, accounting for 5%-15% of all intracranial aneurysms and more than 50% of posterior circulation aneurysms (18, 21). Compared with anterior circulation aneurysms, ruptured basilar artery bifurcation aneurysms have higher mortality and disability rates. Once the diagnosis is clear, surgical treatment should follow (10).

At present, the most common methods are interventional embolization and traditional craniotomy to treat the posterior circulation aneurysms (11,13,21). This method is usually the first choice for basilar aneurysms with interventional embolization (9). Craniotomy is also a safe and effective choice for patients with difficult interventional embolization (14,16). The reasons for surgical clipping treatment of all patients included in this study are as follows: First, compared with interventional therapy, surgical clipping should warrant better rates of aneurysmal exclusion and retreatment (15). Second, for aneurysms with complex neck morphologies, aneurysms close to important perforating arteries or tortuous vascular paths, we prefer surgical clipping for safety reasons. Finally, the cost of surgery in the developing world is also a consideration. Surgical clipping is less expensive than interventional treatment. There were 26 patients with Hunt-Hess grades I and II, and only one patient had Hunt-Hess grade III. We did not choose open surgery in the acute stage of hemorrhage. After 10-14 days of hemorrhage, when subarachnoid hemorrhage was almost completely absorbed and the patient was stable, and following evaluation, we chose clipping therapy.

Preoperative imaging examinations are crucial in choosing an appropriate surgical approach. The relationship between the aneurysmal neck and posterior clinoid process, size, projection, and perforator vessels are considered comprehensively. The purpose is to show the aneurysm well and reduce traction and injury to nerves, blood vessels and brain tissue (18). The most important step is to understand the relationship between the position of the top of the basilar artery and the horizontal line of the anterior skull base or the posterior clinoid process (21). In this study, 8 patients were treated using the subtemporal approach, and 19 cases were treated with the frontotemporal approach.

The microsurgical treatment of basilar aneurysms is limited in time and space. One of the most critical steps for successful surgery is to create a larger operating space and visual angle by removing bone, releasing cerebrospinal fluid, ventilating the site and administering medication (mannitol) (21). 1) The bone is removed at the mid-level skull base via the subtemporal approach, which makes it easier to enter from the skull base.

If the mastoid air chamber was opened, the bone wax was sealed in time or blocked with fat. The cerebrospinal fluid is released with the drainage system by lumbar puncturing before craniotomy. The brain tissue is retracted to a certain extent, thus forming a more relaxed operative space between the brain tissue and the skull base. This will make it easier to gently pull the temporal lobe and protect Labbe's vein from tearing it up after lifting the temporal lobe. To avoid injury to the trochlear nerve, the tentorial margin of the cerebellum can be raised by a meningeal hook, and then the tentorial margin can be cut (4). 2) If the intracranial pressure is high via the frontotemporal approach, the ventricle can be punctured by modified Paine's point (7). After the cerebrospinal fluid is sucked from the lateral ventricle, the traction to the brain tissue will be reduced. After opening the Sylvian fissure, the cistern of the carotid artery and optic chiasm, the cerebrospinal fluid is fully released to enter from the internal carotid artery-oculomotor nerve triangle or optic nerve-internal carotid artery triangle. The relationship between the aneurysmal neck and posterior clinoid process, especially upper aneurysms or larger aneurysms 1.5 cm above the posterior clinoid process, requires removal of the zygomatic arch or "eggshell" technology to grind the lateral orbital wall to increase the observation angle. To fully expose the aneurysm, the anterior clinoid process can be removed to increase the operative field when the parent artery is difficult to expose, even it requires opening the lateral wall of the cavernous sinus or sacrificing the nondominant anterior temporal artery if necessary (3).

The subtemporal approach was initiated and described in detail by Gonzalez et al. and Spetzler et al. for the treatment of basilar bifurcation aneurysms (2,17). The advantages of this approach are that the operative path is short, the operation is relatively simple, the deep skull base structure does not need to be abraded, and the tentorial margin of the cerebellum can be cut off to obtain a larger space. The aneurysm and the perforating branch artery posteriorly are observed, and the proximal basilar artery can be dissected and controlled, then the neck can be exposed. The disadvantage is that the P1 segment of the contralateral posterior cerebral artery and its perforator artery are "blind spots", and there is a risk of misclipping. The temporal lobe is retracted excessively, and temporal lobe contusion and Labbe's vein injury may occur. Hernesniemi et al. considered that the subtemporal approach is suitable for the surgical treatment of most basilar bifurcation aneurysms (3). The subtemporal approach was used in 8 cases in this group, and the results were good.

Microsurgery via the frontotemporal approach mainly addresses upper aneurysms, as the location of the neck is higher than the horizontal line of the anterior skull base or the posterior clinoid process, and larger aneurysms, aneurysms with wide necks and aneurysms in young patients. The advantages of this approach are that the temporal lobe is less retracted, and the natural space of the lateral fissure can be used in dissection to avoid damaging Labbe's vein. It can be simultaneously observed to the interphalangeal cistern, P1 segment of bilateral posterior cerebral artery and partial perforating artery (5,20). This approach can be used to treat ipsilateral anterior circulation aneurysms at the same time as

multiple ruptured aneurysms with no presumed responsibility (23). Krisht et al. reported that this method has been used to treat complex basilar bifurcation aneurysms and has achieved good results (7). In 19 patients with aneurysms clipped via the frontotemporal approach, we chose aneurysms whose bifurcation of the basilar artery was higher than the horizontal line of the anterior skull base. Compared with the subtemporal approach, microsurgery via the frontotemporal approach has some drawbacks in traction of the internal carotid artery and oculomotor nerve and is liable to damage the posterior perforating artery in the blind spot. There is a higher risk of oculomotor nerve palsy via this approach; 13 of 19 patients had oculomotor nerve palsy, and all but 1 of them recovered during follow-up. Posterior thalamic perforator artery infarction occurred in 2 cases. One patient had consciousness disturbance and limb movement disturbance after the operation, and a tracheotomy was performed 4 days after the operation because of pulmonary infection.

The published studies of open surgery for ruptured basilar aneurysms are summarized below. Lawton reported 56 patients with aneurysms, of which ruptured aneurysms accounted for 55% (8). Overall, good outcomes were achieved in 84% of patients, with 9% surgical mortality. Sekhar et al. reported patients with 63 ruptured basilar aneurysms (15). Good outcomes were achieved in 71% of patients. Lusseveld et al. reported 44 patients with ruptured basilar aneurysms (9). Good outcome was demonstrated in 71% of patients. Sriamornrattanakul et al. reported patients with 23 ruptured basilar aneurysms, and good outcomes were demonstrated in 80% of patients (19). This shows that surgical treatment of basilar bifurcation aneurysms is safe and effective. Compared with the single surgery method in other studies, the good outcomes of our personalized surgery method were demonstrated in 81.5% of patients.

The development of surgical equipment makes surgical treatment of aneurysms safer, such as intraoperative ultrasound, indocyanine green angiography (ICGA) and neuroendoscopy, which are complementary to conventional instruments (1,12). Neuroendoscopy has the characteristics of close illumination and local enlargement. Various directions were observed according to the fine structures of the parent artery, the neck of the aneurysm and the perforating artery around the aneurysm. The application of neuroendoscopy can solve the problem with the infratemporal approach that cannot identify contralateral structures and avoid or reduce the risk of incomplete clipping, unsatisfactory placement of clips or misclipping (1,12). In addition, electrophysiological monitoring equipment makes the operation safer and more accurate, effectively reducing postoperative complications.

There are several limitations to the present study. First, this study was limited by its retrospective design and the relatively small number of patients. Second, compared with randomized controlled studies, this study may have selection bias because surgeons tend to use highly skilled techniques to treat diseases. Therefore, it is necessary to conduct a large sample and multi center randomized controlled study to further prove the conclusion of this study.

## CONCLUSION

Satisfactory results were achieved by microsurgical clipping for basilar bifurcation aneurysms. According to the location and projection of aneurysms, personalized treatment was chosen. The transfrontotemporal approach is the most suitable approach for the treatment of upper basilar bifurcation aneurysms, especially under subarachnoid hemorrhage causing brain swelling.

## AUTHORSHIP CONTRIBUTION

Study conception and design: HW, XT

Data collection: HW, YS

Analysis and interpretation of results: YS, YF, HZ

Draft manuscript preparation: HW, YS

Critical revision of the article: XT

Other (study supervision, fundings, materials, etc...): HW, YS, XT

All authors (HW, YS, YF, HZ, XT) reviewed the results and approved the final version of the manuscript.

## REFERENCES

1. Eliava SS, Shekhtman OD, Pilipenko YV, Okishev DN, Kheireddin AS, Kisar'ev SA, Kaftanov AN: Intraoperative indocyanine green fluorescence angiography in surgery of brain aneurysms. The first experience with using the technique and literature review. *Zh Vopr Neurokhir Im N N Burdenko* 79: 33-34, 2015
2. Gonzalez LF, Amin-Hanjani S, Bambakidis NC, Spetzler RF: Skull base approaches to the basilar artery. *Neurosurg Focus* 19: E3, 2005
3. Hernesniemi J, Ishii K, Niemelä M, Kivipelto L, Fujiki M, Shen H: Subtemporal approach to basilar bifurcation aneurysms: Advanced technique and clinical experience. *Acta Neurochir Suppl* 94:31-38, 2005
4. Jaechan Park, In-Suk Hamm: Revision of Paine's technique for intraoperative ventricular puncture. *Surg Neurol* 70:503-508, 2008
5. Krisht AF: Transcavernous approach to diseases of the anterior upper third of the posterior fossa. *Neurosurg Focus* 56:261-273, 2005
6. Krisht AF, Kadri PA: Surgical clipping of complex basilar apex aneurysms: A strategy for successful outcome using the pretemporal transzygomatic transcavernous approach. *Neurosurgery* 56:261-273, 2005
7. Krisht AF, Krayenbuhl N, Sercl D, Bikmaz K, Kadri PA: Results of microsurgical clipping of 50 high complexity basilar apex aneurysms. *Neurosurg* 60:242-252, 2007
8. Lawton MT: Basilar apex aneurysms: Surgical results and perspectives from an initial experience. *Neurosurgery* 50:1-8, 2002
9. Lusseveld E, Brilstra EH, Nijssen PC, van Rooij WJ, Sluzewski M, Tulleken CA, Wijnalda D, Schellens RL, van der Graaf Y, Rinkel GJ: Endovascular coiling versus neurosurgical clipping in patients with a ruptured basilar tip aneurysm. *J Neuro Neurosurg Psychiatry* 73:591-593, 2002

10. Molyneux AJ, Kerr RS, Yu LM, Clarke M, Sneade M, Yarnold JA, Sandercock P: International subarachnoid aneurysm trial (ISAT) of neurosurgical clipping versus endovascular coiling in 2143 patients with ruptured intracranial aneurysms—a randomized comparison of effects on survival, dependency, seizures, rebleeding, subgroups, and aneurysm occlusion. *Lancet* 366:809-917, 2005
11. Nagashima H, Kobayashi S, Tanaka Y, Hongo K: Endovascular therapy versus surgical clipping for basilar artery bifurcation aneurysm: Retrospective analysis of 117 cases. *J Clin Neurosci* 11:475-479, 2004
12. Peris-Celda M, Da Roz L, Monroy-Sosa A, Morishita T, Rhoton AL Jr: Surgical anatomy of endoscope-assisted approaches to common aneurysm sites. *Neurosurg* 10:121-144, 2014
13. Sanai N, Tarapore P, Lee AC, Lawton MT: The current role of microsurgery for posterior circulation aneurysms: A selective approach in the endovascular era. *Neurosurg* 62:1236-1253, 2008
14. Sharma RK, Kumar A, Yamada Y, Tanaka R, Sharma S, Miyatani K, Higashiguchi S, Kawase T, Talluri S, Kato Y: Institutional experience of microsurgical management in posterior circulation aneurysm. *Asian J Neurosurg* 15(3):484-493, 2020
15. Sekhar LN, Tariq F, Morton RP, Ghodke B, Hallam DK, Barber J, Kim LJ: Basilar tip aneurysms: A microsurgical and endovascular contemporary series of 100 patients. *Neurosurgery* 72:284-298, 2013
16. Spetzler RF, McDougall CG, Zabramski JM, Albuquerque FC, Hills NK, Nakaji P, Karis JP, Wallace RC: Ten-year analysis of saccular aneurysms in the Barrow Ruptured Aneurysm Trial. *J Neurosurg* 8:1-6, 2019
17. Spetzler RF, McDougall CG, Zabramski JM, Albuquerque FC, Hills NK, Russin JJ, Partovi S, Nakaji P, Wallace RC: The barrow ruptured aneurysm trial: 6-year results. *J Neurosurg* 123:609-617, 2015
18. Spiessberger A, Strange F, Fandino J, Marbacher S: Microsurgical clipping of basilar apex aneurysms: A systematic historical review of approaches and their results. *World Neurosurg* 114:305-316, 2018
19. Sriamornrattanakul K, Wongsuriyanan S, Akharathamachote N: Anterior temporal approach for clipping of upper basilar artery aneurysms: Surgical techniques and treatment outcomes. *World Neurosurg* 131:e530-e542, 2019
20. Tayebi Meybodi A, Benet A, Rodriguez Rubio R, Yousef S, Mokhtari P, Preul MC, Lawton MT: Comparative analysis of orbitozygomatic and subtemporal approaches to the basilar apex: a cadaveric study. *World Neurosurg* 119:607-616, 2018
21. Tjahjadi M, Kivelev J, Serrone JC, Maekawa H, Kerro O, Jahromi BR, Lehto H, Niemelä M, Hernesniemi JA: Factors determining surgical approaches to basilar bifurcation aneurysms and its surgical outcomes. *Neurosurg* 78:181-191, 2016
22. Tjahjadi M, Serrone J, Hernesniemi J: Should we still consider clips for basilar apex aneurysms? A critical appraisal of the literature. *Surg Neurol Int* 9:44, 2018
23. Yonekawa Y, Khan N, Imhof HG, Roth P: Basilar bifurcation aneurysms. Lessons learnt from 40 consecutive cases. *Acta Neurochir Suppl* 94:39-44, 2005