



# Total En Bloc Spondylectomy of C7 Vertebrae for Primary Bone Tumors: The Efficacy of Autologous Sternal Structural Grafts

Younggyu OH<sup>1</sup>, Subum LEE<sup>1</sup>, Yong-Hee KIM<sup>2</sup>, Geun Dong LEE<sup>2</sup>, Jin Hoon PARK<sup>3</sup>

<sup>1</sup>Korea University Anam Hospital, Korea University College of Medicine, Department of Neurological Surgery, Seoul, Republic of Korea

<sup>2</sup>University of Ulsan College of Medicine, Asan Medical Center, Department of Thoracic and Cardiovascular Surgery, Seoul, Republic of Korea

<sup>3</sup>University of Ulsan College of Medicine, Asan Medical Center, Department of Neurological Surgery, Seoul, Republic of Korea

Corresponding author: Jin Hoon PARK ✉ [jhpark@amc.seoul.kr](mailto:jhpark@amc.seoul.kr)

## ABSTRACT

**AIM:** To evaluate the efficacy and safety of total en bloc spondylectomy with autologous sternal structural graft, subaxial pedicle screws, and 5.5 mm titanium rods in primary bone tumor surgery.

**MATERIAL and METHODS:** From January 2019 to February 2020, two patients with lower cervical spine (C7) primary bone tumor underwent total en bloc spondylectomy, interbody fusion with sternal structural autograft, and posterior instrumentation using subaxial pedicle screws. The medical records and radiographic findings of the patients were reviewed.

**RESULTS:** C7 total en bloc spondylectomy was successfully performed; the anterior column was reconstructed with an autologous sternal structural graft with posterior instrumentation using subaxial pedicle screws and 5.5 mm titanium rods. After surgery, the VAS scores of neck and radiating arm pain in both patients were relieved considerably. Bony fusion was achieved in all patient by 6 months after surgery. There were no postoperative complications associated with the donor site.

**CONCLUSION:** Structural bone obtained from the sternum is safe and provides a viable alternative to cervical fusion for patients with primary bone tumor. It confers the advantages of autograft fusion without the complications associated with donor site morbidities.

**KEYWORDS:** Cervical vertebra, Bone neoplasm, Sternum


## INTRODUCTION


The autologous iliac bone is commonly used for anterior cervical fusion (ACF) (2,13). However, the incidence of complications after iliac crest harvest, including pain, lateral femoral cutaneous nerve injury, and peritoneal perforation, ranges from 10–40% (15,16). Although artificial bone can substitute for bone grafts, these materials are less reliable for successful fusion (2,8,13). Several alternative autologous bone materials, such as the sternum, fibula, patella, and rib, have therefore been utilized, as these materials can achieve the advantages of autologous bone grafts while avoiding the morbidities associated with iliac crest harvest (2,13,14). For example, bone chips harvested from the sternum have been utilized as interbody cages for anterior cervical discectomy and fusion (ACDF) (18).


This technical report describes two patients with primary bone tumors on the C7 vertebra who underwent total en bloc spondylectomy (TES) followed by reconstruction with subaxial cervical pedicle screw (CPS) placement and an autologous sternal structural bone graft.


### Surgical Procedure


These operations were performed posteriorly and then anteriorly. Initially, the patient was placed in the prone position, and the posterior elements were exposed subperiosteally. The pedicle screws were inserted using the free-hand technique. After both transverse processes were removed, the pedicles were osteotomized and the yellow ligament was removed between C6–C7 and C7–T1. The posterior elements of C7

Younggyu OH  : 0000-0002-7805-9884

Subum LEE  : 0000-0003-4732-8137

Yong-Hee KIM  : 0000-0003-2177-4876

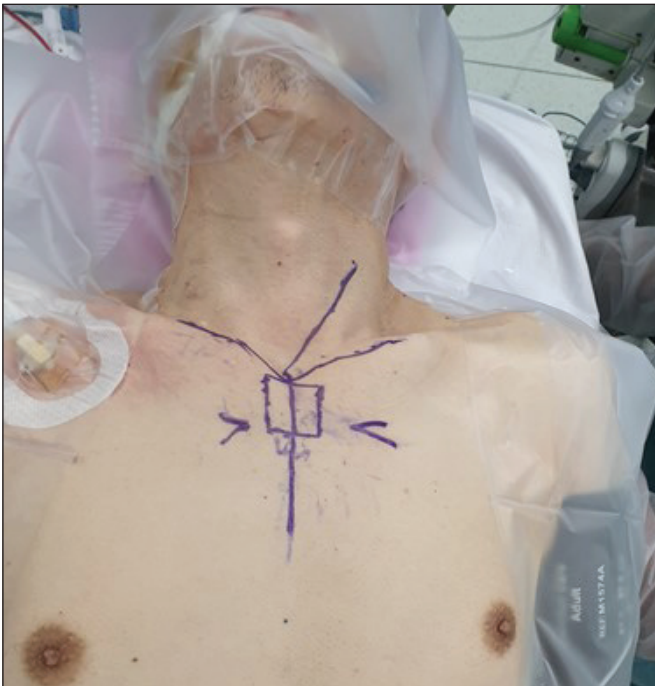Geun Dong LEE  : 0000-0003-1890-7455

Jin Hoon PARK  : 0000-0002-0903-3146

were subsequently removed in one piece, and 5.5 mm titanium rods were connected to the screws.

In the second stage, the patient was placed in the supine position. The incision line was extended beyond the suprasternal notch using an oblique incision in front of the neck (Figure 1A, B). The anterior aspect of the C7 vertebra was exposed, followed by discectomies at C6–C7 and C7–T1. The C7 vertebral body containing the tumor was subsequently removed en bloc.

In the next step, bone material was harvested from the manubrium for bone grafting. The surface of the manubrium was exposed, and a bone block was removed from the manubrium using an osteotome. This bone block was inserted



**Figure 1:** Skin incision line used in the anterior approach.

into the anterior defect of C7. The manubrium defect was not specifically reconstructed.

#### Description of Patient 1

Patient 1 was a 31-year-old man with progressively worsening neck pain beginning 3 years earlier. His neck pain (visual analog scale [VAS] 5) radiated to the right arm and hand (VAS 5), but he had no neurological deficits. He had never been diagnosed with malignancy and he had undergone only conservative treatment. Imaging work-up at our institution showed a lesion in the C7 vertebral body (Figure 2). A needle biopsy of the lesion showed a giant cell tumor (GCT) at the C7 vertebra.

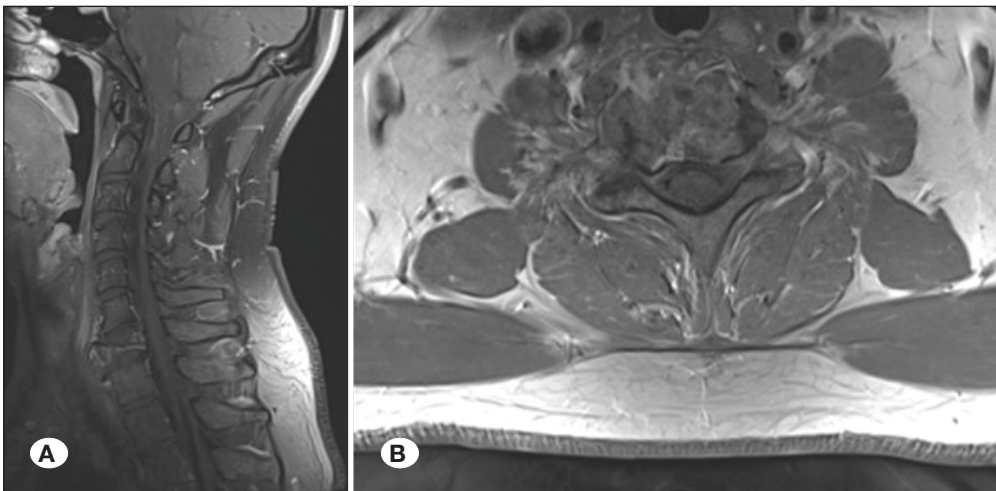
Chest and abdominal computed tomography (CT) and positron emission tomography (PET) were negative for visceral malignancy, but metastasis to lymph nodes in the mediastinum was suspected.

The operation was performed successfully, resulting in tumor-free margins of the resected body. The anterior defect was reconstructed with an autologous sternal structural graft with posterior instrumentation from C6–T2. Simultaneously, the thoracic surgery team performed an open thoracotomy, followed by excisional biopsy of mediastinal lymph nodes. The sternum was reconstructed using titanium plates and screws included in the SternaLock system (Biomet Microfixation Inc., Jacksonville, FL, USA) (Figure 3). Postoperatively, the patient had no neurologic symptoms and little pain.

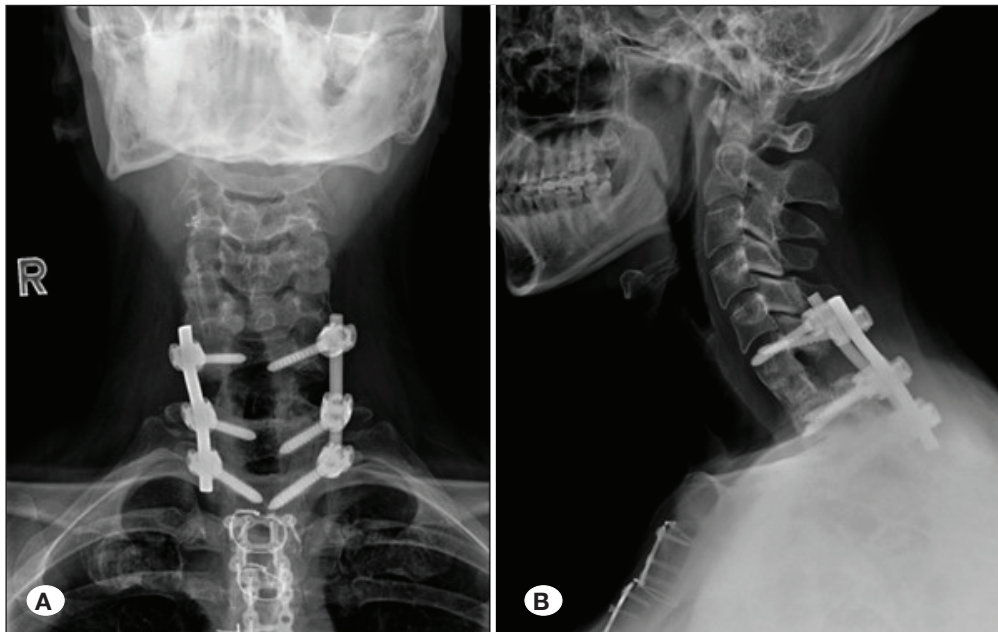
Follow-up 4 years later showed no evidence of disease recurrence. The patient remains pain free. Postoperative images were also good, with no apparent problems (Figure 4).

#### Description of Patient 2

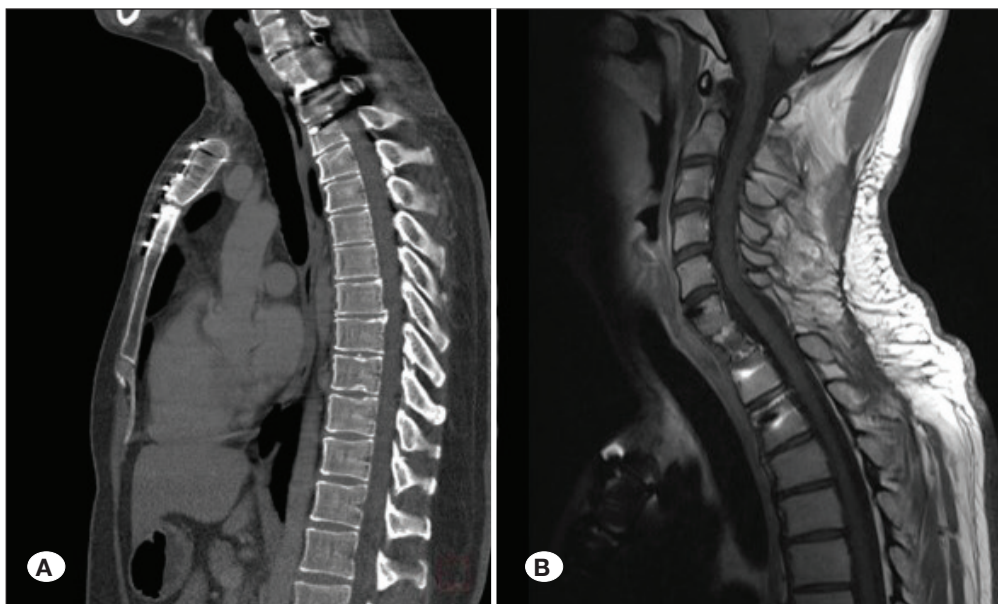
Patient 2 was a 79-year-old man with moderate pain in the posterior neck, both scapula, and arm pain beginning 3 months earlier (VAS 5). He had no neurological abnormalities. He received physical therapy at a private clinic for 2 months, but his symptoms persisted. Subsequent magnetic resonance imaging (MRI) revealed a tumor in the C7 vertebra (Figure 5), and he was referred to our institution for evaluation. CT



**Figure 2:** Preoperative T1 enhanced sagittal (A) and axial (B) MRIs views in patient 1.



**Figure 3:** Postoperative 6 month X-rays AP (A), lateral (B) view in Patient 1.



**Figure 4:** A) Postoperative 6 month CT scan, midsagittal view in Patient 1. B) T1-weighted contrast-enhanced MRI, midsagittal view in Patient 1.

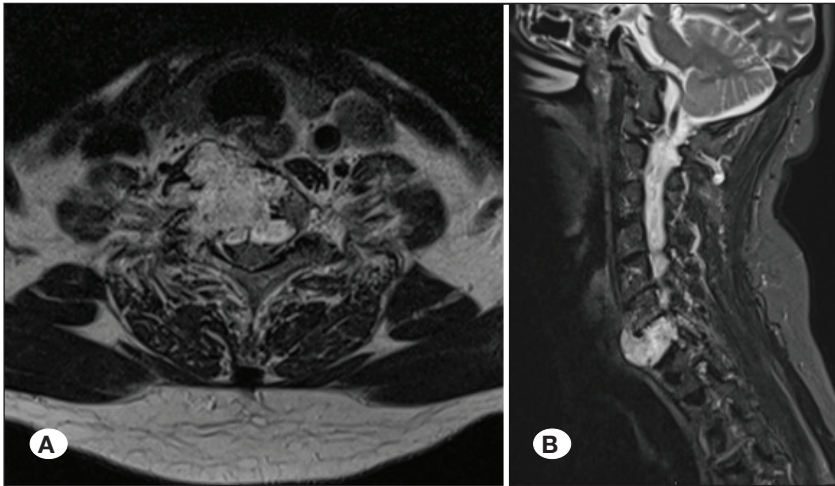
scans of the chest and abdomen and PET excluded visceral metastases. A CT-guided needle biopsy of the C7 vertebral body revealed a chordoma. Surgery was successful, resulting in tumor-free margins of the resected body. The anterior defect was reconstructed with an autologous sternal structural graft with posterior instrumentation from C6–T2. The patient’s postoperative course was uneventful, as he experienced no neurological compromise and considerably diminished neck, scapular, and arm pain.

Postoperatively, however, this patient complained of hoarseness and a swallowing disorder that was thought to be recurrent laryngeal nerve palsy. One month later, hyaluronic acid was injected into his right vocal by an otolaryngologist, resulting in resolution of these symptoms.

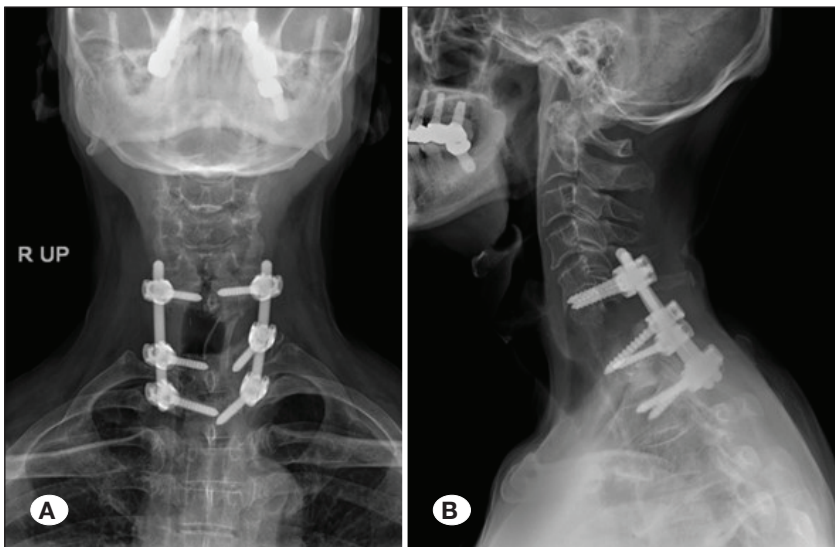
Examination 4 years later showed that the patient remained disease free, with no neurologic symptoms and little pain. Postoperative images were also good, with no apparent problems (Figures 6,7,8).

## ■ DISCUSSION

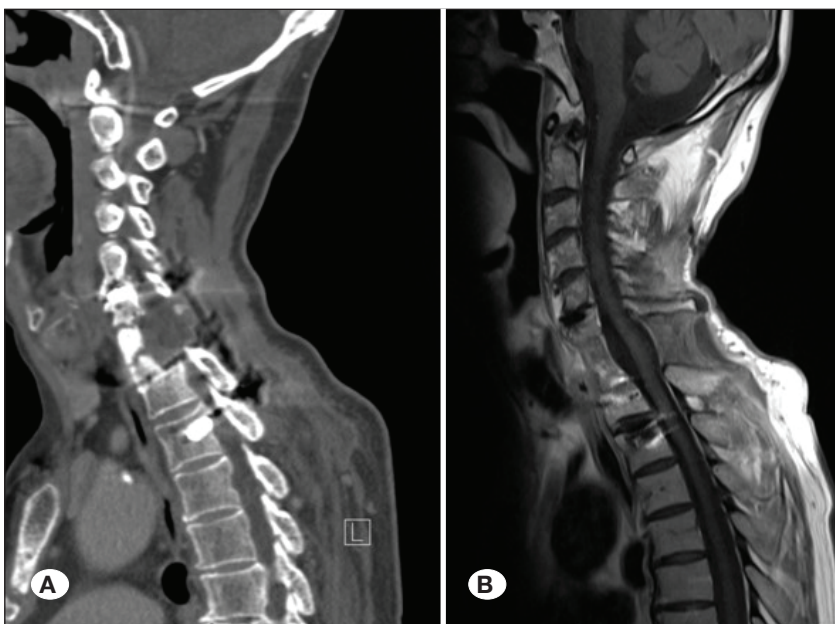
Cancellous autografts have been widely used as fusion material to fill defects after ACF, as they have higher fusion rates and lower infection rates, as well as being more cost effective, than allografts (3,9). Although iliac bone is regarded as the most popular bone graft source, iliac bone harvesting has been associated with several complications, such as pain and functional impairments (15,16).



**Figure 5:** Preoperative T1-weighted contrast-enhanced axial (A) and sagittal (B) MRIs views in Patient 2.



**Figure 6:** Postoperative 6 month X-rays AP (A), lateral (B) view in Patient 2.



**Figure 7:** A) Postoperative 6 month CT scan, midsagittal view in Patient 2. B) T1-weighted contrast-enhanced MRI, midsagittal view in Patient 2.

Autografts have been obtained from different sites, including as bone chips from the sternum (5,12,14,18). To our knowledge, however, no studies have reported the use of structural blocks harvested from the sternum as allografts. This procedure has two major advantages. First, the sternum is one of the closest anatomical structures to the surgical site that can be easily harvested. Second, postoperative MRI can evaluate artifacts without interference from metal artifacts, such as after using artificial cages made of metal or polyetheretherketone. High quality MRI without interference from metal artifacts is especially important in patients with GCTs and chordomas because their risk of recurrence is high (1,7). Neither of the two patients in the present study showed any evidence of tumor recurrence 4 years postoperatively.

In general, reconstruction is not required when part of the sternal manubrium is removed as a bony graft without damage to the bilateral sternoclavicular joint (17). Thus, patient 2 did not require sternal reconstruction (Figure 9). Patient 1, however, underwent upper partial sternotomy for

dissection of the right upper and lower paratracheal lymph nodes during surgery, with the sternum partially resected for harvesting the bony graft. This patient therefore underwent chest wall reconstruction to cover bony defects during sternal approximation (Figure 10). Because the gap between the sternoclavicular joints was small, it was not easy to obtain a bony graft of sufficient width. Therefore, harvesting procedures in the upper part of the manubrium require special care to avoid injury to the sternoclavicular joints, preventing the disruption of chest wall integrity (17).

In addition, this procedure carries a risk of mediastinal vessel injury (14). To avoid perforating the sternum, its anatomy should be determined preoperatively. Taking precautions to avoid injuring vessels underlying sternal bone will result in more tolerable postoperative pain during harvesting because of the absence of subcutaneous fat and muscle under the same skin incision (12).

Subaxial CPS has the strongest biomechanical stability, resulting in shorter segment fixation, better preservation of mobile segments, and higher fusion rates compared with other methods (6,10,11). The advanced CPS placement technique used in these patients consisted of a combination of 5.5 mm diameter rods without an anterior plate (4). This method avoided metal artifacts, preserved the maximal cervical motion segment stopping at the C6 vertebra, and achieved successful bone fusion.

One important limitation of this study was that it included only two patients, thereby preventing assessments of the effects of this technique in patients with anatomic variations, such as a lack of cortical bone or osteoporotic sternum. Studies in a larger numbers of patients are required.

**CONCLUSION**

Autologous sternal structural bone graft is a useful source for replacing primary bone tumors on the C7 vertebra.

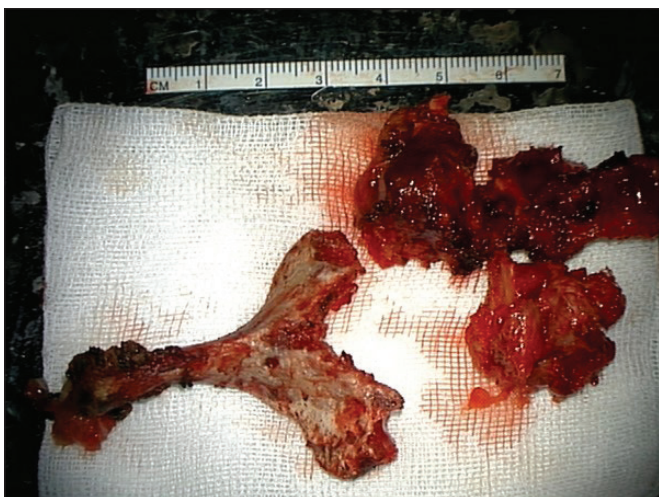

Figure 8: Resected C7 vertebra with tumor from Patient 2.

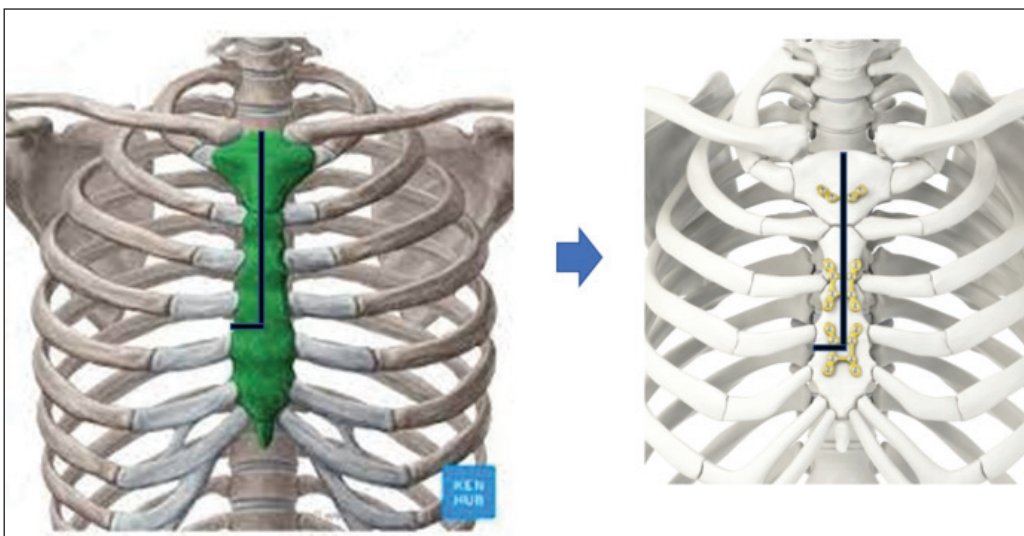
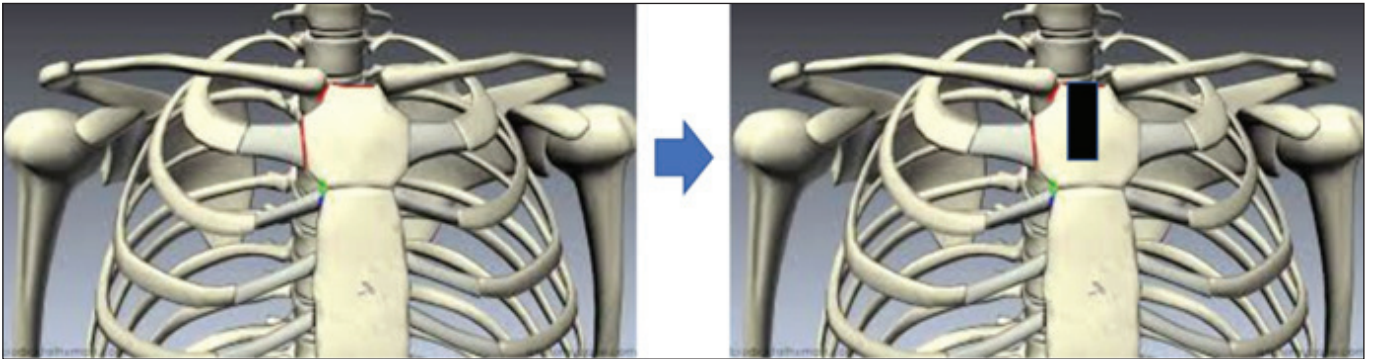


Figure 9: Sites of manubrial harvesting (black colored squares) in Patient 2.



**Figure 10:** Sternal reconstruction after upper partial sternotomy for mediastinal lymph node dissection in Patient 1.

#### AUTHORSHIP CONTRIBUTION

Study conception and design: JHP

Data collection: YO

Analysis and interpretation of results: GDL

Draft manuscript preparation: SL

Critical revision of the article: JHP

Other (study supervision, fundings, materials, etc...): YHK

All authors (YO, SL, YHK, GDL, JHP) reviewed the results and approved the final version of the manuscript.

#### REFERENCES

- Balke M, Schremper L, Gebert C, Ahrens H, Streitbuerger A, Koehler G, Harges J, Gosheger G: Giant cell tumor of bone: Treatment and outcome of 214 cases. *J Cancer Res Clin Oncol* 134: 969-978, 2008
- Chau AM, Mobbs RJ: Bone graft substitutes in anterior cervical discectomy and fusion. *Eur Spine J* 18: 449-464, 2009
- Goldberg VM: Natural history of autografts and allografts. In: Older MWJ (ed), *Bone Implant Grafting*. London: Springer, 1992:9-12
- Heo Y, Lee SB, Lee BJ, Jeong SK, Rhim SC, Roh SW, Park JH: The Learning curve of subaxial cervical pedicle screw placement: How can we avoid neurovascular complications in the initial period? *Oper Neurosurg (Hagerstown)* 17:603-607, 2019
- Iwasaki K, Ikedo T, Hashikata H, Toda H: Autologous clavicle bone graft for anterior cervical discectomy and fusion with titanium interbody cage. *J Neurosurg Spine* 21:761-768, 2014
- Jung YG, Jung SK, Lee BJ, Lee S, Jeong SK, Kim M, Park JH: The subaxial cervical pedicle screw for cervical spine diseases: The review of technical developments and complication avoidance. *Neurol Med Chir* 60:231-243, 2020
- Klenke FM, Wenger DE, Inwards CY, Rose PS, Sim FH: Giant cell tumor of bone: Risk factors for recurrence. *Clin Orthop Relat Res* 469:591-599, 2011
- Lebow R, Yao T, Stevenson CB, Cheng JS: Bone graft options, bone graft substitutes, and bone harvest techniques. In: Winn HR (ed), *Youmans Neurological Surgery*, 6<sup>th</sup> ed. Philadelphia, PA: Elsevier, 2011: 2992-2998
- Malloy KM, Hilibrand AS: Autograft versus allograft in degenerative cervical disease. *Clin Orthop Relat Res* 394:27-38, 2002
- Park JH, Jeon SR, Roh SW, Kim JH, Rhim SC: The safety and accuracy of freehand pedicle screw placement in the subaxial cervical spine: A series of 45 consecutive patients. *Spine* 39: 280-285, 2014
- Park JH, Roh SW, Rhim SC: A single-stage posterior approach with open reduction and pedicle screw fixation in subaxial cervical facet dislocations. *J Neurosurg Spine* 23:35-41, 2015
- Peelle MW, Rawlins BA, Frelinghuysen P: A novel source of cancellous autograft for ACDF surgery: The manubrium. *Clin Spine Surg* 20:36-41, 2007
- Ryken TC, Heary RF, Matz PG, Anderson PA, Groff MW, Holly LT, Kaiser MG, Mummaneni PV, Choudhri TF, Vresilovic EJ: Techniques for cervical interbody grafting. *J Neurosurg Spine* 11:203-220, 2009
- Sangala JR, Nichols T, Uribe JS, Melton M, Vale FL: Sternal cancellous bone graft harvest for anterior cervical discectomy and fusion with interbody cage devices. *Clinical neurology and neurosurgery* 112: 470-473, 2010
- Seiler 3rd J, Johnson J: Iliac crest autogenous bone grafting: donor site complications. *Journal of the Southern Orthopaedic Association* 9: 91, 2000
- Shamsaldin M, Mouchaty H, Desogus N, Costagliola C, Di Lorenzo N: Evaluation of donor site pain after anterior iliac crest harvesting for cervical fusion: A prospective study on 50 patients. *Acta Neurochirurgica* 148:1071-1074, 2006
- Xiu P, Shui D, Wang Q, Wang G, Lan Y: Anatomic and morphometric analysis of manubrium sterni as a source of autograft for anterior cervical fusion surgery using quantitative 3-dimensional computed tomographic scans. *Spine* 37: E935-E941, 2012
- Xu S, Wang Q, Xiong YI, Wang G, Yang J, Zhang S: Structural manubrium autograft in cervical fusion for patients with cervical tuberculosis: A preliminary study. *Research Square*, 2020