



Factors Affecting Resorption Following Cranioplasty with an Autologous Bone Graft

Burak YURUK¹, Ayhan TEKINER², Yavuz ERDEM², Haydar CELIK², Mehmet Emre YILDIRIM², Adem KURTULUS³, Omer SAHIN², Koray OZTURK², Tuncer TASCIOGLU², Kemal KANTARCI⁴, Berkay AYHAN², Zeliha CULCU GURCAN², Huseyin Omer SEMIZ², Mehmet Akif BAYAR²

¹Nigde Research and Training Hospital, Department of Neurosurgery, Nigde, Türkiye

²Ankara Research and Training Hospital, Department of Neurosurgery, Ankara, Türkiye

³Duzce University, School of Medicine, Department of Neurosurgery, Duzce, Türkiye

⁴Hatay Research and Training Hospital, Department of Neurosurgery, Hatay, Türkiye

Corresponding author: Burak YURUK ✉ burakyuruk26@gmail.com

ABSTRACT

AIM: To evaluate the relationship between the surgical techniques, the waiting time for surgery, postoperative distance between the graft-bone margin and the percentage of bone resorption, we analyzed patients who underwent cranioplasty. Cranioplasty is a necessary surgery to preserve brain tissue and provide an appropriate microenvironment.

MATERIAL and METHODS: In this study, patients who underwent autologous bone grafting after decompressive craniectomy by the Neurosurgery Clinic of University of Health Sciences Ankara Training and Research Hospital between 2018 and 2021 were examined.

RESULTS: Thirty-nine patients who underwent autologous cranioplasty following decompressive craniectomy were included in the study. The average expected time for cranioplasty surgery following decompressive craniectomy was 16.97±13.478 weeks (min:2 max:62 weeks). The expected time between decompressive craniectomy and cranioplasty surgeries and resorption rates were compared. The resorption rate was above 30% in 7 of 10 patients with 24 weeks or more between craniectomy and cranioplasty, and less than 30% in 17 of 25 patients in surgeries less than 24 weeks (p=0.04). Following cranioplasty surgery, the distance between the graft-bone margin and the resorption rates were also compared. In this analysis, statistically significant differences were detected between the distance between the graft-bone border and the resorption rates. Resorption rates increased in 15 of 19 patients with a postcranioplasty distance of 1 mm or more (p<0.00001).

CONCLUSION: Early cranioplasty surgery is important in order to reduce complications that may occur after craniectomy. In addition, it is important to keep the defect area small in size during craniectomy surgery and to keep the cutting edge thinner when the bone graft is taken, in order to reduce the development of bone graft resorption.

KEYWORDS: Decompressive craniectomy, Grafts, Cranium, Craniectomy, Resorption, Size

Burak YURUK : 0000-0001-9901-2690 Adem KURTULUS : 0000-0002-8084-1015 Berkay AYHAN : 0000-0001-9746-1492
Ayhan TEKINER : 0000-0002-3835-2568 Omer SAHIN : 0000-0001-9689-0068 Zeliha CULCU GURCAN : 0000-0002-6564-1963
Yavuz ERDEM : 0000-0002-4446-9228 Koray OZTURK : 0000-0003-3149-1749 Huseyin Omer SEMIZ : 0000-0003-2156-7121
Haydar CELIK : 0000-0002-2702-5457 Tuncer TASCIOGLU : 0000-0002-0359-7274 Mehmet Akif BAYAR : 0000-0002-4285-9476
Mehmet Emre YILDIRIM : 0000-0001-7039-2706 Kemal KANTARCI : 0000-0002-4246-6138

■ INTRODUCTION

Decompressive craniectomy is a surgical intervention frequently used to treat pathologies of elevated intracranial pressure (28). It is the standard surgical treatment for cerebral infarction, intracranial hemorrhage, and malignant brain edema and brain herniation that result from severe traumatic brain injuries (4,10,13,25-27,32). Following decompressive craniectomy, cranioplasty is usually performed for cosmetic improvement and to prevent the development of Trepine Syndrome.

Various materials can be used to repair cranial defects. The traditional and most commonly used material is an autologous bone graft in conjunction with the repositioning of the native bone flap (6). Complications that may develop after cranioplasty, such as those following ventriculoperitoneal shunt surgery, are important (18). The complication rate following cranioplasty can be high as 34% (11), and the postoperative complications include infection, hematoma formation, hydrocephalus, seizures, and bone resorption (6). The rate of post-cranioplasty bone resorption varies (2-32%) in adult patients and can be affected by various factors such as the native bone flap condition, retention techniques, time-to-bone flap repositioning, and patient characteristics (15,22).

Cranioplasty is necessary in patients following decompressive craniectomy to preserve brain tissue and provide an appropriate microenvironment, benefiting the patient both functionally and cosmetically. Currently, a cranial defect of >3 cm is an indication for cranioplasty (1). Following craniectomy, repairing the defect with the patient's own bone is effective in several ways, if the conditions are favorable (e.g., the ability to adequately close the defect and provide the necessary protection). The bone flap is stored in the subcutaneous area of the abdomen following decompressive craniectomy (5,17,21), which is reportedly economically and technically convenient, safe, and preferred in terms of avoiding the risk of infection (5,19,24).

In this study, we evaluated the patients in whom a bone flap was stored in the suprafascial area of the abdomen following decompression, the surgical technique used in autologous cranioplasty, the interval between decompression and cranioplasty, and the relationship between the post-cranioplasty graft-bone border distance and the percentage of bone resorption. The results obtained in this study, its comparison to results of previous studies, and our recommendations are shared in the present study.

■ MATERIAL and METHODS

The data of 121 patients who underwent decompressive craniectomy at the Neurosurgery Clinic, whose records are maintained at SBU Ankara Training and Research Hospital, between 2018 and 2021 were examined. The study was approved by the Ethics Committee of SBU Ankara Training and Research Hospital (No: E-93471371-514.99-890; 16/02/2022).

Inclusion Criteria

The following patients were included:

1. Patients who underwent frontotemporoparietal craniectomy at our clinic
2. Patients in whom the bone flap was placed under the skin in the abdomen during the craniectomy
3. Those who had undergone autologous cranioplasty at our clinic during the follow-up period
4. Patients with adequate follow-up and radiological examinations following craniectomy and cranioplasty

Exclusion Criteria

The following patients were excluded,

1. Patients in whom the craniectomy did not cover the frontotemporoparietal area
2. Patients in whom the bone flap was sacrificed following removal during craniectomy because it could not be stored in the abdomen subcutaneously or could not be reused in the future
3. Patients with insufficient follow-up data or radiological examination data following craniectomy and cranioplasty
4. Patients who have undergone bilateral decompressive craniectomy

Surgery and Follow-Up

In our study, craniectomy covering the frontotemporoparietal region was performed for acute subdural hematoma, parenchymal hematoma, ischemic and/or hemorrhagic, cerebrovascular accident (CVA) and intracranial tumor. In some of the patients, the skin and temporal muscle were stripped and flipped anteriorly in the form of a flap, and the musculocutaneous flap was inverted as one unit. In other patients, the temporal muscle was preserved without dissection. A durotomy was performed in all the patients during surgery. The excised bone was embedded in the suprafacial area of the prepared abdomen during the same procedure. A non-contrast control brain CT was obtained postoperatively in all the patients following the stabilization of their vitals.

During cranioplasty, once the bone flaps were deemed to be favorable for the procedure, the bony margins were established using the previous cranial skin incision. The bone graft was appropriately placed, and a drain was placed in the epidural space. The patients were administered the required daily dose of antibiotics. Postoperatively, the patients were evaluated with a control brain CT.

The patients were followed up after cranioplasty. Early (<40 weeks) and late (>40 weeks) non-contrast control brain CT scans were obtained in all the patients.

Radiological Evaluation

The CT scans of the patients within the first 24 h following frontotemporoparietal craniectomy, within the first 24 h following cranioplasty, and in the early (<40 weeks) and late (>40 weeks) periods following cranioplasty were examined. CT

sections were obtained using the single- and/or multi-detector (helical/multi-slice) technique, with a maximum thickness of 1.3 mm. The sagittal, coronal, and axial section views that were obtained in the bone window format were evaluated and used to reconstruct a 3D model. The post-craniectomy bone defect (cm²), fragmentation of the resected bone flap, shortest distance between the cranioplasty bone graft and the surrounding bone, and percentage of bone resorption on the early and late CT scans were measured. The craniectomy defect (cm²) was calculated by measuring the anteroposterior (AP) and superoinferior (SI) diameters on the 3D reconstructed model of the non-contrast brain CT scans. These diameters were then multiplied by the number of π and divided by four.

To calculate the post-cranioplasty graft distance, the cross-section was aligned in a way that the lateral ventricles and foramen of Monro were visible in the same axial sections of the non-contrast brain CT scans. The shortest distance between the bone graft and the adjacent bone border was measured in the bone window in the anterior craniectomy region. This was taken as the reference because the bone graft is fixed by leaning anteriorly in cranioplasty.

To evaluate the resorption rate of the bone graft following cranioplasty, the patient's long-term non-contrast control brain CT images were aligned in the same way as that for calculating the post-cranioplasty graft distance. A straight line was drawn within the lateral ventricle behind the craniectomy border and on either side of the line (shown Figure 1). The surgical side thickness was compared to that of the non-surgical side by measuring the temporal bone thickness at the border.

Statistical Analysis

All the statistical analyses were performed using SPSS version 21. Visual (histogram and probability graphs) and analytical (Shapiro–Wilk Test) methods were used to assess the variables for normal distribution. Descriptive data are presented as mean and standard deviation for normally distributed variables, median and interquartile range for non-normally distributed variables, and frequency tables for nominal variables. The groups were compared using the Student's t-test for normally distributed variables and Mann–Whitney U-test for non-normally distributed variables. The relationship of non-normally distributed continuous variables was analyzed using the Spearman Rank Correlation Coefficient, and a p-value <0.05 was considered significant.

RESULTS

Among the 121 patients who underwent decompressive craniectomy at our clinic, 39 underwent autologous cranioplasty during the follow-up period and were included in the study [26 (66.7%) male and 13 (33.3%) female]. The mean age of the study participants was 47.31 ± 16.15 years. The patient underwent decompression for the following reasons: parenchymal hematoma (16; 41%), subdural hematoma (12; 30.8%), ischemic CVA (9; 23.1%), and intracranial tumors (2; 5.1%). Eight (20.5%) of the study participants had a history of head trauma at the time of the first admission, while 31 (79.5%) did not.

The temporal muscle and skin were lifted together as a musculocutaneous flap in 12 (30.8%) patients, and the temporal muscle and skin were dissected separately in 27 (69.2%). Among the bone flaps excised during decompression, 35 (89.7%) were placed as a single piece and 4 (10.3%) were placed as fragments in the abdomen. The demographic and pre-cranioplasty characteristics of the patients are listed in Table I.

The average interval between decompressive craniectomy and cranioplasty was 16.97 ± 13.478 weeks (min: 2 weeks, max: 62 weeks). The mean bone defect following decompressive craniectomy was 92.2 ± 10.7 cm² (min: 73.6 cm², max:110.6 cm²).

The resorption rates were not assessed in four patients who underwent revision surgery. More than 70% of the grafted bone thickness was preserved in 20 of the 35 patients, when compared to the bone thickness on the nonsurgical side. In these patients, the resorption rate was <30%. There was no increase in the autologous bone thickness in any of the patients (Figure 1).

There was no statistically significant difference in the post-cranioplasty resorption rates between the patients who presented with head trauma at the first admission and those who did not [OR There was no significant association between the post-cranioplasty resorption rate and the presence of head trauma at the first admission] (p=0.962).

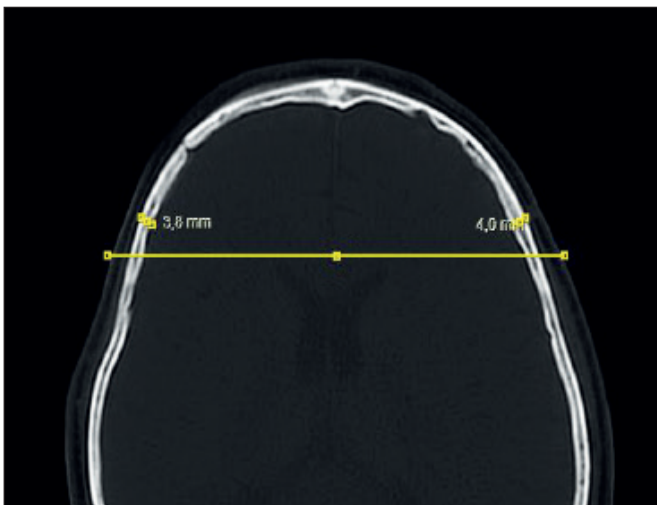
Table I: The Demographic and Cranioplasty Characteristics of the Patients

		n (%)
Gender	Male	26 (66.7)
	Female	13 (33.3)
Decompression indication	Parenchymal hematoma	16 (41)
	Acute Subdural Hematoma	12 (30.8)
	Ischemic CVA	9 (23.1)
	Intracranial tumor	2 (5.1)
Trauma history	Yes	8 (20.5)
	No	31 (79.5)
Decompression Side	Right	19 (48.7)
	Left	20 (51.3)
Musculocutaneous flap	Yes	12 (30.8)
	No	27 (69.2)
Fragmented bone	Yes	4 (10.3)
	No	35 (89.7)
Revision surgery	Yes	4 (7.7)
	No	35 (92.3)

CVA: Cerebrovascular accident.

Table II: The Factors for Craniectomy-Cranioplasty Surgery

		Absorption rate over 30% (n)	Absorption rate below 30% (n)	Total (n)	p-value
Time between craniectomy and cranioplasty	<24 weeks ago	8	17	25	p=0.04
	after >24 weeks	7	3	10	
Craniectomy defect area	70-85cm ²	7	4	11	p=0.39
	85-100 cm ²	6	7	13	
	≥100 cm ²	8	3	11	
Post-cranioplasty distance	< 1mm	0	16	16	p<0.00001
	>1mm	15	4	19	

**Figure 1:** The comparative measurement of the temporal bone thickness in axial sections in non-contrast brain CT during the follow-up of the patients after cranioplasty.

There was no statistically significant difference post-cranioplasty resorption rates between patients in whom musculocutaneous flaps were used during decompressive craniectomy and those in whom musculocutaneous flaps were not. There was no statistically significant association between the post-cranioplasty resorption rate and the use of musculocutaneous flaps during decompressive craniectomy ($p=0.4$).

The association between resorption rates and the interval between decompressive craniectomy and cranioplasty was assessed. The resorption rate was >30% in 7 of the 10 patients in whom the surgeries were performed ≥ 24 weeks apart and <30% in 17 of the 25 patients in whom the surgeries were performed <24 weeks apart ($p=0.04$) (Table II).

There was no significant association between the resorption rates and the existing bone defect area following decompressive craniectomy ($p=0.89$). When the defect dimensions are evaluated in three subgroups, The resorption rate was <30% in 4 of the 11 patients with a defect size of 70–85 cm², in 7 of the 13 patients with a defect of 85–100 cm², and in 3 of the 11 patients with a defect of >100 cm² ($p=0.39$) (Table II).

There was a statistically significant association between the post-cranioplasty resorption rates and the graft-bone border distance (Figure 2). The resorption rates increased in 15 of the 19 patients with a post-cranioplasty distance of ≥ 1 mm ($p<0.00001$). The bone thickness on the surgical side was <70% of the bone thickness on the non-surgical side (Table II).

DISCUSSION

In this study, we detected a decrease in the autologous bone thickness as the interval between the decompressive craniectomy and cranioplasty increased. Furthermore, a distance of ≥ 1 mm between the bone and graft was associated with an increase in the post-cranioplasty resorption rate.

The indication for performing cranioplasty affects the rate of autologous bone graft resorption. Furthermore, bone graft resorption occurs more frequently in patients who have undergone decompressive craniectomy for a traumatic brain injury than in those who have undergone decompression for other causes (6). In a meta-analysis that evaluated the complications of cranioplasty following decompressive craniectomy for a traumatic brain injury, the relative risk of bone graft resorption increased significantly in patients with a history of trauma than in those with other indications for craniectomy (14). Furthermore, patients with bone flap fragmentation following a severe traumatic injury are at greater risk of developing bone resorption than those without bone flap fragmentation. Dunisch et al. reported that fragmentation of the bone graft into two or more fragments is a significant predictor of a higher probability of bone resorption (8). Furthermore, trauma was detected as the indication for primary craniectomy in 89 of the 254 patients who were followed up to determine the long-term complications of cranioplasty. In the present study, the bone resorption was 4%, and 7 of the 10 patients had a history of trauma. A previous study reported that bone fragmentation is a risk factor for resorption (30). In our study, a history of trauma did not affect the resorption rate. The number of patients and possibility of multiple fragmentation of the bone graft for post-traumatic autologous cranioplasty may have affected the study outcome because only patients who underwent autologous cranioplasty were included in our study (3).

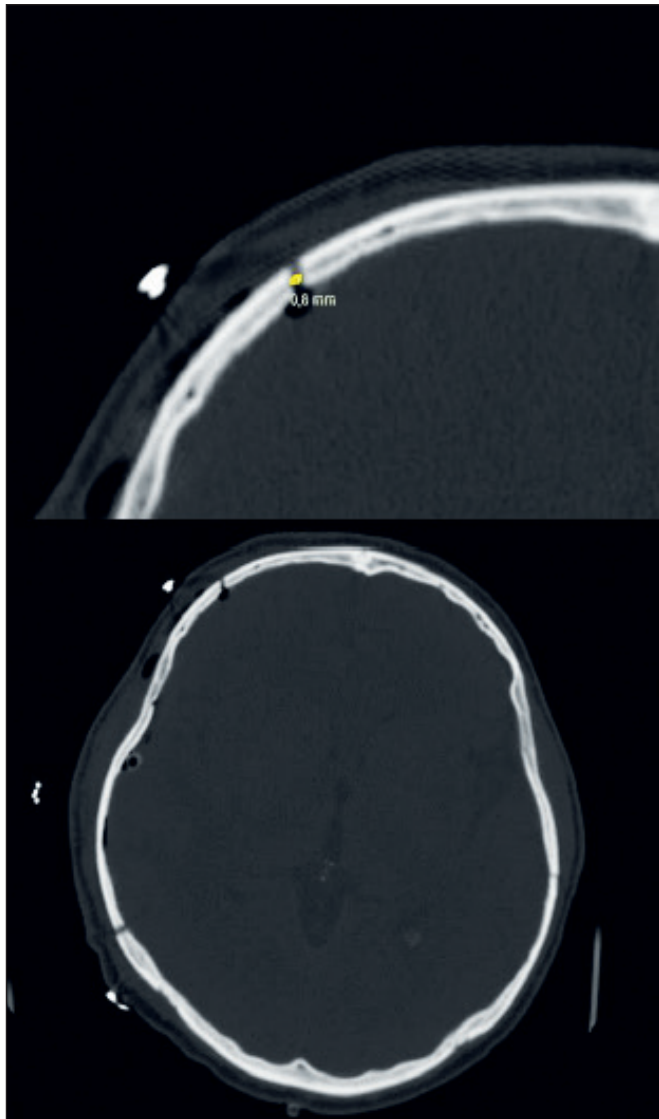


Figure 2: The measurement of the distance between the graft-bone border in the axial section non-contrast brain CT after the cranioplasty surgery of the patients.

The timing of cranioplasty reportedly plays a role in resorption. Although waiting 4–6 months prior to performing cranioplasty is beneficial, recently, an expert's opinion suggests that early cranioplasty should be considered in patients with subcutaneously stored autologous bone grafts because they can undergo progressive resorption over time (14). Further, the resorption rate can increase in patients with an interval of >1 year between decompressive craniectomy and cranioplasty (9). In a study that evaluated 754 patients, in which 532 autologous bone cranioplasties were performed at a single center, the bone resorption rate was the lowest in patients who underwent cranioplasty 15–30 days after decompressive craniectomy (23). In another study of 114 patients who underwent cranioplasty following decompressive craniectomy for a traumatic brain injury, patients in whom cranioplasty was performed within 24 weeks had the least complication rate

(2). Similarly, in the present study, patients who underwent cranioplasty >24 weeks after craniectomy had statistically significant resorption rates. This finding is remarkable in that complications were not seen when cranioplasty performed within 24 weeks.

A study evaluating the complications of early autologous cranioplasty determined that the bone graft was not completely implanted along the edge of the previous craniectomy site. Thus, a gap was formed between the bone graft and skull. When this distance was measured using 3D CT imaging, the resorption rate was 17% in patients with a cavity size of <2 mm and 50% in patients with a cavity size of ≥ 4 mm (31). In a retrospective study that examined bone graft resorption-fusion rates following cranioplasty, fusion occurred successfully in patients with a gap of <1 mm (16). In the present study, the resorption rate was >30% in 15 of the 19 patients with a gap of ≥ 1 mm. Furthermore, the bone thickness on the operated side was <70% when compared to the bone thickness on the non-surgical side ($p < 0.00001$). This shows that the surgical instruments used for craniectomy and the surgical technique applied should leave a finer gap.

In the present study, all 20 patients with 70% resorption were over the age of 18 years. In the study of Badih et al., resorption occurred in 3 patients over the age of 18, at 6, 9 and 19 months (6). In studies conducted in the pediatric age group, this time varies between 4.8–13.3 months. Studies show that bone resorption is more common in patients who are younger than in those who are older (3,12,20). Furthermore, younger patients tend to develop bone flap resorption at earlier time intervals. Schuss et al. reported that 60% of bone flap resorption was detected in patients who were followed up for 1 year, but not in patients those who were followed up for >5 years (29). However, age was not a consistent risk factor for bone resorption in all the studies.

In the present study, the resorption rate was <30% in 4 of the 11 patients with a bone defect of 70–85 cm², in 7 of the 13 patients with a bone defect of 85–100 cm², and in 3 of the 11 patients with a bone defect of >100 cm² ($p = 0.39$). Grant et al. (12) reported that the incidence of bone resorption was significantly associated with an increased skull defect area. They reported a resorption rate of 60% resorption if the bone graft size was >75 cm²; there was no resorption if the bone graft size was <75 cm². Schoekler et al. evaluated eight patients and determined that a defect of >120 cm² was associated with a higher risk of bone graft resorption (29). However, other studies did not detect any relationship between the bone flap size and an increase in the resorption rates (7,8). Although all patients had a large defect in the study by Daou et al., the rate of resorption was still low (6). Thus, it remains unclear whether the defect size is a risk factor.

The study had some limitations. It was conducted at a single center and only patients who underwent autologous bone grafting were evaluated. However, a strength of our study was that we noted that the instruments used for craniectomy and the technique applied are capable of leaving thinner gaps.

CONCLUSION

The present study findings support those of literature that early cranioplasty after a craniectomy reduces the risk of complications. Additionally, the defect produced during craniectomy should be small and the gap between the bone graft and craniectomy edge should be reduced to decrease the risk developing bone graft resorption. Further studies are required in this area with larger sample sizes.

AUTHORSHIP CONTRIBUTION

Study conception and design: BY

Data collection: BY, BA, ZCG

Analysis and interpretation of results: AT, YE, HC

Draft manuscript preparation: BY, MEY, AK, OS

Critical revision of the article: KO, TT, KK, HOS, MAB

Other (study supervision, fundings, materials, etc...): MAB

All authors (BY, AT, YE, HC, MEY, AK, OS, KO, TT, KK, BA, ZCG, HOS, MAB) reviewed the results and approved the final version of the manuscript.

REFERENCES

- Aydin S, Kucukyuruk B, Abuzayed B, Aydin S, Sanus GZ: Cranioplasty: Review of materials and techniques. *J Neurosci Rural Pract* 2:162-167, 2011. <https://doi.org/10.4103/0976-3147.83584>
- Basheer N, Gupta D, Mahapatra A, Gurjar H: Cranioplasty following decompressive craniectomy in traumatic brain injury: Experience at Level-I apex trauma centre. *Indian J Neurotrauma* 7:139-144, 2010. [https://doi.org/10.1016/S0973-0508\(10\)80029-2](https://doi.org/10.1016/S0973-0508(10)80029-2)
- Bowers CA, Riva-Cambrin J, Hertzler DA, Walker ML: Risk factors and rates of bone flap resorption in pediatric patients after decompressive craniectomy for traumatic brain injury. *J Neurosurg Pediatrics* 11:526-532, 2013. <https://doi.org/10.3171/2013.1.PEDS12483>
- Celik H, Kurtulus A, Yildirim ME, Tekiner A, Erdem Y, Kantarci K, Halil K, Bayar MA: The comparison of autologous bone, methyl-methacrylate, porous polyethylene, and titanium mesh in cranioplasty. *Turk Neurosurg* 32:841-844, 2022. <https://doi.org/10.5137/1019-5149.JTN.37476-21.1>
- Cheah PP, Rosman AK, Cheang CK, Idris B: Autologous cranioplasty post-operative surgical site infection: Does it matter if the bone flaps were stored and handled differently? *The Malaysian J Med Sci* 24:68, 2017. <https://doi.org/10.21315/mjms2017.24.6.8>
- Daou B, Zanaty M, Chalouhi N, Dalyai R, Jabbour P, Yang S, Rosenwasser RH, Tjoumakaris S: Low incidence of bone flap resorption after native bone cranioplasty in adults. *World Neurosurg* 92:89-94, 2016. <https://doi.org/10.1016/j.wneu.2016.04.115>
- De Bonis P, Frassanito P, Mangiola A, Nucci CG, Anile C, Pompucci A: Cranial repair: How complicated is filling a "hole"? *J Neurotrauma* 29:1071-1076, 2012. <https://doi.org/10.1089/neu.2011.2116>
- Duenisch P, Walter J, Sakr Y, Kalff R, Waschke A, Ewald C: Risk factors of aseptic bone resorption: A study after autologous bone flap reinsertion due to decompressive craniotomy. *J Neurosurg* 118:1141-1147, 2013. <https://doi.org/10.3171/2013.1.JNS12860>
- Fan Mc, Wang QI, Sun P, Zhan Sh, Guo P, Deng Ws, Dong Q: Cryopreservation of autologous cranial bone flaps for cranioplasty: A large sample retrospective study. *World Neurosurg* 109:e853-e859, 2018. <https://doi.org/10.1016/j.wneu.2017.10.112>
- Fiorot Jr JA, Silva GS, Cavalheiro S, Massaro AR: Use of decompressive craniectomy in the treatment of hemispheric infarction. *Arq Neuropsiquiatr* 66:204-208, 2008. <https://doi.org/10.1590/S0004-282X2008000200012>
- Gooch MR, Gin GE, Kenning TJ, German JW: Complications of cranioplasty following decompressive craniectomy: Analysis of 62 cases. *Neurosurg Focus* 26:E9, 2009. <https://doi.org/10.3171/2009.3.FOCUS0962>
- Grant GA, Jolley M, Ellenbogen RG, Roberts TS, Gruss JR, Loeser JD: Failure of autologous bone-assisted cranioplasty following decompressive craniectomy in children and adolescents. *J Neurosurg Pediatrics* 100:163-168, 2004. <https://doi.org/10.3171/ped.2004.100.2.0163>
- Halil K, Celik H, Kurtulus A, Tekiner A, Erdem Y, Gulnur K, Bayar MA: The effect of alpha lipoic acid on cerebrospinal fluid biochemistry and brain edema after experimental traumatic brain injury. *Turk Neurosurg* 30:666-672, 2020
- Henry J, Amoo M, Murphy A, O'Brien DP: Complications of cranioplasty following decompressive craniectomy for traumatic brain injury: Systematic review and meta-analysis. *Acta Neurochirurgica* 163:1423-1435, 2021. <https://doi.org/10.1007/s00701-021-04809-z>
- Iwama T, Yamada J, Imai S, Shinoda J, Funakoshi T, Sakai N: The use of frozen autogenous bone flaps in delayed cranioplasty revisited. *Neurosurgery* 52:591-596, 2003. <https://doi.org/10.1227/01.NEU.0000047891.86938.46>
- Jeon JP, Heo Y, Kang SH, Yang JS, Choi HJ, Cho YJ: Retrospective chronologic computed tomography analysis of bone flap fusion and resorption after craniotomy and autologous cryopreserved cranioplasty. *World Neurosurg* 129:e900-e906, 2019. <https://doi.org/10.1016/j.wneu.2019.06.088>
- Kreider GN: Repair of cranial defect by new method: report of apparently successful case. *J Am Med Assoc* 74:1024-1024, 1920. <https://doi.org/10.1001/jama.1920.26210150001013>
- Kurtulus A, Tekiner A, Halil K, Erdem Y, Celik H, Yildirim ME, Bayar MA: Evaluation of shunt revisions in pediatric hydrocephalus cases. *Eskisehir Medical Journal* 3:5-10, 2022. <https://doi.org/10.48176/esmj.2022.46>
- Lee BS, Min KS, Lee MS, Kim YG, Kim DH: Comparison with subcutaneous abdominal preservation and cryoconservation using autologous bone flap after decompressive craniectomy. *Korean J Nutrition* 8:21-25, 2012. <https://doi.org/10.13004/kjnt.2012.8.1.21>
- Martin KD, Franz B, Kirsch M, Polanski W, von der Hagen M, Schackert G, Sobottka SB: Autologous bone flap cranioplasty following decompressive craniectomy is combined with a high complication rate in pediatric traumatic brain injury patients. *Acta Neurochirurgica* 156:813-824, 2014. <https://doi.org/10.1007/s00701-014-2021-0>

21. Menekse G, Celik H, Erdem Y, Guvenc Y, Cikla U, Kul H, Tekiner A, Caydere M, Bayar MA: Deneysel rat laminektomi modelinde Contractubex®; in adezyon önleyici özellikleri: Morfolojik ve histopatolojik bir çalışma. *J Neurological Sci* 32:708-717, 2015 (Turkish)
22. Moreira-Gonzalez A, Jackson IT, Miyawaki T, Barakat K, Dinick V: Clinical outcome in cranioplasty: Critical review in long-term follow-up. *J Craniofacial Surg* 14:144-153, 2003. <https://doi.org/10.1097/00001665-200303000-00003>
23. Morton RP, Abecassis IJ, Hanson JF, Barber JK, Chen M, Kelly CM, Nerva JD, Emerson SN, Ene CI, Levitt MR: Timing of cranioplasty: A 10.75-year single-center analysis of 754 patients. *J Neurosurg* 128:1648-1652, 2017. <https://doi.org/10.3171/2016.11.JNS161917>
24. Movassaghi K, Ver Halen J, Ganchi P, Amin-Hanjani S, Mesa J, Yaremchuk MJ: Cranioplasty with subcutaneously preserved autologous bone grafts. *Plast Reconstr Surg* 117:202-206, 2006. <https://doi.org/10.1097/01.prs.0000187152.48402.17>
25. Murthy J, Chowdary G, Murthy T, Syed Ameer Bhasha P, Jaishree Naryanan T: Decompressive craniectomy with clot evacuation in large hemispheric hypertensive intracerebral hemorrhage. *Neurocrit Care* 2:258-262, 2005. <https://doi.org/10.1385/NCC:2:3:258>
26. Otani N, Takasato Y, Masaoka H, Hayakawa T, Yoshino Y, Yatsushige H, Miyawaki H, Sumiyoshi K, Chikashi A, Takeuchi S: Surgical outcome following decompressive craniectomy for poor-grade aneurysmal subarachnoid hemorrhage in patients with associated massive intracerebral or Sylvian hematomas. *Cerebrovasc Dis* 26:612-617, 2008. <https://doi.org/10.1159/000165115>
27. Qiu W, Guo C, Shen H, Chen K, Wen L, Huang H, Ding M, Sun L, Jiang Q, Wang W: Effects of unilateral decompressive craniectomy on patients with unilateral acute post-traumatic brain swelling after severe traumatic brain injury. *Crit Care* 13:1-7, 2009. <https://doi.org/10.1186/cc8178>
28. Rossini Z, Nicolosi F, Koliass AG, Hutchinson PJ, De Sanctis P, Servadei F: The history of decompressive craniectomy in traumatic brain injury. *Front Neurol* 10:458, 2019. <https://doi.org/10.3389/fneur.2019.00458>
29. Schoekler B, Trummer M: Prediction parameters of bone flap resorption following cranioplasty with autologous bone. *Clin Neurol Neurosurg* 120:64-67, 2014. <https://doi.org/10.1016/j.clineuro.2014.02.014>
30. Schuss P, Vatter H, Oszvald Á, Marquardt G, Imöhl L, Seifert V, Guresir E: Bone flap resorption: Risk factors for the development of a long-term complication following cranioplasty after decompressive craniectomy. *J Neurotrauma* 30:91-95, 2013. <https://doi.org/10.1089/neu.2012.2542>
31. Zawy Alsofy S, Stroop R, Fusek I, Sakellaropoulou I, Lewitz M, Nakamura M, Ewelt C, Fortmann T: Early autologous cranioplasty: complications and identification of risk factors using virtual reality visualisation technique. *Br J Neurosurg* 33:664-670, 2019. <https://doi.org/10.1080/02688697.2019.1661962>
32. Zhao Z, Yu J, Liao S, Xiong L, Liang Z, Ling L, Wang F, Hou Q, Zhou W, Pei Z: Delayed decompressive craniectomy improves the long-term outcomes in hypertensive rats with space-occupying cerebral infarction. *Neurocrit Care* 7:263-269, 2007. <https://doi.org/10.1007/s12028-007-0074-0>