



# Morphometry of Latissimus Dorsi in Fetal Cadavers for Prenatal Spina Bifida Surgery

Berfu OZDEMIR<sup>1</sup>, Ahmet DURSUN<sup>2</sup>, Yedigir KASTAMONI<sup>1</sup>, Mehtap AYAZOGLU<sup>3</sup>, Onur Can SANLI<sup>4</sup>, Soner ALBAY<sup>1</sup>

<sup>1</sup>Suleyman Demirel University, Faculty of Medicine, Department of Anatomy, Isparta, Türkiye

<sup>2</sup>Karamanoglu Mehmetbey University, Faculty of Medicine, Department of Anatomy, Karaman, Türkiye

<sup>3</sup>Kirklareli University, Faculty of Medicine, Department of Anatomy, Kirklareli, Türkiye

<sup>4</sup>Lokman Hekim University, Faculty of Medicine, Department of Anatomy, Ankara, Türkiye

**Corresponding author:** Berfu OZDEMIR ✉ d2140305003@ogr.sdu.edu.tr, ozdemir.berf@gmail.com

## ABSTRACT

**AIM:** To investigate latissimus dorsi morphometry, innervation, vascularization, and variational situations in fetuses.

**MATERIAL and METHODS:** Forty-nine fetuses, aged between 15 and 40 weeks of gestation, were examined for the morphological development of the latissimus dorsi. The horizontal lengths of the thoracolumbar fascia, the dimensions of the latissimus dorsi and its tendon were measured. Additionally, the attachments of the latissimus dorsi and the branching pattern of the thoracodorsal nerve were evaluated. The development of all measured parameters during gestational age (trimester) and their interrelationships were assessed. Data were compared across sides (right and left) and genders.

**RESULTS:** The study found that the increase in all parameters was proportional to gestational age. No significant differences were observed between sides or genders. The latissimus dorsi was directly attached (via muscle fiber) to the iliac crest in 60.2% of cases. An 88.5% attachment rate to the inferior angle of the scapula was noted, with 4.1% of these attachments being muscular. Additionally, 9.8% of latissimus dorsi tendons were found to adhere to the teres major tendon. The thoracodorsal nerve was observed to divide into 2 to 8 branches before entering the latissimus dorsi.

**CONCLUSION:** We believe this study will provide valuable insights into the development of intrauterine invasive fetal procedures for tendon, muscle, and nerve transfer repair and assist in determining the most appropriate timing for intervention.

**KEYWORDS:** Development, Latissimus dorsi, Spina bifida, Thoracodorsal nerve, Thoracolumbar fascia

**ABBREVIATIONS:** LD: Latissimus dorsi, TLF: Thoracolumbar fascia, TN: Thoracodorsal nerve, DP: Dominant pedicle, TM: Teres major, SD: Standard deviation

## INTRODUCTION

Latissimus dorsi (LD) is a large triangular-shaped muscle that originates from the third or fourth ribs, iliac crest, spinous processes of the last six thoracic vertebrae (T7-T12), and thoracolumbar fascia (TLF) (9). The upper part of the muscle undergoes a 180-degree rotation to form the tendon

that inserts into the intertubercular sulcus of the humerus (9). Innervation is performed by the thoracodorsal nerve (TN) (9). LD is supplied primarily by the thoracodorsal artery, the terminal branch of the subscapular artery (9). LD is supplied secondarily by the ninth, tenth, and eleventh posterior intercostal arteries, subcostal artery, first and second lumbar arteries (9).

Berfu OZDEMIR : 0000-0001-5851-0300  
Ahmet DURSUN : 0000-0003-4568-8761  
Yedigir KASTAMONI : 0000-0002-3504-5853

Mehtap AYAZOGLU : 0000-0001-9027-7633  
Onur Can SANLI : 0000-0003-4225-0000  
Soner ALBAY : 0000-0001-8438-8628

Most of the studies on LD have been done on adult cadavers. Few studies have been found in the literature on fetal cadavers using the dissection method (5,9,17). It is essential to investigate LD in fetal cadavers. It is a versatile muscle with a wide range of use in neonatal and intrauterine flap surgery and adults (5).

We believe that understanding the development and variations of the LD during the fetal period will enhance the evaluation of intrauterine cases. It will offer insights for future intrauterine flap surgery in patients with myelomeningocele, as well as aid in diagnosing anomalies and pathologies related to LD. Accordingly, this study aimed to explore the morphometry, innervation, vascularization, and variational states of the LD in fetuses.

**■ MATERIAL and METHODS**

This study was performed in line with the principles of the Declaration of Helsinki. Approval was granted by the Ethics Committee of the Faculty of Medicine (Date: 01.04.2021, Decision No: 9/161). The study was conducted on 49 formalin-fixed fetuses (98 pcs LD) (25 male, 24 female) in the laboratory of the Department of Anatomy, Faculty of Medicine. Fetuses, aged between 15–40 weeks of gestation, not having external anomalies and pathologies (Table I), were procured from the Maternity and Children’s Hospital between 1996 and 2014, with the consent of their families. The reason for death in fetuses are not specified. All fetuses were arterially injected with 10% (v/v) formaldehyde solution into the water and preserved in a pool containing the same solution.

Crown-rump length, bi-parietal diameter, head circumference, femur length, and foot length were used to determine the gestational age (20,23). Cases with tissue loss from previous dissections, which would prevent safe measurements, were excluded from the study. This study was approved by the Clin-

ical Research Ethics Committee of the Faculty of Medicine (Date: 01.04.2021, Decision No: 9/161). The authors confirm that all efforts were made to comply with local and international ethical guidelines and laws regarding the use of human cadaveric donors in anatomical research.

A skin incision was made along the mid-axillary line in the axillary region of fetuses. In the same way, a skin incision was made along the line of spinous processes of vertebrae, and superficial fascia was removed from fetuses by lifting it together with skin.

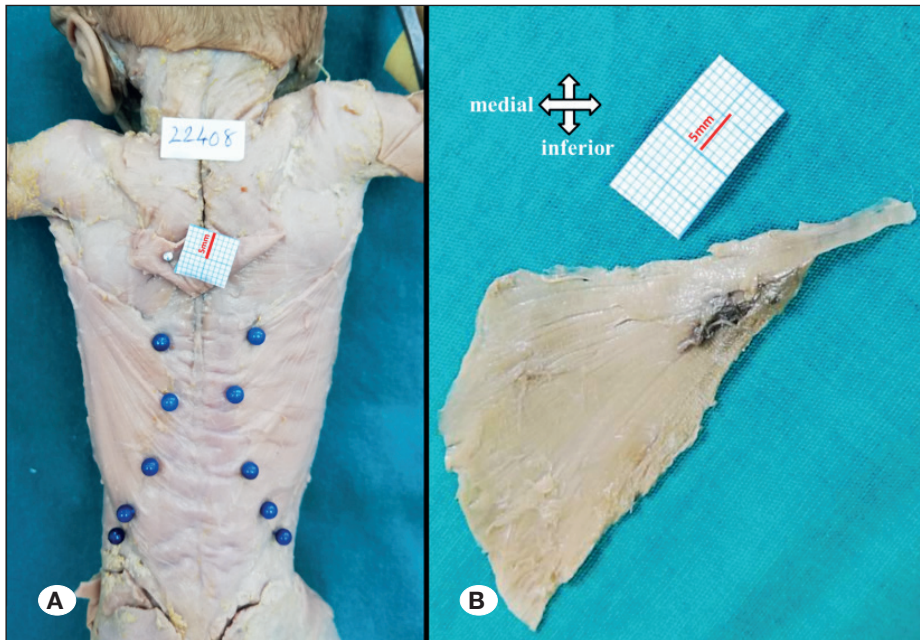
The lower part of the trapezius was removed, making LD visible. Fetuses were photographed from the same distance and position with a millimeter scale by placing arms in a prone horizontal position in abduction so that right and left LD are visible (Figure 1A). Then, by feeding the LD proximally, the thoracodorsal artery, vein, and nerve were dissected bilaterally and made visible using magnifying glasses with 3.5x magnification.

By preserving the integrity of the LD, its anterior edge, posterior edge, attachment to the iliac crest, and the tendon in the humerus where it was inserted were cut and removed, along with the muscle’s neurovascular structures. LDs were photographed again on a flat surface with its costal surface on top (Figure 1B).

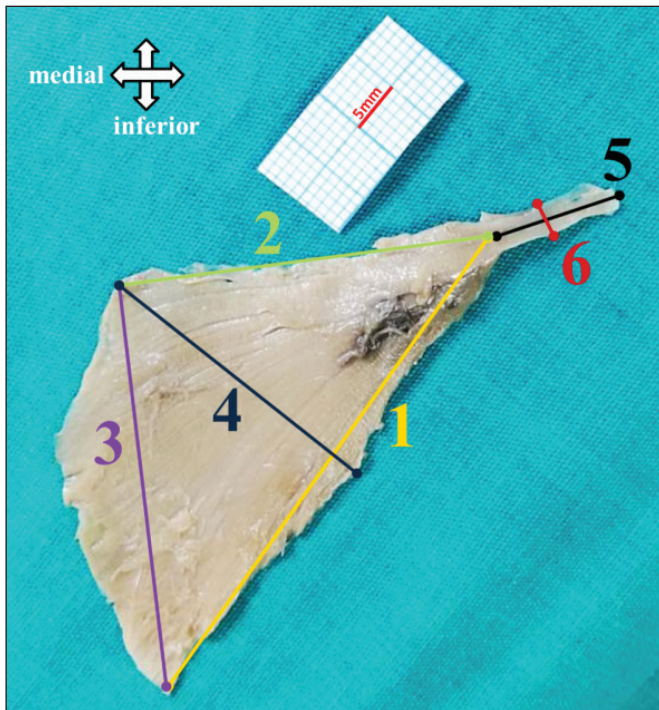
Anterior border length of LD: The distance between the tendon origin of LD and the iliac crest was measured (Figure 2). Superior border length of LD: The length of the upper edge of the muscle from the tendon origin of LD to the spinous process of the thoracic vertebra was measured (Figure 2). Posterior border length of LD: The distance from the spinous process of the thoracic vertebra, where the upper edge of LD terminates, to the place where it attaches to the iliac crest, was measured (Figure 2). Width of LD: Measured at the widest level of the muscle (Figure 2). Tendon length of LD: Measured

**Table I:** Number of Fetuses by Trimester, Month and Sex

Trimester (Weeks)	Months (Weeks)	Number of gender		%
		Male	Female	
2 <sup>nd</sup> trimester (15-24 weeks)	4 <sup>th</sup> month (15-16 weeks)	0	1	2.04
	5 <sup>th</sup> month (17-20 weeks)	2	5	14.29
	6 <sup>th</sup> month (21-24 weeks)	3	3	12.24
	Total (15-24 weeks)	5	9	28.57
3 <sup>rd</sup> trimester (25-36 weeks)	7 <sup>th</sup> month (25-28 weeks)	7	4	22.45
	8 <sup>th</sup> month (29-32 weeks)	4	4	16.33
	9 <sup>th</sup> month (33-36 weeks)	3	3	12.24
	Total (25-36 weeks)	14	11	51.02
Full term (37-40 weeks)	10 <sup>th</sup> month (37-40 weeks)	6	4	20.41
	Total (37-40 weeks)	6	4	20.41
Total (15-40 weeks)		25	24	100.00



**Figure 1: A)** Right and left latissimus dorsi (LD) image of a 24-week-old fetus. **B)** The costal surface on top, left LD with dominant pedicle removed.



**Figure 2:** Left latissimus dorsi (LD) image of a 24-week-old fetus with costal surface on top, 1- Anterior border length of LD, 2- Superior border length of LD, 3- Posterior border length of LD, 4- Width of LD, 5- Tendon length of LD, 6- Tendon width of LD.

at the middle level of the tendon (Figure 2). Tendon width of LD: Measured at the widest level of the tendon (Figure 2).

Distance between insertion of LD and dominant pedicle (DP) (Insertion of LD - DP): The longest distance between the insertion of LD and the point where the dominant neurovascu-

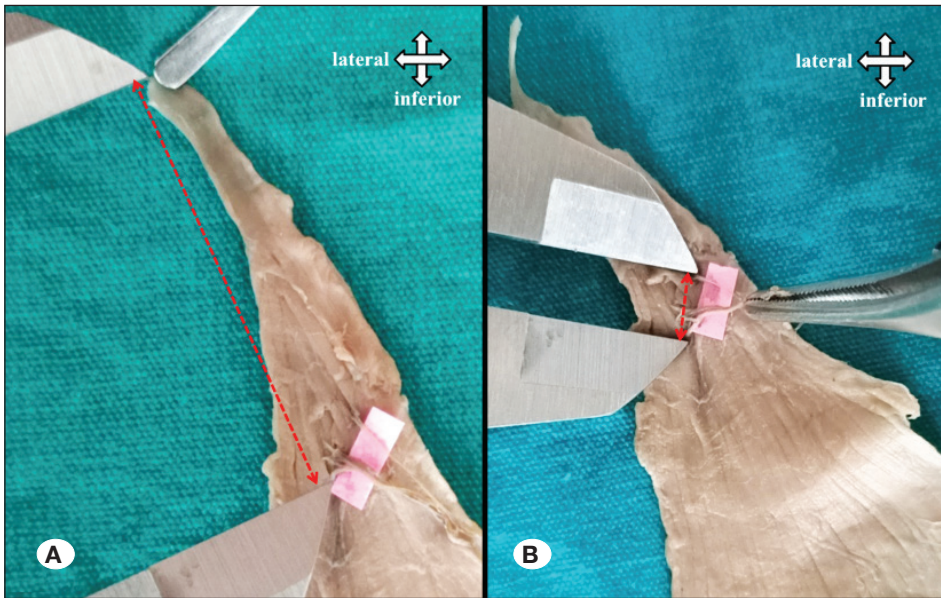
lar pedicle enters LD was measured (Figure 3A). Dominant pedicle width of LD: The longest distance between the points where the neurovascular structures of the dominant pedicle enter LD was measured (Figure 3B).

Horizontal lengths of thoracolumbar fascia at T7, T10, T12, L2, and L4 vertebral segments (TLF T7, TLF T10, TLF T12, TLF L2, TLF L4): The distance from spinous processes of T7, T10, T12, L2 and L4 vertebrae to the junction of LD with TLF was measured horizontally (Figure 4).

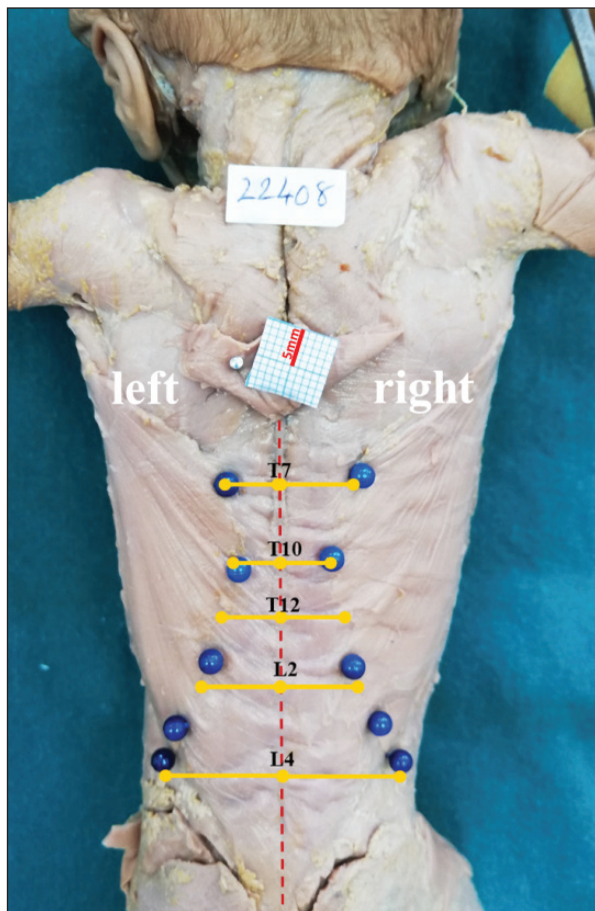
It was evaluated whether the attachment of the lowest muscle fibers of LD to the iliac crest was direct or through fascia. It was assessed whether LD was attached to the inferior angle of the scapula (Figure 5). The positional relationship between LD and teres major (TM) tendons was evaluated (Figure 6). The branching pattern and number of TN were determined when entering LD.

In our study, necessary evaluations were documented, and measurements of Insertion of LD – DP and Dominant pedicle width of LD were taken using a digital vernier caliper with 0.01 mm sensitivity. Other measurements were conducted using the ImageJ program (National Institutes of Health, Bethesda, MD) on photographs. Additionally, any detected variational conditions were recorded.

The data were analyzed using SPSS version 20 for Windows. Minimum, maximum, mean, and standard deviation (SD) values of parameters were calculated according to gestational age groups (trimester and month) and gender. The normality of Z-score distributions was assessed using the Kolmogorov-Smirnov and Shapiro-Wilk W-tests. Due to the large sample sizes, a statistically significant non-normality was accepted unless the normal plot showed a clear deviation from a straight line (22). Independent samples t-test, One-way ANOVA, Pearson correlation test, and Simple Linear Regression



**Figure 3:** **A)** Insertion of latissimus dorsi (LD) - dominant pedicle (DP): Distance between insertion of LD and dominant pedicle. **B)** Dominant pedicle width of LD.



**Figure 4:** Red vertical dashed line: shows the middle line (spinous processes of vertebrae), Blue pins: indicate the junctional border of thoracolumbar fascial (TLF) with latissimus dorsi (LD), Horizontal yellow lines: show horizontal length between spinous process (T7, T10, T12, L2, and L4) in the corresponding vertebra and the junction of TLF with LD.

Models were used since our data showed normal distribution. The P value  $<0.05$  was considered statistically significant.

## RESULTS

All 49 fetuses in our study had bilateral LD. The maximum, minimum, mean, and SD of all the measured parameters related to the LD are presented in Table II. When right and left side measurements were compared, no significant difference was found in all parameters in general and trimester groups. No statistically significant difference was determined upon evaluating the parameters regarding gender.

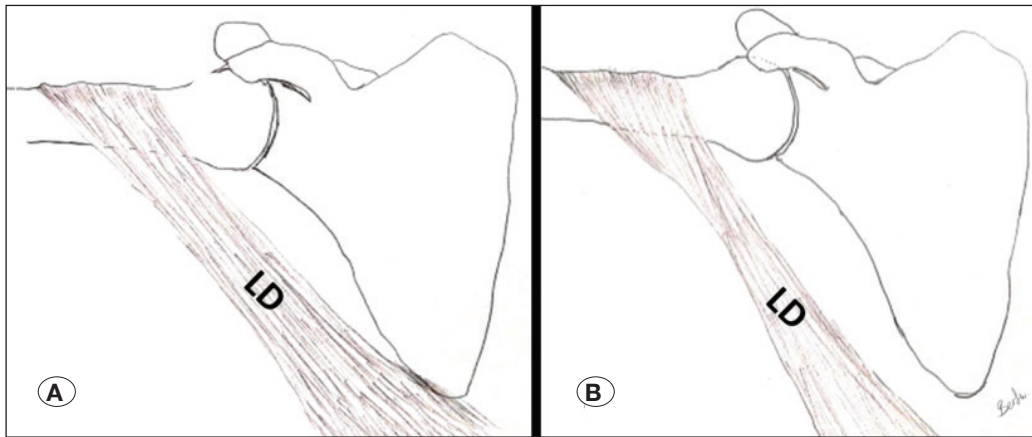
It was determined that all of these parameters of LD increased according to trimesters, and there was a statistically significant difference between trimesters ( $p < 0.001$ , Table II).

When examining the correlation of gestational age (weeks) with the Anterior border length of LD ( $r = 0.913$ ), Posterior border length of LD ( $r = 0.912$ ), and Width of LD ( $r = 0.942$ ), a very strong relationship was detected. The regression graph and equation showing the change in these parameters according to gestational age (weeks) are given in Figures 7 and 8.

Attachment of LD to the iliac crest was evaluated in 98 cases. It was determined that it was attached directly by muscle fiber in 59 cases (60.2%), and in 39 cases (39.8%) it was attached through fascia.

The attachment of LD to the inferior angle of the scapula was investigated in 96 cases. Attachment to the inferior angle of the scapula was detected in 85 cases (88.5%). It was seen that only 4 (4.1%) of those attachments were through muscle fiber, while 81 (84.4%) of them were through fascia (Table III).

Positionally, due to the close proximity of LD and TM tendons, the separate or combined course of the tendons was investigated. It was observed that LD and TM tendons were completely separated and inserted into separate places in 83



**Figure 5: A)** Latissimus dorsi (LD) is attached to the inferior angle of the scapula. **B)** LD not attached to the inferior angle of the scapula.

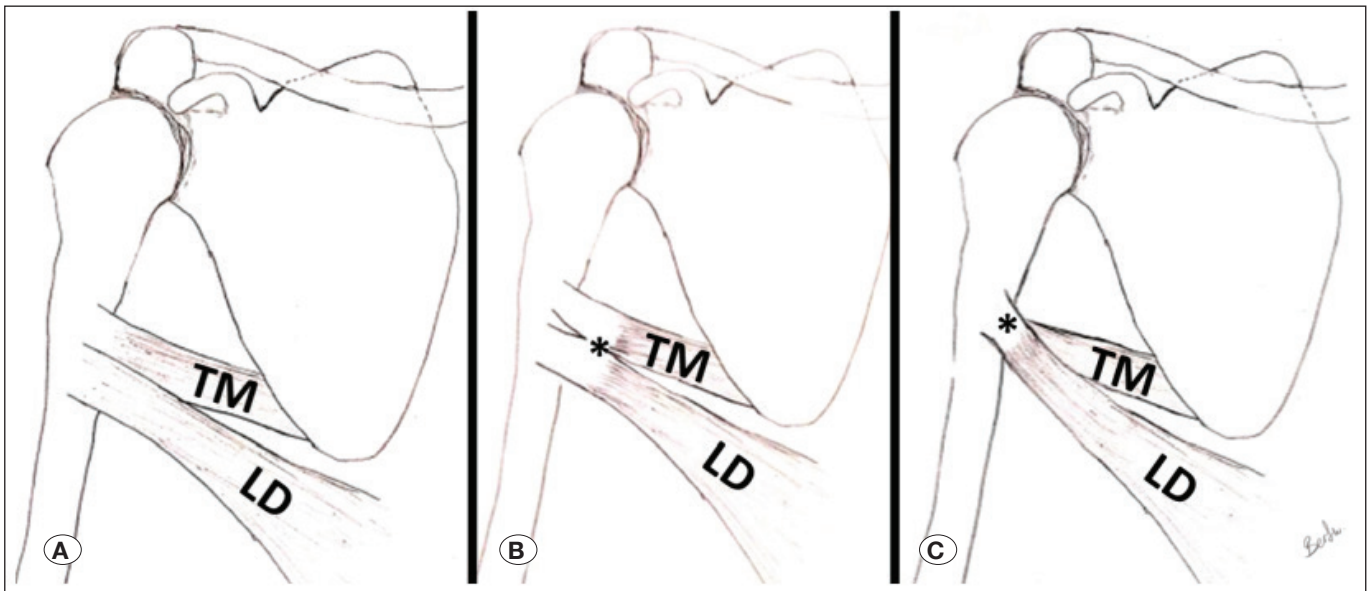
**Table II:** The Maximum, Minimum, Mean, SD Values and Comparison according to Trimesters of all the Measured Parameters Related to LD

Parameters	Trimester	n	Minimum (mm)	Maximum (mm)	Mean (mm)	SD	p-value
Anterior border length of LD	2	26	37.55	73.04	51.49	9.12	<0.001
	3	46	46.11	122.42	82.27	17.43	
	4	20	79.97	130.87	108.17	11.83	
	Total	92	37.55	130.87	79.20	24.72	
Superior border length of LD	2	26	15.28	43.24	27.30	5.94	<0.001
	3	46	22.39	70.13	42.47	10.27	
	4	20	39.23	71.51	54.92	8.80	
	Total	92	15.28	71.51	40.89	13.24	
Posterior border length of LD	2	26	22.02	53.07	37.22	8.43	<0.001
	3	46	42.68	84.93	61.09	12.07	
	4	20	55.54	100.55	82.03	11.21	
	Total	92	22.02	100.55	58.90	19.29	
Width of LD	2	26	10.52	33.18	23.78	5.84	<0.001
	3	46	27.00	59.06	40.35	8.70	
	4	20	44.74	63.88	54.69	4.65	
	Total	92	10.52	63.88	38.78	13.13	
Tendon length of LD	2	26	7.22	14.93	11.91	1.92	<0.001
	3	46	10.31	24.17	16.21	3.21	
	4	20	16.80	27.52	20.90	2.63	
	Total	92	7.22	27.52	16.01	4.20	

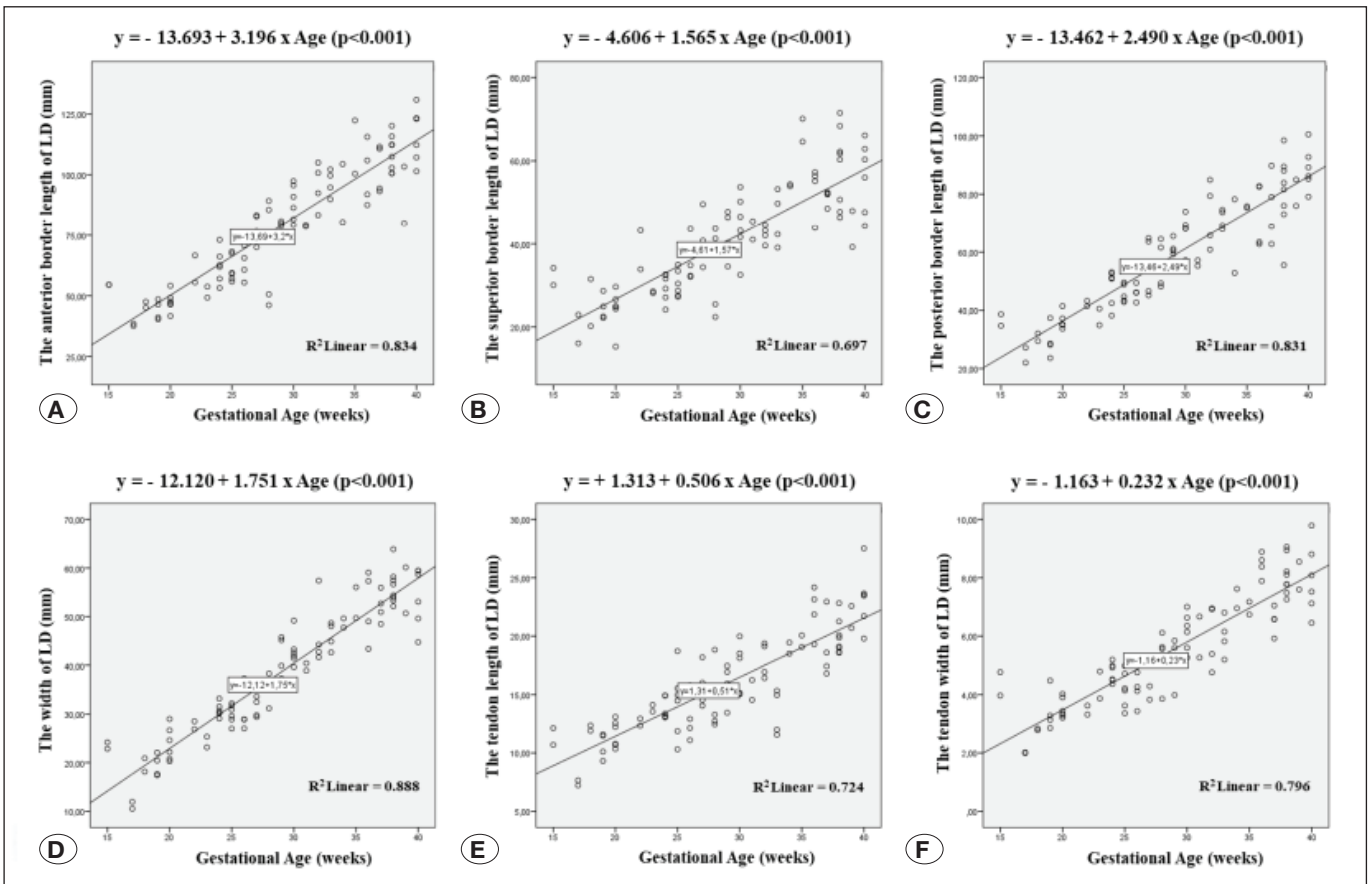
Table II: Cont.

Parameters	Trimester	n	Minimum (mm)	Maximum (mm)	Mean (mm)	SD	p-value
Tendon width of LD	2	26	2.00	5.19	3.75	0.89	<0.001
	3	46	3.36	8.89	5.68	1.40	
	4	20	5.92	9.79	7.73	0.99	
	Total	92	2.00	9.79	5.58	1.84	
Insertion of LD - DP	2	25	16.93	29.52	22.57	3.08	<0.001
	3	48	20.08	44.32	31.07	5.63	
	4	20	31.45	46.90	39.32	3.68	
	Total	93	16.93	46.90	30.56	7.46	
Dominant pedicle width of LD	2	25	3.57	9.30	5.45	1.46	<0.001
	3	48	4.07	16.52	8.13	2.69	
	4	20	5.15	14.85	11.14	2.47	
	Total	93	3.57	16.52	8.06	3.07	
TLF T7	2	26	7.23	17.64	10.86	2.60	<0.001
	3	50	6.73	24.24	12.62	3.58	
	4	20	10.96	22.17	16.69	3.01	
	Total	96	6.73	24.24	12.99	3.79	
TLF T10	2	26	5.45	13.10	8.44	1.75	<0.001
	3	50	5.75	17.11	10.12	2.69	
	4	20	9.51	18.56	13.88	2.38	
	Total	96	5.45	18.56	10.45	3.05	
TLF T12	2	26	3.95	13.79	9.35	2.45	<0.001
	3	50	6.45	24.85	13.10	3.73	
	4	20	9.47	18.88	15.15	2.37	
	Total	96	3.95	24.85	12.51	3.78	
TLF L2	2	26	7.93	16.50	11.50	2.40	<0.001
	3	50	8.97	30.43	16.96	4.18	
	4	20	14.11	27.82	21.76	3.46	
	Total	96	7.93	30.43	16.48	5.07	
TLF L4	2	26	7.97	19.61	12.93	2.84	<0.001
	3	50	12.34	31.42	18.16	3.48	
	4	20	17.23	33.81	24.37	5.21	
	Total	96	7.97	33.81	18.04	5.42	

**LD:** Latissimus dorsi, **Insertion of LD - DP:** Distance between insertion of LD and dominant pedicle, **TLF:** Thoracolumbar fascia, **SD:** Standard deviation.



**Figure 6:** LD: Latissimus dorsi, TM: Teres major, (\*): adhesion point. **A)** LD and TM tendons are completely separate. **B)** LD and TM tendons are adhered. **C)** LD and TM tendons are fully fused.



**Figure 7:** Linear regression graphs and equations of all parameters with gestational age. **A)** Anterior border length of LD. **B)** Superior border length of LD. **C)** Posterior border length of LD. **D)** Width of LD. **E)** Tendon length of LD. **F)** Tendon width of LD.

**Table III:** Attachment of LD to Inferior Angle of Scapula

Attachment of LD to inferior angle of scapula	n (%)
Absent	11 (11.5)
Available (via fascia)	81 (84.4)
Available (via muscle fiber)	4 (4.1)
Total	96 (100.0)

**LD:** *Latissimus dorsi*.

**Table IV:** Relationship Between LD and TM Tendons

Relationship between LD and TM tendons	n (%)
Adhered	9 (9.8)
Completely separate	83 (90.2)
Total	92 (100.0)

**LD:** *Latissimus dorsi*, **TM:** *Teres major*

**Table V:** Branch Number and Shape of TN

Number branches of TN	Branching pattern of TN	n (%)
2	2 major branches	11 (11.3)
	Total	11 (11.3)
3	3 major branches	15 (15.4)
	2 major branches; one of the branches splits into 2	2 (2.1)
	Total	17 (17.5)
4	4 major branches	28 (28.9)
	2 major branches; one of the branches splits into 3	1 (1.0)
	2 major branches; both branches split into 2	8 (8.2)
	Total	37 (38.1)
5	5 major branches	18 (18.6)
	2 major branches; one of the branches splits into 3, the other splits into 2	1 (1.0)
	Total	19 (19.6)
6	6 major branches	7 (7.2)
	4 major branches; one of the branches splits into 3	1 (1.0)
	3 major branches; all three branches split into 2	1 (1.0)
	2 major branches; both branches split into 3	2 (2.1)
Total	11 (11.3)	
7	2 major branches; one of the branches splits into 4, the other splits into 3	1 (1.0)
	Total	1 (1.0)
8	2 major branches; one of the branches splits into 6, the other splits into 2	1 (1.0)
	Total	1 (1.0)
<b>Total</b>		<b>97 (100.0)</b>

**TN:** *Thoracodorsal nerve*.

cases. At the same time, it was determined that the tendons progressed together and separated from each other during insertion in 9 cases. No tendon relationship was observed that progressed completely together and ended by insertion in the same place in any case (Table IV).

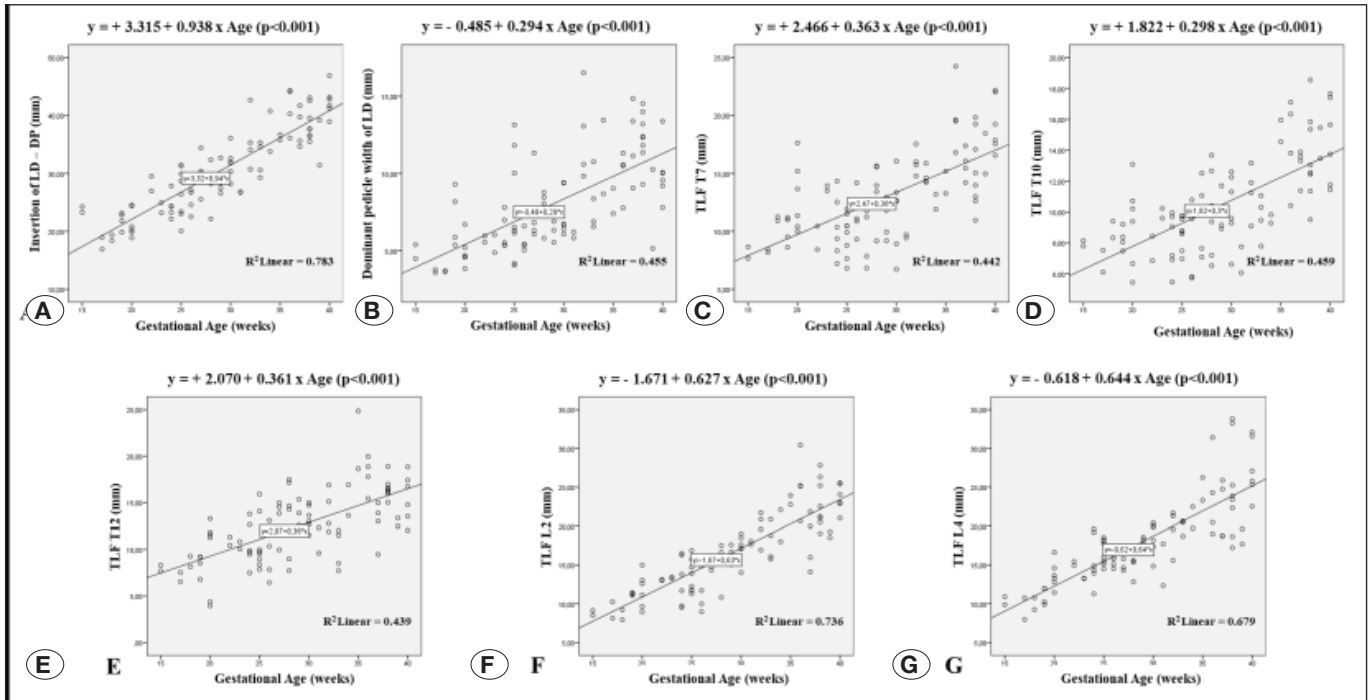
TN was seen to branch in different numbers up to the point where it entered LD. Accordingly, it was determined that TN gave 2-8 branches (Figure 9, 10). The way TN is divided into branch numbers was also noted (Table V).

#### Variation Outcomes


In the study, 4 axillary arches were found bilaterally in two female fetuses at 21 (second trimester) and 28 (third trimester) weeks of age. It was detected that there was an additional tendon for LD insertion bilaterally in the 21-week-old fetus. It was observed that both right and left variational tendons were inserted into the coracoid process.

It was determined that the axillary arch, which was detected bilaterally in the 28-week-old fetus, had a different course. The right axillary arch inserts into the short head of the biceps bra-






**Figure 8:** Linear regression graphs and equations of all parameters with gestational age. **A)** Inset of LD - DP. **B)** Dominant pedicle width of LD. **C)** TLF T7. **D)** TLF T10. **E)** TLF T12. **F)** TLF L2. **G)** TLF L4.



**Figure 9:** LD: Latissimus dorsi, TN: Thoracodorsal nerve, Red dots: branches from TN. **A)** TN is divided into 2 branches. **B)** TN is divided into 3 branches. **C)** TN is divided into 4 branches. **D)** TN is divided into 5 branches.



**Figure 10:** LD: Latissimus dorsi, TN: Thoracodorsal nerve, Red dots: branches from TN. **A)** TN is divided into 6 branches. **B)** TN is divided into 7 branches. **C)** TN is divided into 8 branches.

chii. It was revealed that the left axillary arch was divided into two parts and inserted in two different places; one of the variational tendons was inserted in the short head of the biceps brachii, while the other was inserted in the coracoid process.

## DISCUSSION

It has been shown that prenatal intervention in patients with myelomeningocele can arrest the neural destruction caused by exposure of the spinal cord to the intrauterine environment and thus significantly improve the neurological outcome at birth (17). Latissimus dorsi is widely used in intrauterine or postnatal myelomeningocele repairs (17,28,29). Although there are many studies on LD morphometry, innervation, vascularization, and variations (14,19,21), little information has been published about these data in fetal cadavers (5,9). Investigating variations and development of LD and TLF in the fetal period, revealing the normal anatomy, will be a guide in studies and surgical interventions in this region.

When length and width measurements were evaluated, a statistically significant increase was observed in all parameters during gestational age ( $p < 0.001$ ). We found few studies in the literature on anterior, superior, and posterior border lengths of LD (5,9). In the study conducted by De Andrade et al. on the left side of 8 fetuses, anterior, superior, and posterior border lengths of LD were reported as 59-98 mm range, 21-58 mm range, and 40-71 mm range, respectively (9). In the study conducted by Beger et al. bilaterally on 50 fetuses, the mean anterior, superior, and posterior border lengths of LD were reported as  $76.41 \pm 21.40$  mm,  $45.44 \pm 13.53$  mm, and  $44.44 \pm 11.84$  mm, respectively (5). In our study, the mean

anterior, superior, and posterior border lengths of LD were  $79.20 \pm 24.72$  mm,  $40.89 \pm 13.24$  mm, and  $58.90 \pm 19.29$  mm, respectively. Although anterior, superior, and posterior border lengths of LD in our study were consistent with the data of other studies, slight differences were observed. We think this may be due to the difference in the population and the number of samples studied.

Mean width of LD, tendon length of LD, and tendon width of LD values were reported by Beger et al. as  $23.32 \pm 5.85$  mm,  $6.77 \pm 1.56$  mm, and  $3.46 \pm 0.96$  mm, respectively (5). In our study, the mean width of LD, tendon length of LD, and tendon width of LD values were found to be  $38.78 \pm 13.13$  mm,  $16.01 \pm 4.20$  mm, and  $5.58 \pm 1.84$  mm, respectively. The mean width of LD, tendon length of LD, and tendon width of LD values in our study were found to be higher than the values in the study of Beger et al. (5). We believe that this discrepancy could be because, in our work, LD-related parameters were measured after the fetus was separated, whereas Beger et al. (5) measured LD-related parameters on the fetus. Our measurement method may provide more reliable results, considering using LD as an appropriately sized free flap.

We could not find a statistically significant difference when we compared all the length and width measurement values between right - left and genders. Similar to our findings, Beger et al. also observed no statistical difference between sides and genders during the fetal period (5).

LD tendon transfer has been used before for irreparable tears of Rotator Cuff and has been reported to give successful results (12). In addition, LD tendon transfer can be performed in children born with brachial plexus palsy (4). It is predicted that

defining the location of neurovascular structures relative to the tendon of LD will provide information that will facilitate tendon transfer (21). For this reason, we included measurements of the insertion of LD – DP and dominant pedicle width of LD in our study, as these were not reported in the existing literature. We believe this data is crucial for identifying the entry points of neurovascular structures into the LD and preserving the thoracodorsal artery, vein, and nerve. Based on our findings, the inferior limit should not exceed approximately 30 mm from the insertion point to ensure safe LD tendon transfer in newborns.

It was stated that to understand and palpate TLF, the width of TLF should be measured according to different vertebral segments (16). It was emphasized that these measurements are essential in diagnosing TLF-related pathologies, determining correct palpation methods, and planning treatment (16). Data comparison is based on a previous fetal histological section study and an adult anatomical study, as we could not find any published studies in fetuses of the horizontal length of TLF to the border with LD. In the study by Abe et al., in which they examined the connections of the posterior layer of the TLF on paraffin-embedded histological sections of 25 fetuses, they reported that they saw LD in the thoracic sections, not in the abdominal sections (1). In a study conducted by Marpalli et al., using a millimetric ruler on 20 adult cadavers, it was reported that the horizontal length of TLF was different at different vertebral segments, and the measurement at the L4 segment was higher than at other vertebral segments. In addition, the authors found no significant difference between side measurements at the same vertebral segment (16). Similarly, in our study, the widest TLF horizontal length was measured at the L4 segment, and no statistically significant difference was observed between the sides at the same vertebral segment. We think that the reason why our results are similar to those of Abe et al. and Marpalli et al. may be because the direction of TLF during prenatal growth and development is compatible with the adult TLF configuration (1,16). We think TLF horizontal length data at the vertebral level can contribute to determining the appropriate LD flap designs for prenatal and postnatal repair surgeries.

It has been reported that regression formulas related to LD width and margin lengths may be helpful in designing flap sizes when LD muscle is suitable for flap surgery that should be performed immediately after birth or in the womb (5). Of 100 LD muscles aged between 18 to 36 weeks, Beger et al. identified a positive correlation between gestational age and Surface Area of LD ( $R^2 = 0.814$ ;  $p < 0.001$ ), Length of Anterior Margin of LD ( $R^2 = 0.794$ ;  $p < 0.001$ ), Length of Posterior Margin of LD ( $R^2 = 0.706$ ;  $p < 0.001$ ) (5). In this study, a robust relationship was established between gestational age and Anterior border length of LD ( $R^2 = 0.834$ ;  $p < 0.001$ ), Posterior border length of LD ( $R^2 = 0.831$ ;  $p < 0.001$ ), Width of LD ( $R^2 = 0.888$ ;  $p < 0.001$ ), (Figure 7).

Beger et al. emphasize that LD can be preferred in cases requiring osteomuscular flaps, and for this, how LD is attached to the iliac crest plays a crucial role (5). Moreover, it may also be necessary for LD flap design to be planned more distally. It has been stated that it is not possible to know whether LD

muscle fibers come into contact with the iliac crest before the operation (7). In the study of Yahia and Vacher (7), on 30 adult and 6 fetal cadavers, they reported the rate of direct attachment of LD muscle fibers to the iliac crest as 13.33% and 66.66%, respectively. Beger et al. reported the rate of direct attachment of LD muscle fibers to the iliac crest as 59% in their study on 50 fetuses (5). Our study determined the rate of direct attachment of LD muscle fibers to the iliac crest to be 60.2%. The similarity between our results and those of Beger et al. could be attributed to their study's comparable number and population of fetuses (5). We think the difference in the results of Yahia and Vacher (7) may be due to the different number of fetuses studied. The results of adult and fetal cadaver studies suggest that the fascia attachment of LD to the iliac crest may vary with age. Early in development, LD was predominantly attached directly to the iliac crest by muscle fibers. Still, as it developed, it revealed a more extensive attachment to the iliac crest via fascia. Thus, it can be considered that LD muscle can be used effectively in cases requiring osteomuscular flaps at an early age.

Very few studies have been conducted on the relationship between LD and the inferior angle of the scapula (22, 31). Some anatomy textbooks state that the LD attaches to the inferior angle of the scapula, yet no detailed information is provided on this aspect (25, 26). It has been stated that the attachment of LD to the inferior angle of the scapula via muscle fibers may limit the mobility of the tendon and muscle in the abduction and external rotation of the humerus (22). It was noted that 43% of LD was attached to the inferior angle of the scapula via muscle fibers in 100 cadaver shoulders examined by Pouliart and Gagey (22). Williams et al. (31) examined 8 cadaver shoulders and reported that no LD was attached to the inferior angle of the scapula by muscle fibers. Our study noted that 88.5% of LD was attached to the inferior angle of the scapula, and only 4.1% of these were via muscle fiber. The results of our study regarding the attachment of LD to the inferior angle of the scapula show some differences from other studies. This difference may be due to the different cadaver populations and the number studied.

It has been reported that the LD tendon is a suitable option for use in tendon transfer surgery in the shoulder region due to its ideal length and strength (10). Moreover, findings have been reported that LD and TM tendons are interconnected, which makes separation difficult (4). Therefore, various studies on the relationship between LD and TM tendons (4,6,10,11). Table VI summarizes studies on the relationship between LD and TM tendons. The results of these studies, ours included, differ from each other, possibly due to the variety of breeds studied and the differences in sample sizes. Investigating the tendon relationships between the LD and the TM may aid in predicting outcomes in surgical procedures requiring tendon release or transfer and preventing damage to adjacent structures.

It has been reported that the TN yields successful outcomes in situations requiring nerve grafting, such as in cases of facial nerve paralysis (24). This success is attributed to TN's characteristics as a motor nerve, including its appropriate branching pattern, length, and capacity (30). Therefore, there are various

**Table VI:** Comparison of the Relationship Between LD and TM Tendons in Our Study with Other Studies

	LD and TM tendons are fully fused (ending with insertion at the same point)	LD and TM tendons adhered (ending with insertion at different points)	LD and TM tendons are completely separate (ending with separate insertion)
	n (%)	n (%)	n (%)
Beck and Hoffer, (4) (n=8)		1 (12.5)	7 (87.5)
Iamsaard et al., (11) (n=1)	1 (100.0)		
Goldberg et al., (10) (n=12)	1 (8.3)	3 (25.0)	8 (66.7)
Beger et al., (6) (n=100)	4 (4.0)	2 (2.0)	94 (94.0)
Present study (n=92)	0 (0.0)	9 (9.8)	83 (90.2)

**LD:** *Latissimus dorsi*, **TM:** *Teres major*.

studies on how many branches TN splits before entering LD (3,5,28,29). It was determined by Bartlett et al. that 2 branches were separated in 86% of the samples, and a small medial branch was separated from the lateral branch in 14% (3). It was reported by Theeuwes et al. that 2 branches were separated in 27% (on three sides) and 3 branches in 73% (on eight sides) of the samples (28). It was found by Tobin et al. that 2 branches were separated in 94% and 3-4 branches in 6% of the samples (29). It was reported by Beger et al. that 2 branches were separated in 93% (93 sides), 3 branches in 6%, and 4 branches in 1% of the samples (5). Although our data on the branching of TN did not match the rates of other studies, it was observed that TN was divided into 5-8 branches with a rate of 32.9%. We think that the differences may be due to the number of samples studied and differences between populations. Therefore, more studies are needed on the number and shape of TN branching.

The axillary arch is a variational muscle originating from LD while inserting in different places (13). It has been observed that this anomaly commonly extends to TM, long head of triceps brachii, short head of biceps brachii, coracobrachialis, coracoid process, medial epicondyle of humerus, pectoralis major and minor (2). When Tattera et al. evaluated all 28 studies in their meta-analysis study, the incidence of the axillary arch was found to be 5.3% (27). In our study, we observed the axillary arch in 4 cases (4.1%). This rate is consistent with the rates reported in the literature. Moreover, the literature has reported that the axillary arch is a bidirectional slip that typically includes an origo and an insertion (8). However, a few cases where the connections of the axillary arch are more complex, extending to more than one region, have also been described (15,18). Similarly, our study found a multiple axillary arch in one axilla, originating from the LD, then branching off and terminating in two regions: the short head of the biceps brachii and the coracoid process.

## ■ CONCLUSION

Understanding the development, morphometric characteristics, and variations of the LD and the TLF during the fetal

period is crucial for diagnosing pathologies in that region and planning treatments for anomalies. For this reason, our study presents data on parameters and variational conditions of LD not observed in initial examinations of fetal cadavers, offering insights from a more comprehensive series than those in previous studies. In the morphometric measurements obtained, it was discovered that the development of LD in the intrauterine period was similar between right - left sides and between genders, and no statistically significant difference was observed in the developmental patterns of these groups during the intrauterine period. Moreover, the detailed description of muscle anomalies in the axilla and evaluation of the associated clinical results may help better understand the basis of surgical intervention in this region. In the presence of a variational condition in this region, such as the axillary arch, it may be beneficial for clinicians and surgeons to consider that the lymph node may be hidden behind this arch and cause compression of the neurovascular structures.

It seems possible that the LD musculocutaneous flap can be used effectively and reliably to close large lumbosacral defects. It should be taken into consideration that, especially in cases where myelomeningocele is detected, repair before birth may have a protective effect and prevent the neural plate from drying out. We anticipate that this study and subsequent research comparing prenatal and postnatal treatments will provide valuable insights for developing intrauterine invasive fetal procedures and determining the optimal timing for intervention.

## ■ ACKNOWLEDGMENTS

This study was prepared from the MS thesis of Berfu Ozdemir.

The authors sincerely thank the individuals who donated their bodies to science, enabling anatomical research to be conducted. Results from this research have the potential to enhance our collective knowledge and subsequently improve patient care. Accordingly, these donors and their families are owed our deepest gratitude.

**Declarations**

**Funding:** No funding or support from any organization was received for the submitted work.

**Availability of data and materials:** The data analyzed or used to support the findings of the current study are available from the corresponding author upon reasonable request.

**Disclosure:** The authors declare that they have no conflict of interest.

**AUTHORSHIP CONTRIBUTION**

Study conception and design: BO, AD, SA

Data collection: BO, YK, MS

Analysis and interpretation of results: BO, AD, OCS

Draft manuscript preparation: MS, OCS

Critical revision of the article: BO, AD, YK, SA

Other (study supervision, fundings, materials, etc...): BO, MS, OCS

All authors (BO, AD, YK, MS, OCS, SA) reviewed the results and approved the final version of the manuscript.

**REFERENCES**

1. Abe H, Hayashi S, Kim JH, Murakami G, Rodríguez-Vázquez JF, Jin ZW: Fetal development of the thoracolumbar fascia with special reference to the fascial connection with the transversus abdominis, latissimus dorsi, and serratus posterior inferior muscles. *Surg Radiol Anat* 43:917-928, 2021. <https://doi.org/10.1007/s00276-020-02668-4>
2. Baidya R, Kumar S: Extra slip of latissimus dorsi tendon and its clinical significance. *Int J Anat Res* 5:4733-4735, 2017. <https://doi.org/10.16965/ijar.2017.459>
3. Bartlett SP, May JW Jr, Yaremchuk MJ: The latissimus dorsi muscle: A fresh cadaver study of the primary neurovascular pedicle. *Plast Reconstr Surg* 67:631-636, 1981. <https://doi.org/10.1097/00006534-198105000-00010>
4. Beck PA, Hoffer MM: Latissimus dorsi and teres major tendons: Separate or conjoint tendons? *J Pediatr Orthop* 9:308-309, 1989. <https://doi.org/10.1097/01241398-198905000-00009>
5. Beger O, Beger B, Uzmanse D, Erdogan S, Kurtoglu Z: Morphometric properties of the latissimus dorsi muscle in human fetuses for flap surgery. *Surg Radiol Anat* 40:881-889, 2018. <https://doi.org/10.1007/s00276-017-1946-4>
6. Beger O, Koc T, Beger B, Kayan G, Uzmanse D, Olgunus ZK: Quantitative assessment of the growth dynamics of the teres major in human fetuses. *Surg Radiol Anat* 40:1349-1356, 2018. <https://doi.org/10.1007/s00276-018-2090-5>
7. Ben Hadj Yahia S, Vacher C: Does the latissimus dorsi insert on the iliac crest in man? Anatomic and ontogenic study. *Surg Radiol Anat* 33:751-754, 2011. <https://doi.org/10.1007/s00276-011-0812-z>
8. Bonastre V, Rodríguez-Niedenführ M, Choi D, Sañudo JR: Coexistence of a pectoralis quartus muscle and an unusual axillary arch: Case report and review. *Clin Anat* 15:366-370, 2002. <https://doi.org/10.1002/ca.10053>
9. De Andrade FG, Lima JSB, Oliveira MFQ, Da Silva LCL, Teixeira JG, Salvador LH: Morphometric study of the latissimus dorsi muscle in human fetuses. *Rev Bras Cir Pla'st* 30:51-57, 2015. <https://doi.org/10.5935/2177-1235.2015RBCP0116>
10. Goldberg BA, Elhassan B, Marciniak S, Dunn JH: Surgical anatomy of latissimus dorsi muscle in transfers about the shoulder. *Am J Orthop (Belle Mead NJ)* 38:E64-67, 2009
11. Iamsaard S, Thunyaharn N, Chaisiwamongkol K, Boonruangsri P, Uabundit N, Hipkaeo W: Variant insertion of the teres major muscle. *Anat Cell Biol* 45:211-213, 2012. <https://doi.org/10.5115/acb.2012.45.3.211>
12. Kadow TR, Meredith SJ, Garcia D, Minorini R, Delaney R, Baratz M, Lin A: Latissimus dorsi tendon transfer and superior capsular reconstruction for irreparable, posterosuperior rotator cuff tears. *Arch Bone Jt Surg* 9:44-49, 2021
13. Kalaycioglu A, Gumusalan Y, Ozan H: Anomalous insertional slip of latissimus dorsi muscle: Arcus axillaris. *Surg Radiol Anat* 20:73-75, 1998. <https://doi.org/10.1007/s00276-998-0073-7>
14. Lama P, Potu BK, Bhat KM: Chondrohumeralis and axillary arch of Langer: A rare combination of variant muscles with unique insertion. *Rom J Morphol Embryol* 51:395-397, 2010
15. Loukas M, Noordeh N, Tubbs RS, Jordan R: Variation of the axillary arch muscle with multiple insertions. *Singapore Med J* 50:e88-90, 2009
16. Marpalli S, Mohandas Rao KG, Venkatesan P, George BM: The morphological and microscopical characteristics of posterior layer of human thoracolumbar fascia; A potential source of low back pain. *Morphologie* 105:308-315, 2021. <https://doi.org/10.1016/j.morpho.2021.01.001>
17. Meuli-Simmen C, Meuli M, Adzick NS, Harrison MR: Latissimus dorsi flap procedures to cover myelomeningocele in utero: A feasibility study in human fetuses. *J Pediatr Surg* 32:1154-1156, 1997. [https://doi.org/10.1016/S0022-3468\(97\)90673-4](https://doi.org/10.1016/S0022-3468(97)90673-4)
18. Mirhoseini M, Haratizadeh S, Shokri M, Torabi F, Talebpour Amiri FB: Introduction of a variation in latissimus dorsi muscle (the axillary arch of Langer). *Jentashapir J Health Res* 6:54-56, 2015. <https://doi.org/10.17795/jjhr-24364>
19. Moore CW, Rice CL: Rare muscular variations identified in a single cadaveric upper limb: A four-headed biceps brachii and muscular elevator of the latissimus dorsi tendon. *Anat Sci Int* 93:311-316, 2018. <https://doi.org/10.1007/s12565-017-0408-8>
20. Moore KL, Persaud TVN, Torchia MG: The developing human: Clinical oriented embryology, 11th ed. Philadelphia: Elsevier, 2020:76-99
21. Morelli M, Nagamori J, Gilbert M, Miniaci A: Latissimus dorsi tendon transfer for massive irreparable cuff tears: An anatomic study. *J Shoulder Elbow Surg* 17:139-143, 2008. <https://doi.org/10.1016/j.jse.2007.03.018>

22. Pouliart N, Gagey O: Significance of the latissimus dorsi for shoulder instability. I. Variations in its anatomy around the humerus and scapula. *Clin Anat* 18:493-499, 2005. <https://doi.org/10.1002/ca.20185>
23. Salomon LJ, Bernard JP, Duyme M, Buvat I, Ville Y: The impact of choice of reference charts and equations on the assessment of fetal biometry. *Ultrasound Obstet Gynecol* 25:559-565, 2005. <https://doi.org/10.1002/uog.1901>
24. Samardzic MM, Grujicic DM, Rasulic LG, Milicic BR: The use of thoracodorsal nerve transfer in restoration of irreparable C5 and C6 spinal nerve lesions. *Br J Plast Surg* 58(4):541-546, 2005. <https://doi.org/10.1016/j.bjps.2003.12.027>
25. Schunke M, Schulte E, Schumacher U, Voll M, Wesker K: *Atlas de Anatomia Prometheus*, 1st ed. Rio de Janeiro: Guanabara Koogan, 2007:118- 179
26. Standring S: *Gray's anatomy: The anatomical basis of clinical practice*, 41st ed. London: Churchill Livingstone, Elsevier, 2016:815- 922
27. Tattera D, Henry BM, Zarzecki MP, Sanna B, Pekala PA, Ciocchi R, Walocha JA, Tubbs RS, Tomaszewski KA: Prevalence and anatomy of the axillary arch and its implications in surgical practice: A meta-analysis. *Surgeon* 17:43-51, 2019. <https://doi.org/10.1016/j.surge.2018.04.003>
28. Theeuwes HP, Gosselink MP, Bruynzeel H, Kleinrensink GJ, Walbeehm ET: An anatomical study of the length of the neural pedicle after the bifurcation of the thoracodorsal nerve: Implications for innervated free partial latissimus dorsi flaps. *Plast Reconstr Surg* 127:210-214, 2011. <https://doi.org/10.1097/PRS.0b013e3181f95a8e>
29. Tobin GR, Schusterman M, Peterson GH, Nichols G, Bland KI: The intramuscular neurovascular anatomy of the latissimus dorsi muscle: The basis for splitting the flap. *Plast Reconstr Surg* 67:637-641, 1981. <https://doi.org/10.1097/00006534-198105000-00011>
30. White WM, McKenna MJ, Deschler DG: Use of the thoracodorsal nerve for facial nerve grafting in the setting of pedicled latissimus dorsi reconstruction. *Otolaryngol Head Neck Surg* 135:962-964, 2006. <https://doi.org/10.1016/j.otohns.2005.09.017>
31. Williams GR Jr, Shakil M, Klimkiewicz J, Iannotti JP: Anatomy of the scapulothoracic articulation. *Clin Orthop Relat Res* 359:237-246, 1999. <https://doi.org/10.1097/00003086-199902000-00027>