



# Relationship Between Defect Volume and Comorbid Pathologies in Patients Undergoing Surgery for Myelomeningocele

Zeliha CULCU GURCAN<sup>1</sup>, Haydar CELIK<sup>2</sup>, Yavuz ERDEM<sup>2</sup>, Ayhan TEKINER<sup>2</sup>, Dilek KAHVECIOGULLARI<sup>2</sup>, Berkay AYHAN<sup>3</sup>, Burak YURUK<sup>4</sup>, Serdar CENGİZ<sup>5</sup>, Kemal KANTARCI<sup>6</sup>, Tuncer TASCIOGLU<sup>2</sup>, Mehmet Emre YILDIRIM<sup>2</sup>, Hakan GURCAN<sup>7</sup>, Omer SAHIN<sup>2</sup>

<sup>1</sup>Sincan Training and Research Hospital, Department of Neurosurgery, Ankara, Türkiye

<sup>2</sup>Ankara Training and Research Hospital, Department of Neurosurgery, Ankara, Türkiye

<sup>3</sup>Duzce Ataturk Public Hospital, Department of Neurosurgery, Duzce, Türkiye

<sup>4</sup>Nigde Omer Halisdemir Training and Research Hospital, Department of Neurosurgery, Nigde, Türkiye

<sup>5</sup>Genesis Hospital, Department of Neurosurgery, Türkiye

<sup>6</sup>Hatay Training and Research Hospital, Department of Neurosurgery, Hatay, Türkiye

<sup>7</sup>Dr. Sami Ulus Children's Diseases Training and Research Hospital, Department of Pediatrics, Ankara, Türkiye

Corresponding author: Zeliha CULCU GURCAN ✉ culcuzeliha@gmail.com

## ABSTRACT

**AIM:** To determine sac volume based on radiological examinations in patients undergoing surgery for myelomeningocele (MMC) and to investigate the relationship of sac volume with hydrocephalus and Chiari malformation type 2 (CM) with a view to determining the optimum length of follow-up and recommend a treatment plan.

**MATERIAL and METHODS:** The present study involved the retrospective review of radiologic examinations and medical files of 81 patients who underwent surgery for myelomeningocele between 2015 and 2022 in the neurosurgery clinic of Ankara Training and Research Hospital. Then, MMC sac volumes were measured and the statistical relationship of these measurements with the Evans Index, progressive enlargement of the ventricles after sac repair and CM was investigated.

**RESULTS:** Of the 81 patients, 41 (50.6%) were boys and 40 (49.4%) were girls. The median MMC sac volume was 11,005.28 mm<sup>3</sup> and the mean Evans index (EI) based on brain tomography performed on postnatal day 1 was 0.405 ± 0.146. Analysis of the relationship between the EI and MMC sac volume yielded r=0.622, p<0.001 and showed a strong positive correlation between the two parameters at a statistical significance level of 5%. Evans Indexes based on brain tomography scans performed on postnatal day 1 showed that ventriculomegaly was present in 49 (60.5%) patients and absent in 32 (39.5%) patients. In patients who developed hydrocephalus after sac repair, there was no correlation between the day of intervention and sac volume. Mean sac volume was 28,297.36 mm<sup>3</sup> in 28 patients with comorbid CM versus 7,600.32 mm<sup>3</sup> in patients without CM. All children with CM required shunting.

**CONCLUSION:** Patients with larger myelomeningocele sac volume have higher risk of concomitant hydrocephalus or subsequent development of hydrocephalus after sac repair compared to patients with a smaller sac volume. These patients should definitely be evaluated for same-session intervention. Patients with a larger sac volume and/or comorbid CM should be followed up more frequently and for a longer period of time.

**KEYWORDS:** Arnold-Chiari malformation, Evans index, Hydrocephalus, Myelomeningocele, Ventriculomegaly

**ABBREVIATIONS:** **CM:** Chiari Malformation type 2, **EI:** Evans index, **CSF:** Cerebrospinal fluid, **CT:** Computer tomography, **C/S:** Cesarean section, **MMC:** Myelomeningocele, **MRI:** Magnetic resonans imaging, **NSVD:** Normal spontaneous vaginal delivery

Zeliha CULCU GURCAN : 0000-0002-6564-1963 Berkay AYHAN : 0000-0001-9746-1492 Mehmet Emre YILDIRIM : 0000-0001-7039-2706  
Haydar CELIK : 0000-0002-2702-5457 Burak YURUK : 0000-0001-9901-2690 Hakan GURCAN : 0009-0006-4226-3548  
Yavuz ERDEM : 0000-0002-4446-9228 Serdar CENGİZ : 0000-0002-9596-2601 Omer SAHIN : 0000-0001-9689-0068  
Ayhan TEKINER : 0000-0002-3835-2568 Kemal KANTARCI : 0000-0002-4246-6138  
Dilek KAHVECIOGULLARI : 0000-0002-9081-5902 Tuncer TASCIOGLU : 0000-0002-0359-7274

## ■ INTRODUCTION

Myelomeningocele, a common neural tube defect that falls within the spina bifida aperta group, occurs on days 28–30 of pregnancy. The neural placode herniates from the meninges and the damage progressively increases as the neural tissue is exposed to the amnion. Since the neural tube starts closing from the cranial part toward the caudal part, defects that occur earlier are associated with the anterior neuropore, while defects that occur at later stages, such as myelomeningocele, are more caudal (15,21). Global prevalence is approximately 1/1000. Studies from different provinces of Turkey have reported a prevalence of approximately 3 to 5.8/1000 pregnancies for neural tube defects in the country (5). Nowadays, thanks to improved ultrasonography and fetal screening tests, nearly 90% of these defects are prenatally diagnosed and 22% of the pregnancies are terminated (8,15). Most cases are sporadic, but a number of genetic and environmental factors are involved in the etiology (9), including maternal folate deficiency, anticonvulsant therapy, diabetes mellitus and maternal obesity (2,6). There is a strong correlation between the location of lesion and neurological deficit. Usually, as the location of lesion moves caudally, more neurologic function is preserved (16). Although it has been hypothesized that tissues may be exposed to micro trauma during normal spontaneous vaginal delivery (NSVD) and this may further increase damage, studies have found no significant difference between NSVD and cesarean section (C/S) (12). The aim of myelomeningocele treatment is to expose the neural tissue with minimal damage, then create a closed system for cerebrospinal fluid (CSF) circulation and keep neural structures safe (1). Introduction of shunting has been a breakthrough in the treatment of myelomeningocele, because the most serious and mortal pathology associated with MMC is the presence of hydrocephalus (10,17). Although ventricular dimensions are found to be enlarged at birth in 90% of the cases, symptomatic hydrocephalus occurs at a rate of 65% (14). Measurements of head circumference and monitoring fontanelle in the newborn can be misleading; concurrent USG studies have shown that these findings are actually related signs of hydrocephalus, especially in preterm infants (13). That is why some experts advocate simultaneous shunting in case of ventriculomegaly even in the absence of progressive enlargement of the ventricles in order to prevent cognitive impairment that may result from hydrocephalus and to reduce the risk of CSF fistula formation after sac repair.

Others oppose this view, citing shunt infection and related morbidity (11,22). Chiari malformation type 2 (CM) is another condition that affects mortality and morbidity when it accompanies MMC. CM occurs when the cerebellum and brain stem herniate below the foramen magnum (4,23). The extent of herniation correlates with the severity of symptoms. 95% of children diagnosed with CM also have MMC (7).

The present study sought to investigate the association between sac volume in patients who underwent surgery for MMC and the risk of hydrocephalus and Chiari malformation type 2 with a view to identifying the optimum length of follow-up and incorporating new parameters to treatment.

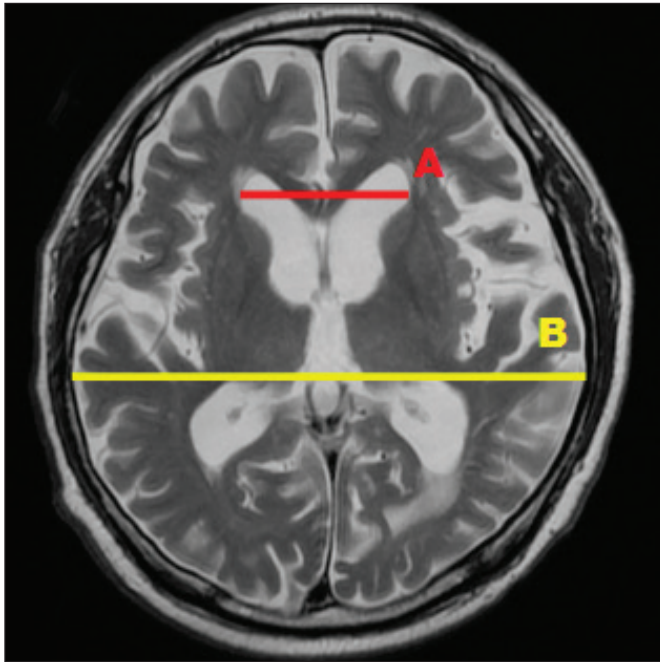
## ■ MATERIAL and METHODS

The study included 81 patients who underwent surgery for MMC in the neurosurgery clinic of SBU Ankara Training and Research Hospital between 2015 and 2022. Approval for the study was received from the Ethics Committee of Ankara Training and Research Hospital, (study no. 1120, E-93471371-514.99). The medical files and radiological examinations of the patients were retrospectively reviewed. Hydrocephalus was identified by using non-contrast brain computed tomography (CT) performed on postnatal day 1 and measurement of Evans Index (EI) yielding a result above 0.3 was interpreted as ventriculomegaly (Figure 1). Patients' MMC sac volumes were measured approximately through pre-operative spinal MRIs using the formula A (anterior-posterior diameter) x B (medial-lateral diameter) x C (superior-inferior diameter) x 0.52. The presence of Chiari malformation and the extent of herniation were also measured using MRI.

The variables were checked for normality of distribution using visual methods (histogram and probability plots) and analytical methods (Kolmogorov-Smirnov test). Descriptive analyses were presented using mean and standard deviation for normally distributed variables and using median and interquartile range for non-normally distributed variables. Nominal and ordinal variables were expressed using frequency tables. Comparisons between groups were performed using Student's t-test for normally distributed variable and Mann Whitney U test for non-normally distributed variables. The relationship between non-normally distributed continuous variables was analyzed using Spearman's rank correlation coefficient. Since the EI value was found to be normally distributed, this parameter was compared across classes of lower extremity mobility (mobile, hypoactive and paraplegic) through one-way analysis of variance test. Homogeneity of variances was evaluated using Levene's test. When there was a significant difference between groups, pair wise post hoc comparisons were performed using Tamhane's T2 test. Frequency of categorical variables was presented using cross-tabulations. Analysis of whether or not groups differed in terms of frequency was presented using chi-square test, Fisher's exact test (when values in cells did not meet the assumptions of the chi-square test) or Monte Carlo Pearson's chi-square test depending on relevance. Further comparisons using post-hoc analysis was processed with Bonferroni correction. P values below 0.05 in the SPSS21 program were considered statistically significant.

## ■ RESULTS

Of the 81 patients included in the study, 41 (50.6%) were boys and 40 (49.4%) were girls. Of the total, 24 (29.6%) of the patients had a gestational age of less than 37 weeks while 57 (70.4%) had a gestational age of 37 weeks or above. The median gestational age was 38 weeks and the median birth weight was 3,040 grams. The method of delivery was cesarean section (C/S) in 57 (70.4%) patients and NSVD in 24 (29.6%) patients. The mean maternal age was  $28.25 \pm 6.35$  years and 29 mothers were outside the age range of 20 to 35 years. The median head circumference of the infants was 36 cm.



**Figure 1:** Evans Index: A/B (3).

The location of the sac was lumbosacral in 46 (56.8%) patients, sacral in 14 (17.3%) patients, lumbar in 14 (17.2%) patients, thoracolumbar in 5 (6.2%) patients and thoracic in 2 (2.5%) patients. Analysis of the relationship between defect location and lower extremity muscle strength yielded Monte Carlo Pearson chi-square =28.187,  $p=0.001$ . In other words, there was a statistically significant relationship between lower extremity muscle strength and sac location. Post-hoc analyses showed that difference was caused by the group with natural lower extremity mobility. In this group, the most common category was patients whose defect was located at the sacral level.

The mean EI based on brain CT scans performed on postnatal day 1 was  $0.405 \pm 0.146$ . Of the 81 patients, 49 (60.5%) had ventriculomegaly at birth and 32 (39.5%) did not. Of these patients, 48 (59.3%) received shunting and 33 (40.7%) did not require shunting. The median MMC sac volume was  $11,005.28 \text{ mm}^3$ . Analysis of the relationship between the EI and MMC sac volume yielded a value of  $r = 0.622$ ,  $p=0.001$ , indicating a strong positive correlation between the two parameters. Those with larger MMC sac volumes had larger EI values on CT brain imaging performed on postnatal day 1. Of the patients, 28 underwent shunting at the same session as sac repair, i.e., on day 12 on average, while 20 patients exhibited a progressive increase in their EI after sac repair and these patients underwent shunting on day 28 on average. The mean MMC sac volume was  $11,511.214 \text{ mm}^3$  in the 20 patients who developed hydrocephalus subsequently *versus*  $3,066.999709 \text{ mm}^3$  in patients who did not require shunting before or after sac repair. There was no statistically significant correlation between sac volume and the day of intervention in patients who developed hydrocephalus after sac repair.

CM was present in 28 (34.6%) of the patients and absent in 53 (65.4%). The mean sac volume was  $28,297.36 \text{ mm}^3$  in patients with CM *versus*  $7,600.32 \text{ mm}^3$  in patients without CM. Analysis of the relationship between CM and MMC sac volume yielded a Mann-Whitney U value=362.5 and  $p=0.001$ . In other words, the groups had a statistically significant difference in their sac volume depending on the presence or absence of CM. Patients with a larger sac volume were more likely to have CM.

Using brain CT scans performed on postnatal day 1, EI values were compared between those with and without CM; the mean EI value was  $0.54 \pm 0.146$  in those with Chiari Malformation type-2 and  $0.34 \pm 0.087$  in those without CM, with  $t=-6.678$  and  $p=0.001$ . The difference in the mean EI values was statistically significant between patients with and without CM. Patients with CM were more likely to have hydrocephalus.

Comparison of lower extremity muscle strength between patients with and without CM yielded chi-square =17.337,  $p=0.001$ . Further post-hoc analysis showed that this difference was between the paraplegic and mobile group. The proportion of patients who had normal lower extremity mobility was lower among those with CM (21.4) compared to those without CM (62.3). Post-hoc analyses were performed with pair wise comparisons and values below the type-1 error ( $0.05/3=0.016$ ) after Bonferroni correction were considered significant. In other words, the presence of CM is associated with a greater likelihood of motor loss in the lower extremities.

## ■ DISCUSSION

Myelomeningocele, one of the most severe congenital diseases that are compatible with life, is still common worldwide, with 50% of these patients dying during intrauterine life or at birth (20). Although studies have showed that it predominantly affects females, our study found an approximately equal sex distribution. The median head circumference of the patients was 36 cm in the present study and was reported to be  $35.8 \pm 3.8 \text{ cm}$  by Oncel et al. (20). During initial examination, the anterior fontanelle of 26 (32%) infants was found to be tense.

Maternal age may be a risk factor for myelomeningocele; the likelihood of having a baby with myelomeningocele has been reported to be 5.6 per 1000 live births in mothers under 20 years of age and over 35 years of age (3,18). In the present study, the youngest mother was 17 years old and the oldest mother was 41 years old, with a mean maternal age of  $28.25 \pm 6.35$  years. 29 mothers were outside the age range 20 to 35 years.

The level of the sac was lumbosacral in 46 (56.8%) patients, sacral in 14 (17.3%) patients, lumbar in 14 (17.2%) patients, thoracolumbar in 5 (6.2%) patients and thoracic in 2 (2.5%) patients. Analysis of the relationship between defect location and lower extremity muscle strength yielded a statistically significant result. The difference was caused by the group with natural lower extremity mobility. In this group, the most common category was patients whose defect was located at the sacral level. All children with lesions located at the thoracic level were paraplegic. This result is in line with Noetzel's study;



as the location of lesion progresses toward the caudal part, motor muscle strength is affected less (18).

Although the effect of method of delivery on mortality has not been clearly proven, recent studies suggest that 69%–80% of children with MMC are delivered through C/S (13). In the present study, 57 (70.4%) of the patients were delivered via C/S and 24 (29.6%) via NSVM.

Radiologic examinations in myelomeningocele patients detect an associated ventriculomegaly at a rate as high as 90%. Brain CT scan performed on postnatal day 1 for the 81 patients in the present study revealed a mean EI of  $0.405 \pm 0.146$  and ventriculomegaly was detected in 49 of them. Conversely, 20 patients exhibited a progressive increase in their ventricular dimensions within the first 2 months after myelomeningocele surgery and these patients required a second surgery for shunting. A study of 10,627 patients conducted in 2019 by Mc Carthy et al. reported that 57%–86% of patients developed hydrocephalus after defect repair (13). When this was analyzed in relation to sac volumes before defect repair, the mean MMC sac volume was found to be  $11,511.214 \text{ mm}^3$  among the 20 patients who developed hydrocephalus after the first procedure *versus*  $3,066.999709 \text{ mm}^3$  among patients who did not require shunting before or after sac repair. In other words, those with a larger sac volume have an increased risk of developing hydrocephalus after a repair surgery even if initial evaluation does not show any need for shunting. This suggests that the primary problem is CSF malabsorption and that the volume of CSF produced remains actually the same. There was no significant correlation between sac volume and the day of shunting in patients who developed hydrocephalus after repair surgery. In the case of CM, which is another comorbid condition, it is hypothesized that tonsils that migrate down ward cause a relative obstruction in the CSF circulation pathway. That is why it has been reported that 90% of patients with both myelomeningocele and CM have hydrocephalus and 80%–86% of them require shunting (19). In the present study, 28 (34.6%) of the patients had CM and the mean EI of these patients on postnatal day 1 was  $0.54 \pm 0.146$  *versus*  $0.34 \pm 0.087$  in those without CM. Of these 28 patients with CM, 26 required shunting during the first surgery and two of them required shunting during a second procedure after sac repair. Although it has been reported that 14 to 20% of children with myelomeningocele who also have CM manifest symptoms during infancy and early childhood, only one of the patients in our study underwent decompressive surgery and this happened at the age of 4 years.

### Limitations

Sac volume in the present study was measured using the formula  $AXBXCX0.52$ , which provides approximate values. The syringomyelia criterion caused statistical deviations and could not be included in the parameters as it was not detected in sufficient numbers.

The intention was to evaluate the patients using the Spina Bifida Neurological Scale, but this was not possible due to the small number of patients that could be followed up to the age of toilet training.

Studies conducted over a longer period of time with a larger number of patients could provide more precise data and can incorporate CSF flow MRI to determine the correlation between sac volume and the numerical value of partial obstruction in the presence of CM.

## CONCLUSION

Myelomeningocele is a disease that is compatible with life but is associated with high morbidity due to its own pathophysiology and related comorbidities. Its progression can however be prevented through a multidisciplinary approach.

Although different hypotheses have been put forward concerning the etiology of hydrocephalus, the most common condition affecting mortality and morbidity in myelomeningocele patients, it can be caused by obstruction in the CSF circulation pathway, defects in CSF absorption, irregularities in the distribution of CSF volume and the presence of many other pathologies that have not yet been elucidated.

Treatment planning and follow-up process of the patients is lengthy and requires dedication. The results of the present study showed that patients with a large sac volume have a high risk of developing hydrocephalus before or after sac repair, and this risk increases further in the presence of CM.

Against this background, we believe that patients with a relatively larger sac volume should undergo a longer period of follow-up, scheduled at more frequent intervals.

### Declarations

**Funding:** We certify that this manuscript is not sponsored directly or indirectly by a pharmaceutical company, equipment manufacturer, public relations firm, or any other commercial entity. Moreover, I certify that neither any immediate family member nor I currently have a financial interest in, or arrangement with, any organization that may have direct interest in the subject matter of this article, except as may be disclosed in an attachment to this statement.

**Availability of data and materials:** All data generated during this study are included in this published article.

**Disclosure:** The authors declare that they have no competing interest.

### AUTHORSHIP CONTRIBUTION

Study conception and design: ZCG, KK

Data collection: BA, BY, SC

Analysis and interpretation of results: HC, OS

Draft manuscript preparation: YE, DK

Critical revision of the article: TT, HG

Other (study supervision, fundings, materials, etc.): MEY, AT

All authors (ZCG, HC, YE, AT, DK, BA, BY, SC, KK, TT, MEY, HG, OS) reviewed the results and approved the final version of the manuscript.

## ■ REFERENCES

1. Akalan N: Myelomeningocele (open spina bifida) - surgical management. *Adv Tech Stand Neurosurg* 37:113-141, 2011. [http://doi.org/10.1007/978-3-7091-0673-0\\_5](http://doi.org/10.1007/978-3-7091-0673-0_5)
2. Bell WO, Sumner TE, Volberg FM: The significance of ventriculomegaly in the newborn with myelodysplasia. In: Matsumoto S, Sato K, Tamaki N, Oi S, (eds). *Annual Review of Hydrocephalus*. Berlin, Heidelberg: Springer, 1990. [http://doi.org/10.1007/978-3-662-11152-9\\_84](http://doi.org/10.1007/978-3-662-11152-9_84)
3. Ben-Sira L, Garel C, Malinger G, Constantini S: Prenatal diagnosis of spinal dysraphism. *Childs Nerv Syst* 29:1541-1552, 2013. <http://doi.org/10.1007/s00381-013-2178-5>
4. Blencowe H, Kancharla V, Moorathie S, Darlison MW, Modell B: Estimates of global and regional prevalence of neural tube defects for 2015: A systematic analysis. *Ann NY Acad Sci* 1414:31-46, 2018. <http://doi.org/10.1111/nyas.13548>
5. Buyukseker M, Yilmaz OH, Yilmaz FM: Nöral tüp defekti risk faktörü olarak çevresel ve mesleki toksik madde maruziyeti. *JGON* 14:82-86, 2017
6. Copp AJ, Adzick NS, Chitty LS, Fletcher JM, Holmbeck GN, Shaw GM: Spina bifida. *Nat Rev Dis Primers* 1:15007, 2015. <http://doi.org/10.1038/nrdp.2015.7>
7. De Freitas GL, De Sena RR, E Silva JCF, Faleiros F: The reality of children and adolescents with meningomyelocele and their families, in the city of Belo Horizonte and its metropolitan area, Brazil. *Health* 8:559-566, 2016. <http://doi.org/10.4236/health.2016.86059>
8. Istemen I, Arslan A, Olguner SK, Acik V, Okten AI, Babaoglan M: Shunt timing in meningomyelocele and clinical results: Analysis of 80 cases. *Childs Nerv Syst* 37:107-113, 2021. <http://doi.org/10.1007/s00381-020-04786-1>
9. Jentink J, Loane MA, Dolk H, Barisic I: Valproic acid monotherapy in pregnancy and major congenital malformations. *New England J Med* 362:2185-2193, 2010
10. Liptak GS, Dosa NP: Myelomeningocele. *Pediatr Rev* 31:443-450, 2010. <http://doi.org/10.1542/pir.31-11-443>
11. Machado HR, Santos De Oliveira R: Simultaneous repair of myelomeningocele and shunt insertion. *Childs Nerv Syst* 20:107-109, 2004. <http://doi.org/10.1007/s00381-003-0853-7>
12. Mattogno PP, Massimi L, Tamburrini G, Frassanito P, Di Rocco C, Caldarelli M: Myelomeningocele repair: Surgical management based on a 30-year experience. In: Visocchi M, Mehdorn HM, Katayama Y, Von Wild KRH, (eds). *Trends in Reconstructive Neurosurgery*. Cham: Springer, 2017:143-148, [http://doi.org/10.1007/978-3-319-39546-3\\_22](http://doi.org/10.1007/978-3-319-39546-3_22)
13. McCarthy DJ, Sheinberg DL, Luther E, McCrea HJ: Myelomeningocele-associated hydrocephalus: Nationwide analysis and systematic review. *Neurosurg Focus* 47:E5, 2019. <http://doi.org/10.3171/2019.7.FOCUS19469>
14. McClugage SG, Oakes WJ: The Chiari I malformation: JNSPG 75<sup>th</sup> anniversary invited review article. *J Neurosurg Pediatr* 24:217-226, 2019. <http://doi.org/10.3171/2019.5.PEDS18382>
15. McLone DG: Spinal dysraphism: Impact of technique and technology on expectations. *Clin Neurosurg* 52:261-264, 2005
16. Merrill DC, Goodwin P, Burson JM, Sato Y, Williamson R, Weiner CP: The optimal route of delivery for fetal meningomyelocele. *Am J Obst Gynecol* 179:235-240, 1998. [http://doi.org/10.1016/S0002-9378\(98\)70278-9](http://doi.org/10.1016/S0002-9378(98)70278-9)
17. Miller PD, Pollack IF, Pang D, Albright AL: Comparison of simultaneous versus delayed ventriculoperitoneal shunt insertion in children undergoing myelomeningocele repair. *J Child Neurol* 11:370-372, 1996. <http://doi.org/10.1177/088307389601100504>
18. Noetzel MJ: Myelomeningocele: Current concepts of management. *Clin Perinatol* 16:311-329, 1989. [http://doi.org/10.1016/S0095-5108\(18\)30634-1](http://doi.org/10.1016/S0095-5108(18)30634-1)
19. Oi S, Matsumoto S: A proposed grading and scoring system for spina bifida: Spina Bifida Neurological Scale (SBNS). *Childs Nerv Syst* 8:337-342, 1992. <http://doi.org/10.1007/BF00296565>
20. Oncel MY, Ozdemir R, Kahilogullari G, Yurttutan S, Erdeve O, Dilmen U: The effect of surgery time on prognosis in newborns with meningomyelocele. *J Korean Neurosurg Soc* 51:359-364, 2012. <http://doi.org/10.3340/jkns.2012.51.6.359>
21. Rankin TM, Wormer BA, Tokin C, Kaoutzanis C, Al Kassis S, Wellons JC, Braun S: Quadruple perforator flaps for primary closure of large myelomeningoceles: An evaluation of the butterfly flap technique. *Ann Plast Surg* 82:S389-S393, 2019. <http://doi.org/10.1097/SAP.0000000000001668>
22. Stark G, Drummond M: Spina bifida as an obstetric problem. *Develop Med Child Neurol* 12:157-160, 1970. <http://doi.org/10.1111/j.1469-8749.1970.tb03020.x>
23. Teo C, Parker EC, Aureli S, Boop FA: The Chiari II malformation: A surgical series. *Pediatr Neurosurg* 27:223-229, 1997. <http://doi.org/10.1159/000121258>