



Analysis of Intracranial Compliance Through Noninvasive Intracranial Pressure Waveforms in Hydrocephalus Patients. A Pilot Study

Raphael BERTANI¹, Stefan KOESTER², Caio PERRET³, Paulo Santa MARIA³, Sérgio BRASIL⁴, Gustavo FRIGIERI⁵, Sávio BATISTA⁶, Nicolas Nunes RABELLO⁴, Ruy MONTEIRO³

¹University of São Paulo, Department of Neurosurgery, SP, Brazil

²Vanderbilt University School of Medicine, Nashville, TN, USA

³Hospital Municipal Miguel Couto, Department of Neurosurgery, Rio de Janeiro, RJ, Brazil

⁴University of São Paulo, Department of Neurology, Division of Neurosurgery, SP, Brazil

⁵University of São Paulo, School of Medicine, Medical Investigation Laboratory 62, SP, Brazil

⁶Federal University of Rio de Janeiro, Faculty of Medicine, Rio de Janeiro, RJ, Brazil

This study has been presented at the 14th Meeting of the Hydrocephalus Society, Hydrocephalus 2022, September 9-12, 2022 in Gothenburg, Sweden.

Corresponding author: Raphael BERTANI ✉ contato@rbertani.com

ABSTRACT

AIM: To assess the changes of intracranial pressure waveforms (ICPW) acquired noninvasively in a set of acute hydrocephalus patients prior to and posterior to interventions.

MATERIAL and METHODS: Patients with clinical and radiological diagnosis of hydrocephalus were evaluated for alterations in ICPW by means of a system that detects cranial micro expansions just before and immediately after interventions. The system quantified the difference between ICPW peaks (P1 and P2), providing the P2/P1 ratio.

RESULTS: Fourteen patients aged from 26 to 73 years old met the inclusion criteria. Hydrocephalus etiologies were normal pressure hydrocephalus, post-traumatic and all patients had an abnormal intracranial compliance waveform, with P2>P1 before the procedure (5 external ventricular drains (EVD) and 9 ventriculoperitoneal shunts (VPS). Immediately after, 75% of the patients changed to a standard pattern with P1>P2.

CONCLUSION: In this exploratory study using a novel noninvasive technique, rapid cerebrospinal fluid drainage by means of EVD and VPS was effectively assessed and had a positive impact on intracranial compliance.

KEYWORDS: Hydrocephalus, Intracranial pressure, Noninvasive, Brain compliance

INTRODUCTION

Hydrocephalus is a common condition resulting from excessive production, insufficient absorption, or blockage of cerebrospinal fluid (CSF) (20,35). The classical radiological presentation is an abnormal enlargement of the cerebral ventricles and may present with or without symptoms related to increased intracranial pressure (ICP) (1,3). Previously thought of as a pediatric condition, it is now recognized to be common among adults as well (18,42).

Infant hydrocephalus, which is mostly obstructive, occurs in approximately 1 in every 1000 births, whereas the prevalence of adult hydrocephalus is variable and not yet clear in the literature (40), but may occur due to various spinal and cranial disorders, such as traumatic injuries and hemorrhages, for example (5).

Currently, the two most common methods of relieving intracranial hypertension caused by hydrocephalus are ventricular shunts, such as the ventriculoperitoneal shunt (VPS), and ex-

Raphael BERTANI : 0000-0001-6546-2634

Stefan KOESTER : 0000-0003-1156-4090

Caio PERRET : 0000-0003-1769-2034

Paulo Santa MARIA : 0000-0002-6373-9537

Sérgio BRASIL : 0000-0003-2397-9947

Gustavo FRIGIERI : 0000-0002-4288-468X

Sávio BATISTA : 0000-0002-6861-0505

Nicolas Nunes RABELLO : 0000-0001-5238-8658

Ruy MONTEIRO : 0000-0003-1775-8670

ternal ventricular drains (EVD) or lumbar drains (31,32). Unfortunately, the main tools available for assessing and diagnosing hydrocephalus are imaging modalities such as magnetic resonance imaging (MRI) and computerized tomography (CT) of the head (20,28), with the disadvantages of low sensitivity in some cases, poor temporary resolution, and brain stiffness (41). Alternatively, another diagnostic option is measuring CSF opening pressure, which requires a lumbar puncture (39).

With improvements in ICP monitoring techniques and understanding, the analysis of ICP waveforms (ICPW) and their correlation to pathological scenarios requiring surgical treatment have made ICPW monitoring a standard of care (4,21,22). Intracranial compliance (ICC) refers to the balance between intracranial volumes, including blood, brain tissue, and CSF, which contributes to the generation of a standardized ICP gradient (24,30,33). Recent studies have indicated that ICPW is a reliable marker of ICC, suggesting that focusing on this parameter may be more important than ICP itself (10,15,23).

Therefore, in the present study, we tested the hypothesis of the analysis of ICPW as valuable indicators for the assessment of hydrocephalus, using a novel noninvasive technique for providing ICPW, previously correlated with the gold standard technique (10,16).

■ MATERIAL and METHODS

Study Design and Population

This single-center, cross-sectional study was conducted in the emergency room, wards, and outpatient clinic of our in-

stitution between 2020 and 2022. The clinical trial study protocol was approved by the local Ethics Committee in 2020 under number 39765120.1.0000.5279. Informed consent was obtained from legally authorized representatives/next of kin of patients before inclusion. This study was performed according to the Standards for Reporting of Diagnostic Accuracy Studies. Patients were recruited based on a previous radiological diagnosis of symptomatic hydrocephalus requiring surgical interventions: EVD or VPS. Patients with incomplete or missing medical records, as well as those who were monitored with the device but not diagnosed with hydrocephalus, were excluded from the study. All patients with missing information or incomplete records were excluded.

Neuromonitoring

Waveform acquisition was performed using an extensometer-type sensor (Figure 1), similar to those used for stress-strain measurements or tensile tests (B4C- Braincare Corp, São Carlos, Brazil). Engineering and technical information has been published elsewhere (2,11). The B4C system detects tiny skull deformations on a micrometric scale caused by dynamic, physiological, or pathological changes in ICP (25). These changes in ICP generate pulse waves similar to those monitored invasively (10,16). The characteristics of ICP waveforms have been defined and characterized in previous studies according to their peaks: P1, related to arterial pressure being transmitted from the vessels of the choroid plexus to the ventricles; P2, related to blood spread through brain parenchyma, and P3, the dicrotic wave, related to the closure of the aortic valve. Under normal conditions, the relations of the peaks in

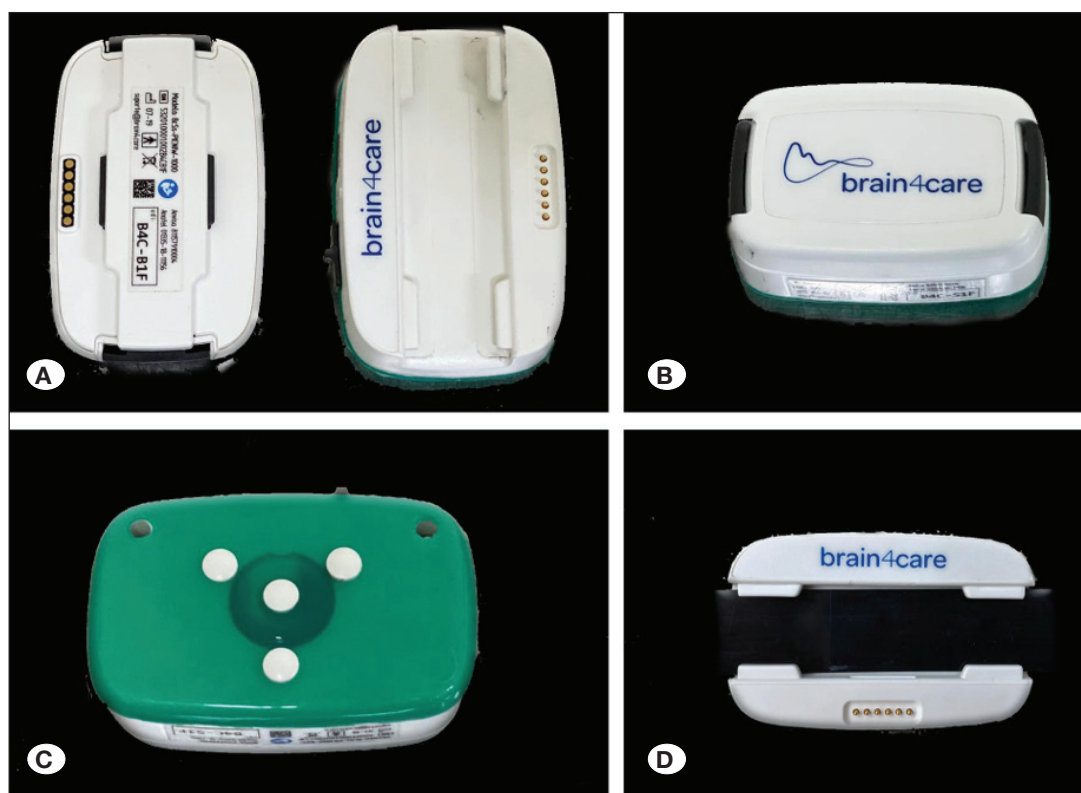

Figure 1: Picture for illustration of the sensor. **A)** On the left, the external battery unit for the sensor, which serves to recharge and extend battery life for prolonged usage, is on the right, the sensor, without a headband attached. **B)** Outer surface (no contact with patients) of external battery unit and sensor, connected. **C)** Inner, soft surface of the sensor, that is in contact with the patient's head. **D)** Sensor unit, with headband, attached.

the waveform are $P1 > P2 > P3$. However, in the case of ICC impairment, P2 becomes of higher amplitude than P1 (27,29,37). B4C waveforms are real-time processed, and the P2/P1 ratio is provided; therefore, an indicator of ICC impairment is provided by this system (6,7,9,36). The device is fixed, and the point of contact with the scalp rests at the front parietal region lateral to the sagittal suture, but this position can be optimized for better patient comfort and signal acquisition if necessary. Fitting to the head with adjustable bands is typically easy and takes approximately 1-5 minutes, depending on the patient.

Routine

Patients were monitored for ICPW for at least 5 minutes, while resting in bed (at zero degrees) with the sensor (Figure 2) before induction of general anesthesia for the surgical procedure (whether EVD, VPS, or valve adjustment) and on the following day post-procedure, to rule out potential effects

of anesthesia on ICC, and therefore, on ICPW (Figure 3). While being monitored, patients were asked to indicate if they experienced any physical discomfort caused by the device.

Data Acquisition and Analysis

The normality of the numerical distribution of the P2/P1 ratio was assessed through a Shapiro-Wilk test. The assessment of the P2/P1 ratio employed an Analysis of Variance for the comparisons of the means before and after the interventions. Both tests were considered to be statistically significant at the 95% significance level. Medcalc software was employed for the statistical analysis and graphic presentation of the results.

RESULTS

A total of 35 adults aged 18 to 73 years, with diverse pathologies previously confirmed through imaging, were

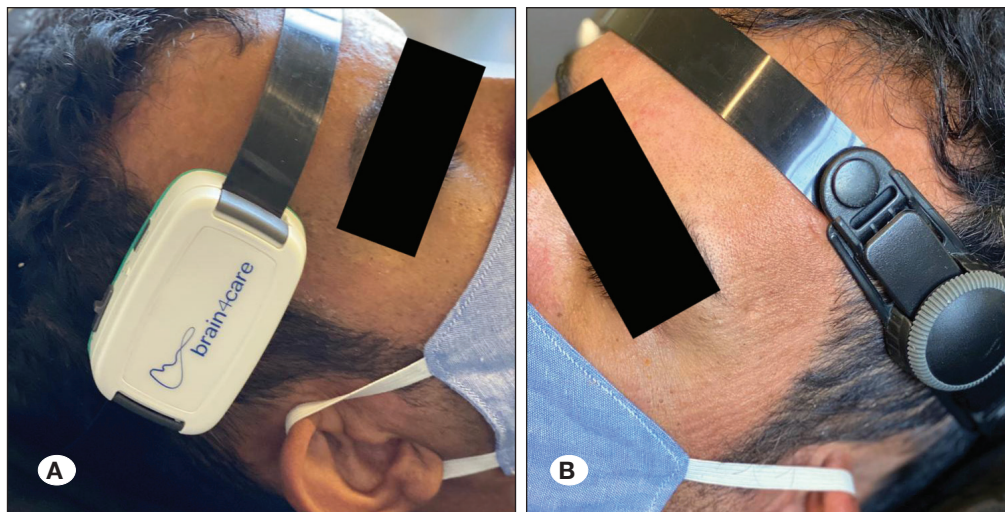


Figure 2: A) External surface of the sensor placed on the temporal area of the head. B) Turnbuckle used to adjust and secure the band on head.

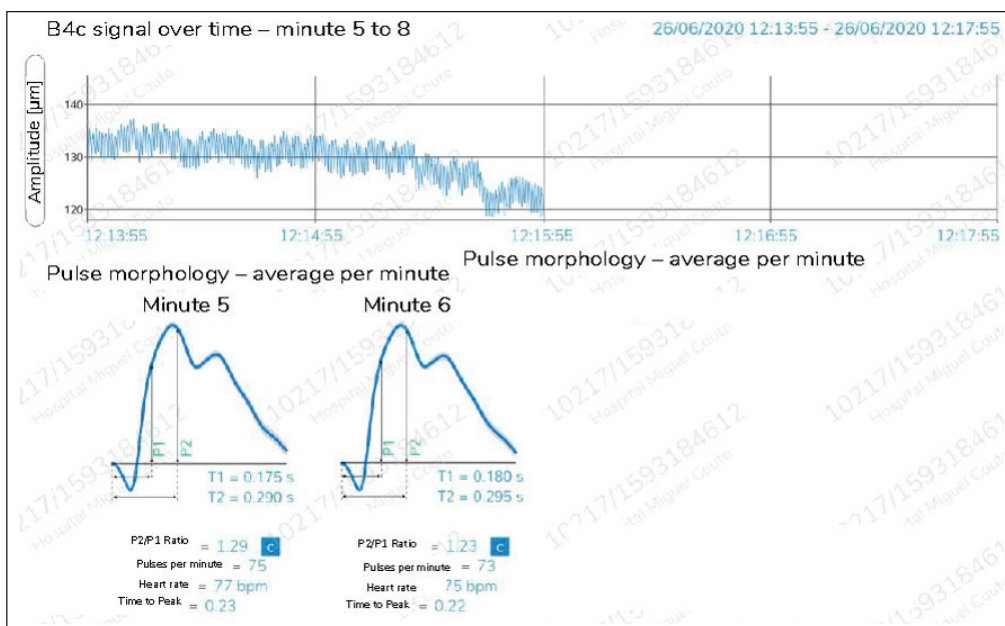


Figure 3: Waveform analysis displayed by the device, on a minute-by-minute basis. The waveform can be seen with P1 and P2 being shown, as well as the P2/P1 ratio calculated and other parameters, such as the Time to Peak (TTP). In this example, the report shows an abnormal waveform as the P2/P1 ratio of 1.29 in minute 6.

included, including hydrocephalus variants such as normal pressure hydrocephalus, idiopathic intracranial hypertension, and different types of brain tumors exerting a mass effect. With the exception of two patients who already had a VPS with an adjustable valve and were monitored before and after adjustment, all patients underwent surgical procedures (lumbar taps, shunts, drainages, or tumor removal), and monitoring was conducted both before (pre) and after (post) the procedure. Out of this total, 14 patients were selected, forming a single group of participants diagnosed with hydrocephalus, presenting symptoms of increased ICP (such as headaches, altered mental status, and/or vomiting), and undergoing either EVD, VPS, or valve adjustment (Table I). Of these patients, 5 underwent EVD, and 9 underwent VPS (including 2 who underwent valve adjustment). To rule out possible effects of anesthesia drugs on ICC, all patients were monitored before anesthesia induction and at least 2 hours after awakening following surgical procedures, while maintaining the same lying down position. All patients self-reported feeling comfortable with the device and did not report any issues to our team during the entire procedure.

Waveform Results

A total of 14 symptomatic patients with a previous radiological diagnosis of hydrocephalus required intervention. Table I presents the patient demographics and individual device measurements. Additionally, measurements from two patients before and after valve adjustments were included for separate descriptive analysis. The operations included four (29%) with an external ventricular drain and ten (71%)

with a ventriculoperitoneal shunt. Before the procedures, all 14 patients exhibited abnormal waveforms, with $P2 > P1$. Following the procedure, 11 (79%) patients showed a $P1 > P2$ pattern, indicating a more appropriate waveform. The mean postoperative $P2/P1$ ratio was significantly lower compared to the preoperative ratio (0.89 ± 0.21 vs 1.62 ± 0.56 , respectively) (Figure 4). This difference was statistically significant using both the t-test and Mood’s Median test ($p < 0.001$). Treatment resulted in a mean relative reduction in the $P2/P1$ ratio of 45.1%. Among the four patients receiving an EVD, a relative reduction of 48.9% was achieved, with a pre-procedure $P2/P1$ ratio of 1.52 ± 0.39 and a post-procedure ratio of 0.78 ± 0.12 ($p = 0.01$). For the ten patients receiving a VPS, a relative reduction of 43.7% was achieved, with a pre-procedure $P2/P1$ ratio of 1.66 ± 0.63 and a post-procedure ratio of 0.93 ± 0.22 ($p = 0.003$). Notably, the two patients who underwent valve adjustment procedures had a lower relative reduction at 25.0%. In this cohort, the pre-procedure $P2/P1$ ratio was higher at 1.26 ± 0.08 compared to the post-procedure ratio of 0.94 ± 0.34 ($p = 0.32$).

DISCUSSION

Elevation in ICP and subsequent reduction in ICC lead to discernible alterations in the waveform, marked by distinct characteristic peaks. Notably, a prominent shift is observed in the $P2$ peak, exhibiting an augmented amplitude relative to $P1$. Consequently, this dynamic yields a heightened $P2/P1$ ratio, underscoring the significance of these changes in reflecting alterations in cerebral physiology (13,19). In other studies, a progressive increase in the $P2$ peak over $P1$ has consistently

Table I: Clinical Assessment of Hydrocephalus Patients

N	Age	Sex	Initial Clinical Symptoms	Pre-Op P2/P1 ratio	Post-Op P2/P1 ratio	Reduction of Ratio	Percentage (%)	Procedure
1	49	M	H, PRH	1.5	1.18	0.23	31	VPS
2	69	M	D, E	1.68	0.6	1.08	64	VPS
3	37	M	D, E, H	1.6	0.86	0.8	46	VPS
4	78	F	D, E	1.54	0.84	0.7	45	VPS
5	18	M	H	1.37	0.92	0.45	33	EVD
6	26	F	D	2	0.65	1.35	67.5	EVD
7	29	F	E, H	1.2	0.7	0.5	41	VPS
8	59	F	D, H	1.3	0.8	0.5	33	VPS
9	73	M	H	1.5	1.2	0.3	31	VPS
10	64	M	H	1.3	0.9	0.4	30	VPS
11	43	F	D, E	1.6	0.84	0.84	47.5	EVD
12	57	F	D, E, H	3.4	0.99	2.41	70	VPS
13	58	M	D, E, H	1.1	0.7	0.4	36	EVD
14	55	M	D	1.54	1.25	0.29	19	VPS

M: Male, **F:** Female, **H:** Headache, **PRH:** Previous right hemiparesis, **D:** Drowsiness, **E:** Emesis; **VPS:** Ventriculoperitoneal shunting, **EVD:** External ventricular drainages.

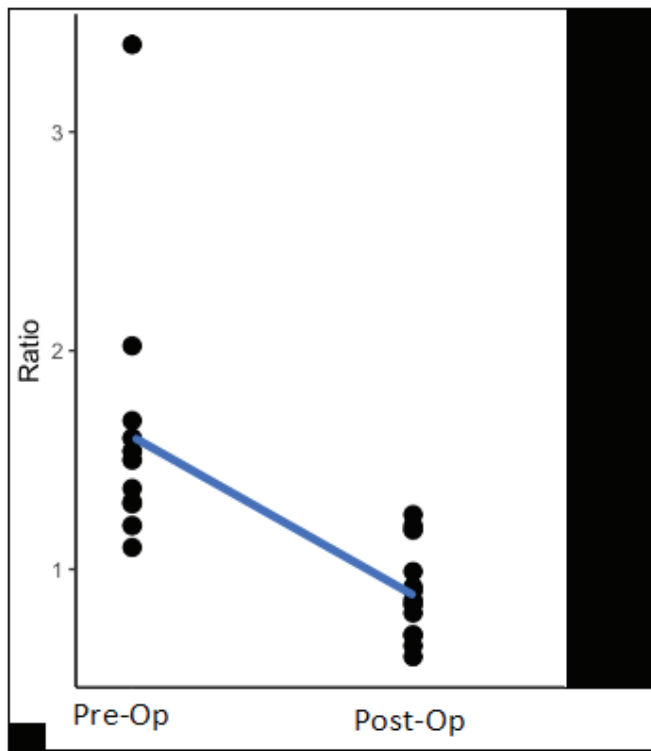


Figure 4: A scatter plot of P2/P1 ratio of pre and post-operative patients through an ICP noninvasive measurement.

emerged as a predictor of reduced brain compliance and heightened ICP. This trend has been supported by a consensus cutoff ratio of 0.8 for forecasting ICP elevation with invasive monitoring (14). Moreover, research has demonstrated a decline in P2 values following normalization of ICP in critical patients (17,26), mirroring the findings observed in our study both pre- and post-hydrocephalus treatment.

The methodology employed in our study has showcased robust nonlinear correlations between its waveforms and the gold standard ICP measurement, as evidenced in experimental setups (12) and among neurocritical patients (10,16), including waveform-derived compliance indexes (21). Furthermore, our findings indicate that neurocritical patients experiencing intracranial hypertension and poorer outcomes exhibit notably elevated noninvasive ICPW parameters (7).

The utilization of a noninvasive device capable of reliably monitoring ICP through the analysis of ICPW holds promise for reducing reliance on potentially harmful imaging techniques such as CT scans. This could consequently mitigate the need for other diagnostic modalities like MRI, thereby curbing overall healthcare costs. For instance, a case-controlled study conducted by Shao et al. revealed a significant correlation between exposure to radiation from CT scans and heightened risks of thyroid cancer and leukemia (37). While efforts have been undertaken to minimize radiation exposure through the use of low-dose CT scans (27), even these reduced doses have been associated with an elevated risk of childhood leukemia (29). Notably, over the past two decades, there has

been a notable and, in some cases, rapid escalation in the utilization of diagnostic imaging scans.

Between 1996 and 2006, research conducted by Smith-Bindman et al. revealed a notable doubling in the number of CT and MRI scans performed on the central nervous system, accompanied by a corresponding increase in spending on imaging services (38). Introducing a bedside, dynamic, and easily repeatable technique devoid of harm potential holds promise for alleviating the impact of radiation exposure and the economic strain associated with imaging in the follow-up of hydrocephalus patients. Moreover, patients lacking formal indications for invasive ICP monitoring, such as those with hydrocephalus, stand to benefit from ICPW monitoring, given the diverse array of conditions that can lead to neurological impairment (8,11,34). An elevated P2/P1 ratio may indicate deterioration in the patient's condition, warranting a reassessment of the current therapeutic approach, while its normalization could signal patient recovery, reduction of brain edema, and consequently, restoration of homeostasis.

Implementing such a technique could potentially enhance the timing of shunt replacement or revision, leading to improved outcomes for patients with hydrocephalus. Although there is no consensus regarding the ideal timing for shunt implantation, research by Kowalski et al. demonstrated that earlier shunt placement in posttraumatic hydrocephalus correlated with more favorable outcomes (23). In scenarios involving suspicion of hydrocephalus or during follow-up, the ability to promptly monitor patients and facilitate referral to a neurosurgery facility could prove invaluable for optimizing timing strategies.

Limitations

It's important to acknowledge several limitations inherent in both the present technique and our study. Firstly, the sensor's susceptibility to motion artifacts poses a significant challenge, particularly in agitated, non-compliant, and pediatric patients. Monitoring becomes impractical if a patient cannot remain still for at least 5 minutes. Additionally, the sensor measures physiological changes in the skull in micrometers, rendering it unable to directly acquire ICP values. Instead, it provides visualization of ICP waveforms with automated calculations of parameters such as the P2/P1 ratio and TTP. While knowledge of ICP waveforms isn't novel, integrating these derived parameters into daily clinical practice may necessitate considerable adaptation from nursing and medical staff.

Furthermore, it's essential to recognize that our study involved a small and exploratory cohort of hydrocephalus patients. Subsequent monitoring sessions during follow-up consultations would offer valuable prognostic insights and enable the assessment of therapy success and the utility of this tool in decision-making processes.

CONCLUSION

Abnormal patterns of intracranial pressure waveform were noninvasively demonstrated, indicating intracranial compliance impairment among hydrocephalus patients. A significant

trend toward normalization of ICPW parameters was observed after standard procedures, which points to the promise of this technique in the assessment of hydrocephalus. Further larger studies in this regard are warranted.

Declarations

Funding: We report that, although we did not receive funding from brain4care®, the developer of the novel non-invasive device, they did provide us with all the equipment necessary for our research.

Availability of data and materials: Data and materials are available at Hospital of Miguel Couto archives.

Disclosure: Gustavo Frigieri is scientific director for brain4care®.

Dr. Sergio Brasil and Dr. Raphael Bertani are consultants for brain4care®.

AUTHORSHIP CONTRIBUTION

Study conception and design: RB, GF, SB

Data collection: RB, CP, PSM

Analysis and interpretation of results: SB, SK

Draft manuscript preparation: RB, SK, SB

Critical revision of the article: NNR, RM

Other (study supervision, fundings, materials, etc...): GF, SB, RM

All authors (RB, SK, CP, PSM, SB, GF, SB, NNR, RM) reviewed the results and approved the final version of the manuscript.

REFERENCES

- Adams RD, Fisher CM, Hakim S, Ojemann RG, Sweet WH: Symptomatic occult hydrocephalus with "normal" cerebrospinal-fluid pressure. A treatable syndrome. *N Engl J Med* 273:117-126, 1965. <https://doi.org/10.1056/NEJM196507152730301>
- Andrade RAP, Oshiro HE, Miyazaki CK, Hayashi CY, Morais MA, Brunelli R, Carmo JP: A nanometer resolution wearable wireless medical device for non invasive intracranial pressure monitoring. *IEEE Sens J* 21:22270, 2021. <https://doi.org/10.1109/JSEN.2021.3090648>
- Aschoff A, Kremer P, Hashemi B, Kunze S: The scientific history of hydrocephalus and its treatment. *Neurosurg Rev* 22:67-93, 1999. <https://doi.org/10.1007/s101430050035>
- Ballestero MFM, Frigieri G, Cabella BCT, de Oliveira SM, de Oliveira RS: Prediction of intracranial hypertension through noninvasive intracranial pressure waveform analysis in pediatric hydrocephalus. *Childs Nerv Syst* 33:1517-1524, 2017. <https://doi.org/10.1007/s00381-017-3475-1>
- Bramall AN, Anton ES, Kahle KT, Fecci PE: Navigating the ventricles: Novel insights into the pathogenesis of hydrocephalus. *EBioMedicine* 78:103931, 2022. <https://doi.org/10.1016/j.ebiom.2022.103931>
- Brasil S: Intracranial pressure pulse morphology: The missing link? *Intensive Care Med* 48:1667-1669, 2022. <https://doi.org/10.1007/s00134-022-06855-2>
- Brasil S, Frigieri G, Taccone FS, Robba C, Solla DJF, de Carvalho Nogueira R, Yoshikawa MH, Teixeira MJ, Malbouisson LMS, Paiva WS: Noninvasive intracranial pressure waveforms for estimation of intracranial hypertension and outcome prediction in acute brain-injured patients. *J Clin Monit Comput* 37:753-760, 2023. <https://doi.org/10.1007/s10877-022-00941-y>
- Brasil S, Renck AC, Taccone FS, Fontoura Solla DJ, Tomazini BM, Wayhs SY, Fonseca S, Bassi E, Lucena B, De Carvalho Nogueira R, Paiva W, Teixeira MJ, Frade Costa EM, Sá Malbouisson LM: Obesity and its implications on cerebral circulation and intracranial compliance in severe COVID-19. *Obes Sci Pract* 7:751-759, 2021. <https://doi.org/10.1002/osp4.534>
- Brasil S, Solla DJF, Nogueira RdC, Jacobsen Teixeira M, Malbouisson LMS, Paiva WS: Intracranial compliance assessed by intracranial pressure pulse waveform. *Brain Sci* 11:971, 2021. <https://doi.org/10.3390/brainsci11080971>
- Brasil S, Solla DJF, Nogueira RdC, Teixeira MJ, Malbouisson LMS, Paiva WdS: A novel noninvasive technique for intracranial pressure waveform monitoring in critical care. *J Pers Med* 11:1302, 2021. <https://doi.org/10.3390/jpm11121302>
- Brasil S, Taccone F, Wayhs S, Tomazini B, Annoni F, Fonseca S, Bassi E, Lucena B, Nogueira RC, De-Lima-Oliveira M, Bor-Seng-Shu E, Paiva W, Turgeon AF, Jacobsen Teixeira M, Malbouisson LMS: Cerebral hemodynamics and intracranial compliance impairment in critically ill Covid-19 patients: A pilot study. *Brain Sci* 11:874, 2021. <https://doi.org/10.3390/brainsci11070874>
- Cabella B, Vilela GH, Mascarenhas S, Czosnyka M, Smielewski P, Dias C, Cardim DA, Wang CC, Mascarenhas P, Andrade R, Tanaka K, Lopes LS, Colli BO: Validation of a new noninvasive intracranial pressure monitoring method by direct comparison with an invasive technique. *Acta Neurochir Suppl* 122:93-96, 2016. https://doi.org/10.1007/978-3-319-22533-3_18
- Cardoso ER, Rowan JO, Galbraith S: Analysis of the cerebrospinal fluid pulse wave in intracranial pressure. *J Neurosurg* 59:817-821, 1983. <https://doi.org/10.3171/jns.1983.59.5.0817>
- Contant CF Jr, Robertson CS, Crouch J, Gopinath SP, Narayan RK, Grossman RG: Intracranial pressure waveform indices in transient and refractory intracranial hypertension. *J Neurosci Methods* 57:15-25, 1995. [https://doi.org/10.1016/0165-0270\(94\)00106-Q](https://doi.org/10.1016/0165-0270(94)00106-Q)
- Czosnyka M, Czosnyka Z: Origin of intracranial pressure pulse waveform. *Acta Neurochir (Wien)* 162:1815-1817, 2020. <https://doi.org/10.1007/s00701-020-04424-4>
- de Moraes FM, Rocha E, Barros FCD, Freitas FGR, Miranda M, Valiente RA, de Andrade JBC, Neto FEAC, Silva GS: Waveform morphology as a surrogate for ICP monitoring: A comparison between an invasive and a noninvasive method. *Neurocrit Care* 37:219-227, 2022. <https://doi.org/10.1007/s12028-022-01477-4>
- Dias C, Maia I, Cerejo A, Varsos G, Smielewski P, Paiva JA, Czosnyka M: Pressures, flow, and brain oxygenation during plateau waves of intracranial pressure. *Neurocrit Care* 21:124-132, 2014. <https://doi.org/10.1007/s12028-013-9918-y>
- Edwards RJ, Dombrowski SM, Luciano MG, Pople IK: Chronic hydrocephalus in adults. *Brain Pathol* 14:325-336, 2004. <https://doi.org/10.1111/j.1750-3639.2004.tb00072.x>
- Fan JY, Kirkness C, Vicini P, Burr R, Mitchell P: Intracranial pressure waveform morphology and intracranial adaptive capacity. *Am J Crit Care* 17:545-554, 2008. <https://doi.org/10.4037/ajcc2008.17.6.545>

20. Frank E, Buonocore M, Hein L: Magnetic resonance imaging analysis of extremely slow flow in a model shunt system. *Childs Nerv Syst* 8:73-75, 1992. <https://doi.org/10.1007/BF00298443>
21. Hassett CE, Uysal SP, Butler R, Moore NZ, Cardim D, Gomes JA: Assessment of cerebral autoregulation using invasive and noninvasive methods of intracranial pressure monitoring. *Neurocrit Care* 38:591-599, 2023. <https://doi.org/10.1007/s12028-022-01585-1>
22. Kazimierska A, Kasprowicz M, Czosnyka M, Placek MM, Baledent O, Smielewski P, Czosnyka Z: Compliance of the cerebrospinal space: Comparison of three methods. *Acta Neurochir (Wien)* 163:1979-1989, 2021. <https://doi.org/10.1007/s00701-021-04834-y>
23. Kowalski RG, Weintraub AH, Rubin BA, Gerber DJ, Olsen AJ: Impact of timing of ventriculoperitoneal shunt placement on outcome in posttraumatic hydrocephalus. *J Neurosurg* 130:406-417, 2018. <https://doi.org/10.3171/2017.7.JNS17555>
24. Langfitt TW: Increased intracranial pressure. *Clin Neurosurg* 16:436-471, 1969. https://doi.org/10.1093/neurosurgery/16.CN_suppl_1.436
25. Mascarenhas S, Vilela GH, Carlotti C, Damiano LE, Seluque W, Colli B, Tanaka K, Wang CC, Nonaka KO: The new ICP minimally invasive method shows that the Monro-Kellie doctrine is not valid. *Acta Neurochir Suppl* 114:117-120, 2012. https://doi.org/10.1007/978-3-7091-0956-4_21
26. Matsumoto T, Nagai H, Kasuga Y, Kamiya K: Changes in intracranial pressure (ICP) pulse wave following hydrocephalus. *Acta Neurochir (Wien)* 82:50-56, 1986. <https://doi.org/10.1007/BF01456319>
27. Mettler FA Jr, Huda W, Yoshizumi TT, Mahesh M: Effective doses in radiology and diagnostic nuclear medicine: A catalog. *Radiology* 248:254-263, 2008. <https://doi.org/10.1148/radiol.2481071451>
28. Miskin N, Patel H, Franceschi AM, Ades-Aron B, Le A, Damadian BE, Stanton C, Serulle Y, Golomb J, Gonen O, Rusinek H, George AE; Alzheimer's Disease Neuroimaging Initiative. Diagnosis of normal-pressure hydrocephalus: Use of traditional measures in the era of volumetric MR Imaging. *Radiology* 285:197-205, 2017. <https://doi.org/10.1148/radiol.2017161216>
29. Nikkila A, Raitanen J, Lohi O, Auvinen A: Radiation exposure from computerized tomography and risk of childhood leukemia: Finnish register-based case-control study of childhood leukemia (FRECCLE). *Haematologica* 105:849-850, 2020. <https://doi.org/10.3324/haematol.2019.245704>
30. Nucci CG, De Bonis P, Mangiola A, Santini P, Sciandrone M, Risi A, Anile C: Intracranial pressure wave morphological classification: Automated analysis and clinical validation. *Acta Neurochir (Wien)* 158:581-588, 2016. <https://doi.org/10.1007/s00701-015-2672-5>
31. Patwardhan RV, Nanda A: Implanted ventricular shunts in the United States: The billion-dollar-a-year cost of hydrocephalus treatment. *Neurosurgery* 56:139-144; discussion 144-145, 2005. <https://doi.org/10.1227/01.NEU.0000146206.40375.41>
32. Pople IK: Hydrocephalus and shunts: what the neurologist should know. *J Neurol Neurosurg Psychiatry* 73 Suppl 1:i17-22, 2002
33. Rabelo NN, da Silva Brito J, da Silva JS, de Souza NB, Coelho G, Brasil S, Frigieri G: The historic evolution of intracranial pressure and cerebrospinal fluid pulse pressure concepts: Two centuries of challenges. *Surg Neurol Int* 12:274, 2021. https://doi.org/10.25259/SNI_53_2021
34. Rickli C, Cosmoski LD, Dos Santos FA, Frigieri GH, Rabelo NN, Schuinski AM, Mascarenhas S, Velloso JCR: Use of non-invasive intracranial pressure pulse waveform to monitor patients with End-Stage Renal Disease (ESRD). *PLoS One* 16:e0240570, 2021. <https://doi.org/10.1371/journal.pone.0240570>
35. Riva-Cambrin J, Kestle JR, Holubkov R, Butler J, Kulkarni AV, Drake J, Whitehead WE, Wellons JC 3rd, Shannon CN, Tamber MS, Limbrick DD Jr, Rozzelle C, Browd SR, Simon TD: Risk factors for shunt malfunction in pediatric hydrocephalus: A multicenter prospective cohort study. *J Neurosurg Pediatr* 17:382-390, 2016. <https://doi.org/10.3171/2015.6.PEDS14670>
36. Rubiano AM, Figaji A, Hawryluk GW: Intracranial pressure management: Moving beyond guidelines. *Curr Opin Crit Care* 28:101-110, 2022. <https://doi.org/10.1097/MCC.0000000000000920>
37. Shao YH, Tsai K, Kim S, Wu YJ, Demissie K: Exposure to tomographic scans and cancer risks. *JNCI Cancer Spectr* 4:pkz072, 2020. <https://doi.org/10.1093/jncics/pkz072>
38. Smith-Bindman R, Miglioretti DL, Larson EB: Rising use of diagnostic medical imaging in a large integrated health system. *Health Aff (Millwood)* 27:1491-502, 2008. <https://doi.org/10.1377/hlthaff.27.6.1491>
39. Thakur SK, Serulle Y, Miskin NP, Rusinek H, Golomb J, George AE: Lumbar puncture test in normal pressure hydrocephalus: Does the volume of CSF removed affect the response to tap? *AJNR Am J Neuroradiol* 38:1456-1460, 2017. <https://doi.org/10.3174/ajnr.A5187>
40. Tully HM, Dobyns WB: Infantile hydrocephalus: A review of epidemiology, classification and causes. *Eur J Med Genet* 57:359-368, 2014. <https://doi.org/10.1016/j.ejmg.2014.06.002>
41. Wagshul ME, McAllister JP, Limbrick DD Jr, Yang S, Mowrey W, Goodrich JT, Meiri A, Morales DM, Kobets A, Abbott R: MR Elastography demonstrates reduced white matter shear stiffness in early-onset hydrocephalus. *Neuroimage Clin* 30:102579, 2021. <https://doi.org/10.1016/j.nicl.2021.102579>
42. Williams MA, Malm J: Diagnosis and treatment of idiopathic normal pressure hydrocephalus. *Continuum (Minneap Minn)* 22:579-599, 2016. <https://doi.org/10.1212/CON.0000000000000305>