

Original Investigation

Neurotrauma

Analysis of Preoperative Imaging Factors and Development of a Nomogram Model for Predicting Recurrence in Patients with Septated Chronic Subdural Hematoma

Xi CAO, Kunliang HUO, Liang CHEN, Jiayu LI, Ziyin YANG, Jun HUANG, Anliang GAO

Department of Neurosurgery, The Second Affiliated Hospital of Chengdu Medical College, China National Nuclear Corporation 416 Hospital, Chengdu 610000, China

Corresponding author: Anliang GAO ✉ xycx416@163.com

ABSTRACT

AIM: To develop a nomogram model that provides a clinical prediction method for preventing septated chronic subdural hematoma (sCSDH) recurrence after surgery and serves as a reference for selecting surgical approaches.

MATERIAL and METHODS: This study involved 237 patients diagnosed with sCSDH. Based on the recurrence status of the affected side during follow-up, patients were divided into a recurrence group (43 cases) and a non-recurrence group (194 cases). The imaging-related factors influencing the recurrence of sCSDH after surgery were initially screened using univariate analysis, followed by multivariate logistic regression analysis to identify independent risk factors. A nomogram model was developed using R software, and internal validation was conducted using the bootstrap method.

RESULTS: The univariate analysis revealed that cerebral atrophy, bilateral hematomas, preoperative midline shift distance, sCSDH typing, and neovascularization were the significant factors in the postoperative recurrence of sCSDH. However, the multivariate logistic regression analysis identified encephalatrophy, bilateral hematomas, and neovascularization as independent risk factors for sCSDH recurrence. Furthermore, the nomogram model analysis demonstrated good discrimination with an AUC of 0.764 (95% CI: 0.6958-0.8322), while the P-value of the Hosmer-Lemeshow test was 0.4382, indicating good consistency.

CONCLUSION: Encephalatrophy, bilateral hematomas, and neovascularization are independent imaging risk factors associated with sCSDH recurrence. The developed nomogram model will enable clinicians to assess and identify patients at a higher risk of sCSDH recurrence, enabling them to formulate appropriate diagnostic and treatment strategies.

KEYWORDS: Septated chronic subdural hematoma, Postoperative recurrence, Imaging features, Risk factors, Nomogram model

INTRODUCTION

Chronic subdural hematoma (CSDH) is a prevalent neurosurgical condition commonly observed in elderly individuals with a history of craniocerebral trauma, often presenting with evident neurological dysfunction. The current annual incidence rate of CSDH ranges from 1.7 to 20.6 per 100,000 individuals (1). Although surgery is the primary treatment for CSDH, the condition is associated with a high postoperative recurrence rate, which can reach up to 33% (3,6,7).

Septated chronic subdural hematoma (sCSDH) is a distinct subtype characterized by the presence of multiple fiber septum compartments within the hematoma. Due to the extensive fibrous space within the hematoma cavity, surgical intervention is challenging, and postoperative recurrence rates are higher compared to general CSDH cases (13,15). While MRI examination has been routinely employed for diagnosing and preoperatively evaluating sCSDH, few studies have investigated the impact of preoperative imaging characteristics on

Xi CAO : 0009-0009-1370-2435

Kunliang HUO : 0009-0008-3994-2480

Liang CHEN : 0009-0005-6044-4177

Jiayu LI : 0009-0002-5408-8290

Ziyin YANG : 0009-0001-6667-8821

Jun HUANG : 0009-0006-2494-7698

Anliang GAO : 0009-0007-3144-3815



This work is licensed by "Creative Commons Attribution-NonCommercial-4.0 International (CC)".

its postoperative recurrence risk. In this retrospective study, imaging data from 237 surgically treated patients diagnosed with sCSDH between January 2016 and January 2023 were analyzed. The aim was to explore preoperative imaging-related risk factors associated with postoperative recurrence and provide predictive methods for clinical prevention of sCSDH recurrence while offering reference guidelines for selecting appropriate surgical approaches.

■ MATERIAL and METHODS

This study has been approved by the Ethics Committee of the Second Affiliated Hospital of Chengdu Medical College, the number is YJ-2024-011.

General Information

This study considered preoperative imaging data from 277 patients with sCSDH who were admitted to the Second Affiliated Hospital of Chengdu Medical College from January 2016 to January 2023. Based on inclusion and exclusion criteria, 237 patients were included in the study and categorized into non-recurrent and recurrent groups based on whether recurrence occurred within three months after surgery. The non-recurrence group consisted of 194 patients who did not experience recurrence within the first three months of postoperative follow-up, including 61 females and 133 males. The recurrence group comprised 43 patients who experienced recurrence within three months after surgery and required reoperation, including 14 females and 29 males. All enrolled cases were diagnosed with sCSDH, underwent surgical intervention, and were given a preoperative head MRI. Various factors such as age, gender, encephalatrophy score, neovascularization status, bilateral hematomas presence, preoperative hematoma volume/thickness/midline shift measurements, and signal manifestation characteristics on T1WI/T2WI images for hematomas were recorded along with septation type information. The degree of encephalatrophy was assessed using preoperative head MRI based on the Koedam score, which categorizes the condition into four levels (10): Grade 0 indicates closed sulcus with no gyrus atrophy; Grade 1 denotes mild sulcus widening and gyrus atrophy; Grade 2 represents significant sulcus enlargement and gyrus atrophy; and Grade 3 indicates pronounced sulcus enlargement accompanied by blade-like gyrus atrophy. The MRI findings were further classified as single septal, multiseptal, or honeycomb types based on compartment division. Previous studies have suggested a three-month timeframe as the most common duration for CSDH recurrence evaluation (2). In this study, recurrence was defined as radiographic evidence of relapse within three months after initial surgery along with corresponding neurological dysfunction (2,17,24).

Inclusion and Exclusion Criteria

The inclusion criteria were as follows:

1) Condition confirmed by head MRI; 2) Symptoms of increased intracranial pressure and impaired neurological function; 3) Complete medical record information with long-term

follow-up in our department; 4) Follow-up time of more than three months.

The exclusion criteria were as follows:

1) Other intracranial hemorrhagic diseases, such as cerebral parenchymal hemorrhage, subarachnoid hemorrhage, epidural hematoma, etc.; 2) Long-term use of anticoagulants; 3) Loss to follow-up due to various reasons; 4) Concomitant presence of critical underlying diseases.

Surgical Method

Traditional Drilling and Drainage

Patients under general anesthesia assume a supine position with shoulders and head appropriately padded and the head to the healthy side, according to the patient's preoperative CT or MRI positioning. A full-thickness transverse incision of approximately 5.0 cm long is made in the scalp at the thickest point of the hematoma. Subcutaneous tissue and periosteum are separated, using a skull electric drill to make a bone hole, and an incision is made in the dura mater. A dark red subdural hematoma outflow occurs, and a drainage tube, approximately 4.0 cm long, is inserted for slow irrigation with normal saline until clear rinse liquid flows from the hematoma cavity. The drainage tube is kept in place for two to three days, and a postoperative drainage bag is fitted to maintain low drainage.

Small Bone Window Hematoma Removal Under Neuroendoscopy

The anesthesia method, surgical position, skin incision, and drilling position are consistent with the drilling drainage procedure. Following drilling, a 3 cm × 3 cm bone window is milled using a milling cutter. The dura mater and outer membrane of the hematoma are opened. Subsequently, the hematoma fluid is slowly released while employing rigid 0° endoscopy to remove any residual hematoma. The diaphragm and fibrous bands are separated, and complete hemostasis in the operative area is ensured. The hematoma cavity is rinsed multiple times with normal saline until a clear rinse solution is obtained. A drainage tube is inserted, and routine closure of the scalp is performed. The drainage tube remains in place for two to three days while maintaining low positioning of the postoperative drainage bag.

Statistical Methods

Data processing was performed using SPSS 26.0 statistical software. Measurement data meeting normal distribution were presented as mean ± standard deviation (±s). An independent sample t-test was employed for intergroup comparisons. Count data were expressed as frequency/rate (%) and analyzed using the chi-square test (χ² test). Multivariate logistic regression analysis was conducted for multivariate analysis. Based on the results of the multivariate analysis, a nomogram model was established using R software (R 4.3.1). Internal verification was performed using the bootstrap method, while discrimination and calibration of the model were evaluated through calibration curve and ROC curve analyses. Statistical significance was set at p<0.05.

RESULTS

Univariate Analysis Result

Encephalatrophy, bilateral hematomas, preoperative midline shift ≥ 15 mm, Neovascularization, and sCSDH classification were identified as significant factors influencing postoperative recurrence in patients with sCSDH (Table I).

Table I: Comparison of General Characteristics Between Non-recurrence Group and Recurrence Group

Variable	No-recurrence group (n=194)	Recurrent group (n=43)	p-value
	n (%)	n (%)	
Age	65.8 \pm 8.7	68.3 \pm 8.7	0.092
Gender			1
Female	61 (31.4)	14 (32.6)	
Male	133 (68.6)	29 (67.4)	
Encephalatrophy			<0.001
<level 2	125 (64.4)	12 (27.9)	
\geq level 2	69 (35.6)	31 (72.1)	
Neovascularization			0.009
No	99 (51)	32 (74.4)	
Yes	95 (49)	11 (25.6)	
Bilateral hematomas			0.006
No	47 (24.2)	20 (46.5)	
Yes	147 (75.8)	23 (53.5)	
Hematoma volume			1
<120ml	83 (42.8)	18 (41.9)	
\geq 120ml	111 (57.2)	25 (58.1)	
Hematoma width			0.55
<20mm	80 (41.2)	15 (34.9)	
\geq 20mm	114 (58.8)	28 (65.1)	
Midline shift			0.031
<10mm	48 (24.7)	6 (14)	
10-20mm	75 (38.7)	12 (27.9)	
\geq 20mm	71 (36.6)	25 (58.1)	
Type of sCSDH			0.017
Single septated	75 (38.7)	7 (16.3)	
Multi septated	63 (32.5)	21 (48.8)	
Honeycomb	56 (28.9)	15 (34.9)	
T 1WI			0.861
Low	99 (51)	20 (46.5)	
Isointensity	59 (30.4)	14 (32.6)	
High	36 (18.6)	9 (20.9)	
T 2WI			0.807
Low	79 (40.7)	17 (39.5)	
Isointensity	43 (22.2)	8 (18.6)	
High	72 (37.1)	18 (41.9)	

Multivariate Analysis

Encephalatrophy, bilateral hematomas, and neovascularization were identified as independent risk factors for postoperative recurrence in patients with sCSDH ($p < 0.05$) (Table II).

Construction and Validation of the Nomogram Model

Multivariate logistic regression analysis identified three independent risk factors, which were incorporated into R software to develop the nomogram prediction model (Figure 1). The AUC/C-index of the nomogram prediction model was 0.764 (95% confidence interval: 0.6958-0.8322), indicating good discrimination (Figure 2). Internal verification of the nomogram model was performed using the bootstrap resampling method ($B=1000$), the calibration curve was drawn, and the Hosmer-Lemeshow test was performed. The results showed that the Hosmer-Lemeshow test p-value was 0.4382 (> 0.05), suggesting good consistency between the predicted probability and actual probability (Figure 3).

DISCUSSION

sCSDH, as a distinct subtype of chronic subdural hematoma, is characterized by localized inflammatory responses triggered post-hemorrhage, gradually producing an envelope. The hyperplasia, fibrosis, and organization of granulation tissues within these envelopes contribute to the separation. CT findings in sCSDH patients often reveal mixed high- and low-density shadows with a crescent-shaped hematoma exhibiting uneven wall thickness and irregular intima (1,22). In comparison to CT, MRI can further elucidate factors such as the separation of the hematoma, thickening of the capsule,

Table II: The results of Multivariate Logistic Regression Analysis for Preoperative Imaging Features in Predicting Postoperative Recurrence Among Patients with sCSDH

	OR	95% CI	p-value
Encephalatrophy			
<level 2 ^a			
\geq level 2	4.033	1.866-8.714	<0.001
Neovascularization			
No ^a			
Yes	2.7	1.206-6.041	0.016
Bilateral hematomas			
No ^a			
Yes	0.341	0.158-0.736	0.006
Midline shift			
<10mm ^a			
10-20mm	1.328	0.428-4.125	0.623
\geq 20mm	2.748	0.956-7.898	0.06
Type of sCSDH			
Single septated ^a			
Multi septated	2.403	0.89-6.485	0.083
Honeycomb	2.466	0.871-6.98	0.089

^a is used as a control in the categorical variables.

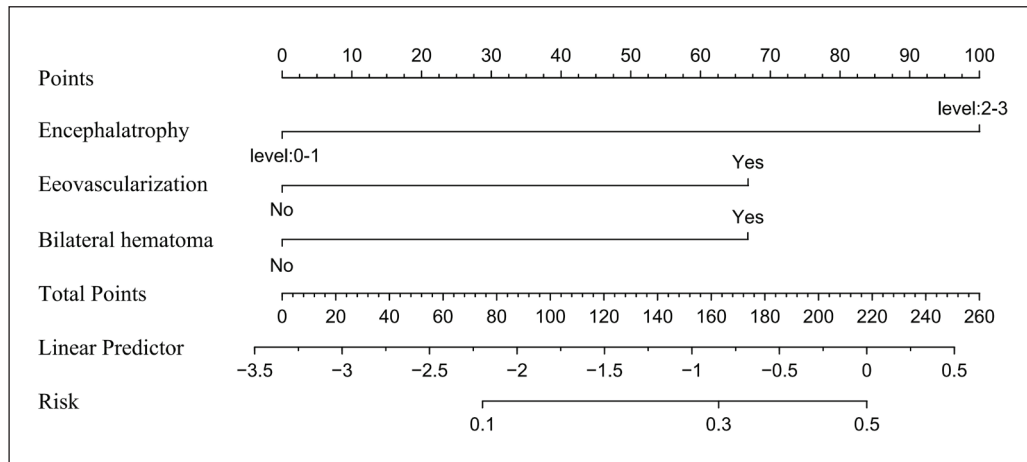


Figure 1: Nomogram model for predicting postoperative recurrence of sCSDH.

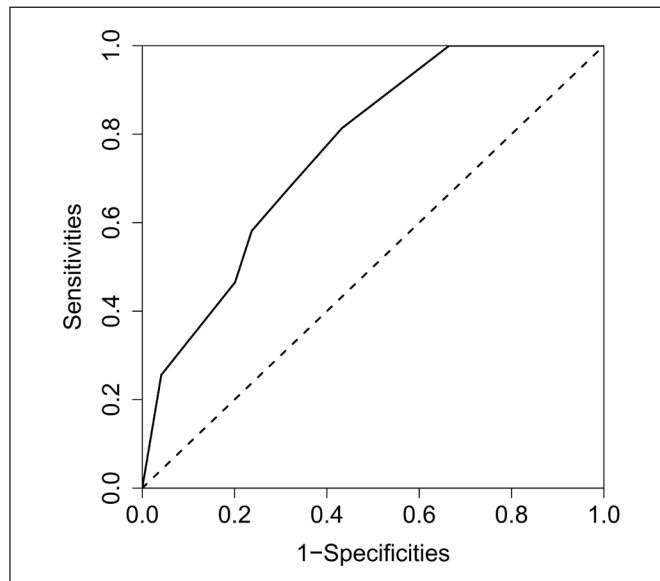


Figure 2: ROC curve of nomogram model for predicting postoperative recurrence of sCSDH.

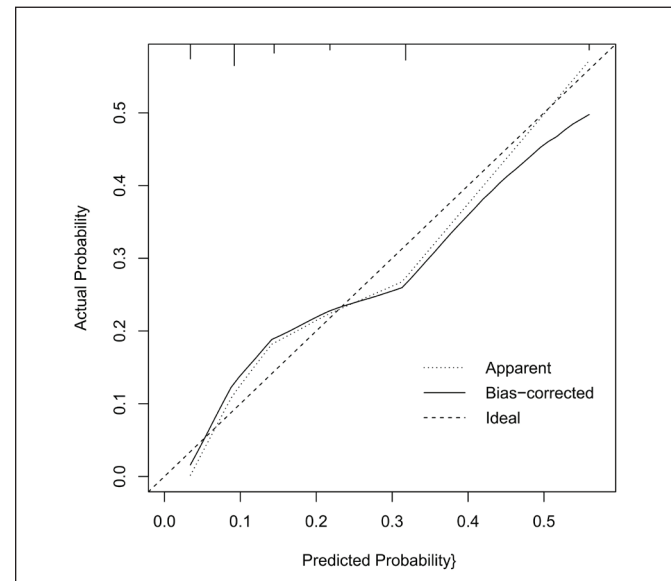


Figure 3: Calibration curve of nomogram model for predicting postoperative recurrence of sCSDH.

calcification, and neovascularization. Due to the occurrence of these characteristics, surgical complexity and postoperative recurrence rates are higher in sCSDH patients compared to those with general types of CSDH. Recurrent hematomas exert repetitive pressure on brain tissue, leading to irreversible damage in atrophic brain regions while significantly impacting patient prognosis and quality of life. Therefore, exploring preoperative imaging characteristics as risk factors for postoperative recurrence in sCSDH is essential to providing predictive methods for clinical prevention and guiding surgical approach selection.

In the univariate analysis, significant differences were observed between the two groups in terms of encephalatrophy, bilateral hematomas, preoperative midline shift ≥ 15 mm, neovascularization, and sCSDH classification ($p < 0.05$). A preoperative midline shift greater than 10 mm has been recognized as a risk factor for poor postoperative brain expansion, which increases the likelihood of hematoma reaccumulation and

subsequent recurrence (11). Our multivariable regression analysis revealed that patients with a preoperative midline shift of 15 mm had a higher tendency for relapse after surgery; however, this difference was not statistically significant ($p > 0.05$). We posit that this finding can be attributed to the inclusion of bilateral sCSDH cases in this study, wherein both brain hemispheres were simultaneously compressed, impeding accurate measurement of midline offset distance. Jack et al. consider septal hematoma as an important risk factor for recurrence after CSDH (9), while Stanišić and Pripp find no obvious relationship between septal hematoma and postoperative recurrence (18). The present study suggests that the multi-segment type of sCSDH is associated with a higher recurrence rate, which we attribute to factors such as the extensive separation of hematoma, surgical challenges in achieving complete removal, mixed density of hematoma, and potential residual hematoma post-surgery (9,17). However, our multivariate analysis did not reveal any statistically significant difference between the two

groups ($p>0.05$), which can be attributed to our preoperative selection of surgical methods.

This study demonstrates that grade 2 or higher encephalatrophy, bilateral hematomas, and neovascularization within the hematoma cavity are independent risk factors for postoperative recurrence in patients with sCSDH ($p<0.05$). Lee found that encephalatrophy was one of the risk factors for the onset and recurrence of CSDH (12). Patients with encephalatrophy have more extracerebral space and sufficient subdural space after surgery. The elasticity of encephalatrophy patients is poor, plasticity is low, the ability of cerebral recovery is low, and the speed of retraction is slow (4,8,12). These factors provide the conditions for the recurrence of the hematoma. The present study suggests that bilateral sCSDHs are more recurrent than unilateral ones, which is consistent with previous studies (21).

Bilateral sCSDH often presents with severe encephalatrophy, resulting in delayed expansion of brain tissue and hematoma reformation post-surgery. Therefore, we postulate a potential correlation between bilateral hematomas and encephalatrophy; the encephalatrophy provides a potential space for the expansion of bilateral hematomas, which may allow for the expansion of the hematoma. Additionally, prolonged compression of the hematoma can weaken adhesion between the inner and outer membranes of subdural chronic hematoma (sCSDH), increasing the likelihood of postoperative recurrence (14). The elevated expression of various growth factors (e.g., VEGF) within the hematoma cavity leads to increased neovascularization with an unstable vascular wall, potentially destabilizing the internal structure of the cavity and causing significant plasma extravasation and recurrent bleeding, ultimately facilitating hematoma formation and postoperative recurrence (16,23). Some studies suggest these neovascularizations are connected to the middle meningeal artery, highlighting this situation as one of the reasons for sCSDH's postoperative recurrence (19). The endoscopic examination allows for clear visualization of the internal partition and surface neovascularization of the hematoma, revealing pathological manifestations such as neovascularization, fibrous tissue hyperplasia, inflammatory cell infiltration, neogranulation, and local hyperfibrinolysis within the hematoma cavity. These factors contribute to impaired coagulation, resulting in a high recurrence rate (5,20). Therefore, effective treatment of separation and prevention of neovascularization-induced rebleeding are crucial in surgical management. In summary, neovascularization, bilateral hematomas presence, and neovascularization within the hematoma cavity are independent imaging risk factors associated with chronic subdural hematoma recurrence following surgery.

Based on this multivariate logistic regression analysis, a nomogram was subsequently constructed using the R language and internally validated through the bootstrap method. The findings from the ROC curve and calibration curve indicated that the model exhibited excellent discrimination and consistency, as well as robust predictive capability. This study focused on preoperative imaging data of patients to predict the risk of postoperative recurrence in individuals with sCSDH, thereby enabling proactive prevention and serving as a reference for surgical approach selection. Consequently, the

established nomogram prediction model holds significant clinical value.

The limitations of this study are; it is a single-center retrospective study with the purpose of predicting postoperative recurrence at the time of preliminary preoperative diagnosis. This model needs to be validated in multi-centers with more patients. We will conduct further studies.

CONCLUSION

Encephalatrophy, bilateral hematomas, and neovascularization are independent imaging risk factors associated with sCSDH recurrence. We recommend the endoscopic evacuation of the hematoma as an effective method for managing neovascularization. The developed nomogram model will enable clinicians to assess and identify patients at a higher risk of sCSDH recurrence, enabling them to formulate appropriate diagnostic and treatment strategies.

Declarations

Funding: No financial support was received for this research.

Availability of data and materials: The datasets generated and/or analyzed during the current study are available from the corresponding author by reasonable request.

Disclosure: The authors declare no competing interests.

AUTHORSHIP CONTRIBUTION

Study conception and design: XC, AG

Data collection: XC, KH, LC

Analysis and interpretation of results: XC, LC, JL, ZY

Draft manuscript preparation: XC

Critical revision of the article: AG

Other (study supervision, fundings, materials, etc...): ZY, JH, AG

All authors (XC, KH, LC, JL, ZY, JH, AG) reviewed the results and approved the final version of the manuscript.

REFERENCES

- Berhouma M, Jacquesson T, Jouanneau E: The minimally invasive endoscopic management of septated chronic subdural hematomas: Surgical technique. *Acta Neurochir (Wien)* 156:2359-2362, 2014. <https://doi.org/10.1007/s00701-014-2219-1>
- Chari A, Hocking KC, Broughton E, Turner C, Santarius T, Hutchinson PJ, Koliass AG: Core outcomes and common data elements in chronic subdural hematoma: A systematic review of the literature focusing on reported outcomes. *J Neurotrauma* 33:1212-1219, 2016. <https://doi.org/10.1089/neu.2015.3983>
- Chinese Society of Neurosurgery, Chinese Neurosurgery Critical Care Management Collaboration Group: Expert consensus on drug therapy for chronic subdural hematoma [J]. *Chinese Med J* 100:566-572, 2020. <https://doi:10.3760/cma.j.isn.0376-2491.2020.08.003>
- Desai VR, Scranton RA, Britz GW: Management of recurrent subdural hematomas. *Neurosurg Clin N Am* 28:279-286, 2017. <https://doi.org/10.1016/j.nec.2016.11.010>

5. Edlmann E, Giorgi-Coll S, Whitfield PC, Carpenter KLH, Hutchinson PJ: Pathophysiology of chronic subdural haematoma: inflammation, angiogenesis and implications for pharmacotherapy. *J Neuroinflammation* 14:108, 2017. <https://doi.org/10.1186/s12974-017-0881-y>
6. Feghali J, Yang W, Huang J: Updates in chronic subdural hematoma: epidemiology, etiology, pathogenesis, treatment, and outcome. *World Neurosurg* 141:339-345, 2020. <https://doi.org/10.1016/j.wneu.2020.06.140>
7. Guo S, Gao W, Cheng W, Liang C, Wu A: Endoscope-assisted surgery vs. burr-hole craniostomy for the treatment of chronic subdural hematoma: A systemic review and meta-analysis. *Front Neurol* 11:540911, 2020. <https://doi.org/10.3389/fneur.2020.540911>
8. Han MH, Ryu JI, Kim CH, Kim JM, Cheong JH, Yi HJ: Predictive factors for recurrence and clinical outcomes in patients with chronic subdural hematoma. *J Neurosurg* 127:1117-1125, 2017. <https://doi.org/10.3171/2016.8.JNS16867>
9. Jack A, O'Kelly C, McDougall C, Findlay JM: Predicting recurrence after chronic subdural haematoma drainage. *Can J Neurol Sci* 42:34-39, 2015. <https://doi.org/10.1017/cjn.2014.122>
10. Koedam EL, Lehmann M, van der Flier WM, Scheltens P, Pijnenburg YA, Fox N, Barkhof F, Wattjes MP: Visual assessment of posterior atrophy development of a MRI rating scale. *Eur Radiol* 21:2618-2625, 2011. <https://doi.org/10.1007/s00330-011-2205-4>
11. Kristof RA, Grimm JM, Stoffel-Wagner B: Cerebrospinal fluid leakage into the subdural space: possible influence on the pathogenesis and recurrence frequency of chronic subdural hematoma and subdural hygroma. *J Neurosurg* 108:275-280, 2008. <https://doi.org/10.3171/JNS/2008/108/2/0275>
12. Lee KS: Chronic subdural hematoma in the aged, trauma or degeneration? *J Korean Neurosurg Soc* 59:1-5, 2016. <https://doi.org/10.3340/jkns.2016.59.1.1>
13. Liu LX, Cao XD, Ren YM, Zhou LX, Yang CH: Risk factors for recurrence of chronic subdural hematoma: A single center experience. *World Neurosurg* 132:e506-e513, 2019. <https://doi.org/10.1016/j.wneu.2019.08.089>
14. Maroufi SF, Farahbakhsh F, Macdonald RL, Khoshnevisan A: Risk factors for recurrence of chronic subdural hematoma after surgical evacuation: A systematic review and meta-analysis. *Neurosurg Rev* 46:270, 2023. <https://doi.org/10.1007/s10143-023-02175-1>
15. Miranda LB, Braxton E, Hobbs J, Quigley MR: Chronic subdural hematoma in the elderly: Not a benign disease. *J Neurosurg* 114:72-76, 2011. <https://doi.org/10.3171/2010.8.JNS10298>
16. Petrov A, Ivanov A, Dryagina N, Petrova A, Samochernykh K, Rozhchenko L: Angiogenetic factors in chronic subdural hematoma development. *Diagnostics* 12:2787, 2022. <https://doi.org/10.3390/diagnostics12112787>
17. Ro HW, Park SK, Jang DK, Yoon WS, Jang KS, Han YM: Pre-operative predictive factors for surgical and functional outcomes in chronic subdural hematoma. *Acta Neurochir (Wien)* 158:135-139, 2016. <https://doi.org/10.1007/s00701-015-2625-z>
18. Stanišić M, Pripp AH: A Reliable grading system for prediction of chronic subdural hematoma recurrence requiring reoperation after initial burr-hole surgery. *Neurosurgery* 81:752-760, 2017. <https://doi.org/10.1093/neuros/nyx090>
19. Tanaka T, Kaimori M: Histological study of vascular structure between the dura mater and the outer membrane in chronic subdural hematoma in an adult. *No Shinkei Geka Neurological Surgery* 27:431-436, 1999
20. Tao Z, Lin Y, Hu M, Ding S, Li J, Qiu Y: Mechanism of subdural effusion evolves into chronic subdural hematoma: IL-8 inducing neutrophil oxidative burst. *Med Hypotheses* 86:43-46, 2016. <https://doi.org/10.1016/j.mehy.2015.11.027>
21. Torihashi K, Sadamasa N, Yoshida K, Narumi O, Chin M, Yamagata S: Independent predictors for recurrence of chronic subdural hematoma: A review of 343 consecutive surgical cases. *Neurosurgery* 63:1125-129, 2008. <https://doi.org/10.1227/01.NEU.0000335782.60059.17>
22. Wakuta N, Abe H, Nonaka M, Morishita T, Higashi T, Arima H, Inoue T: Analysis of endoscopic findings in the chronic subdural hematoma cavity: Bleeding factors in chronic subdural hematoma natural history and as predictors of recurrence. *World Neurosurg*, 2018 (Online ahead of print). <https://doi.org/10.1016/j.wneu.2018.12.078>
23. Yokota M, Osuka K, Ohmichi Y, Ohmichi M, Suzuki C, Aoyama M, Iwami K, Honma S, Miyachi S: Platelet-derived growth factor activates pericytes in the microvessels of chronic subdural hematoma outer membranes. *Neurol Med Chir (Tokyo)* 64:50-55, 2024. <https://doi.org/10.2176/jns-nmc.2023-0079>
24. Zhang Y, Chen S, Xiao Y, Tang W: Effects of dexamethasone in the treatment of recurrent chronic subdural hematoma. *World Neurosurg* 105:115-121, 2017. <https://doi.org/10.1016/j.wneu.2017.05.135>