

Primary Osseous Malignant Fibrous Hystiocytoma Of The Skull: A Case Report

Kafatasında Primer Osseöz Malign Fibröz Histiositoma: Olgu Sunumu

KAYHAN KUZAYLI, ERTUĞRUL ÇAKIR, ABDÜLKADİR REİS,
SÜLEYMAN BAYKAL, HAVVANUR TURGUTALP

Karadeniz Technical University Medical Faculty, Departments of Neurosurgery (KK, EÇ, SB) and
Pathology (AR, HT), Trabzon, Turkey

Received: 4.2.1999 ⇔ Accepted: 23.11.1999

Abstract: Malignant fibrous histiocytoma rarely affects the cranium. This report describes a case of primary osseous malignant fibrous histiocytoma of the temporal bone in a 58-year-old male patient. The tumor was thought to have originated in the inner table of the bone of the skull, with subsequent intracranial-extracranial extension. Lung metastasis developed and the patient died 6 months after the histopathological diagnosis. We discuss the case and review the relevant literature.

Key words: Computerized tomography, magnetic resonance imaging, malignant fibrous histiocytoma, skull

Özet: Kraniyal malign fibröz histiositomalar nadir tümörlerdir. Bu makalede 58 yaşında erkek hastada görülen; temporal kemiğin malign fibröz histiositoma olgusunu sunduk. Tümörün iç tabuladan köken aldığı ve daha sonra intra ve ekstrakraniyal yayılım gösterdiği düşünüldü. Hasta cerrahiden altı ay sonra kaybedildi. Olgu ilgili literatür gözden geçirilerek tartışıldı.

Anahtar Kelimeler: Bilgisayarlı tomografi, kafatası, malign fibröz histiositoma, manyetik rezonans görüntüleme

INTRODUCTION

Malignant fibrous histiocytoma (MFH) is a malignant tumor typically found in soft tissue and long bones (4,6,9). This neoplasm has been reported in areas of irradiated (11) or traumatized bone, at sites of infarcted bone (8), and in association with Paget's disease (7) and fibrous dysplasia (9), but MFH of the skull is extremely rare (2,4-6,9).

CASE REPORT

A 58-year-old male presented with a nonspecific left temporoparietal headache. Physical examination

revealed pain on palpation of the right temporoparietal region as the only abnormality. The patient's neurological exam was normal. Cranial x-rays showed abnormal bone density in the right temporoparietal region (Figure 1). Computerized tomography (CT) revealed irregularity of the inner table of the skull bone in this area, and a hyperdense lesion with no mass effect in the adjacent brain tissue (Figure 2a). A bone window CT scan of the same lesion showed marked destruction of the inner table of the cranium at the site (Figure 2b). Contrast-enhanced CT scans revealed no changes in the lesion's appearance. The patient's blood

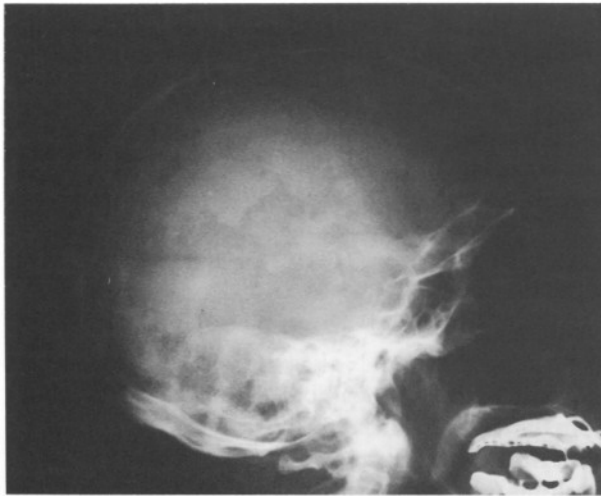

Figure 1: Lateral craniography shows abnormal bone density in the temporoparietal region.

biochemistry and whole blood count were normal. A magnetic resonance imaging (MRI) study was also planned.

Twenty days after initial presentation, the patient's headache had worsened considerably. Examination revealed a palpable and painful swelling in his right temporoparietal area. T2-weighted MR images showed a right calvarial extraaxial lesion with intra-extracranial extension

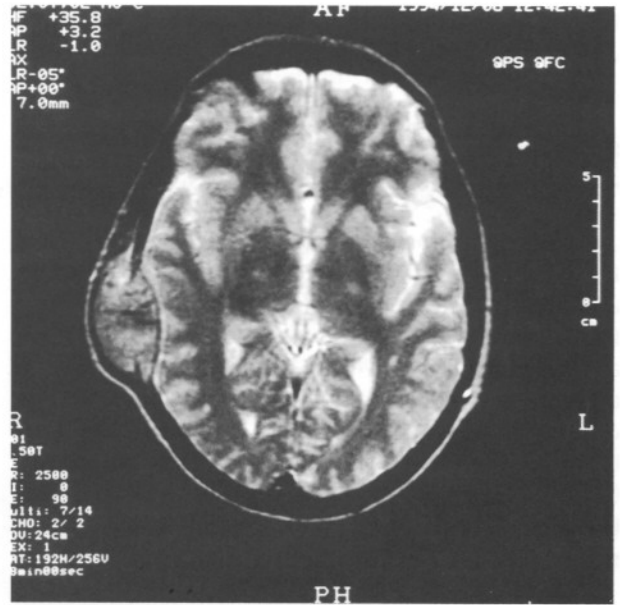


Figure 3: T2-weighted axial MRI done 17 days after the CT scan shows rapid tumor growth. The neoplasm is extraaxial and iso-hypointense compared to the brain parenchyma, and a mass effect is now apparent.

(Figure 3). We performed a right-sided temporoparietal craniectomy, and found a tumor originating from the inner table of the bone of the skull, with no macroscopic evidence of dural invasion. The mass was nodular and encased in a thin capsule. Surgery involved total excision of the

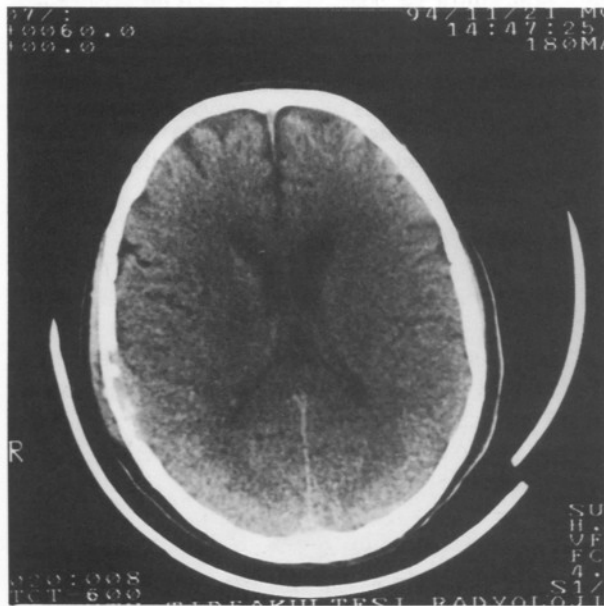


Figure 2a: Axial CT without contrast shows destruction of the inner table of the bone of the skull. Note that there is no mass effect associated with the hyperdense lesion in the adjacent parenchyma.

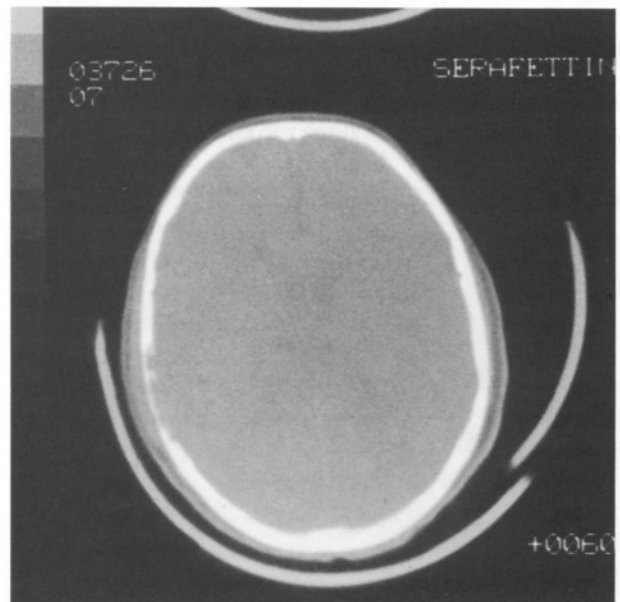


Figure 2b: A bone window CT scan of the same lesion shows marked destruction of the inner table of the skull bone.

tumor, with no cranioplasty at the site of the bone defect.

Histopathologic examination revealed that the mass consisted of highly pleomorphic cells with atypical mitotic activity (Figure 4a-c).

Immunohistochemical studies showed that the neoplastic cells stained strongly for vimentin and alpha-1-antichymotrypsin (Figure 4d), showed focal mild staining for Factor 8 and S-100 protein, and did not stain for epithelial membrane antigen, or smooth muscle actin and desmin. The diagnosis was MFH, and the patient underwent treatment with fractionated radiotherapy (4,500 cGy). The patient died 6 months after the histopathological diagnosis, due to lung metastasis.

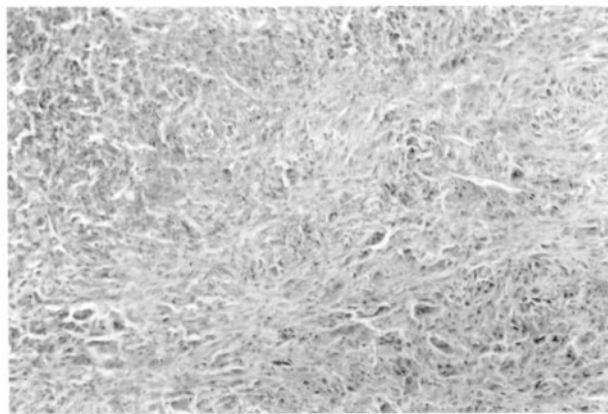


Figure 4a: A photomicrograph shows the tumor's characteristic storiform pattern. (HE x100)

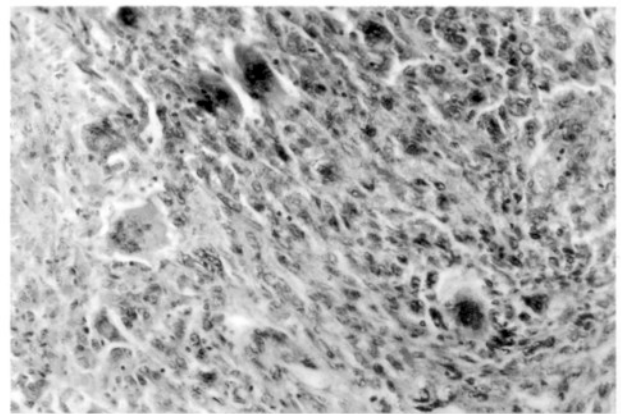


Figure 4c: A photomicrograph shows a field densely populated with giant tumoral cells. (HE x200)

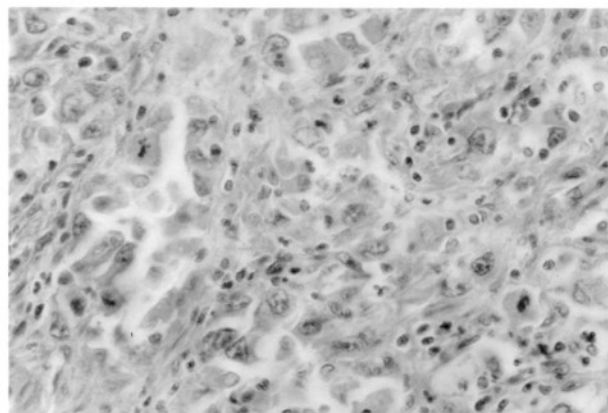


Figure 4b: A photomicrograph shows pleomorphic tumor cells with atypical mitotic figures, as well as infiltrating inflammatory cells. (HE x 400).

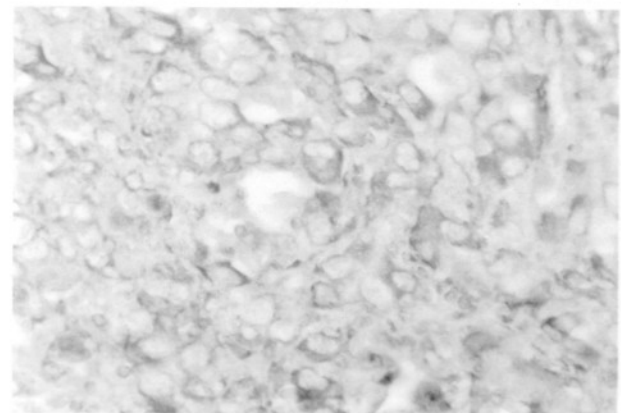


Figure 4d: Immunohistochemical staining reveals a positive reaction to alpha-1-antichymotrypsin in the cytoplasm of the tumor cells. (x 400)

DISCUSSION

MFH is a malignant pleomorphic mesenchymal tumor that consists of a bicellular population of fibroblasts and histiocytes in varying proportions (12). This neoplasm is the most common malignant tumor of soft tissue (9,10,12), but is rarely seen in the bones of the skull and face (2,4-6,9,11). Our literature search revealed only 20 cases of the latter type (1,3-5,9).

According to Nakayama et al., MFH can originate from the inner table of the bones of the skull, from the diploe, or from the dura mater (9). Like other skull tumors, MFH can present as painful soft-tissue swelling. The tumor in our case first destroyed the inner table of the bone in the patient's right temporoparietal area. At the time of our initial work-up, there was no notable intracranial or extracranial

mass lesion (Figures 2a,b); however, MRI done 2 weeks later revealed a significant intracranial-extraaxial mass lesion (Figure 3). The literature provides no detailed information about the rate at which these tumors grow, but they are thought to progress rapidly. Treatment for MFH involves surgical removal followed by adjuvant chemotherapy and radiotherapy. Aggressive treatment is vital because of the tumor's potential to grow and metastasize quickly (9).

In summary, this report is significant because primary skull MFH is a highly unusual finding. Although there have been approximately 20 reported cases to date, our report is the first to document the occurrence of early bone destruction with no associated mass effect. We believe that primary MFH of the cranium originates from the inner table of the bones of the skull rather than the dura mater. Our case demonstrates the speed, at which these tumors can grow, a threat that highlights the need for new treatment modalities. The surgeon should always be suspicious of metastasis whenever a patient is diagnosed with MFH.

Correspondence: Doç.Dr. Kayhan Kuzeyli,
KTÜ Tıp Fakültesi Nöroşirurji A.B.D.
61080, Trabzon, Turkey
Tel: +90 462 377 5454
Fax: +90 462 325 0518

REFERENCES

1. Black SW, Adelstein E, Levine C: A typical malignant fibrous histiocytoma of the skull of an infant: Case report. *J Neurosurg* 53:556-9, 1980
2. Cappana R, Bertoni F, Bacchini P, Bacci G, Guerra A, Campaccini M: Malignant fibrous histiocytoma of bone. *Cancer* 54: 177-187, 1984
3. Chitale VS, Sundaresan N, Helson L, et.al: Malignant fibrous histiocytoma of the temporal bone with intracranial extension. *Acta Neurochir (Wien)* 59:239-246, 1981
4. Cook BR, Vries JK, Martinez J: Malignant fibrous histiocytoma of the clivus. Case report. *Neurosurgery* 20:632-635, 1987
5. Dyck P: Malignant fibrous histiocytoma of the pericranium. Case report: *Acta Neurochir (Wien)* 86(1-2):61-4, 1987
6. Hayter JP, Williams DM, Cannell H, Hope SH: Malignant fibrous histiocytoma of the maxilla. Case report and review of the literature. *J Maxillofac Surg* 13(4):167-171, 1985
7. Kannan V, Von Ruden D: Malignant fibrous histiocytoma of bone: Initial diagnosis by aspiration biopsy cytology. *Diagn Cytopathol* 4(3): 262-4, 1988
8. Nagle CE, Morayati SJ, Le Duc MA: Skull infarction in a patient with malignant fibrous histiocytoma. *Clin Nuc Med* 12(9): 735-6, 1987
9. Nakayama K, Namato Y, Inoue Y, et.al: Malignant Fibrous Hystiocytoma of the Temporal bone with endocranial extension. *AJNR* 18(2): 331-334, 1997
10. Natali F, Fesselet J, Jancovici R, Pons F: Histiocytofibrome malign primitif intrathoracique (Malignant primary intrathoracic histiocytofibroma) *Rev Pneumol Clin* 48(6): 269-274, 1992
11. Romero FJ, Ortega A, Ibarra B, Piqueras J, Rovira M: Post-radiation malignant fibrous histiocytoma studied by CT: *Comput Med Imaging Graph* 13(2): 191-194, 1989
12. Voorhies Mr, Sundaresan N: Tumors of the Skull. in *Neurosurgery* Wilkins RH, Rengachary SS (eds) Mc Graw Hill Book Co New York, 1985, pp 996-997.