

An Unusual Presentation of Solitary Osteochondroma of the Cervical Spine: Case Report

Servikal Omurgada Olağandışı Yerleşim Gösteren Soliter Osteokondroma: Olgu Sunumu

SÜLEYMAN R. ÇAYLI, ÇİĞDEM İRKKAN, ÖMER SÖKMEN

Departments of Neurosurgery And Pathology (SRÇ, ÇI), Oncology Hospital (ÖS), Ankara, Turkey

Received : 7.12.1999 ⇔ Accepted : 25.5.2000

Abstract: Osteochondroma of the spine is a rare condition that may or may not be accompanied by neurological dysfunction. We report a case of cervical osteochondroma originating from the transverse process of the fifth cervical vertebra, and discuss the main clinical, pathological and radiological features that were observed in this patient.

Key Words: Cervical spine, osteochondroma, spinal tumor,

Özet: Osteokondroma omurgada nadir görülen, nörolojik fonksiyon bozukluğu yapabilen bir patolojidir. Beşinci servikal vertebranın transvers uzantısından köken alan bir osteokondroma olgusu sunularak klinik, patolojik ve radyolojik görünümleri tartışıldı.

Anahtar Kelimeler: Servikal vertebra, spinal tumor, osteokondroma

INTRODUCTION

Osteochondroma is one of the most common benign tumors of bone. Also known as osteocartilaginous exostosis, this form of neoplasia accounts for roughly 8.5% of all osseous tumors, and approximately 36-40% of benign tumors overall (6,9). This tumor may be solitary, or may arise in the context of multiple exostoses or hereditary multiple exostoses. It is usually found in the diaphysis of the affected bone, and spinal origin is rare. We report a case of solitary osteochondroma in a lower cervical vertebra, a neck mass that was not associated with neurological deficits.

CASE REPORT

A 14-year-old male presented with a painless mass on the right side of his neck. He had first noticed the mass 3 months prior to examination, and reported that it had increased in size since it was first noted. The patient's medical and family history was unremarkable.

Physical examination revealed a painless, solid, mass lesion on the right side of the neck. There were no neurological symptoms of radicular pain or motor deficit, nor was there any limitation of neck movement. The patient's neurological examination

was normal. Plain radiographs of the cervical spine showed a well-delineated lesion containing foci of calcification and protruding from the right transverse process of the fifth cervical vertebra (Figure 1). A computerized tomography (CT) scan revealed a heavily calcified lesion originating from right transverse process of this vertebra (Figure 2). The vertebral canal and all other components of the vertebra were normal.

Surgery involved a lateral approach to the neck in order to explore behind the right sternocleidomastoideus muscle. We removed the tumor en bloc, along with the distal part of the transverse process. Histological analysis confirmed the diagnosis of osteochondroma (Figure 3). The patient's postoperative course was uneventful.

DISCUSSION

Osteochondroma is a common tumor of the skeletal system. These neoplasms are believed to arise through lateral displacement of a portion of epiphyseal cartilage. Based on this, many

pathologists consider osteochondromas to be developmental anomalies rather than true tumors (13). Their origin means that these growths are found in all sites where endochondral ossification occurs,

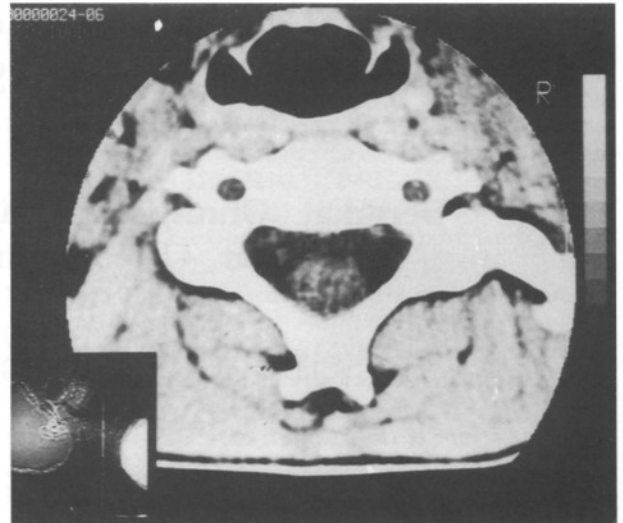

Figure 2: An axial CT scan shows a calcified lesion arising from the right transverse process of the C5 vertebra.

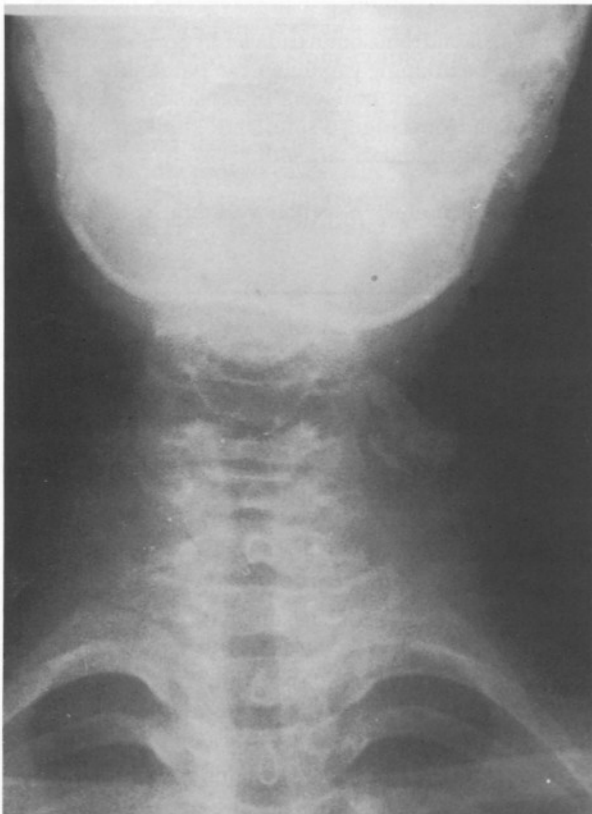


Figure 1: An anteroposterior view on a plain x-ray of the cervical spine demonstrates a mass lesion lateral to the transverse process of the C5 vertebra.

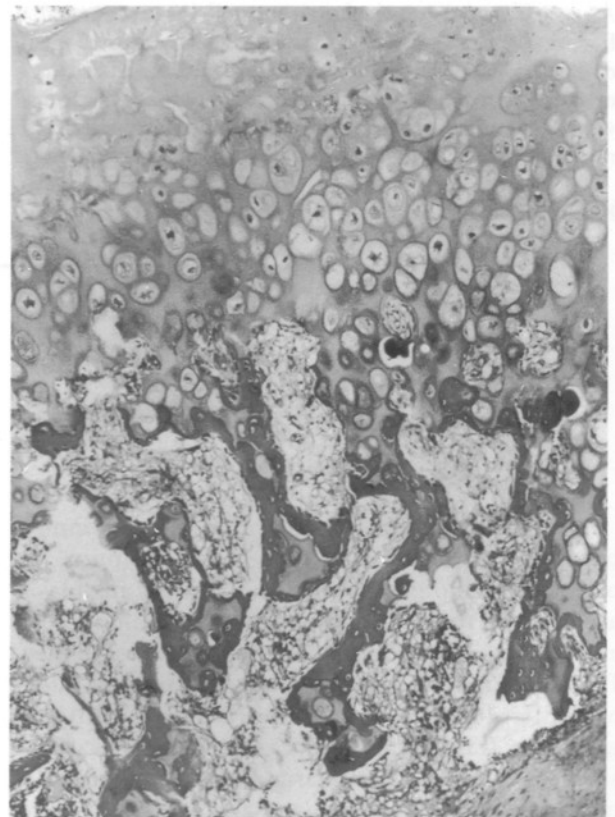


Figure 3: Mature trabecular bone covered by a cartilaginous cap (HE x40).

and generally not in bones that develop through membranous ossification, such as the cranial vault.

Osteochondromas manifest as sessile or pedunculated bony excrescences with periosteum and cortex that are continuous with those of the host bone. They occur in two different patterns, namely, solitary lesions with no genetic component or as multiple lesions known as hereditary multiple exostoses. As mentioned, osteochondromas usually affect long bones. Spinal involvement is rare, especially in the solitary form. Only 1.3% to 4.1% of solitary osteochondromas arise in the spine (1,6), whereas roughly 9% of patients with hereditary multiple osteochondroma have spinal lesions.

Solitary and multiple osteochondroma are more common in males than females, with a male-to-female ratio of about 1.5:1. Most patients are 20 years of age or younger (1,6,12,16). The clinical manifestations vary widely. The tumors may present as painful sites (13) or as palpable masses that may or may not be painful (18). Neurological signs are exhibited when the lesion involves the spinal canal (4,10), and these tumors may cause radiculopathy or myelopathy (2). Neurologic disease is the result of progressive encroachment of the slowly expanding osteochondroma on neural structures (4,5,7,10,15,20). One case report described sudden death in a patient who had an osteochondroma of the odontoid process of the axis that partially transected the cervical spinal cord (17). Anterior cervical osteochondroma may present as a pharyngeal mass (14), as "calcified goiter," or with vocal hoarseness and dysphagia (1,11).

A review of the literature indicates that the upper cervical vertebrae are the most frequently involved cervical vertebrae, particularly C2 (1,2,5). The tumor usually originates from the neural arch and is most often located close to sites of secondary ossification, commonly near the tip of the spinous process or transverse processes (3,8,19). Nevertheless, osteochondromas can arise at any location in the vertebra, and there are reported cases of lesions originating from the intervertebral joints, the pedicles, sites of costovertebral articulation, and the vertebral body (13,19). In our patient, tumor growth started at the tip of the transverse process of the C5 vertebra, and expanded externally from that point without causing any further bony changes in the vertebra.

Spinal osteochondromas are more difficult to detect on plain radiographs, probably because of the complex image that the spine forms (13). When visible, they typically appear as pedunculated or sessile bone-like projections. In our case, plain radiographs showed a smooth calcified mass arising from the tip of the transverse process of the fifth cervical vertebra. CT demonstrates bone detail very well, as our patient's scan showed. Nuclear magnetic resonance imaging is superior to CT for defining an extradural intracanalicular component of the tumor and any dural compression (4).

Surgical treatment should be performed as soon as the tumor becomes symptomatic, or for cosmetic reasons. In our patient's case, a visible mass lesion on the neck was the indication for surgical intervention. The aim of surgical treatment should be to remove as much of the tumor as possible without causing functional deficit. All the published cases of cervical spine involvement showed improvement after a decompression procedure. Recurrence is rare, even when excision is incomplete.

Correspondence: Dr. Süleyman R. Çaylı
Çöşnük mah. Mehmet Buyruk cad.
Bayrak sitesi 5, Daire:3
Malatya, Turkey
Tel: 04223113067
Fax: 04223410726

REFERENCES

1. Albrecht S, Crutchfield S, SeGall G: On spinal osteochondromas. *J Neurosurg* 77; 247-252, 1992
2. Arasyl E, Erdem A, Yüceer N: Osteochondroma of the upper cervical spine. *Spine* 21; 516-518, 1996
3. Beabout JW, McLeod RA, Dahlin DC: Benign tumors. *Semin Roentgenol* 14; 33-43, 1979
4. Cherubino P, Benazzo F, Castelli C: Osteochondroma of the cervical spine. *Ital J Orthop Travmatol* 17; 131-134, 1991
5. Cooke RS, Cumming JK, Cowie RA: Osteochondroma of the cervical spine; case report and review of the literature. *Br J Neurosurg* 8; 359-363, 1994
6. Dahlin DC, Unni KK, Bone Tumors. Springfield, Ill: Charles C Thomas, 1986, 19-32, 228- 229
7. Di Lorenzo N, Delfini R, Ciappetta P, Cantare G, Fortuna A: Primary tumors of the cervical spine; surgical experience with 38 cases. *Surg Neurol* 38; 12-18, 1992
8. Esposito PW, Crawford AH, Vogler C: Solitary osteochondroma occurring on the transverse process of the lumbar spine. A case report. *Spine* 10; 398-400, 1985
9. Glassauer FE. Benign lesions of the cervical spine: *Acta Neurochir (Wien)* 42; 161-175, 1979

10. Inglis AE, Rubin RM, Lewis RJ, Villacin A: Osteochondroma of the cervical spine. *Clin Orthop* 126; 127-129, 1977
11. Kozlowski K, Beluffi G, Mazel J: Primary vertebral tumors in children. Report of 20 cases with brief literature review. *Pediatr Radiol* 14; 129-139, 1984
12. Mirra JM, Picci P, Gold RH, Bone Tumors. Clinical radiologic and pathologic correlations. Philadelphia: Lea & Febiger, 1989: 1626-1659
13. Morard M, de Preux J: Solitary osteochondroma presenting as a neck mass with spinal cord compression syndrome. *Surg Neurol* 37; 402 - 405, 1992
14. Nielsen OG, Gadegaard L, Fogh A: Osteochondroma of the cervical spine. *J Laryngol Otol* 100; 733-736, 1986
15. Prasad A, Renjen PN, Prasad ML: Solitary spinal osteochondroma causing neural symptoms. *Paraplegia* 30; 678-680, 1992
16. Roblot P, Alcalay M, Casenave-Roblot F, Levy P, Bontoux D: Osteochondroma of the thoracic spine. *Spine* 15; 240-243, 1990
17. Rose EG, Fekete A: Odontoid osteochondroma causing sudden death. *Am J Clin Pathol* 42; 606-609, 1964
18. Scher N, Pange WR: Osteochondroma presenting as a neck mass: a case report. *Laryngoscope* 98; 550-553, 1988
19. Spallone A, DiLorenzo N, Nardi P, Nolletti A: Spinal osteochondroma diagnosed by computed tomography. Report of two cases and review of literature. *Acta Neurochir* 58; 105-114, 1981
20. Thomas ML, Andress MR: Osteochondroma of the cervical spine causing cord compression. *Br J Radiol* 44; 549-550, 1971