

Brain Metastasis From Follicular Thyroid Carcinoma: Case report and Literature Review

Foliküler Tiroid Karsinomunun Beyin Metastazı: Olgu Sunumu ve Literatür İncelemesi

ABSTRACT

Brain metastasis is an uncommon and morbid complication of thyroid carcinoma, especially follicular carcinoma. Because of its rarity, management is still debated.

A 64-year-old woman presented with signs of blindness. After ophthalmological and radiological evaluations, A frontobasal mass lesion was detected. The lesion was removed and pathological examination revealed the diagnosis of follicular thyroid carcinoma metastasis. The patient also underwent thyroidectomy, radiotherapy and chemotherapy for follicular carcinoma.

This case shows that the follicular thyroid carcinoma may present with distant metastasis even if it is a rare occurrence.

KEY WORDS: Follicular thyroid carcinoma, brain metastasis, surgery

ÖZ

Beyin metastazı tiroid karsinomunun özellikle foliküler karsinomun nadir ve morbid bir komplikasyonudur. Nadir olduğu için tedavisi halen tartışmalıdır.

64 yaşında bir kadın görme şikayeti ile başvurdu. Oftalmolojik ve radyolojik değerlendirmenin ardından frontobazal kitle lezyonu tesbit edildi. Lezyonun çıkarılmasından sonra patolojik inceleme foliküler tiroid karsinomu tanısını ortaya koydu. Nöroşirürjikal girişimi müteakip hastaya foliküler karsinoma için tiroidektomi, radyoterapi ve kemoterapi uygulandı.

Bu olgu, foliküler tiroid karsinomunun nadir de olsa uzak metastaz ile ortaya çıkabileceğini göstermektedir.

ANAHTAR SÖZCÜKLER: Foliküler tiroid karsinomu, beyin metastazı, cerrahi

Yusuf İZCI¹
Engin GÖNÜL²
Doğa GÜRKANLAR³
Erol BOLU⁴

1,2,3 Department of Neurosurgery,
4 Department of Endocrinology,
Gulhane Military Medical Academy,
Ankara-Turkey

Received: 09.02.2005

Accepted: 03.05.2005

Correspondence Address:

Yusuf İZCI
Gülhane Askeri Tıp Akademisi,
Beyin ve Sinir Cerrahisi AD.,
06018 Etlik-Ankara, TURKEY
Phone :+90 312 3045318
Fax :+90 312 3045300
E-mail : yusufizci@yahoo.com

INTRODUCTION

Follicular thyroid carcinoma (FTC) is a well-differentiated tumor, originates in follicular cells and is the second most common cancer of the thyroid after papillary carcinoma. Despite its well-differentiated characteristics, follicular carcinoma may be overtly or minimally invasive. In fact, FTC may spread easily to other organs, and metastasis is most common in the lung and bone, followed by the brain, the liver and other sites in descending order of frequency (3).

We report a patient with FTC who presented with brain metastasis. She underwent radiotherapy and chemotherapy following surgery for brain metastasis and on the thyroid. We analyze the clinical, radiological and pathological characteristics and discuss relevant medical reports.

CASE REPORT

A 64-year-old woman presented with a 2-year history of headache and loss of vision. She had been examined previously by an ophthalmologist and undergone medical treatment. Because of her dramatically worsened clinical condition, she was referred to our department for further evaluation. There was no family history of cancer. The neurological examination revealed bilateral homonymous hemianopsia and her fundoscopic examination showed bilateral papilledema.

After the neurological assessment, she underwent radiological evaluation with computed tomography (CT) and magnetic resonance imaging (MRI). The cranial CT scan of the patient demonstrated a hyperdense mass lesion involving the frontal lobe, ethmoid sinus and sphenoid sinus. There was no ventricular involvement. No hydrocephalus was noted but there was significant edema. CT scan of the sella turcica was also performed and revealed invasion of mass lesion at the right site of the pituitary region. Cranial MRI showed a hyperintense mass lesion located in the frontobasal region (Figures 1A and 1B).

After the radiological evaluation, a bifrontal craniotomy was performed. A soft gray mass lesion was observed covering the right internal carotid artery (ICA) and all sellar regions. The tumor was removed subtotally to protect the right ICA. After the initial removal of mass lesion, a dural dissection through the right site of sphenoid sinus was performed and the tumor was released from the sinus mucosa, both optic nerves and the frontal sinus wall.

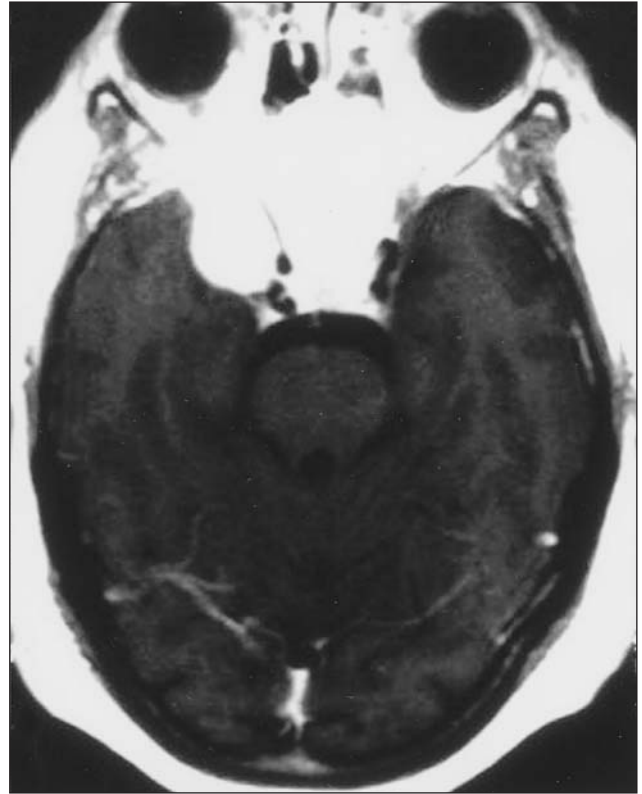


Figure 1A: The axial T1-weighted MRI scan of the patient showing the contrast enhancing mass lesion in the sella turcica and right temporal lobe.

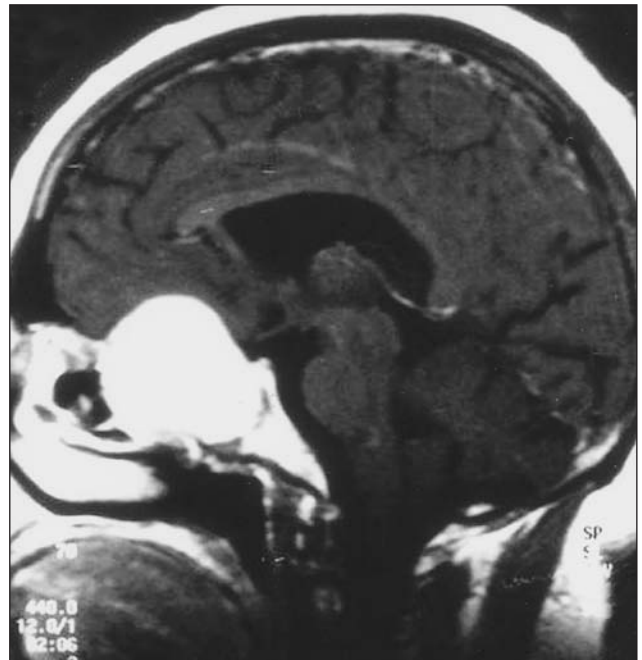


Figure 1B: The sagittal T1-weighted MRI scan of the patient showing the contrast enhancing mass lesion in the sella turcica, sphenoid sinus and extending toward the frontal lobe.

Histopathological examination of the specimen confirmed the diagnosis of follicular thyroid carcinoma metastasis. Small follicles filled with colloid were observed in the tumor specimens after applying hematoxylin and eosin (Figure 2A). Immunoperoxidase staining of tumor cells showed thyroglobulin immunopositivity which confirmed the thyroid origin of the tumor (Figure 2B).

After the operation, the patient underwent evaluation of thyroid gland with ultrasound which revealed calcified semisolid nodules in the thyroid lobes. The patient was referred to the department of surgery and she underwent radiotherapy and chemotherapy following total thyroidectomy. She is still alive without recurrence at the time of this writing.

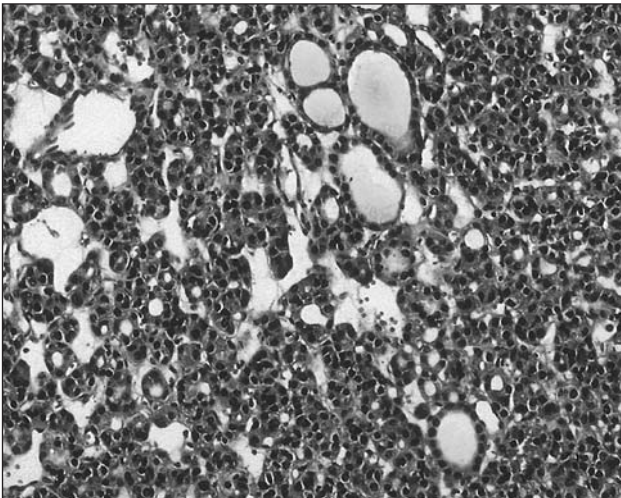


Figure 2A: Metastatic malignant tumoral lesion excised from frontal lobe showing small follicles with colloid. (Hematoxylin&Eosin, X100)

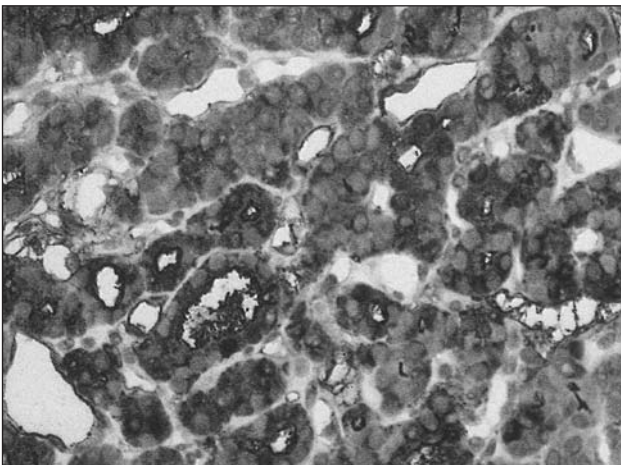


Figure 2B: Thyroglobulin immunopositivity of the metastatic tumor cells confirmed the thyroid origin. (Immunoperoxidase stain, X200)

DISCUSSION

The intracranial compartment is a common site of metastatic cancer. The importance of intracranial metastasis is, however, not primarily due to its frequent occurrence but to the fact that the large majority of the new foci become symptomatic. Compared with the other organs, such as the lung and liver, in which the incidence of metastasis is even higher, the manifestations of metastases affecting the brain are usually more overt and disabling and if untreated, tend to be rapidly lethal. For these reasons, brain metastasis demands prompt diagnostic and therapeutic attention (4).

Approximately 16 to 18 percent of cancer patients develop brain metastases, and intracranial metastases represent the only site of cancer in about 9 percent. Because of their prevalence or unusual frequency, brain metastases originating from cancer of the lung, breast, colon and kidney and from melanoma are of special interest (8). Metastasis from thyroid carcinoma is rare and represents 0.1-5% of cases in reported series (1, 2, 5).

Thyroid carcinoma may be classified into two types, depending upon whether the lesion arises in the thyroid follicular epithelium or from the parafollicular or C cells. The carcinomas of follicular epithelium are classified into three groups according to the histological differentiation as follows: papillary carcinoma, follicular carcinoma and anaplastic carcinoma. Follicular carcinoma histologically mimics normal thyroid tissue. This lesion usually undergoes early hematogenous spread and the patient may present with a distant metastasis, usually in the lung or bone (13). This type of carcinoma is generally seen in the elderly females, primarily having longstanding non-toxic multinodular goitre (50.2%), solitary thyroid nodule (44.2%) and rarely in patients with endemic goitre (9). Neoplasm is probably induced by chronically elevated thyroid-stimulating hormone (TSH) levels. Follicular carcinoma in patients over 45 years of age has a more aggressive course.

All follicular neoplasms should be regarded as potential malignant. 2-5% of the follicular neoplasms have distant metastases outside the neck and mediastinum at the time of diagnosis. Metastatic potential is generally a function of primary tumor size and is common in tumors with gross breaching of tumor pseudocapsule or extensive involvement of blood vessels (major capsular invasion). There are

few reported cases of follicular carcinoma with soft tissue metastasis and initial presentation may very rarely be in the form of a soft tissue metastasis (12).

Yodonawa et al. reported a case of brain metastasis of follicular carcinoma of the thyroid gland in 1987 and they emphasized the meningioma-like radiological features of this rare tumor (14). Tagle et al. also reported 4 cases of isolated meningeal metastasis which were considered meningioma as the main preoperative diagnosis. One of their cases was a thyroid carcinoma metastasis (11). Recently, McWilliams et al. published the largest series of metastatic thyroid carcinoma to the brain with 16 patients and 2 of them were diagnosed as follicular carcinoma. Their results showed that surgical resection of brain metastases was associated with a trend toward longer survival. The average survival after the diagnosis of brain metastasis was 17.4 months in this study. The results of this study also indicated that local treatments appear to control brain metastases in the large majority of thyroid carcinoma patients with metastases to the brain (6). Pak et al. studied the impact of metastasectomy on the outcome of thyroid carcinoma and they stated that the extensive targeted metastasectomy in the setting of a tertiary center can be beneficial to patients with disseminated thyroid carcinoma with persistent or recurrent distant disease, when used in conjunction with non-surgical treatment modalities (7). Rosahl et al. reported a case of solitary FTC of the skull base and they applied galectin to differentiate between ectopic thyroid adenoma and carcinoma. They performed I131 internal radiation and TSH suppression therapy following surgery and emphasized that the prognosis is by far not as poor as in brain metastases and appears to depend largely on location, size and histological appearance (10). We also performed radiotherapy and chemotherapy for the thyroid carcinoma following surgery.

Most of these tumors can be "very" or "extremely" vascular at the time of surgery or imaging may demonstrate evidence of hemorrhage (6). In our patient, there was no sign of bleeding in the preoperative imaging studies and no vascular structures were observed during the operation.

In conclusion, FTC is the rare tumor that may presents with cerebral metastasis and thyroid carcinomas must always kept in mind in the differential diagnosis of contrast-enhancing mass lesions of the brain, especially meningiomas.

REFERENCES

1. Cha ST, Jarrahy R, Mathiesen RA, Suh R, Shahinian HK: Cerebellopontine angle metastasis from papillary carcinoma of the thyroid. *Surg Neurol* 54: 320-326, 2000
2. Chiu AC, Delpassand ES, Sherman SI: Prognosis and treatment of brain metastases in thyroid carcinoma. *J Clin Endocrinol Metab* 82: 3637-3642, 1997
3. Fraker DL, Skarulis M, Livolsi V: Thyroid tumors. In: DeVita VT Jr et al. (eds). *Cancer, Principles and Practice of Oncology*, 5th edition Philadelphia: Lippincott Williams&Wilkins, 1997: 1629-1652
4. Galicich JH, Arbit E, Wronski M: Metastatic brain tumors. In: Wilkins RH, Rengachary SS (eds): *Neurosurgery*; McGraw-Hill, New York, 1996: 807-821
5. Lin CK, Lieu AS, Howng SL: Hemorrhagic cerebellar metastasis from papillary thyroid carcinoma. *Kaohsiung J Med Sci* 15: 234-238, 1999
6. Mc Williams RR, Giannini C: Hay ID, Atkinson JL, Stafford SL, Buckner JC. Management of brain metastases from thyroid carcinoma: a study of 16 pathologically confirmed cases over 25 years. *Cancer* 98: 356-362, 2003
7. Pak H, Gourgiotis L, Chang WI, Guthrie LC, Skarulis MC, Reynolds JC, Merino MJ, Schrupp DS, Libutti SK, Alexander HR Jr, Sarlis NJ: Role of metastasectomy in the management of thyroid carcinoma: the NIH experience. *J Surg Oncol* 82; 8-10, 2003
8. Posner JB, Chernik NL: Intracranial metastases from systemic cancer. *Adv Neurol* 19; 579-592, 1978
9. Rao RS, Parikh HK: Prognostic factors in well-differentiated carcinoma of thyroid. In: Shah DH, Samuel AM, Rao RS (eds). *Thyroid Cancer-An Indian Perspective*. Mumbai. Quest Publications, 1998: 443-450
10. Rosahl SK, Erpenbeck V, Vorkapic P, Samii M: Solitary follicular thyroid carcinoma of the skull base and its differentiation from ectopic adenoma-review, use of galectin and report of a new case. *Clin Neurol Neurosurg* 102: 149-155, 2000
11. Tagle P, Villanueva P, Torrealba G, Huete I: Intracranial metastasis or meningioma? An uncommon clinical diagnostic dilemma. *Surg Neurol* 58: 241-245, 2002
12. Vittal S: Current concepts in the malignancy of thyroid. In: Gupta RL (ed). *Recent Advances in Surgery-7*. New Delhi, Jaypee Brothers, 2000: 152-158
13. Wartofsky L, Ingbar SH. Diseases of the thyroid. In: Wilson JD, Braunwald E, Isselbacher KJ, Petersdorf RG, Martin JB, Fauci AS, Root RK. (eds): *Harrison's Principles of Internal Medicine*. 12th edition. McGraw-Hill, New York, 1991: 1692-1712
14. Yodonawa M, Tanaka S, Kohno K, Ishii Z, Tamura M, Ohye C: Brain metastasis of follicular carcinoma of the thyroid gland. Meningioma-like features demonstrated by CT scan and cerebral angiography: case report. *Neurol Med Chir (Tokyo)* 27: 995-999, 1987