

Intracranial Symptomatic Giant Arachnoid Cyst of the Interhemispheric Fissure Presenting With Frontal Lobe Syndrome

ABSTRACT

Symptomatic interhemispheric arachnoid cysts (ACs) are extremely rare lesions seen more frequently in the elderly. Only 13 cases of symptomatic interhemispheric ACs in the elderly have previously been reported. Herein, we describe a 70-year-old female with symptoms of vertigo, memory and behavior disturbances. Magnetic resonance imaging (MRI) revealed a giant arachnoid cyst (AC) on the interhemispheric fissure, which was exerting a mass effect and displacement on the corpus callosum and anterior cerebral vessels, with a massive midline shift. The patient was treated with a cysto-peritoneal shunt. Reports to date have reviewed the pathology, clinical presentation, radiology and surgical management of interhemispheric symptomatic arachnoid cysts in elderly patients.

KEY WORDS: Arachnoid Cyst, Giant, Interhemispheric Fissure, Intracranial, Frontal Lobe Syndrome, Symptomatic.

INTRODUCTION

Arachnoid cysts (AC) are congenital, fluid-filled compartments within the cerebrospinal fluid (CSF) cisterns and major cerebral fissures such as middle fossa, cerebral convexity and in the posterior fossa, intimately bordered by the arachnoid membrane [5]. They are filled with clear, colorless fluid almost identical to CSF [5].

The incidence of AC is low and accounts for approximately 1% of all intracranial masses [5-11, 20-22]. Autopsy reports estimate approximately 0.1–0.7% exposure to this disorder at the time of death. Although most ACs occur in the sylvian fissure, approximately 5% are located in the convexity or interhemispheric fissure (rare localization). To our knowledge, only 13 cases of symptomatic interhemispheric ACs in adults have been reported to date [8-10, 12, 15, 19-23] (Table I). According to the literature, it is highly probable that patients are suffering from an AC when an interhemispheric cyst without agenesis of the corpus callosum occurs in adults [1, 17, 18, 22]. The management of symptomatic interhemispheric AC in elderly patients is herein described.

CASE REPORT

A 70-year-old female suffering from chronic nonspecific headaches, acute vertigo and memory disturbances was admitted to a psychiatric clinic, a month prior to examination at our institution. There was no medical history of cerebral trauma. A cranial MRI was performed and

Kadir KOTIL
Nurgül BALCI
Turgay BILGE

Haseki Educational and Research
Hospital, Neurosurgery,
Istanbul, Turkey

Received : 28.02.2007

Accepted : 14.05.2007

Correspondence address:

Kadir KOTIL

Haseki Educational and Research
Hospital, Neurosurgery, Istanbul, Turkey
E-mail : kadirkotil@gmail.com

Table I: Symptomatic Interhemispheric Arachnoid Cyst in the Elderly

Author (year)	Age/Sex	Symptom	Course (month)	Site	Corpus callosum	Surgery	Complication	Outcome
1. Jakubiak (1967)	32/M	General convulsion	12mo	Right	Normal	Direct	Postoperative convulsion	Excellent
2. Matsuda (1982)	52/M	Left Hemiparesis	3mo	Right	Normal	Direct	Hemiparesis	Good
3. Hirohata (1992)	58/M	Gait Disturbance	24 mo	Bilateral	Normal	Direct	Postoperative convulsion	Excellent
4. Hirohata (1992)	66/M	Headache	3mo	Right	Normal	Direct	Postoperative convulsion	Excellent
5. Rivieres (1993)	M60/M	FLS	Unknown	IHF	Normal	Endoscopic	No	Excellent
6. Rivieres (1993)	M 62/M	FLS	6 yr	IHF	Normal	Endoscopic	No	Excellent
7. Watanabe (1994)	68/F	Left Hemiparesis	8 yr	Right	Normal	Direct	No	Excellent
8. Watanabe (1994)	72/F	Left Hemiparesis	10 yr	Right	Normal	Direct	No	Excellent
9. Tomabechi (1999)	54/F	Gait Disturbance	7 mo	Left	Normal	Direct	Restlessness	Excellent
10. Hayashi T. (2001)	64/F	Right leg monoparesia	2 yr	Left	Normal	Direct	No	Excellent
11. Yamasaki (2002)	62/F	Left Hemiparesis	12 yr	Right	Normal	Direct	Asy	Excellent
12. Hishikawa T. (2002)	64/F	Left Hemiparesis	2 yr	Right	No	Direct	No	Excellent
13. Hishikawa T. (2002)	73/F	HA/SD	1yr	Right	No	Direct	No	Excellent
14. Present case (2005)	65/F	Frontal Lobe syndrome	22 mo	Left	Normal	Cysto-Peritoneal Shunt	No	Excellent

Abbreviations: HA; Headache, SD; Speech disorder, PA; Partial agenesis, As; Asymptomatic, IHF; interhemispheric fissure, FLS; Frontal lobe syndrome/

revealed an AC on the left frontal lobe. The patient complained of memory disturbances, in addition to behavioral disturbances including an inability to recall long-known and major details such as her own address, perception difficulties and impaired short- and long-term memory. The patient was admitted to our clinic for evaluation of cerebral interhemispheric AC. An initial neurological examination revealed unilateral papilledema in funduscopy and apraxia of the right hand. The patient showed increased tone in the right-side extremities and deep tendon reflex. Examination of the cranial nerves revealed no abnormalities. The disturbance was very slight compared to the usual symptoms of apraxia and the patient could obey all simple commands given during the evaluation. In addition, she had some symptoms such as decreased spontaneous attention,

perception, initiation, motivation and psychomotor movement. A memory evaluation using the Wechsler Memory Scale-Revised (WMS-R) test measured her verbal and visual memories before surgery. The verbal memory (VEM) score (45 points) was lower than the visual memory (VIM) score (55 points) with general memory (GM) 100 points and delayed recall (DR) 85 points. These findings indicated her behavior disturbance was due to memory dysfunction. A subsequent MRI revealed a left cystic lesion which was believed to be compressing and shifting the contralateral hemisphere (Figure 1A, B). Cyst dimensions were as follows: 61x65x69 mm. The mass of the AC was believed to be the reason for the symptoms. An MRI (T1-weighted sagittal view) showed displacement of the anterior body of the corpus callosum (Figure 2)

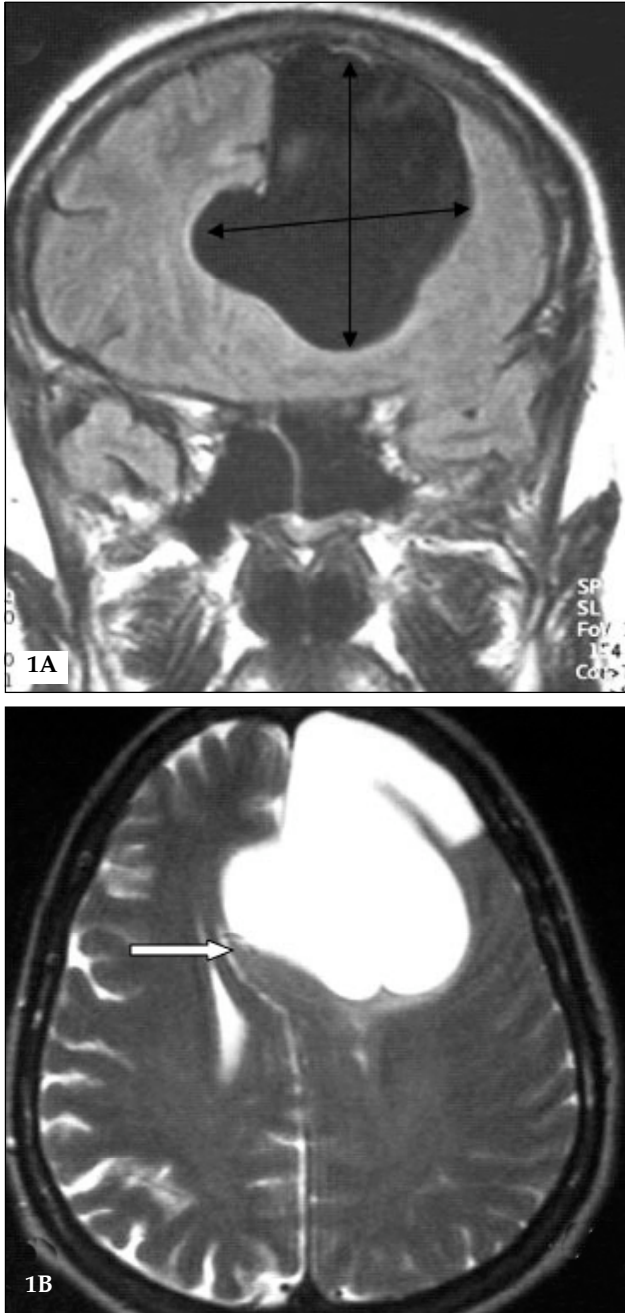


Figure 1: A subsequent MRI revealed a left cystic lesion which was believed to be compressing and shifting the contralateral hemisphere (Fig. 1A, B).

The patient experienced myocardial ischemia, thus, minimum invasive surgery (cysto-peritoneal shunting) was performed with a duration time of 40 minutes. The findings did not indicate any evidence of a previous haemorrhage.

An early postoperative evaluation (patient attention, perception, and memory dysfunction) was excellent and it appeared that the patient made a full

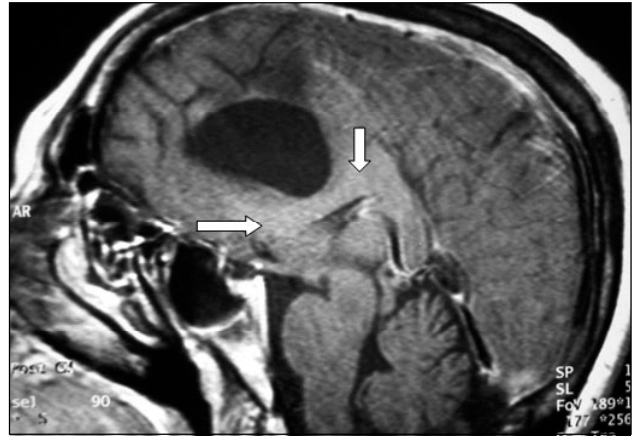

Figure 2: An MRI (T1-weighted sagittal view) showed displacement of the anterior body of the corpus callosum. Cyst dimensions were as follows: 61x65x69 mm. The mass of the AC was believed to be the reason for the symptoms.

memory recovery. Verbal communication was excellent. However, neuropsychiatric abnormalities were observed. A neuropsychological evaluation of memory using the WMS-R test was performed, 10 days postoperatively, the VEM score had improved to 75 points, VIM to 85 points, GM to 155 points, and DR to 98 points. Computed tomography revealed decompression of the left frontal lobe and all behavioral and vertiginous disturbances completely resolved. The shunt catheter tip was visualized in the remnant cystic area (Figure 3) and the patient had fully recovered at discharge.

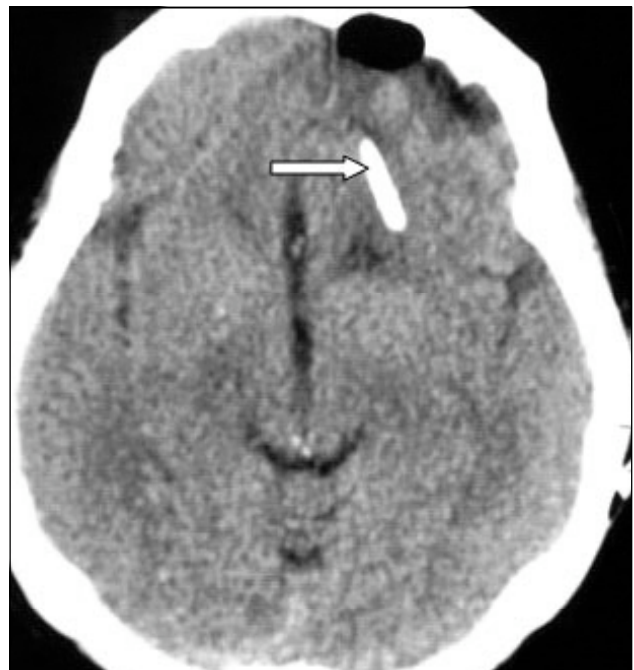

Figure 3: A postoperative CT showed the shunt catheter tip in the remnant cystic area.

A CT scan was normal at 14 months postoperatively and the patient appeared healthy with no clinical complaints.

DISCUSSION

The interhemispheric fissure is an uncommon site for benign intracranial cysts [14, 21]. All intracranial ACs are associated with a normal subarachnoid cistern. An interhemispheric AC is located in the region of the pericallosal cistern [1, 2, 4, 9, 13, 14, 17, 20, 21, 23]. ACs that appear in the temporal area are asymptomatic and do not enlarge; however, these cysts may enlarge and/or may be symptomatic in the vertex region [14] as in the present case.

The most important characteristics of these cases is that none of them have been associated with agenesis of the corpus callosum, whereas interhemispheric ACs in infants, as well as interhemispheric neuroepithelial cysts, ependymal cysts, and colloid cysts, which occur predominantly in children, are always described in association with complete or partial agenesis of the corpus callosum [4, 9, 18-23]. Therefore, it is highly likely that an interhemispheric cyst without agenesis of the corpus callosum in an adult is an AC.

Symptoms of interhemispheric ACs in the elderly include headache, seizure, motor disturbances and neuropsychological dysfunction especially with large and shifted cysts. Thirteen cases of symptomatic interhemispheric ACs in adults have previously been reported and have had neurological deficits such as paraparesis and hemiparesis at onset [6, 8, 9, 12, 19-23]. In elderly patients, the symptoms are usually headache, hemiparesis, gait disturbance and dementia, which are similar to symptoms of chronic subdural hematoma and normal pressure hydrocephalus [16].

A neuropsychometric evaluation on our patient using the psychometric test revealed a low score, indicating disturbance of the dominant hemisphere [23]. We therefore suspected that the left frontal AC was compressing the bilateral frontal lobe, causing ischemia which might have induced the memory dysfunction. Functional disorders of the dominant frontal lobe occasionally cause apraxia [5]. Apraxia is usually caused by a lesion in the dominant hemisphere. Left supramarginal gyrus, the corpus callosum, the area in front of the motor cortex and interconnecting fibres seem to play an essential part in the reproduction of acquired movement [6, 8, 9,

12, 15-23]. Lesions that sever the decussating fibres that spread throughout the rostrum of the corpus callosum to the right frontal lobe produce apraxia on the left [5]. The patient in the present study demonstrated ideational apraxia, which is an inability to coordinate activities with multiple, sequential movements, such as dressing, eating, and bathing.

The aim of surgical treatment is to reduce the pressure exerted by the AC and adjacent brain structures. The techniques for cyst surgery include craniotomy and cyst wall excision [9, 12, 19-23], stereotactic cyst aspiration [22], shunting of cystic fluid to the peritoneal cavity [3, 5], and endoscopic fenestration [11, 14] of cysts to the subarachnoid space or the ventricles. No single surgical technique has proved universally successful in the management of interhemispheric cysts [5, 9, 12, 20]; however, we treated the patient with cysto-peritoneal shunt placement. After shunt placement, displaced cortex and midline shift may realign rapidly. Bridging veins stretched along the cyst walls may be injured during catheter placement, leading to intracystic or subdural hemorrhage. Shunt obstruction and shunt infection are further complications of the cysto-peritoneal shunt [3, 23]. However, none of these complications were observed in our patient during a 14-month follow-up period.

Each procedure has distinct advantages and disadvantages. The advantages of cysto-peritoneal shunt placement include the relative simplicity of the procedure and low morbidity associated with fluid diversion. Disadvantages include the numerous complications of CSF shunts (infection, overdrainage, hindbrain herniation, low-pressure headache syndromes, and shunt failure). Cysto-peritoneal shunt procedures have been advocated for the surgical management of interhemispheric ACs [1, 3, 5]. A low-pressure shunt system with a small (approximately 4 cm) intracystic catheter should be used to achieve drainage of the cyst. Direct surgery was performed in 13 previously reported cases of symptomatic ACs. Preoperative neurologic deficits improved right up until discharge, and no patient required further surgery. In contrast to shunting, craniotomy overlying the cyst allows excision of the cyst walls and fenestration of the cyst into the arachnoid cisterns [3, 9, 12, 15-23]. Excellent outcomes have been reported after

endoscopic cyst fenestration [22, 23]. Schroeder et al. [15] used a rigid endoscopic technique for drainage of a sylvian cyst. Complications of direct surgery for interhemispheric ACs in the elderly include postoperative seizures and temporary worsening of hemiparesis [23]. Considerable controversy exists regarding the preferred intervention.

In conclusion, no single surgical technique has proved universally successful in the management of interhemispheric ACs. Cases similar to our case have previously been reported in the literature, but our case was operated by the cysto-peritoneal shunt procedure for the first time. We believe long-term follow-up and serial imaging studies are necessary in these patients.

REFERENCES

- Banson DF, Geschwind N. The aphasia and related disturbance, in Baker AB, Baker LH(eds): clinical Neurology, 1:8. Philadelphia, New York, Harper&Row Publisher, 1980 16-20
- Choi J, Kim D. Pathogenesis of arachnoid cyst: congenital or traumatic? *Pediatr Neurosurg* 1998;29:260-266
- Ciricillo SF, Cogen PH, Harsh GR, Edwards MS. Intracranial arachnoid cysts in children. A comparison of the effects of fenestration and shunting. *J Neurosurg.* 1991;74(2):230-5
- Coffey RJ, Lunsford LD. Supracallosal interhemispheric arachnoid cysts: resolution after intracystic hemorrhage and infection. *Surg Neurol* 1988;29:153-8
- Hirohata M, Matsuo H, Miyagi J. Interhemispheric arachnoid cyst; report of three cases] *No Shinkei Geka.* 1992;20(6):701-5. Review. Japanese
- Jakubiak P, Dunsmore RH, Beckett RS. Supratentorial brain cysts. *J Neurosurg.* 1968; 28(2):129-36
- Kanev P.M. Arachnoid cyst, in Youmans JR, (ed): Neurological surgery, ed 3, vol 3, Chapter208, Philadelphia, WB Saunders, 2004, pp;3289-99
- Matsuda M, Hirai O, Munemitsu H, Kawamura J, Matsubayashi K. Arachnoid cysts--report of two adult cases in the interhemispheric fissure and over the cerebral convexity. *Neurol Med Chir (Tokyo).* 1982;22(1):71-6
- Okura A, Noguchi S, Yuge T. A case of convexity arachnoid cyst associated with chronic subdural hematoma and intracystic hemorrhage] *No Shinkei Geka.*1994;22(3):273-7. Japanese
- Raeder MB, Helland CA, Hugdahl K, Wester K. Arachnoid cysts cause cognitive deficits that improve after surgery. *Neurology.* 2005;11;64(1):160-2
- Rao G, Anderson RC, Feldstein NA, Brockmeyer DL. Expansion of arachnoid cysts in children: report of two cases and review of the literature. *J Neurosurg.* 2005;102(3 Suppl):314-7
- Rengachary SS, Watanabe I, Brackett CE. Pathogenesis of intracranial arachnoid cysts. *Surg Neurol.* 1978;9(2):139-44
- Rivierez M. Treatment of frontal interhemispheric arachnoid cysts by fenestration of the lamina terminalis. *Neurochirurgie.* 1993;39(5):311-4. French
- Santamarta D, Aguas J, Ferrer E. The natural history of arachnoid cysts: endoscopic and cine-mode MRI evidence of a slit-valve mechanism. *Minim Invasive Neurosurg.* 1995;38(4):133-7. Review
- Schroeder HWS, Gaab MR, Niendorf WR. Neuroendoscopic approach to arachnoid cysts. *J Neurosurg* 1996;85:293-8
- Shuangshoti S, Roberts MP, Netsky MG. Neuroepithelial (colloid) cysts: pathogenesis and relation to choroid plexus and ependyma. *Arch pathol.* 1965 sep;80:214-24
- Solt LC, Deck JH, Baim RS, TerBrugge K. Interhemispheric cyst of neuroepithelial origin in association with partial agenesis of the corpus callosum. Case report and review of the literature. *J Neurosurg* 1980 Mar; 52 (3):399-403
- Tohma Y, Hasegawa M, Nakau H. Obstructive hydrocephalus associated with arachnoid cyst in the elderly. *J Clin Neurosci.* 2004;1(5):542-4
- Tomabechi M, Takano K, Suzuki N. A case of symptomatic interhemispheric arachnoid cyst in the elderly] *No Shinkei Geka.* 1999;27(4):377-81. Japanese
- Tsurushima H, Harakuni T, Saito A. Symptomatic arachnoid cyst of the left frontal convexity presenting with memory disturbance--case report. *Neurol Med Chir (Tokyo).*2000; 40(6):339-41
- Watanabe M, Kameyama S, Takeda N. Two cases of symptomatic interhemispheric arachnoid cyst in the elderly. *Surg Neurol.* 2004; 42(4):346-51
- Wester K. Peculiarities of intracranial arachnoid cysts: location, sidedness, and sex distribution in 126 consecutive patients. *Neurosurgery.* 1999; 45(4):775-9
- Yamasaki F, Kodama Y, Hotta T, Taniguchi E, Eguchi K, Yoshioka H, Arita K, Kurisu K. Interhemispheric arachnoid cyst in the elderly: case report and review of the literature. *Surg Neurol.* 2003;59(1):68-74