

# Rapidly Resolution of Interhemispheric Acute Subdural Hematoma: Case Report & Literature Review

## İnterhemisferik Akut Subdural Hematomun Hızlı Rezolüsyonu: Olgu Sunumu ve Literatürün Gözden Geçirilmesi

### ABSTRACT

Acute subdural hematoma (ASDH) is a neurosurgical emergency. Spontaneous resolution of acute subdural hematoma is extremely rare and the mechanisms are still unclear. However, several mechanisms of spontaneous resolution of acute subdural hematoma have been reported. We have witnessed a patient with a spontaneously resolved subdural hematoma within 14 hours after the initial diagnosis by cranial CT that had been performed just 1 hour after a traffic accident. To our knowledge, a rapid resolution like this has been reported for 36 cases previously. In this article, we report a patient with a rapidly spontaneous resolution of ASDH. We discussed resolution of ASDH mechanisms and also review the literature.

**KEY WORDS:** Acute subdural hematoma, mechanism, rapid resolution

### ÖZ

Akut subdural hematom (ASDH) nöroşirurjinin acillerinden biridir. ASDH spontan rezolüsyonu çok nadir görülür ve mekanizması hala belirgin değildir. Buna rağmen ASDH spontan rezolüsyonuna ait bir çok mekanizma rapor edilmiştir. Trafik kazası geçiren bir hastaya olaydan bir saat sonra çekilen ilk CT de tespit edilen interhemisferik ASDH'nın 14 saat sonra çekilen CT ise spontan rezolüsyonunu saptadık. Bizim bilğimiz dahilinde bu kadar hızlı rezolüsyonu olan 36 hasta daha önceden yayınlanmıştır. Biz bu makalede, hızlı rezolüsyona uğrayan ASDH bir hastayı sunduk. ASDH rezolüsyon mekanizmasını tartıştık ve literatürü gözden geçirdik.

**ANAHTAR SÖZCÜKLER:** Akut subdural hematom, hızlı rezolüsyon, mekanizma

Cem Atilla GÖKDUMAN  
A. Celal İPLİKÇIOĞLU  
Murat COŞAR  
Sirzat BEK  
Mahmut ASLAN  
Aykan GÜLEROĞLU

Neurosurgery Clinic, Okmeydanı Teaching Hospital, Istanbul, Turkey

Received : 04.04.2005

Accepted : 09.06.2005

Correspondence address:

**Cem Atilla GÖKDUMAN**  
Talatpaşa Mah. Basıççek Sokak 15/8  
Okmeydanı/Istanbul, Turkey  
Phone : +90 212 2210947  
E-mail : drcemg@yahoo.com

## INTRODUCTION

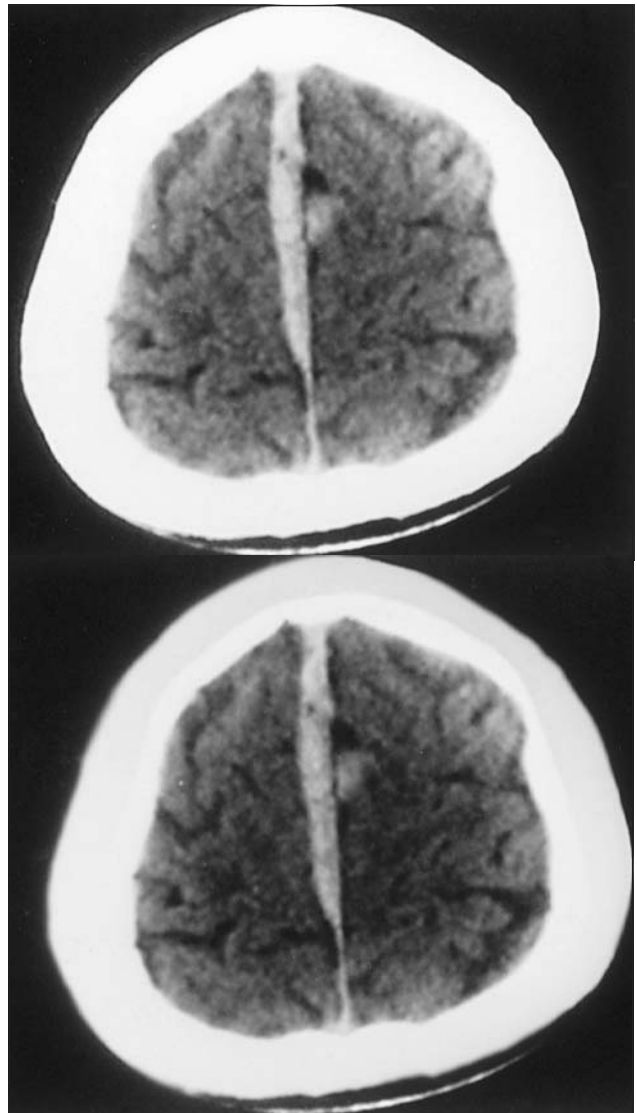
Acute subdural hematoma (ASDH) is a collection of fresh blood under the dura, often large enough to compress the brain (4, 28). It is a common occurrence in patients with severely head-injury and a significant cause of morbidity and mortality (4, 28). Most ASDH patients presenting to the emergency department with altered consciousness experience progressive deterioration of their neurosurgical status unless the hematoma is promptly evacuated by surgery (26). Interhemispheric ASDH is usually caused by head injury and the site of the injury is posterior in the majority of cases (12). The hematoma occurs from bridging veins between the parieto-occipital cortex and superior sagittal sinus or between the falx cerebri and the medial surface of the cerebral hemispheres (12). The natural history of ASDH is not fully understood because of the early surgical intervention (2, 8, 10). Only 37 cases including the present case showing spontaneous resolution of ASDH have been reported (1-11, 14-18, 20-25, 27, 28). Except for two cases including ours which were localized interhemispherically (17), all other cases were localized in the convexity of the cerebral hemispheres. Several mechanism of resolution of ASDH have been reported. The mechanism of ASDH resolution is still unclear (1-10, 27, 28). In this article, we report a patient with rapid and spontaneous resolution of ASDH by discussing the resolution mechanisms with a review of the literature.

## CASE REPORT

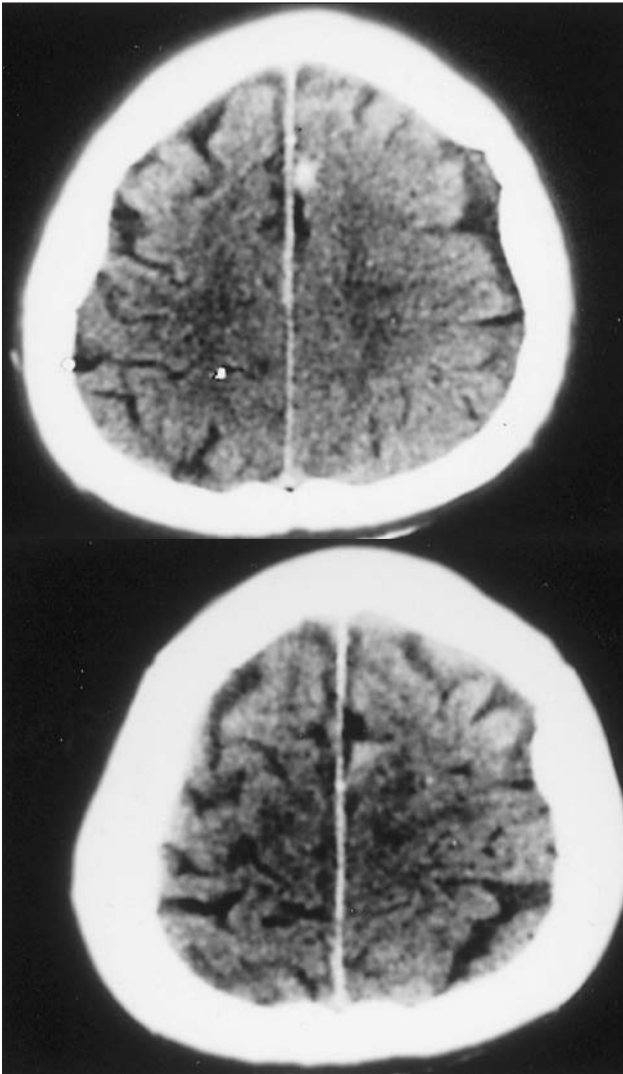
A 55-year-old, previously healthy man was involved in a traffic accident and was hit on his head. He was brought to the emergency department. Routine laboratory examination (including coagulation studies) results were normal. Physical examination was normal, except for ecchymosis on the left leg. Neurological examination was normal but there was vomiting and severe headache. However, his Glasgow Coma Scale (GCS) score was 15.

The plain films of the skull were normal. Initial cranial computed tomography (CT) was performed one hour after the injury. CT revealed an ASDH on both interhemispheric regions without cerebral contusion and brain swelling (Figure 1). Considering these findings, surgery was not planned but the patient was kept under close observation. During

this period, a 250 mg dose of methylprednisolone and osmotherapy (20 % mannitol 1-2gr/kg ) were administered to the patient for the continuous headache, nausea and vomiting. The clinical course was uneventful. A follow-up CT scan was performed 14 hours after the initial CT. We were surprised to observe that the ASDH was vanished (Figure 2). Another follow-up CT scan taken 24 hours after the initial CT showed complete resolution of the interhemispheric ASDH. The patient was discharged on the 4th day without any neurological deficit.



**Figure 1:** Axial CT scan performed 1 hour after the accident revealing interhemispheric acute subdural hematoma



**Figure 2:** Axial CT scan had taken 14 hours after the first CT scan. Interhemispheric acute subdural hematoma has almost completely resolved

### DISCUSSION

Traumatic ASDH is found in 10-20% of all major cranial trauma cases (4, 28). The morbidity and mortality rate of ASDH is about 60-80% in all cases (19, 20). The most common sites for ASDH are the fronto-parietal convexities, the middle cranial fossa and the interhemispheric fissure (12, 28).

With development of neuroradiological techniques such as CT and MRI, a subgroup of subdural hematoma patients are easily detected. Before the advance of CT it was difficult to detect an interhemispheric ASDH (4, 12, 28). CT findings of ASDH are a hyperdense crescent-shaped collection lying between the inner table of the skull and cerebral hemisphere. MRI has the advantage over

CT due to the absence of beam-hardening and multiplanar imaging (15, 28).

ASDH is a neurosurgical emergency. The true incidence of rapid resolution and redistribution of ASDH is underestimated, as most cases will undergo urgent neurosurgical intervention (28). In carefully selected patients ASDH resolves rapidly as a result of intracranial redistribution and close observation of the patient's neurosurgical status obviates the need for emergency surgery (11).

Only 37 (including the present case) cases of ASDH showing rapid spontaneous resolution have been reported since 1985 (Table 1)(1-13, 14-18, 20-25, 27, 28).

The resolution time of the 37 reported cases is between 2 hours and a week. There was no age and sex bias. However 21 patients were male and 16 patients were female. The youngest was 3 years old and the oldest was 87 years old. Eighteen of the cases had resolved in 24 hours. Only 5 cases had remarkable diseases in their past history such as diabetes mellitus (one case), Klippel-Weber Syndrome (one case), cerebral atrophy (two cases), AIDS and cerebral atrophy (one case) and cirrhosis (one case). 35 cases of ASDH were located in the convexity and 2 cases were located interhemispherically. Our case is the second interhemispheric case. 9 cases had signs of herniation (3, 10, 14, 16, 18, 20, 22, 23, 27).

It is difficult to explain the mechanism of rapid resolution of ASDH. Several possible mechanisms for the spontaneous resolution have been reported (Table 2) (2, 6, 8, 20-23).

The reported mechanisms for the spontaneous resolution of ASDH are;

1- Dilution of the hematoma by cerebrospinal fluid (CSF) due to tearing of the arachnoid membrane followed by wash out .

2- Compression of the hematoma by acute brain swelling followed by redistribution.

3- Dura mater tears or skull fractures may allow the clot to be pushed into the diploic bone of the skull or soft tissues.

4- Cerebral atrophy may facilitate accommodation and redistribution of ASDH.

5- The potential for communication between intracranial and epicranial hematomas through a fracture.

6- ASDH resolution has been attributed to intracranial redistribution of hematoma.

**Table 1:** Summary of 37 cases of Rapid spontaneous resolution of ASDH

	NAME	YEAR	AGE/SEX	PREVIOUS HISTORY	INTERVAL	DIAGNOSTIC METHOD
1	Makiyama	1985	17 F	-----	11 hours	CT
2	Nagao	1986	3 F	Klippel Weber	16 hours	CT
3	Polman	1986	26 F	-----	6 hours	CT, MRI
4	Shiokova*	1987	22 M	-----	2 hours	CT
5	Shiokova*	1987	23 F	-----	4 hours	CT
6	Shiokova*	1987	47 F	-----	6 hours	CT
7	Niikawa	1989	63 M	Cirrhosis	24 hours	CT, Angiography
8	Niikawa	1989	48 M	-----	6 hours	CT
9	Niikawa	1989	27 F	-----	6 hours	CT
10	Niikawa	1989	16 M	-----	4 hours	CT
11	Arai	1990	8 M	-----	3 days	CT
12	Arai	1990	8 M	-----	6 hours	CT
13	Fujioka	1990	78 M	-----	33 hours	CT
14	Fujioka	1990	84 F	-----	13 hours	CT
15	Aoki	1990	22 M	-----	14 hours	CT
16	Aoki	1990	23 F	-----	6 hours	CT
17	Joki	1992	21 F	-----	8 hours	CT, MRI
18	Joki	1992	23 M	-----	24 hours	CT, MRI
19	Horimoto	1993	21 M	-----	6 hours	CT
20	Kuroiwa	1993	17 M	-----	12 hours	CT
21	Matsuyama	1997	18 M	-----	3 hours	CT
22	Suziki	1998	7 M	-----	3 hours	CT, MRI
23	Suziki	1998	60 M	Diabetes mell.	12 hours	CT, MRI
24	Cohen	1998	27 M	AIDS, CA	12 hours	CT, MRI
25	Abe	1999	87	-----	9 hours	CT
26	Abe	1999	80	-----	24 hours	CT
27	Tsui	2000	54 M	Alcoholism, CA	6 hours	CT, MRI
28	Kimura	2000	88 F	-----	4 days	CT
29	Kato	2001	79 F	-----	12 hours	CT, MRI
30	Kato	2001	41 F	-----	12 hours	CT, MRI
31	Portales	2002	48 M	Alcoholism, CA	18 hours	CT
32	Rivas	2002	87 F	-----	72 hours	CT
33	Inamasu	2002	16 M	-----	2 days	CT
34	Imai	2003	83 F	Asthma, CVA	1 week	CT
35	Berker	2003	57 M	-----	2 hours	CT
36	Bartolotti	2004	23 F	-----	12 hours	CT
37	Present Case	2004	55 M	-----	14 hours	CT

\* Kato (15), Izumihara (13)

**Table 2:** Possible mechanisms for the spontaneous resolution of ASDH

1- Dilution of the hematoma by CSF due to tearing of the arachnoid membrane followed by wash out	Abe, Fujioka, Matsuyama, Nagao, Rivas, Bartoloti, Inamasu, Niikiwa, Suzuki, Joki, Present Case
2- Compression of the hematoma by acute brain swelling followed by redistribution	Joki, Kuroiwa, Makiyama, Niikiwa
3- Duramater tears or skull fractures may allow the clot to be pushed into the diploic bone of the skull or soft tissues	Fujioka
4- Cerebral atrophy may facilitate accommodation and redistribution of ASDH	Cohen, Portales
5- Reasons unknown	Harimato
6- The potential for communication between intracranial and epicranial hematomas through a fracture	Aoki
7- ASDH resolution has been attributed to intracranial redistribution of hematoma	Polman

We consider the first mechanism as the most sophisticated explanation for resolution of ASDH.

However mechanisms for the spontaneous resolution of ASDH are still unclear. Kato (15) and Suzuki (27) emphasized an important detail, and called it a low density band. The low density band between the hematoma and inner wall of the skull bone on the CT represents co-mingling of the hematoma with CSF. The low-density band has been noted in several cases of rapid spontaneous resolution of ASDH (Table 3) (2, 6, 8-10, 16, 18, 22-24, 27, 28). A low-density band was not observed in our cases.

Treatment of ASDH is by surgery or conservative approach. Several authors have advocated immediate decompressive craniectomy in cases of severe head injury involving a midline shift of greater than 5 mm due to an intracranial mass lesion (19, 26). As is well known, the prognosis of surgery is not as good as expected. Conservative treatment of patients with ASDH is certainly not preferable to operative procedures (8, 18). However conservative treatment with careful monitoring is justified in selected patients who show neurological and

radiological improvement (11) or in neurologically stable patients (12). Kato (15) speculated osmotherapy would provide enough space for hematoma to show rapid redistribution. Therefore the most important factor in ASDH resolution appears to be participation of CSF and presence of a wide subdural space in which the hematoma can be redistributed.

**CONCLUSION**

Reported cases of spontaneous resolution of ASDH are extremely rare because of early surgery. Mechanism of spontaneous resolution of ASDH still unknown. Nowadays, surgical treatment is preferable to conservative treatment. However standard procedures for conservative management is unclear. Criteria for conservative management of ASDH is related to many factors. The patient’s age, the size of the hematoma, neurological examination findings, and the cause of the hematoma should be evaluated. We think that osmotherapy is very important for ASDH treatment. Conservative treatment with osmotherapy can be a treatment option for some ASDH cases.

**Table 3:** Site and features of hematoma

	Name	LDB*	Contusion	Brain Swelling	Site of hematoma
1	Makiyama	+	-	+	Convexity
2	Nagao	-	-	-	Convexity
3	Polman	+	+	+	Convexity
4	Shiokova	NA**	-	+	Convexity
5	Shiokova	NA	-	+	Convexity
6	Shiokova	NA	-	+	Convexity
7	Niikawa	+	-	-	Convexity
8	Niikawa	-	+	+	Convexity
9	Niikawa	+	+	-	Convexity
10	Niikawa	+	-	-	Convexity
11	Arai	+	-	-	Convexity
12	Arai	-	-	-	Convexity
13	Fujioka	+	-	-	Convexity
14	Fujioka	+	-	-	Convexity
15	Aoki	+	-	-	Convexity
16	Aoki	+	+	-	Convexity
17	Joki	+	-	+	Convexity
18	Joki	-	-	+	Convexity
19	Horimoto	+	-	-	Convexity
20	Kuroiwa	+	-	+	Interhemispheric
21	Matsuyama	+	-	-	Convexity
22	Suziki	+	-	-	Convexity
23	Suziki	+	+	-	Convexity
24	Cohen	+	-	-	Convexity
25	Abe	+	-	-	Convexity
26	Abe	+	-	-	Convexity
27	Tsui	+	-	-	Convexity
28	Kimura	+	-	-	Convexity
29	Kato	+	-	-	Convexity
30	Kato	+	-	-	Convexity
31	Portales	-	-	-	Convexity
32	Rivas	+	-	-	Convexity
33	Inamasu	-	-	+	Convexity
34	Imai	+	-	-	Convexity
35	Berker	-	-	-	Convexity
36	Bartolotti	-	-	-	Convexity
37	Present Case	-	-	-	Interhemispheric

\* : Low- density band

\*\* : Not available

## REFERENCES

1. Abe T, Imaizumi Y, Mukasa A, Sashida J, Kawamoto S: Acute subdural hematoma with rapid resolution: Report of three cases. *No Shinkei Geka* 8: 675-679, 1999
2. Aoki N: Acute subdural hematoma with rapid resolution. *Acta Neurochir (Wien)*103: 76-78, 1990
3. Arai H, Ohba M, Ohnuma T: Rapid spontaneous resolution of acute infantile subdural hematoma. A report of two cases. *Shoni No No Shinkei* 15: 155-159, 1990
4. Berker M, Gulsen S, Ozcan OE: Ultra rapid spontaneous resolution of acute posttraumatic subdural hematomas in patient with temporal linear fracture. *Acta Neurochir (Wien)* 145: 715-717, 2003
5. Bortolotti C, Wang H, Fraser K, Lanzino G: Subacute spinal subdural hematoma after spontaneous resolution of cranial subdural hematoma causal relationship or coincidence?. *J Neurosurg (Spine4)* 100: 372-374, 2004
6. Cohen JE, Eger K, Montero A: Rapid spontaneous resolution of acute subdural hematoma and HIV related cerebral atrophy. Case report. *Surg Neurol* 50: 241-244, 1998
7. Fernandez-Portales I, Gomez Peral L, Gabezudo JM, Gimenez-Pando J, Figueroa JA: Rapid spontaneous resolution of acute subdural hematoma. *Neurocirugia (Astur)* 13: 491-494, 2002
8. Fujioka S, Hamada J, Kaku M, Ushio Y: Rapid resolution of acute subdural hematoma . Report of two cases .*Neurol Med Chir (Tokyo)* 30: 827-831, 1990
9. Horimoto C, Yamaga S, Toba T, Tsujimura M: A case of acute subdural hematoma with rapid resolution. *Nihon Kyu Iga Zasshi* 17: 864-865, 1993
10. Imai K: Rapid spontaneous resolution of signs of intracranial herniation due to subdural hematoma. *Neurol. Med Chir (Tokyo)* 43: 125-129, 2003
11. Inamasu J, Nakamura Y, Saito R, Kuroshima Y, Mayanagi K: Rapid resolution of traumatic acute subdural hematoma by redistribution. Letter to the editor *Am.J Emerg Med* 20: 376-377, 2002
12. Iplikcioglu AC, Bayar MA, Kokes F, Doğanay S, Gökçek C: Interhemispheric subdural hematomas. *Bri J. Neurosurg* 8: 627-631, 1994
13. Izumihara A, Orita T, Surutani T, Kajiwara K: Natural course of non operative cases of acute subdural hematoma: sequential computed tomographic study in the acute and subacute stages. *No Shinkei Geka* 25: 307-314, 1997
14. Joki T, Hashimoto T, Akachi K, Boku M, Suziki K: Rapid spontaneous resolution of an subdural hematoma: Report of two cases . *No Shinkei Geka* 20: 915-919, 1992
15. Kato N, Tsunoda T, Matsumura A, Yanaka K, Nose T: Rapid spontaneous resolution of acute subdural hematoma occurs by redistribution: Two cases report. *Neurol Med Chir (Tokyo)* 41: 140-143, 2001
16. Kimura H, Nogaki H, Sawa H, Tamaki N: Rapid spontaneous resolution of a severe acute subdural hematoma in elderly woman. *No Shinkei Geka* 9: 561-564, 2000
17. Kuroiwa T, Tanabe H, Takatsuka H, Arai M, Nobuyoshi S: Rapid spontaneous resolution of extradural and subdural hematoma. *J Neurosurg* 78: 126-128, 1993
18. Makiyama Y, Katayama Y, Ueno Y, Koike Y, Tsubokawa T: Acute subdural hematomas spontaneously disappearing within 3 days following closed head injury; report of two cases. *Nihon Uni.J Med* 27:123-127, 1985
19. Maas AIR, Dearden M, Teasdale GM: EBIC-guidelines for management of severe head injury in adults. *Acta Neurochir (Wien)* 139: 286-294, 1997
20. Matsuyama T, Shimomura T, Okumura Y, Sasaki T: Rapid resolution of symptomatic acute subdural hematoma: case report. *Surg Neurol* 48: 193-196, 1997
21. Nagao T, Aoki N, Mizutani H, Kitamura K: Acute subdural hematoma with rapid resolution in infancy: case report. *Neurosurgery* 19: 465-467, 1986
22. Niikawa S, Sugimoto S, Hattori T: Rapid resolution of acute subdural hematoma: Report of four cases. *Neurol Med. Chir (Tokyo)* 29: 446-448, 1989
23. Polman C.H., Gijssbers C.J., Heimans J.J, Ponsen H., Valk J: Rapid spontaneous resolution of an subdural hematoma. *Neurosurgery* 19: 446-448, 1986
24. Portales IF, Peral G, Cabezudo JM, Pando G, Figueroa JA: Rapid spontaneous resolution of acute subdural hematoma. *Neurochirurgia (Astur)* 13: 491-494, 2002
25. Rivas JJ, Dominquez J, Avila AP, Martin V, Reyes A: Spontaneous resolution of an acute subdural hematoma. *Neurochirurgia (Astur)* 13: 486-489, 2002
26. Seelig JM, Becker DP, Miller JD, Greenberg RP, Ward JD: Traumatic acute subdural hematoma. Major mortality reduction in comatose patients treated within four hours. *N Eng J Med* 304: 1511-1518, 1981
27. Suzuki Y, Kawamata T, Matsumoto H, Kunii N, Matsunoto K: A resolving sign of acute subdural hematoma: from report of two cases. *No Shinkei Geka* 26: 1025-1029, 1998
28. Tsui EYK, Ma KF, Cheung YK, Chan JHM, Yuen MK: Rapid spontaneous resolution and redistribution of acute subdural hematoma in a patient with chronic alcoholism: a case report . *Eur J Radiol* 36: 53-57, 2000