

Transcallosal Transbiforaminal Approach to the Third Ventricle

Üçüncü Ventriküle Transkallozal Transbiforaminal Yaklaşım

ABSTRACT

BACKGROUND: Colloid cysts are benign intracranial lesions but can show signs of severe obstructive hydrocephalus and present with sudden death. The approaches to colloid cysts have been described by many authors. The treatment modalities can be classified as endoscopic and microsurgical. Bilateral access through the foramen is commonly used with transcallosal surgery to reach the third ventricle but has never been described. Cystic lesions can be excised safely with both approaches but the excision of a solid lesion is still challenging despite advances in microsurgical techniques.

METHODS: After routine callosotomy, each foramen of Monroe can be identified with the landmarks of the lateral ventricle. The foramens can be widened with limited manipulation. The solid lesion can be excised with limited traction of the third ventricle and surrounding neural structures. Tumor control can be achieved with the biforaminal approach but the tumor excision should be performed from the right foramen due left side forniceal memory dominance

RESULTS: The postoperative period was uneventful, and the patient was discharged without any memory deficit.

CONCLUSION: Manipulation of both fornices increases the risk of significant memory system deficits. Safer and harmless excision can be achieved with the transbiforaminal approach if the tumor excision is performed from the right foramen.

KEYWORDS: Biforaminal, Transcallosal, Third, Ventricle

ÖZ

AMAÇ: Koloid kistler selim lezyonlar olarak bilinmelerine rağmen, akut hidrosefali bulguları ve ani ölüme sebep olabilir. Kolloid kistlere yaklaşım birçok yazar tarafından tanımlanmıştır. Tedavi seçenekleri endoskopik ve mikrocerrahi olarak sınıflandırılmaktadır. Her iki foramenden uygulanan transkallozal bilateral üçüncü ventrikül yaklaşımı birçok cerrah tarafından kullanılmasına rağmen, henüz tanımlanmamıştır. Kistik lezyonlar her iki yaklaşımla da güvenle çıkartılabilesine rağmen, solid lezyonların sağaltımında gelişmiş mikrocerrahi tekniklere rağmen halen zorlanılmaktadır.

YÖNTEMLER: Rutin kallosotomi sonrası her iki foramen Monro lateral ventriküller içinde tanınır. Sınırlı müdahalelerle foramenler genişletilir. Solid lezyon, üçüncü ventrikül ve çevre beyin dokusuna uygulanan sınırlı traksiyonla çıkartılır. Tümör kontrolü her iki formenden sağlanırken, tümörün sağaltımı sol fornixin hafıza baskınlığı nedeniyle sağ foramenden yapılmalıdır.

BULGULAR: Ameliyat sonrası dönemde bir problem yaşanmayan hastada herhangi bir hafıza problemiyle karşılaşılmadı.

SONUÇ: Her iki fornixe yapılan müdahaleler ciddi hafıza bozukluklarına sebep olabilir. Her iki foramen kullanılarak yapılacak yaklaşımlarda, güvenli ve zararsız sağaltım, tümör eksizyonunun sağ foramenden kontrolünün de sol foramenden yapılmasıyla elde edilebilir.

ANAHTAR SÖZCÜKLER: Biforaminal, Transkallozal, Üçüncü, Ventrikül

Ersin ERDOĞAN¹

Tufan CANSEVER²

¹ Gülhane Military Medical Academy, Neurosurgery Department, Ankara, Turkey

² Baskent University, Neurosurgery Department, Istanbul, Turkey

Received : 21.11.2008

Accepted : 18.03.2009

Correspondence address:

Tufan CANSEVER

E-mail: drtufan@gmail.com

BACKGROUND

Lesions that affect the third ventricle include a large variety of benign and malignant tumors and cyst formations (1,2,17,21). Colloid cysts are benign intracranial lesions that account for 0.5 to 1.0% of brain tumors. A few patients, however, have signs of severe obstructive hydrocephalus and present with sudden death (17). Consequently, early detection and treatment are recommended. Although known as cystic lesions, they can also be solid. Any approach through one foramen of Monro can be harmful to the surrounding neural structures. Bilateral access through the foramina is commonly used with transcallosal surgery to reach the third ventricle but has never been described.

METHODS

A bone flap was planned so that one third was posterior to the coronal suture and two thirds anterior to it. Once the dura was separated from the brain to the sagittal sinus, the leading edge of the hemisphere was retracted laterally away from the midline not more than 2 cm.

The cingulate gyrus and sulcus, the corpus callosum, and the pericallosal arteries were identified. A 15-mm long incision through the corpus callosum was made close to a constantly found, unpaired vessel, which runs in the sulcus between the medial longitudinal striae. Once the cavity of one of the lateral ventricles was reached, the entrances to the left foramen of Monro were identified (Figure 1A). The landmarks to identify the foramen were the vein of the septum pellucidum, the thalamostriate vein, and especially the point at which the choroid plexus bends anteriorly and enters the third ventricle (Figure 1A). The settling of the thalamostriate vein with respect to septum pellucidum was also a landmark for the identification of the side of the ventricle. The septum pellucidum was cut along its insertion line to the corpus callosum. The landmarks were also identified on the right side (Figure 1B). The left septal vein was coagulated and cut to protect the thalamostriate vein by the retraction of foramen of Monro during the dissection of the cyst (Figure 1C). The septum was separated behind the midpoint of the foramen of Monro to protect the fibers in the anterior commissure from stress. The foramina of Monro were dissected towards the velum interpositum medially (Figure 1D). The separation was limited to

1.5 cm to avoid any damage to the fornices and hippocampal commissure. Almost half of the cyst was located posterior to the foramen of Monro and its content was solid (Figure 1E-F-G, 2). The cyst wall and remaining content of the cyst could be pushed from the left foramen and manipulated from the right foramen (Figure 1F).

Debulking of the tumor was performed through the right foramen with a biopsy forceps and suction tip (Figure 1G). The attachments were removed using a microscissor and a microdissector (Figure 1H). After cyst removal, the third ventricle and internal cerebral vein/thalamostriate vein junctions were exposed. Both lateral ventricles and the connections of bilateral foramina of Monro to the third ventricle were easily visualized (Figure 1I).

RESULTS

The postoperative period was uneventful, and the patient was discharged without any memory deficit.

DISCUSSION

The transcallosal biforaminal approach evolved from a desire to perform fine and safer microsurgery in the ventricles and optimal visualization of the most critical anatomy.

Clearly, the other "gold standard" of craniotomy approaches can achieve these goals. However, a surgical pathway of at least 2 cm width is required to maintain stereoscopic vision with excellent lighting using the surgical microscope (7,12). For the interhemispheric, transcallosal approach, this may entail retraction of the frontal lobe and a large callosotomy.

Likewise, transcortical craniotomy requires a significant degree of cortical disruption to position retractors or cylindrical ports of this size. The resection of colloid cysts is possible using much smaller width, retractorless craniotomy pathways (3,4,6,9,14,15).

Furthermore, direct visualization of the tela choroidea (without pulling it into view transforaminally) is often possible only with manipulation of the fornix with either a transchoroidal or interforniceal approach because of the approach angles afforded by the standard craniotomy approaches. Yasargil (27) suggested the fenestration of the septum pellucidum for cerebrospinal fluid drainage if both ventricles are

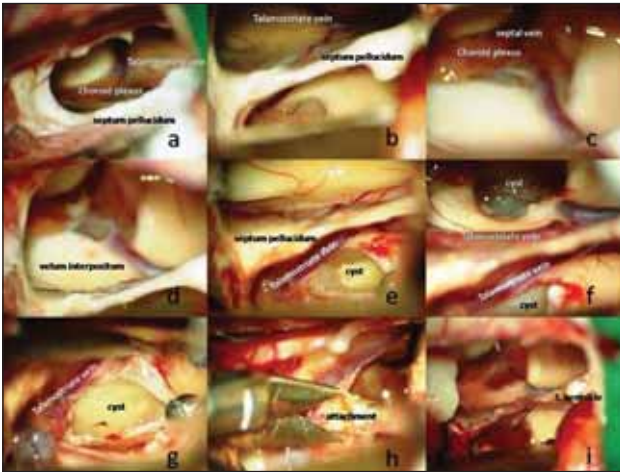


Figure 1: A) The landmarks to identify the foramen were the vein of the septum pellucidum, the thalamostriate vein, and especially the point at which the choroid plexus bends anteriorly and enters the third ventricle.

B) The settling of the thalamostriate vein respect to septum pellucidum was also the landmark to identification of the side of the ventricle.

C) Left septal vein was coagulated and cut to protect the thalamostriate vein by the retraction of foramen of Monro during the dissection of the cyst.

D) Foraminae of Monroe was dissected towards the velum interpositum medially.

E) Almost half of the cyst was located posterior to the foramen of Monro and its content was solid.

F) Cyst wall and rest content of the cyst could be pushed from the left foramen and manipulated from the right foramen.

G) Debulking of the tumor was performed through the right foramen with biopsy forceps and suction tip.

H) The attachments have been removed by a microscissor and a microdissector.

I) Both lateral ventricles and the connections of bilateral foraminae of Monroe to the third ventricle were easily visualized after the total removal of the cyst.

enlarged or bulging of the medial structures obstructed the view during the procedure. In some cases, the cyst attachment can be observed after cyst collapse and drainage using the precoronal approach. However, the retraction and damage of the surrounding structure is unavoidable in cysts with solid content.

Safer and harmless excision can be achieved with a transbiforaminal approach if the tumor excision is performed from the right foramen and tumor extension is controlled from the left foramen.

It is possible to directly and successfully visualize the adherence to the tela choroidea (and other third ventricle structures) of all third ventricle cysts except those with solid content without using the

transchoroidal or interforaminal technique by employing the dual port technique that is used with the frontopolar approach. It may be possible to obtain an adequate view of the roof of the third ventricle in some cases if an extreme lateral, precoronal endoscopic approach is possible. From a technical perspective, the frontopolar approach subjectively provided a more en face view of the foramen of Monro, which facilitated the cyst removal procedure (21).

Clearly, the finesse achievable by one surgeon using both hands exceeds that of two surgeons trying to coordinate movements. Other factors, such as the relative location of the colloid cyst within the third ventricle, should be taken into account when choosing one approach over another. Lastly, collapse of the ventricular “working” space can be problematic with large single-port techniques in which the cerebrospinal fluid is drained before cyst evacuation (4). The collapsed ventricle can be visualized without any harm with the biforaminal approach, and bimanual manipulation makes it easier and safer to evacuate the solid parts of the cyst. Approaches other than the interforaminal or transchoroidal routes have been proposed for visualizing the roof of the third ventricle.

The posterior extent should be no more than 2 cm posterior to the foramen of Monro to avoid injury to the hippocampal commissure (Figure 2). Winkler et al. (23,24) suggested separating the septum pellucidum and fornices posterior to the midpoint of the foramen of Monro to avoid injury to the anterior commissure, which serves as an important connection between the mesial temporal and frontal areas (25, 26). Botez-Marquard and Botez (5) reported deficits in visual retention related to injuries to the anterior commissure and right fornix. Minimizing manipulation of the fornix may reduce the risk of memory deficits. Rosenfeld (19) noted that of 28 patients, 13 had early short-term memory deficits and 3 had a mild degree of short-term memory deficits even 8 to 57 months after surgery. However, the risk of injury to the hippocampal commissure is negligible if dissection is limited to the foramen of Monro.

Horvath et al. (10) described the “radical” removal of three colloid cysts using a dual endoscope, dual-port technique in which one rigid endoscope was placed via a frontopolar burr hole and the second through a contralateral, precoronal

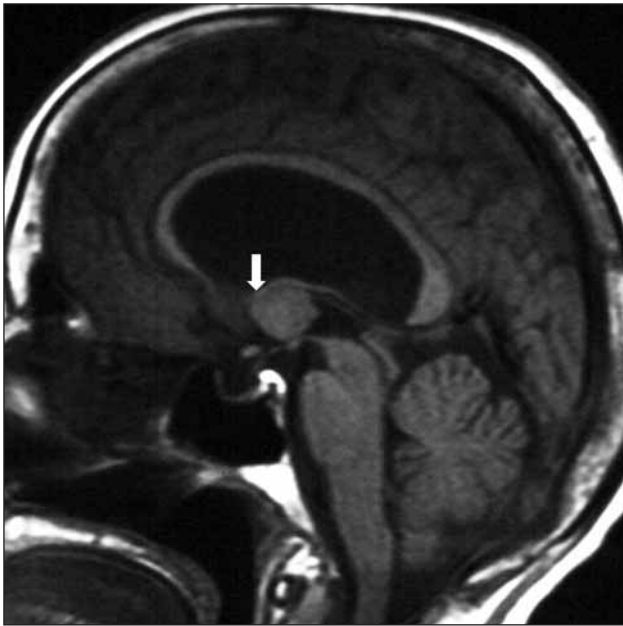


Figure 2: MRI shows almost half of the cyst was located posterior to the foramen of Monro. (White arrow shows the posterior border of the foramen Monro.)

burr hole. Veto et al. (22) described a unilateral, frontopolar-precornal dualport endoscopic approach in which the frontopolar endoscope was used to biopsy malignant lesions located in the posterior third ventricle, whereas the precornal port was used for completion of a third ventriculostomy.

The rationale and possible increased risks associated with previously proposed dual-port neuroendoscopy techniques have been reasonably questioned (2,8). The image quality provided by fiberoptic technology is inadequate to guide fine, microsurgical dissection maneuvers.

The unilateral, dual-port technique described by Bergsneider (4) achieved a gross total resection of the colloid cyst in 10 out of 11 patients. The ability to obtain a complete resection distinguishes the dual-port technique from single-port endoscopy, in which published series report incomplete resection (visible on postoperative imaging) in a significant percentage of patients (18,20). Moreover, the prevalence of coagulated remnant capsules within single-port endoscopy is high (11,13,16,18,20).

CONCLUSION

Transcallosal transbiforaminal approach was planned for the aforementioned patient. The left foramen was exposed first followed by the right

foramen after opening the corpus callosum. The colloid cyst with solid content was evacuated safely. We believe that this technique will be very helpful with a microsurgical approach to solid lesions in the third ventricle. The only disadvantage of this procedure with respect to one-sided approaches can be damage to bilateral fornices that can cause cognitive derangement. Dilatation of the foramens must therefore be done gently, minimally and directed towards the velum interpositum medially. Harm to the fornices can be avoided if the tumor excision can be performed from the right foramen and the tumor extension controlled from the left foramen.

REFERENCES

1. Allen SS, Lovell HW: Tumors of the third ventricle. Arch Neurol Psychiatry 28:990-1006, 1932
2. Apuzzo ML: Endoscopic resection of colloid cysts: Surgical considerations using the rigid endoscope. Neurosurgery 44:1110-1111, 1999
3. Barlas O, Karadereler S: Stereotactically guided microsurgical removal of colloid cysts. Acta Neurochir (Wien) 146: 1199-1204, 2004
4. Bergsneider M: Complete microsurgical resection of colloid cysts with a Dual-Port Endoscopic Technique Neurosurgery; 60 (2 Suppl 1): ONS33-42, 2007
5. Botez-Marquard T, Botez MI: Visual memory deficits after damage to the anterior commissure and right fornix. Arch Neurol 49:321-324, 1992
6. Cabbell KL, Ross DA: Stereotactic microsurgical craniotomy for the treatment of third ventricular colloid cysts. Neurosurgery 38:301-307, 1996
7. Decq P, Le Guerinel C, Brugières P, Djindjian M, Silva D, Kéravel Y, Melon E, Nguyen JP. Endoscopic management of colloid cysts. Neurosurgery Jun;42(6):1288-94,1998
8. Gaab MR, Schroeder HW: Neuroendoscopic approach to intraventricular lesions. J Neurosurg 88:496-505, 1998
9. Harris AE, Hadjipanayis CG, Lunsford LD, Lunsford AK, Kassam AB: Microsurgical removal of intraventricular lesions using endoscopic visualization and stereotactic guidance. Neurosurgery56 (Suppl 1):125-132, 2005
10. Horvath Z, Veto F, Balas I, Doczi T: Complete removal of colloid cyst via CT-guided stereotactic biportal neuroendoscopy. Acta Neurochir (Wien) 142:539-545, 2000
11. Kehler U, Brunori A, Gliemroth J, Nowak G, Delitala A, Chiappetta F, Arnold H: Twenty colloid cysts-comparison of endoscopic and microsurgical management. Minim Invasive Neurosurg 44:121-127, 2001
12. Kelly PJ: Endoscopic management of colloid cysts by Decq et al. J Neurosurg 42:1295, 1998
13. King WA, Ullman JS, Frazee JG, Post KD, Bergsneider M: Endoscopic resection of colloid cysts: Surgical considerations using the rigid endoscope. Neurosurgery 44:1103-1109, 1999
14. Kondziolka D, Lunsford LD: Microsurgical resection of colloid cysts using a stereotactic transventricular approach. Surg Neurol 46:485-490, 1996

15. Lawton MT, Golfinos JG, Spetzler RF: The contralateral transcallosal approach: Experience with 32 patients. *Neurosurgery* 39:729-734, 1996
16. Longatti P, Martinuzzi A, Moro M, Fiorindi A, Carteri A: Endoscopic treatment of colloid cysts of the third ventricle: 9 consecutive cases. *Minim Invasive Neurosurg* 43:118- 123, 2000
17. Pecker J, Guy G, Scarabin J-M: Third ventricular tumours: Including tumours of the septum pellucidum, colloid cysts and subependymal glomerate astrocytoma, in Vinken PJ, Bruyn GW (eds): *Handbook of Clinical Neurology: Tumours of the Brain and Skull-Part II*. vol 17, New York: Elsevier, 1974, pp 440-489
18. Rodziewicz GS, Smith MV, Hodge CJ Jr: Endoscopic colloid cyst surgery. *Neurosurgery* 46:655-660, 2000
19. Rosenfeld JV: James IV Lecture: Epilepsy surgery, hypothalamic hamartomas and the quest for a cure. *J R Coll Surg Edinb* 47:653-659, 2002
20. Schroeder HW, Gaab MR: Endoscopic resection of colloid cysts. *Neurosurgery* 51:1441-1444, 2002
21. Stein BM: Third ventricular tumors. *Clin Neurosurg* 27:315-331, 1980
22. Veto F, Horvath Z, Doczi T: Biportal endoscopic management of third ventricle tumors in patients with occlusive hydrocephalus: Technical note. *Neurosurgery* 40:871-875, 1997
23. Wilson CL, Isokawa M, Babb TL, Crandall PH: Functional connections in the human temporal lobe: Part I—Analysis of limbic system pathways using neuronal responses evoked by electrical stimulation. *Exp Brain Res* 82:279- 292, 1990
24. Wilson CL, Isokawa M, Babb TL, Crandall PH, Levesque MF, Engel J Jr: Functional connections in the human temporal lobe: Part II—Evidence for a loss of functional linkage between contralateral limbic structures. *Exp Brain Res* 85:174-187, 1991
25. Winkler PA, Ilmberger J, Krishnan KG, Reulen HJ: Transcallosal interforaminal-transforaminal approach for removing lesions occupying the third ventricular space: Clinical and neuropsychological results. *Neurosurgery* 46:879-890, 2000
26. Winkler PA, Weis S, Buttner A, Raabe A, Amiridze N, Reulen HJ: The transcallosal interforaminal approach to the third ventricle: Anatomic and microsurgical aspects. *Neurosurgery* 40:973-982, 1997
27. Yasargil MG: *Microneurosurgery; Microneurosurgery of CNS Tumors volume IV B; Craniotomies of individual approaches*. Stuttgart-New York: Georg Thieme Verlag, 1996: 55