

Comparison of the Effect of Mexiletine and Methylprednisolone on Neural Function and Histopathological Damage after Transient Spinal Cord Ischemia in Rabbits

Tavşanlarda Transient Spinal Kord İskemisi Sonrası Gelişen Histopatolojik Hasar ve Nöral Fonksiyon Üzerine Mexiletin ve Metilprednizolonun Etkilerinin Karşılaştırılması

ABSTRACT

AIM: The purpose of this study was to investigate the effect of mexiletine on the neural function and histopathological changes after ischemic spinal cord injury in rabbits. We also compared the effect of mexiletine to that of methylprednisolone.

MATERIAL and METHODS: Twenty six male New Zealand white rabbits were randomly divided into six groups. Group 1; sham operated group (n=3) underwent only the surgical exposure of infrarenal aorta. Group 2 (n=4) received neither intravenous (iv) nor intraperitoneal medication but the infrarenal aorta was cross-clamped. Group 3 (n=5) received intravenous infusion of 20 ml/kg/h normal saline. Group 4 (n=5) received 30mg/kg intravenous methylprednisolone. Group 5 (n=3) received intraperitoneal 20mg/kg/h normal saline. Group 6 (n=6) received 50mg/kg mexiletine intraperitoneally. Temporary spinal cord ischemia was induced by infrarenal aortic occlusion for 25 minutes and followed by reperfusion. The neural status was scored using the Tarlov criteria at 24 hours after reperfusion. Immediately after the neurological scoring, the spinal cords of all animals were removed for histopathological study.

RESULTS: Histopathological examination scores were significantly higher in group 6 compared to group 2 (p<0.05).

CONCLUSION: Mexiletine can significantly ameliorate the neural function and prevent histopathological damage after transient spinal cord ischemia in rabbits. This is the first research that investigates the neuron-protective effect of mexiletine in a spinal cord ischemia model.

KEYWORDS: Spinal cord ischemia, Mexiletine, Methylprednisolone

ÖZ

AMAÇ: Torasik aorta cerrahileri sonrası parapleji ile sonuçlanan spinal kord iskemik hasarı çok yıkıcı bir komplikasyondur. Bu çalışmanın amacı, tavşanlarda spinal kord iskemik hasarı sonrası gelişen histopatolojik hasara ve nöral fonksiyona mexiletinin etkisini araştırmaktır. Aynı zamanda mexiletinin etkilerini metilprednizolonun etkileri ile karşılaştırdık.

Atila KAZANCI¹
Hakan SECKIN²
Umit KARADENİZ³
Dilek KAZANCI⁴
Sema TURAN⁵
Burak KAZANCI⁶
Kazım YIGITKANLI⁷
Murad BAVBEK⁸

¹ Mesa Hospital, Neurosurgery Clinic, Ankara, Turkey

^{2,6,8} Ministry of Health Dışkapı Yıldırım Beyazıt Training and Research Hospital, Neurosurgery Clinic, Ankara, Turkey

^{3,4,5} Türkiye Yüksek İhtisas Education and Research Hospital, Anesthesiology Clinic, Ankara, Turkey

⁷ Ministry of Health, Duatepe Hospital, Neurosurgery Clinic, Ankara, Turkey

Received : 01.06.2009

Accepted : 03.11.2009

Correspondence address:

Atila KAZANCI

E-mail: atillakazanci@gmail.com

YÖNTEM ve GEREÇ: Yirmi altı adet beyaz Yeni Zelanda tavşanı rastgele 6 gruba ayrıldı. Grup1;Sham grubu (n=3) infrarenal aorta sadece cerrahi olarak ortaya kondu. grup 2(n=4) hiçbir intravenöz(iv) veya intraperitoneal medikasyon uygulanmadan sadece çapraz klemp uygulandı. Grup 3 (n=5) 20ml/kg/saat normal salin solüsyon aldı. Grup 4 (n=5) 30 mg/kg metilprednizolon aldı. Grup 5 (n=3) intraperitoneal 20ml/kg/saat normal salin aldı. Grup 6 (n=69 50mg/kg intraperitoneal mexiletin aldı. Geçici spinal kord iskemisi infrarenal aortanın 25 dakika boyunca klemplenmesi ve hemen arkasından reperfüzyon ile sağlandı. Nöral durum reperfüzyon sonrası yirmi dördüncü saatte Tarlov skorlama ile yapıldı. Nörolojik skorlamanın hemen arkasından tüm deneklerin spinal kordları histopatolojik inceleme için çıkarıldı.

BULGULAR: Histopatolojik incelemenin skorları grup 6'da, grup 2'e göre anlamlı olarak yüksek bulundu ($p<0.05$). Mexiletin grubundaki Tarlov skorları metilprednizolon grubuna göre daha yüksek olmakla birlikte bu fark istatistiksel olarak anlamlı bulunmadı.

SONUÇ: Mexiletin tavşanlarda transient spinal kord iskemisi sonrası gelişen histopatolojik hasarı belirgin bir şekilde önleyebilir ve nöral fonksiyonu iyileştirebilir. Bu çalışma spinal kord iskemisi modelinde mexiletinin nöron koruyucu etkisini araştıran ilk çalışmadır.

ANAHTAR SÖZCÜKLER: Spinal kord iskemisi, Mexiletin, Metilprednizolon

INTRODUCTION

Paraplegia secondary to spinal cord injury remains a disastrous and unpredictable complication of descending thoracic and thoracoabdominal aorta surgery (16,14,22,13,4,1,27). The reported spinal cord injury rates range from 10% to 40% (20,35). Therefore, a vast amount of effort has been focused on solving this problem. The commonly used preventive measures are hypothermia, cerebrospinal fluid drainage, temporary bypass, retrograde venous perfusion and pharmacological agents (16,14,22,13,4,1,27,31,10,23,28,15,25,21,2,12). Cellular and molecular mechanisms of ischemic spinal cord injury have not been totally elucidated. Various studies have suggested that free radical production, calcium overload, glutamate neurotoxicity, platelet aggregation, neutrophil accumulation and adhesion following ischemia may contribute to neuronal ischemic spinal cord injury (14,13,1,28,25,21). Zivin et al. developed a highly reproducible model in the rabbit that has become the standard for the study of experimental spinal cord ischemia (40). Transient occlusion of the infrarenal segment of aorta causes in the rabbit causes paraplegia with a low rate of complications such as bowel or kidney ischemia and cardiac dilatation, because of the unique segmental arterial blood supply to the spinal cord from the infrarenal aorta (23,2,12,40).

Mexiletine is a class Ib antiarrhythmic drug that is widely used in treatment of ventricular arrhythmia (6,17,3,30,36,5,39,11,26,7). Like other drugs in class I category, mexiletine blocks sodium channels. In addition to its effects on ion channels it is known to have a potent antioxidant effect and strong lipophilic

character (17,3,39,26). It has also been shown to inhibit free radical production in isolated polymorphonuclear leukocytes (6,39,26,32,38). Several investigators have reported that free radical production after spinal cord ischemia plays an important role in paraplegia after abdominal aorta surgery (16,22,13,4,20,39,26,32). Steroids have been administered empirically to stroke victims for many years without proof of efficacy or safety. Various classes of steroids have been shown to reduce neurological damage (3,24,18,29,8,9). A powerful antioxidant, methylprednisolone may effectively reduce neurological deficits, when given in large doses (17,18,29,8,9).

This study was designed to investigate the effect of mexiletine on the neural function and histopathological changes after ischemic spinal cord injury in rabbits. We also compared the effect of mexiletine to that of methylprednisolone. This is the first research that investigates the neuron-protective effect of mexiletine in a spinal cord ischemia model.

MATERIALS and METHODS

Animal care and surgical preparation

Twenty-six male New Zealand white rabbits weighing 1500 to 2500 gr were randomly assigned to one of six groups. Group 1; sham operated group (n=3) that underwent only the surgical exposure of infrarenal aorta. Group 2 (n=4) received neither intravenous nor intraperitoneal medication but the infrarenal aorta was cross-clamped. Group 3 (n=5) received intravenous infusion of 20ml/kg/h normal saline. Group 4 (n=5) received 30 mg/kg intravenous methylprednisolone. Group 5 (n=3) received intraperitoneal 20mg/kg/h normal saline. Group 6

(n=6) received 50mg/kg mexiletine intraperitoneally. All medications were given before the clamp occlusion of the abdominal aorta. Although many authors used mexiletine via the iv route, we lost some of our animals due to cardiac asystole after iv perfusion, and this lead us to use mexiletine intraperitoneally.

Spinal cord ischemia

Spinal cord ischemia was performed as described previously by Zivin et al. and several authors (16,22,13,4,1,28,40,32,38,19). After an overnight fast with unrestricted access to water, all 26 rabbits were anesthetized with intramuscular ketamine (50mg/kg) and xylazine (5mg/kg) prior to surgery. The left ear vein was cannulated with a 24 gauge catheter for the infusion of medications and intravenous fluids. An arterial line was placed in right ear artery through a 24 gauge catheter in order to monitor the blood pressure. Each procedure was performed in the same operating room. With the rabbits in supine position, the abdomen was opened through a vertical flank incision to expose the abdominal aorta. Aortic occlusion was achieved by placing temporary vascular clamps around the left infrarenal aorta following intravenous heparin (100U/mg) administration. After a previously established ideal ischemic time of precisely 25 minutes, the vascular clamp was removed and thus, reperfusion began. Intravenous cephalatine (25mg/kg) was given to all rabbits. After completion of the procedure, the aorta was detected to be intact, and the abdominal wall was closed with 4-0 nylon suture in separate layers. Systolic blood pressures (SBPs), diastolic blood pressures (DBPs) and heart rates (HRs) were recorded (1) at the beginning (2), 10 minutes after cross-clamping and (3) 10 minutes after reperfusion. Rectal temperature was maintained at 38°C by a heating blanket and overhead lamps. This research was performed under the permission and control of Animal Research Committee of Ankara University Medical School. All animals received humane care in compliance with the "Guide for the Care and Use of Laboratory Animals" published by the National Institutes of Health.

Assessment of neural function

The rabbits were neurologically assessed at 24 hours after reperfusion by an observer who was unaware of the treatment group with modified Tarlov criteria as follows: 0: paraplegic with no lower extremity function; 1: poor lower extremity function

only perceptible movement of joints; 2: active movement but no ability to stand; 3: ability to stand but no ability to walk; 4: completely normal hind limb motor function.

Histopathological examination

The animals were reanesthetized after evaluation of hind limb motor function at 24 hours after reperfusion. Transcardiac perfusion and fixation were performed with 100 ml heparinized saline followed by 500 ml 10% buffered formalin. Lumbar spinal cord was carefully harvested and refrigerated in 10% phosphate buffered formalin for 24 hours, before being set in paraffin blocks for sectioning and histopathological examination. Horizontal sections of the spinal cord that were 4 µm thick were made and stained with hematoxylin and eosin. Neuronal injury was evaluated at 400 x magnification with light microscopy by an observer who was unaware of treatment groups. We used a grading system to perform quantitative evaluation as follows: grade 0: normal spinal cord; grade 1: axonal swelling with 1-5 eosinophilic neurons in gray matter; grade 2: axonal swelling with 5-10 eosinophilic and necrotic neurons in gray matter; grade 3: axonal swelling with eosinophilic and necrotic neurons in less than half of the gray matter and vacuolation; grade 4: diffuse axonal swelling and vacuolation with eosiniophilic and necrotic neurons in more than half of the gray matter. The mean scores and standard deviations were calculated for each animal and group.

Statistical analysis

The Anova test was used for comparison of the groups. Tarlov scores and histopathological grades were analysed with the Kruskal-Wallis test followed by the Mann-Whitney U-test with Bonferroni correction. $P < 0.05$ was considered as statistically significant.

RESULTS

Physiological and hemodynamic parameters

Physiological and hemodynamic parameters are shown in (Table I). There were no statistical differences in mean SBP values among groups but mean SBP1 values in group 2 were significantly higher than mean SBP3 values ($p < 0.05$). There were no statistical differences in mean DBP values among groups but mean DBP3 values in group 1 were significantly lower than mean DBP1 and mean DBP2 values ($p < 0.05$).

Table I: Physiological and hemodynamic parameters of the groups.

		SBP1	SBP2	SBP3	DBP1	DBP2	DBP3	HR1	HR2	HR3
Group 1	Mean ± SD	85 ± 5	82.67 ± 4.04	81.67 ± 2.89	57.33 ± 2.52	55.67 ± 2.08	51.00 ± 1.73	182.67 ± 13.01	174.67 ± 16.04	180.67 ± 10.26
Group 2	Mean ± SD	90.25 ± 6.18	88.75 ± 16.80	80.00 ± 10.89	70.50 ± 4.20	70.25 ± 16.38	56.75 ± 12.79	191.50 ± 27.81	177.50 ± 29.74	179.25 ± 33.38
Group 3	Mean ± SD	87.60 ± 19.20	88.40 ± 18.19	76.40 ± 12.66	65.80 ± 20.44	63.20 ± 17.43	55.80 ± 10.01	194.00 ± 15.03	145.60 ± 18.12	155.40 ± 17.43
Group 4	Mean ± SD	95.80 ± 8.53	93.60 ± 5.13	83.40 ± 6.88	68.00 ± 7.11	64.20 ± 9.26	54.20 ± 10.52	194.20 ± 13.27	169.80 ± 10.94	198.20 ± 16.77
Group 5	Mean ± SD	92.67 ± 15.53	88.67 ± 10.26	78.00 ± 8.19	75.00 ± 14.00	72.00 ± 19.08	65.00 ± 8.66	195.33 ± 18.58	156.67 ± 11.55	165.33 ± 22.03
Group 6	Mean ± SD	85.67 ± 4.50	85.33 ± 6.44	87.17 ± 5.23	57.17 ± 5.04	64.00 ± 7.24	65.17 ± 7.00	199.17 ± 6.88	191.17 ± 17.76	183.50 ± 29.41

Mean HR2 values of group 6 were significantly higher than mean HR2 values of group 3 ($p < 0.05$).

Neurological assessment

The means and standard deviations of Tarlov scores of groups are shown in Figure 1. The mean Tarlov scores in group 2 were significantly lower than mean Tarlov scores of all other 5 groups ($p < 0.05$). The mean Tarlov scores of group 6 (mexiletine group) were similar to the mean of Tarlov scores of group 1 (sham group). The mean Tarlov scores of group 6 (mexiletine group) were better than the mean Tarlov scores of

groups 2,3,4, and 5 but the difference was not statistically significant ($p > 0.05$).

Histopathological changes

The means and standard deviations of histopathological grading scores of groups are shown in Figure 1. All rabbit spinal cord samples in group 1 (sham group) were evaluated as normal spinal cord. The histopathological grading scores in group 1 (sham group) and group 6 (mexiletine group) were significantly lower than the histopathological grading scores of group 2 ($p < 0.05$). The histopathological grading scores in group 1 (sham group) and group 6 (mexiletine group) were lower than the histopathological grading scores of groups 3,4, and 5 but the difference was not statistically significant ($p > 0.05$). In group 2, the segment that had been subjected to spinal cord ischemia showed severe neural damage, as evidenced by reduced number of motor neurons, disappearance of Nissl bodies and nuclei and vacuolation of gray matter. In contrast, the spinal cords of the rabbits in the mexiletine group showed almost intact-looking light microscopic findings (Figure 2).

There was a strong correlation between final neurological function and histopathological findings of the spinal cord at 24 hours after reperfusion ($p < 0.01$).

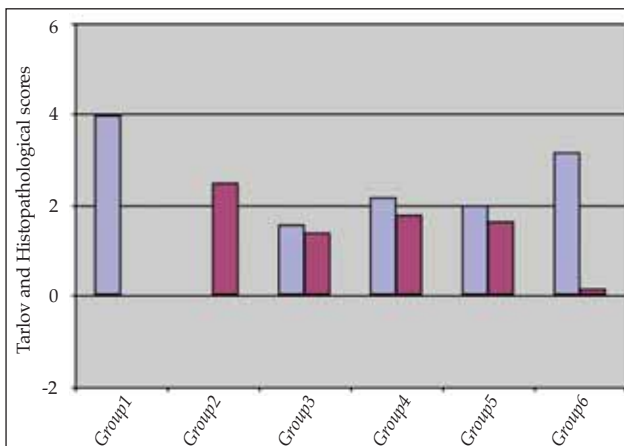


Figure 1: Mean of Tarlov and histopathological scores and standard deviations.

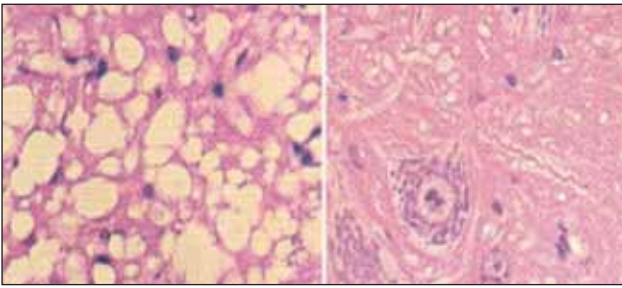


Figure 2: Spinal cord sections at 24 hours after reperfusion. Left : Few motor neurons can be observed and extensive vacuolation is noted in group 1 (HEX400). Right: Intact motor neurons can be observed in the mexiletine group (HEX400).

DISCUSSION

The present study provides evidence for the protective effect of intraperitoneally administered mexiletine pretreatment in the rabbit spinal cord ischemia model. The beneficial effects were observed both histologically and neurologically. No clinically important dose-response effect was observed within the dose range studied in the present study.

Partial to complete paralysis during the early postoperative period is an unfortunate devastating sequela of procedures on the descending thoracic or thoracoabdominal aorta or spinal cord surgery for tumors. Spinal cord ischemia triggers progressive events that include local edema, vasospasm, decrease in circulation and ischemia, free radical formation, calcium influx into the axons, and loss of potassium from the intercellular space (16,22,27,35).

Neurological deficits may be noted during the immediate postoperative period or may be manifested several hours after surgery, which severely influences the surgical outcome and leads to a massive psychological and financial burden (16,22,13,4,27,35). No clinically effective treatment has yet been developed despite various surgical and pharmacological efforts to minimize this complication.

The rabbit model of spinal cord ischemia used in this study, which mimics aortic occlusion during operation on descending thoracic or thoracoabdominal aorta clinically, is a reliable and a reproducible model for producing neural deficits and testing drugs that might serve to protect the spinal cord from ischemic injury (13,4,27,40). Zivin et al. developed a highly reproducible model in the rabbit that has become the standard for the study of experimental spinal cord ischemia (40). Transient occlusion of the infrarenal segment of aorta causes in

the rabbit causes paraplegia with a low rate of complications such as bowel or kidney ischemia and cardiac dilatation, because of the unique segmental arterial blood supply to the spinal cord from the infrarenal aorta (23,2,12,40).

Mexiletine is a class Ib antiarrhythmic drug that is widely used in treatment of ventricular arrhythmia (6,17,3,30,36,5,11,7). Like other drugs in the class I category, mexiletine blocks sodium channels. Chronic administration of mexiletine results in upregulation of cardiac sodium channel expression as several other class Ib drugs do. The stimulatory effect of increased cytoplasmic calcium in the production of reactive oxygen species is well documented (6). Using the rat optic nerve as an in vitro model of white matter anoxia, Stys et al. showed that calcium influx into axons played a key role in mediating irreversible injury and the majority of the deleterious calcium influx occurred via reverse operation of the sodium-calcium exchanger (34). By blocking sodium channels, mexiletine inhibits sodium dependent calcium overload in the cells. The protection against anoxic-ischemic injury by mexiletine is explained by the inhibition of sodium-calcium exchanger with this drug (6,3,9,34,33) Stys and Lesiuk showed that mexiletine was able to protect optic nerves from ischemic injury after systemic administration (33). Kaptanoglu et al. showed that systemic administration of mexiletine had a protective effect on secondary injury after spinal cord trauma (17).

In addition to its effects on ion channels, mexiletine is known to have a potent antioxidant effect and strong lipophilic character (6,17,3,39,26). Demirpence et al. have studied the antioxidant action of mexiletine under different oxidant conditions in vitro. They showed that mexiletine inhibited Fe-Asc-H₂O₂-induced lipid peroxidation in biological membranes and phospholipid liposomes, which was more effective in biomembranes than liposomes (6). It has also been shown to inhibit free radical production of isolated polymorphonuclear leukocytes (6,3,39,26).

Steroids have been administered empirically to stroke victims for many years without proof of efficacy or safety. Various classes of steroids have been shown to reduce neurological damage (3,24,18,29,8,9). A powerful antioxidant, methylprednisolone, may effectively reduce neurological deficits when given in large doses (17,29,8,9). The doses of methylprednisolone that affect this improved recovery

have been demonstrated to inhibit posttraumatic spinal cord lipid peroxidation, which has been postulated to be a key event in the secondary injury-induced degenerative cascade (29,8). At a physiological level, the inhibition of injury-induced lipid peroxidation has been found to result in an attenuation of progressive posttraumatic ischemia and energy failure together with an augmented reversal of intracellular calcium accumulation (8).

There was significant improvement in the neurological outcomes of rabbits that received mexiletine compared to the control group (Group 2). Animals treated with mexiletine just before aortic occlusion were able to stand without difficulty or hop normally and reached a mean Tarlov score of 3.17 after 24 hours while the animals in the control group showed paralysis of the hind limbs. Tetik et al. showed that methylprednisolone treatment prevented hind limb paralysis when Vitamins E and C were added to the therapeutic regiment (37). In the present study, the Tarlov scores of the methylprednisolone group were better than the control group but not as good as the Tetik's study. This may be due to the additional Vitamin C and E therapy.

Histological examination confirmed the ability of mexiletine to limit the degeneration and necrosis of the motor neurons of the spinal cord. Histological examination of the spinal cord revealed either no or very little evidence of injury in rabbits receiving mexiletine. However, the spinal cord from the control animals had clear evidence of extensive spinal injury with a reduced number of motor neurons, perikaryal swelling, vacuolation of gray matter, Nissl substance dissolution, and karyolysis. Methylprednisolone also prevented histopathologic damages in the present study but not as much as mexiletine. The number of normal motor neurons in the anterior horn of spinal cord has a direct relationship with neural function, which was manifested by a strong correlation between the final neurological outcome and the number of normal motor neurons in the anterior horn. The mechanism of motor neuronal cell death after spinal cord ischemia and reperfusion has been explored through molecular, cellular and genetic aspects, but has not been identified yet.

Hemodynamic parameters were also recorded during the experimental procedure. The mean HR2 values of group 6 (mexiletine) were significantly higher than mean HR2 values of group 3 ($p < 0.05$). Mexiletine is primarily an antiarrhythmic drug and

effective on hemodynamic variables. The change in HR2 in group 6 were thought to be secondary to this hemodynamical effect. It is reported to have a relatively narrow therapeutic index (3,24,30,36,5). Care must be taken during systemic administration of mexiletine because of this narrow therapeutic index.

We investigated the protective effect of mexiletine on ischemically injured spinal cord in this study. This is the first study in literature that investigates the effect of mexiletine on spinal cord ischemia. The determination of the optimal therapeutic time window and the optimal dose for mexiletine in transient spinal injury needs further investigation. Mexiletine might have an important clinical application in the prevention of spinal cord injury during thoracoabdominal aortic surgery, spinal tumor surgery and spinal trauma.

CONCLUSION

Mexiletin may ameliorate neural function and prevent the histopathological damage after transient spinal cord ischemia in rabbits. In addition to its effects on ion channels, mexiletine is known to have a potent antioxidant effect and strong lipophilic character that inhibits lipid peroxidation in biological membranes and phospholipid liposomes. Mexiletine was given before ischemic trauma and was investigated for the neuron-protective effect in a spinal cord ischemia model in this study. This is the first study on mexiletine in spinal cord ischemia. More studies are needed to demonstrate the exact effect of mexiletine on spinal cord ischemia.

REFERENCES

1. Apaydin AZ, Büket S: Regional Lidocaine infusion reduces postischemic spinal cord injury in rabbits. *Texas Heart Injury J* 28(3): 172-176, 2001
2. Bartholdi D, Schwab ME: Methylprednisolone inhibits early inflammatory processes but not ischemic cell death after experimental spinal cord lesion in the rat. *Brain Res* 672(1-2):177-186, 1995
3. Caner H, Kwan AL, Bavbek M, Kılınc K, Durieux M, Lee K, Kassell NF: Systemic administration of mexiletine for attenuation of cerebral vasospasm following experimental subarachnoid haemorrhage. *Acta Neurochir (Wien)* 142(4):455-461, 2000
4. Chen S, Xiong L, Wang Q, Sang H, Zhu Z, Dong H, Lu Z: Tetramethylpyrazine attenuates spinal cord ischemic injury due to aortic cross-clamping in rabbits. *BMC Neurol* 1: 2002
5. Chinushi M, Tagawa M, Sugiura H, Komura S, Hosaka Y, Washizuka T, Aizawa Y: Ventricular tachyarrhythmias in a canine model of LQT3: Arrhythmogenic effects of sympathetic activity and therapeutic effects of mexiletine. *Circ J* 67(3):263-268, 2003

6. Demirpençe E, Caner H, Bavbek M, Kılıç K: Antioxidant action of the antiarrhythmic drug mexiletine in brain membranes. *Jpn J Pharmacol* 81(1):7-11, 1999
7. El Yaman M, Perry J, Makielski JC, Ackerman MJ: Suppression of atrial fibrillation with mexiletine pharmacotherapy in a young woman with type 1 long QT syndrome. *Heart Rhythm* 5(3):472-474, 2008 Epub 2007 Oct 18
8. Hall ED: Neuroprotective actions of glucocorticoid and nonglucocorticoid steroids in acute neuronal injury. *Cell Mol Neurobiol* 13(4):415-432, Review, 1993
9. Imamura H: Effects of megadose methylprednisolone therapy on acute spinal cord injury in rats. *Hokkaido Igaku Zasshi* 69(2): 236-247, 1994
10. Iseli E, Dietz V, Curt A: Prognosis and recovery in ischemic and traumatic spinal cord injury: Clinical and electrophysiological evaluation. *J Neurol Neurosurg Psychiatry* 67(5):567-571, 1999
11. Ishibashi S, Yokota T, Inaba A, Yamada M, Mizusawa H, Iwai T, Shiojiri T: Mexiletine is effective on segmental hyperhidrosis: report of two cases. *J Neurol Neurosurg Psychiatry* 72(1):122, 2002
12. Juvonen T, Biancari F, Rimpiläinen J, Satta J, Rainio P, Kiviluoma K: Strategies for spinal cord protection during descending thoracic and thoracoabdominal aortic surgery: Up-to-date experimental and clinical results- A review. *Scand Cardiovasc J* 36(3):136-160, Review, 2002
13. Kakimoto M, Kawaguchi M, Sakamoto T, Inoue S, Furuya H, Nakamura M, Konishi N: Evaluation of rapid ischemic preconditioning in a rabbit model of spinal cord ischemia. *Anesthesiology* 99(5):1112-1117, 2003
14. Kanellopoulos GK, Kato H, Hsu CY, Kouchoukos NT: Spinal cord ischemic injury. Development of a new model in the rat. *Stroke* 28(12):2532-2538, 1997
15. Kanellopoulos GK, Kato H, Wu Y, Kouchoukos NT: Neuronal cell death in the ischemic spinal cord: The effect of methylprednisolone. *Ann Thorac Surg* 64(5):1279-1285; discussion 1286, 1997
16. Kanellopoulos GK, Xu XM, Hsu CY, Lu X, Sundt MT, Kouchoukos NT: White matter injury in spinal cord ischemia: protection by AMPA/kainate glutamate receptor antagonism. *Stroke* 31(8):1945-1952, 2000
17. Kaptanoğlu E, Caner H, Selçuk S, Akbıyık F: Effect of mexiletine on lipid peroxidation and early ultrastructural findings in experimental spinal cord injury. *J Neurosurg* 91(2 Suppl):200-204, 1999
18. Koç RK, Akdemir H, Kurtsoy A, Paşaoğlu H, Kavuncu I, Paşaoğlu A, Karaküçük I: Lipid peroxidation in experimental spinal cord injury. Comparison of treatment with Ginkgo biloba, TRH and methylprednisolone. *Res Exp Med (Berl)* 195 (2): 117-123, 1995
19. Korkmaz A, Oyar EO, Kardeş O, Omeroğlu S: Effects of melatonin on ischemic spinal cord injury caused by aortic cross clamping in rabbits. *Curr Neurovasc Res* 5(1):46-51, 2008
20. Kouchoukos NT, Rokkas CK: Descending thoracic and thoracoabdominal aortic surgery for aneurysms or dissection: How to minimize the risk of spinal cord injury? *Semin Thorac Cardiovasc Surg* 5(1):47-54, Review, 1993
21. Kwon BK, Tetzlaff W, Grauer JN, Beiner J, Vaccaro AR: Pathophysiology and pharmacologic treatment of acute spinal cord injury. *Spine J* 4(4): 451-464, 2004
22. Lang-Lazdunski L, Matsushita K, Hirt L, Waeber C, Vonsattel JP, Moskowitz MA, Dietrich WD: Spinal cord ischemia; Development of a model in a mouse. *Stroke* 31(1):208-213, 2000
23. Lapchak PA, Araujo DM, Song D, Zivin JA: Neuroprotection by the selective Cyclooxygenase-2 inhibitor SC-236 results in improvements in behavioral deficits induced by reversible spinal cord ischemia. *Stroke* 32(5):1220-1225, 2001
24. Lapchak PA, Chapman DF, Nunez SY, Zivin JA: Dehydroepiandrosterone sulphate is neuroprotective in a reversible spinal cord ischemia model: Possible involvement of GABA(A) receptors. *Stroke* 31(8):1953-196; discussion 1957, 2000
25. Laschinger JC, Cunningham JN Jr, Cooper MM, Krieger K, Nathan IM, Spencer FC: Prevention of ischemic spinal cord injury following aortic cross-clamping: use of corticosteroids. *Ann Thorac Surg* 38(5):500-507, 1984
26. Li H, Xu KY, Zhou L, Kalai T, Zweier JL, Hideg K, Kuppusamy P: A pyrroline derivative of mexiletine offers marked protection against ischemia/reperfusion-induced myocardial contractile dysfunction. *J Pharmacol Exp Ther* 295(2):563-571, 2000
27. Marsala J, Jalc P: Short term changes of NADPH diaphorase-exhibiting neuronal pools in the spinal cord of rabbit after repeated sublethal ischemia. *Physiol Res* 49(1):157-165, 2000
28. Matsushita K, Wu Y, Qiu J, Lang-Lazdunski L, Hirt L, Waeber C, Hyman BT, Yuan J, Moskowitz MA: Fas receptor and neuronal cell death after spinal cord ischemia. *J Neurosci* 20(18):6879-6887, 2000
29. Pointillart V, Petitjean ME, Senegas J: Bases for drug therapy of spinal cord injury. *Cah Anesthesiol* 42 (2): 517-520, 1994
30. Saita T, Fujito H, Mori M: Development of enzyme-linked immunosorbent assay for therapeutic drug monitoring of mexiletine. *Biol Pharm Bull* 26(6): 761-765, 2003
31. Sakurai M, Hayashi T, Abe K, Itoyama Y, Tabayashi K, Rosenblum WI: Cyclin D1 and Cdk4 protein induction in motor neurons after transient spinal cord ischemia in rabbits. *Stroke* 31(1):200-207, 2000
32. Shirasawa Y, Matsumoto M, Yoshimura M, Yamashita A, Fukuda S, Ishida K, Sakabe T: Does high-dose opioid anesthesia exacerbate ischemic spinal cord injury in rabbits? *J Anesth* 23(2):242-248. Epub 2009 May 15, 2009
33. Stys PK, Lesiuk H: Correlation between electrophysiological effects of mexiletine and ischemic protection in central nervous system white matter. *Neuroscience* 71(1):27-36, 1996
34. Stys PK, Ransom BR, Waxman SO, Davis PK: Role of extracellular calcium in anoxic injury of mammalian central white matter. *Proc Natl Acad Sci U S A* 87(11):4212-4216, 1990
35. Svensson LG, Crawford ES, Hess KR: Experience with 1509 patients undergoing thoracoabdominal aortic operations. *J Vasc Surg* 17(2):357-368; discussion 368-370, 1993
36. Takahashi MP, Cannon SC: Mexiletine block of disease-associated mutations in S6 segments of the human skeletal muscle Na(+) channel. *J Physiol*. Dec 15;537(Pt 3):701-14, 2001
37. Tetik O, Islamoğlu F, Yağdı T, Atay Y, Çalkavur T, Özbek C, Canpolat L, Buket S, Yüksel M: An intraaortic solution trial to prevent spinal cord injury in a rabbit model. *Eur J Vasc Endovasc Surg* 22(2): 175-179, 2001
38. Wang Q, Ding Q, Zhou Y, Gou X, Hou L, Chen S, Zhu Z, Xiong L: Ethyl pyruvate attenuates spinal cord ischemic injury with a wide therapeutic window through inhibiting high-mobility group box 1 release in rabbits. *Anesthesiology* 110(6):1279-1286, 2009
39. Weiser T, Qu Y, Catterall WA, Scheuer T: Differential interaction of R-mexiletine with the local anesthetic receptor site on brain and heart sodium channel -subunits. *Mol Pharmacol* 56(6): 1238-1244, 1999
40. Zivin JA, De Girolami U: Spinal cord infarction: A highly reproducible stroke model. *Stroke* 11: 200-202, 1980