

The Surgical Anatomy of the Brachial Plexus

Brakial Pleksusun Cerrahi Anatomisi

ABSTRACT

AIM: The brachial plexus (BP) has a complex structure and risky relations with its neighborhoods. This study was designed to investigate and overcome the morphometric features of the BP and the difficulties regarding surgery of BP lesions.

MATERIAL and METHOD: Twelve BP of six adult cadavers were dissected and neural structures, branches, and variations were evaluated. Morphometric measurements were done and surgical approaches were discussed.

RESULTS: The length of anterior (ventral) rami of C₅-T₁ are in decreasing order such as C₅ > C₆ > C₇ > C₈ > T₁ and the width of them is in decreasing order such as C₇ > C₈ > C₆ > T₁ > C₅. The length of upper trunk (UT), middle trunk (MT) and lower trunk (LT) are approximately similar (UT ≈ MT ≈ LT), but the width is in decreasing order as LT > UT > MT. The length of the cords are in decreasing order as posterior cord (PC) > lateral cord (LC) > medial cord (MC), whereas their widths are PC > LC > MC.

CONCLUSION: From the ventral rami to the cords, BP has a complex and variable anatomic structure. The selection of surgical procedure to the BP needs to be mastered by having the best knowledge of the relevant anatomy.

KEYWORDS: Brachial plexus, Anatomy, Surgery

ÖZ

AMAÇ: Brakiyal pleksusun kompleks bir yapısı ve riskli komşulukları vardır. Bu çalışmada, brakiyal pleksusun morfometrik anatomisi ve cerrahisindeki karşılaşılabilecek güçlüklerin ortaya konması amaçlandı.

YÖNTEM ve GEREÇ: Çalışmamızda 6 erişkin kadavraya ait 12 adet brakiyal pleksus bölgesi disseke edilmiş ve normal yapılanma ile anatomik farklılıklar değerlendirilmiştir. Bu bölgeye ait morfometrik ölçümler ve cerrahi yaklaşımlar tartışılmıştır.

BULGULAR: C₅-T₁ anterior (ventral) ramuslarının uzunlukları sırasıyla C₅ > C₆ > C₇ > C₈ > T₁ şeklinde ve genişlikleri ise C₇ > C₈ > C₆ > T₁ > C₅ şeklinde sıralanmaktadır. Üst (UT), orta (MT) ve alt (LT) trunkusların uzunlukları ise hemen hemen birbirine eşittir. Ama genişlikleri LT > UT > MT şeklindedir. Kordlar uzunluklarına göre posterior kord (PC) > lateral cord (LC) > medial kord (MC), genişliklerine göre ise PC > LC > MC şeklinde sıralanmaktadır.

SONUÇ: Brakiyal pleksus ventral ramuslardan kordlara kadar kompleks ve değişken bir anatomik yapıya sahiptir. Brakiyal pleksusa yapılacak cerrahi yöntemin seçiminde ilgili bölgenin anatomisinin çok iyi bilinmesi gereklidir.

ANAHTAR SÖZCÜKLER: Brakiyal pleksus, Anatomi, Cerrahi

I. Murat AKBORU¹

İlker SOLMAZ²

H. İbrahim SECER³

Yusuf IZCI⁴

Mehmet DANEYEMEZ⁵

¹ Etimesgut Military Hospital,
Department of Neurosurgery,
Ankara, Turkey

^{2,3,4,5} Gülhane Military Medical Academy,
Department of Neurosurgery,
Ankara, Turkey

Received : 02.09.2009

Accepted : 03.11.2009

Correspondence address:

İlker SOLMAZ

Phone : +90 312 304 53 05

E-mail : solmazilker@hotmail.com

INTRODUCTION

One of the handicaps that the surgeon commonly faces in surgical procedures of the neck and axillary region is the brachial plexus (BP) and its location. Some of the authors have emphasized that knowing the anatomy of BP and its probable variations in relation to neck, shoulder and axillary region surgery decreases the rate of neurological damages considerably. Complexity of the BP, close relations with its neighboring structures and anatomical location renders BP lesions more complicated and may cause to multiple nerve injuries in upper limbs (20,22,29,75).

Nowadays, peripheral nerve injuries show a tendency to rise due to the increase in traffic, industrial accidents and gunshot wounds (especially in our patient population), (5,14,60,61,62). BP and its branches can also be damaged in concomitant vessel injuries (especially in the subclavian and axillary arteries) due to the close proximity in 25-67 % cases. Although vessel injuries are always treated effectively, plexus damages can be missed and undiagnosed (13, 62).

These plexus injuries can be classified into 3 groups as supraclavicular, infraclavicular and axillary regionalwise and 4 groups as root, trunk, cord and terminal branches locationwise (51,59,62,70,72) (Figure 1).

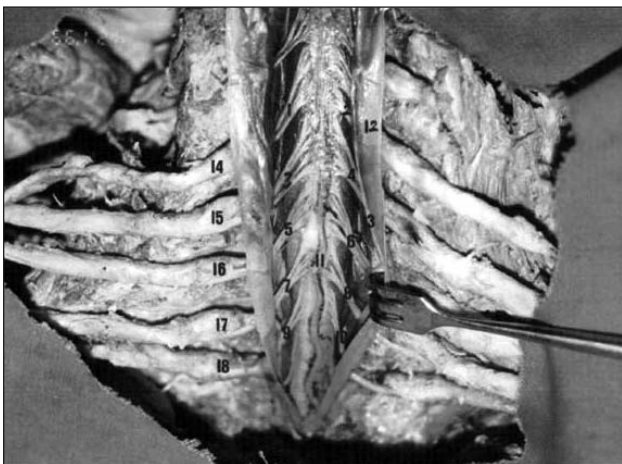


Figure 1: 1, right ventral root of C₅; 2, left ventral root of C₅; 3, right ventral root of C₆; 4, left ventral root of C₆; 5, right ventral root of C₇; 6, left ventral root of C₇; 7, right ventral root of C₈; 8, left ventral root of C₈; 9, right ventral root of T₁; 10, left ventral root of T₁; 11, anterior spinal artery; 12, spinal dura mater; 13, spinal arachnoid mater. In right BP; 14, ventral ramus of C₅; 15, ventral ramus of C₆; 16, ventral ramus of C₇; 17, ventral ramus of C₈; 18, ventral ramus of T₁ can be seen.

As a general rule, it is considered that BP lesions have bad prognosis. The location of the injury must be known exactly before treatment (56). It has been reported that lesions can be treated with surgically in last 40 years and until 1950's amputation had been preferred (66). Kennedy performed the first surgical procedure in C5-C6 roots injuries located out of the intervertebral foramen in three cases and Taylor (1920) treated birth paralysis of 20 newborns (26,41).

Seddon, who first popularized the nerve grafting technique had been using this procedure until 1974 while surgery was generally not considered as a treatment option during those years. Experiences during World War II were not encouraging (49, 63). As a primitive trial, roots that had been torn out were repositioned in the medulla spinalis but no recovery was observed (6,12). Fortunately, nerve segment transfer from intercostal nerves, long thoracic nerves (Bell's nerve) and branches of cervical plexus were performed with successful results in cases of BP paralysis due to nerve branch injuries (2,15,18,21,27,34,35,36,47,50,51,53,57,59,69,74,76).

Despite the belief that BP malformations coexist with the vascular malformations, variations of BP can be seen without vascular aberrations. Variations are mostly seen as attaching or detaching of contributonal elements (20, 29).

Variations of BP have been identified either in cadaver dissections or in clinical cases (20). Studies on BP anatomy have a long history. Walsh (1877), Willar (1888), Franz (1889) and Harris (1904) studied on its consistency and these studies directed to branches and variations resulted in temporary investigations. After rapid development in microsurgical techniques, BP lesions, variations, their diagnosis and treatment were well-described (20,29,30,68,75,76).

The following techniques are used in the diagnosis of BP lesions: Electromyography (EMG), somatosensory evoked potentials (SSEP), myelography, computerized tomography (CT), myelo-CT, magnetic resonance (MR), and magnetic resonance neurography (MRN) (1,7,11,23,24,31,37,40,42,49,54,55,72).

Loss of sensation, holding and grasping of hands and more complicated hand movements are partially or totally lost (22).

BP lesions are not fatal; however, they may cause

serious morbidity and permanent neurological deficits as well as substantial degree of work loss (10, 49). While evaluating BP lesions, the normal anatomy and variations must be well known and taken into account by the physician (20, 29, 65, 67).

The aim of this study was to clarify the topographic relations of BP with its neighboring structures (bones, nerves and vessels) and to investigate the best way of radical surgery without complications.

MATERIALS and METHODS

Anatomic dissection was performed on 12 BP in 6 adult cadavers obtained from the Anatomy Department, upon the official request of the Neurosurgery Department Gülhane Military Medical Academy. To expose the BP, we used the same skin incision, well-described by MacCarty, 1984; Dunkerton, 1988; Hentz, 1991; Leffert, 1993; Ochiai, 1996 (17,26,42,45,53).

For dissection, the skin incision was performed in three steps. First incision was performed along the lateral aspects of the sternocleidomastoid muscle between at its origin and insertion. Second skin incision was begun on medial aspect of the clavicle along to the middle of the clavicle and from this point on, incision was oriented below to fit to the deltopectoral sulcus and was extended to the midpoint of inner side of the arm. Third incision was performed from deltopectoral sulcus to axillary fossa. After all three incisions were completed meticulously, the skin flap was removed from the beginning points of the incisions toward the lateral side of neck. The clavicle was explored and cut medially (acromioclavicular joint) and its lateral (sternoclavicular joint) tip was taken out as a single piece.

The BP, supraclavicular fossa and infraclavicular fossa are in close relationship with vascular structures especially with the arteries. Branches of the subclavian artery and vein and the axillary artery and vein were followed by further dissection and thinner branches were taken out with surrounding connective and adipose tissue. To visualize the division of BP in infraclavicular fossa, the pectoralis major muscle and the pectoralis minor muscle were also removed by cutting near their insertion points. During dissection, big vessel variations as well as the co-existence of vascular

variations and alternative branching of BP were investigated.

Anterior and median scalene muscles were taken out from their origin and insertion to expose radix anterior and posterior which were roots of BP. After this step, all anatomic structures, positioned in front of C₄-T₂ levels vertebrae were removed. Thereafter, the spinal column was reached following by traversing the structures listed below in order; anterior longitudinal ligament, vertebral body, intervertebral discs, and anterior spinal dura mater. After dissecting the posterior longitudinal ligament, the dura mater and then arachnoid mater were cut through a medial incision and anterior and posterior radices were exposed. During the dissection, right and left BP and their branching as well as their variations were evaluated. Serial photographs of normal anatomy and variations of BP were taken.

While using the morphometric method, the roots of plexus (C₅-T₁), the distance between the points between which intervertebral foramina originated and the level they formed trunks, width of upper, middle and lower trunks at the beginning and the length of interval between the point between which posterior and anterior divisions leaving the trunk and the point of insertion of those branches at the spinal cord were measured.

The length of the medial cord was measured between its beginning and the point where it gave rise to the ulnar nerve.

The length of the lateral cord was measured between the insertion point of the anterior divisions of upper and middle trunks to the cord and the point where the musculocutaneous nerve originates from lateral cord.

The length of the posterior cord was measured between the insertion point where the posterior divisions of upper, middle and lower trunks were fused and the point that axillary and radial nerves originated.

BP width measurements were always done at the proximal region where there was no branching. Measurements were calculated as millimeter and the sensitivity was set up to the 1/10th of a millimeter.

RESULTS

In this study, macroscopic appearance, length and width were measured by the morphometric method

and the findings were derived from the BPs of six adult cadavers.

Roots (Anterior or Ventral rami) :

Ventral rami of C₅-T₁ after dissection of spinal dura mater and arachnoid mater by anteromedian incision and their relations with posterior (dorsal) rami can be seen in Figure 1. Length of anterior (ventral) rami of C₅-T₁ were measured as C₅= 55.8 ± 0.81 (SEM) mm, C₆= 52.3 ± 0.97 (SEM) mm, C₇= 48.4 ± 0.94 (SEM) mm, C₈= 39.8 ± 0.82 (SEM) mm and T₁= 34.8 ± 0.95 (SEM) mm in decreasing order of C₅, C₆, C₇, C₈, and T₁. Their widths were measured as C₅= 3.3 ± 0.12 (SEM) mm, C₆= 4.4 ± 0.87 (SEM) mm, C₇= 5.4 ± 0.31 (SEM) mm, C₈= 4.9 ± 0.81 (SEM) mm, T₁= 3.9 ± 0.67 (SEM) mm in a decreasing order of C₇, C₈, C₆, T₁, and C₅ (Figure 1).

Nerves derived from anterior (ventral) rami; dorsal scapular nerve and long thoracic nerve were visualized from beginning to the point where they are inserted into muscle.

In 4 BP (33.3 %) there is a branch derived from C₄ ends in C₅ at which level the phrenic nerve originates.

Trunks (Upper, middle and lower trunks) :

Length of upper trunk (UT), middle trunk (MT) and lower trunk (LT) were as follows in order: UT= 20.3 ± 0.52 (SEM) mm, MT= 20.1 ± 0.42 (SEM) mm, LT= 20.2 ± 0.73 (SEM) mm and UT ~ MT ~ LT. Width of their are UT= 5.9 ± 0.68 (SEM) mm, MT= 5.0 ± 0.25 (SEM) mm and LT= 6.3 ± 0.17 (SEM) mm in decreasing order as LT > UT > MT (Figure 2).

Nerves derived from trunks are the nerves to subclavius and the suprascapular nerve as shown in Figure 2.

Divisions (Anterior and posterior divisions) :

The Length of anterior and posterior divisions are as follows: Anterior division of upper trunk (ADUT) = 28.9 ± 0.92 (SEM) mm, posterior division of upper trunk (PDUT) = 31.0 ± 0.61 (SEM) mm, anterior division of middle trunk (ADMT) = 21.7 ± 0.85 (SEM) mm, posterior division of middle trunk (PDMT) = 23.1 ± 0.90 (SEM) mm, anterior division of lower trunk (ADLT) = 31.8 ± 0.75 (SEM) mm, posterior division of lower trunk (PDLT) = 19.3 ± 0.80 (SEM) mm and they were ordered as ADLT > PDUT > ADUT > PDMT > ADMT > PDLT. The

widths of these structures were ADUT= 3.4 ± 0.72 (SEM) mm, PDUT= 3.5 ± 0.31 (SEM) mm, ADMT= 2.5 ± 0.51 (SEM) mm, PDMT= 2.2 ± 0.15 (SEM) mm, ADLT= 3.8 ± 0.38 (SEM) mm, PDLT= 2.8 ± 0.91 (SEM) mm and were ordered as ADLT > PDUT > ADUT > PDLT > ADMT > PDMT (Figure 2).

Cords (Lateral, medial and posterior cords) :

The lengths of cords were as follows: Lateral cord (LC) = 32.1 ± 0.66 (SEM) mm, medial cord (MC) = 21.6 ± 0.84 (SEM) mm, posterior cord (PC) = 25.4 ± 0.50 (SEM) mm, PC > LC > MC and their widths were LC= 4.4 ± 0.76 (SEM) mm, MC= 3.8 ± 0.76 (SEM) mm, PC= 5.3 ± 0.61 (SEM) mm, PC > LC > MC (Figure 2). In Figure 3, branches of lateral cord, lateral pectoral nerve, musculocutaneous nerve, and lateral root of median nerve can be seen.

Medial pectoral nerve, medial cutaneous nerve of the arm, medial cutaneous nerve of the forearm, ulnar nerve and the medial root of the median nerve which are branches of the medial cord can be seen from the beginning point in Figure 3. Lateral root of median nerve derived from lateral cord and medial root of median nerve are fused to form the median




Figure 2: In left BP; 1, upper trunk; 2, middle trunk; 3, lower trunk, 4, suprascapular nerve: It consists of fibers from upper trunk, travels posterolaterally and gives branches to supraspinatus muscle and infraspinatus muscle; 5, nerve to subclavius: It consists of fibers from C₅ and C₆, goes down and innervates subclavius muscle, 6, ADUT; 7, PDUT; 8, ADLT, 9, PDLT, 10, ADMT, 11, PDMT; 12, lateral cord, 13, posterior cord, 14, medial cord; 15, superior subscapular nerve: After originating posterior cord travels inferoposteriorly and reaches axillary fossa, here it innervates the subscapular muscle located on the anterior surface of scapula; 16, thoracodorsal nerve: It comes to the axillary fossa between the superior and inferior subscapular nerve then goes down reaching the medial surface of latissimus dorsi muscle and innervates it; 17, inferior subscapular nerve: after originating from the posterior cord its branches first to the subscapular muscle and then the teres major muscle are seen.

nerve (Figure 3 and 4). Superior subscapular nerve, thoracodorsal nerve, inferior subscapular nerve, axillary nerve and radial nerve which are branches of the posterior cord can be seen in Figure 3 and 4. The radial nerve takes fibers from the all segments of the plexus like the median nerve.

Median length of BP was 151.8 ± 0.73 (SEM) mm. Close relation of ventral rami of C₅ – T₁ with anterior scalene muscle, medial scalene muscle, subclavian vein and artery, axillary vein, and artery were within the normal range and no vascular variation was observed (Figure 4).

According to our measurements, there was no difference in the sizes of roots, trunks, cords between the left and right plexuses.

DISCUSSION

This study was performed on 12 BP of 6 adult cadavers and consistency, branching levels and variations of plexus have been observed. Dissection had been done bilaterally and length and width of plexus components were measured accordingly.

BP is a union of the lower four cervical ventral rami and the greater part of the first thoracic ventral ramus between anterior and medial scalene muscle (9,48,64,73). Some nerve fibers may join the plexus, mostly from C₄ and rarely from T₂ (73). C₄ fibers joining the plexus via C₅ might be damaged in surgical procedures in the neck region so these variations must be kept in mind (20). In our study, we observed a condition called a pre-fix plexus in two BP (16.66%). Another rare condition, the post-fix plexus meaning T₂ attachment by T₁ was not seen in this study.

Fibers derived from the fifth cervical ventral ramus ending with the phrenic nerve at the level of the first rib are called the accessory phrenic nerve by Moore (48). In this study there were 3 cases (25 %) where some C₄ fibers attached to C₅ from the phrenic nerve.

The fifth and sixth cervical ventral rami bind each other and are called the upper trunk. The seventh cervical ventral ramus is named the middle trunk individually. The eighth cervical and first thoracic ventral rami are called the lower trunk (48,64,73). In two cases (16.66 %) there was a communicating branch from the medial trunk to the musculocutaneous nerve.

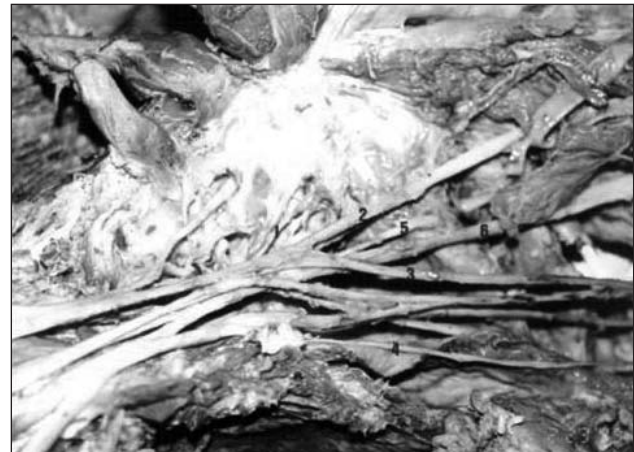

Figure 3: In left BP; 1, lateral pectoral nerve: It is the first branch of the lateral fasciculus and gives branches to pectoral major muscle; 2, musculocutaneous nerve: One of the terminal branches of the lateral cord and it is originated from lateral cord in axillary fossa and travels down to laterally pass to the arm; 3, the lateral root of median nerve: another terminal branch of lateral cord, it first travels downward and becomes a part of median nerve; 4, medial cutaneous nerve of the arm: After originating from medial cord it goes down to arm and penetrating the brachial fascia is delivered to medial surface of the arm; 5, axillary nerve: In the axillary fossa and gives branches to the deltoid muscle and teres minor muscle; 6, radial nerve: It is the other terminal branch of the posterior cord, and goes down lateroinferiorly and behind the humerus as it leaves the axillary fossa.

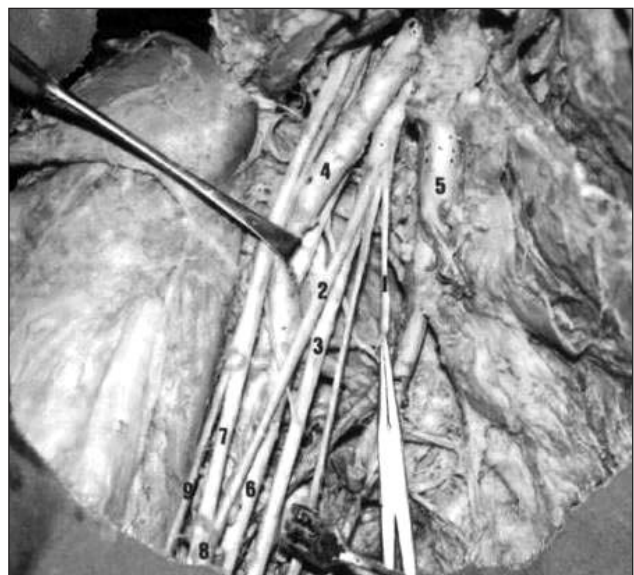


Figure 4: In right BP; 1, medial pectoral nerve: It is the first branch of medial cord and gives fibers to pectoral minor and major muscles; 2, medial root of median nerve: After originating from medial cord, it goes up and laterally and in front of the axillary artery it binds to the median nerve; 3, ulnar nerve: It is the terminal branch of the medial cord going down in the axillary fossa neighboring the axillary artery (4), median nerve laterally and axillary vein (5) medially; 6, brachial artery, 7, lateral root of median nerve, 8, median nerve, 9, musculocutaneous nerve can be seen.

All upper, middle and lower trunks are divided into two divisions as anterior and posterior. Cords of BP originate from combinations of these six divisions. Anterior divisions of upper and middle trunks come together and are called the lateral cord. The anterior division of the lower trunk is named the medial cord individually (25,27,46,63,72). In our study, we observed branching from the lateral cord to the medial root of the median nerve in 4 BPs (33.3%).

The posterior cord is composed of divisions of the upper, middle and lower trunks. In two cases, all three trunks were not fused each other at the same level differing from classical knowledge, and PDLT and PDMT were bound together first and PDUT joined them to originate posterior cord instead, meaning that PDLT and PDMT were located proximally whereas PDUT was located distally.

In the second part of this study, length and width measurement of components of BP in all levels were compared. In our data, in terms of examining the diameters of the components of BP, the thickest root was C₇, and the thinnest root was C₅. At the level of the trunks, the lower trunk was found as the thickest, and the medial trunk was found as the thinnest. At the division level, ADLT was found to be the thickest, and ADMT was found to be the thinnest. At the cord level, the thickest was PC whereas the thinnest was MC.

In terms of root length, the longest root was found as C₅, the shortest one T₁. For trunk length, all three trunks were seen to be equal to each other. In divisions, the longest one was ADLT, the shortest one was PDLT. In cords, the longest one was PC, the shortest one was MC. According to results of length of measurements the average length of BP was calculated as a 151.8 ± 0.73 (SEM) mm. Our measurement is in consensus with the literature data (39).

BP has a complex structure, close relationship with near structures and its location also has a peculiar anatomic structure. BP lesions therefore appear to be more complex than other neurological damages in extremities (20,22,28,62,74). Numerous traffic and industrial accidents occur nowadays and our cases were mostly the victims of the gunshot wounds. The treatment of peripheral nerve wounds has therefore attracted more attention recently (5,14,32). Because of the intricate anatomy and the

close proximity of the plexus with the vital structures, the diagnosis and treatment of BP lesions can be challenging and relevant anatomic structures should be well known and mastered by neurosurgeons (20,29,62,65,67).

There is a seven-seventy rule in BP lesions: In 70% of traumatic plexus lesions, the reason is traffic accidents, 70% of them are cycle and motor-cycle accidents, 70% of them are multiple, 70% of them are supraclavicular lesions, 70% of these supraclavicular lesions one or more spinal nerve roots are avulsed, in 70% of avulsed roots C₇, C₈, T₁ or C₈, T₁ are injured together, and in 70 % of these avulsed cases there is an associated intractable pain (52).

The reasons of BP lesions due to tractions are as follows: Motorcycle accidents, obstetric traumas, holding or pulling of hand, industrial accidents. Injuries due to skiing and climbing have been also reported. In such traumas, root avulsions were more frequently reported (8,15,16,34,45,48,59).

Different imaging techniques, such as myelography, CT and myelo-CT, MR imaging techniques are also used in the diagnosis of BP avulsions (1,7,11,24,31,32,37,49,54,55,72). In addition, neural tissue is more clearly visible with MR neurography (MRN) constructed by adding phase ordered coils. MRN is also used in diagnosis of neuroma fibrosis (focal-diffuse) and traumatic meningocele (23). In root avulsion, the supraclavicular incision is preferred in approaching the BP as this procedure provides neurotization of intercostal and sural nerve grafts.

Thoracic Outlet Syndrome also causes an entrapment neuropathy due to the compression of BP produced by scalene muscles and cervical ribs (24,25,44,71). Lesions of the trunks especially related with retroclavicular region occur with the accompanying clavicle fractures after blunt trauma (3,4).

Gunshot wounds, the second most common cause of brachial plexus injuries (25%), and incisive instrument wounds are generally located in the infraclavicular regions at the level where the divisions and cords of BP are situated (15,38,58,61). Similar lesions in the same structure can also be encountered in scapula fractures (19). The infraclavicular approach enables surgical intervention in that level.

The terminal branches of BP can be damaged secondary to head and neck fractures of humerus due to penetrating and blunt trauma. Vascular lesions accompany these lesions in 25-67% of the cases. Generally the subclavian and axillary arteries are severed (33,43). In such injuries, infraclavicular incisions must be extended through the axillary fossa.

CONCLUSION

BP surgery needs attention and peculiarity in terms of complex anatomical structure and close relationship with neighbouring anatomical structures. In the literature, there are numerous causes of BP lesions coupled with traction; motor accidents, obstetric traumas, drag by pulling from hand, holding of the arm and industrial accidents. In addition, there are sport traumas like skiing and climbing. In this type of injuries, root avulsions may occur. In traumas causing root avulsion, supraclavicular incision as surgical approach in order to reach the BP was preferred. Injuries belonging to trunks especially retroclavicular ones are seen with clavicle fractures after blunt traumas. Gunshot wounds and injuries due to incisive tools are seen mostly in the infraclavicular region and cause division and cord lesions of BP. Infraclavicular approach gives possibility of surgery for lesions at this level.

In addition, terminal branches of BP can be damaged secondary to head-neck fractures of the humerus due to penetrating or blunt trauma. In this kind of wounds, surgery is performed via an infraclavicular incision to the fossa axillaris.

In conclusion; the selection of surgical procedure for BP depends on the localization of the lesion, type and size of wound as well as the relationship with the neighboring neurovascular structures. Supraclavicular, infraclavicular, axillary or combined approaches can be chosen and be tailored according to the above-mentioned factors and the experience of the surgeon.

REFERENCES

- Ahern V, Soo YS, Langlands AD: MRI scanning in brachial plexus neuropathy. *Australasian Radiol* 35: 379-381,1991
- Alliev Y, Cenac P: Neurotization via the spinal accessory nerve in complete paralysis due to multiple avulsion injuries of the brachial plexus. *Clin Orthop* 237: 67-74, 1988
- Alnot JY: Traumatic brachial plexus palsy in the adult. *Clin Orthop* 237: 9-16, 1988
- Barbier O, Malghem J, Delaere O, Vande Berg B, Rombouts JJ: Injury to the brachial plexus by a fragment of bone after fracture of the clavicle. *J Bone Joint Surg* 79-B: 534-536, 1997
- Baysefer A, Izci Y, Akay KM, Kayali H, Timurkaynak E: Surgical outcomes of ulnar nerve lesions in children. A retrospective clinical study. *Pediatr Neurosurg* 40:107-111, 2004
- Birch R: Surgery for brachial plexus injuries. *J Bone Joint Surg* 75-B: 346-348, 1993
- Blair DN, Rapoport S, Sostman HD, Blair DC: Normal brachial plexus: MR imaging. *Radiology* 165: 763-767, 1987
- Bowyer BL, Gooch JL, Geiringer SR: Sports medicine. 2. Upper extremity injuries. *Arch Phys Med Rehabil* 74: 433-437, 1993
- Burt AM: Textbook of Neuroanatomy, 1st ed. Philadelphia: W.B. Saunders Company, 1993: 120-124
- Chuang DC, Epstein D, Yeh MC, Wei FC: Functional restoration of elbow flexion in brachial plexus injuries (excluding obstetric brachial plexus injury). *J Hand Surg* 18-A: 285-291, 1993
- Cooke JC, Parsons C: The anatomy and pathology of the brachial plexus as demonstrated by computed tomography. *Clin Radiol* 39: 595-601, 1988
- Covey DC, Riardon DC, Milstead M, Albright J: Modification of the L'Episcopo procedure for brachial plexus birth palsies. *J Bone Joint Surg* 74-B: 897-901, 1992
- Cusimano MD, Bilbao JM, Cohan SM: Hypertrophic brachial plexus neuritis. *Ann Neurol* 24: 615-622, 1988
- Daneyemez M, Solmaz I, Izci Y: Prognostic factors for the surgical management of peripheral nerve lesions. *Tohoku J Exp Med* 205:269-75, 2005
- Dubussion AS, Kline DG: Indications for peripheral nerve and brachial plexus surgery. *Neurol Clin* 10: 935-951, 1992
- Dumontier C, Gilbert A: Traumatic brachial plexus palsy in children. *Ann Hand Surg* 9: 351-357, 1990
- Dunkerton MC, Boome RS: Stab wounds involving the brachial plexus. *J Bone Joint Surg* 70-B: 566-570, 1988
- Friedman AH, Nunley II JA, Goldner RD, Oakes WJ, Goldner JL, Urbaniak JR: Nerve transposition for the restoration of elbow flexion following brachial plexus avulsion injuries. *J Neurosurg* 72: 59-64, 1990
- Friedman AH, Nunley II JA, Urbaniak JR, Goldner RD: Repair of isolated axillary nerve lesions after infraclavicular brachial plexus injuries. *Neurosurgery* 27: 403-407, 1990
- Gacek RR: Neck dissection injury of a brachial plexus anatomical variant. *Arch Otolaryngol Head Neck Surg* 116: 356-359, 1990
- Gilbert A, Razaboni R, Amar-Khodja S: Indications and results of brachial plexus surgery in obstetrical palsy. *Orthop Clin North Am* 19: 91-105, 1988
- Gökalp HZ, Erongun U: *Nöroşürji Ders Kitabı*. Ankara: Mars Matbaası, 1988: 270-271
- Grant GA, Goodkin R, Kliot M: Evaluation and surgical management of peripheral nerve problems. *Neurosurgery* 825-840, 1999
- Gupta RK, Mehta VS, Banerji AK, Jain RK: MR evaluation of brachial plexus. *Neuroradiology* 31: 377-381, 1989

25. Hama H, Matsusue Y, Ito H, Yamamuro T: Thoracic outlet syndrome associated with an anomalous coracoclavicular joint. *J Bone Joint Surg* 175-A: 1368-1370, 1993
26. Hentz VR, Meyer RB: Brachial plexus microsurgery in children. *Microsurgery* 12: 175-195, 1991
27. Hentz VR, Narakas A: The results of microsurgical reconstruction in complete brachial plexus palsy. *Orthop Clin North Am* 19: 107-114, 1988
28. Hershman EB: Brachial plexus injuries. *Clin Sports Med* 9: 311-329, 1990
29. Herzberg G, Narakas A, Comtet JJ, Bouchet A, Carret JP: Microsurgical relations of the roots of the brachial plexus. *Ann Chir Main* 4: 120-133, 1985
30. Hunt D: Surgical management of brachial plexus injuries. *Develop Med Child Neurol* 30: 321-828, 1988
31. Iyer RB, Fenstermacher MJ, Libshitz HI: MR imaging of the treated brachial plexus. *AJR* 167: 225-229, 1996
32. Izci Y, Gurkanlar D, Ozan H, Gonul E: The morphological aspects of lumbar plexus and roots. An anatomical study. *Turk Neurosurg* 15:87-92, 2005
33. Johnson SF, Johnson B, Strodel WE: Brachial plexus injury: Association with subclavian and axillary vascular trauma. *J Trauma* 31: 1546-1551, 1991
34. Kanaya F, Gonzales M, Park CM, Kutz JE, Kleinert HE, Tsai TM: Improvement in motor function after brachial plexus surgery. *J Hand Surg* 15-A: 30-36, 1990
35. Kawabata H, Masada K, Tsuyuguchi Y, Kawau H, Ono K, Tada K: Early microsurgical reconstruction in birth palsy. *Clin Orthop* 215: 233-242, 1987
36. Kawai H, Kawabata H, Masada K, Ono K, Yamamoto K, Tsuyuguchi Y, Tada K: Nerve repair traumatic brachial plexus palsy with root avulsion. *Clin Orthop* 237: 75-86, 1988
37. Kelman GM, Kneeland JB, Middleton WD, Cates JD, Pech P, Grist TM, Foley WD, Jesmanowicz A, Francisz W, Hyde JS: MR imaging of the supraclavicular region: Normal anatomy. *AJR* 148: 77-82, 1987
38. Kline DG: Civilian gunshot wounds to the brachial plexus. *J Neurosurg* 70: 166-174, 1989
39. Kuran O: *Sistematik Anatomi*. İstanbul: Filiz Kitabevi 1983: 670-681
40. Landi A, Copeland SA, Parry CB, Jones SJ: The role of somatosensory evoked potentials and nerve conduction studies in the surgical management of brachial plexus injuries. *J Bone Joint Surg* 62-B: 492-497, 1980
41. Laurent JP, Lee R, Shenaq S, Parke JT, Solis IS, Kowalik L: Neurosurgical correction of upper brachial plexus birth injuries. *J Neurosurg* 79: 197-203, 1993
42. Leffert RD: Clinical diagnoses, testing and electromyographical study in brachial plexus traction injuries. *Clin Orthop* 237: 24-31, 1987
43. Magalon G, Bordeaux J, Lerge R, Aubert J: Emergency versus delayed repair of severe brachial plexus injuries. *Clin Orthop* 237: 32-35, 1988
44. Mangar D, Relly DL, Holder DD, Comporesi EM: Brachial plexus compression from a malpositioned chest tube after thoracotomy. *Anesthesiology* 74: 780-782, 1991
45. Markey KL, Margaret DB, Curl W: Upper trunk brachial plexopathy. *A J Sports Med* 21: 650-655, 1993
46. Miller SF, Glasier CM, Gribel FA: Brachial plexopathy in infants after traumatic delivery; evaluation with MR imaging. *Radiol* 189: 481-484, 1993
47. Millesi H: Brachial plexus injuries; nerve grafting. *Clin Orthop* 237: 36-42, 1988
48. Moore KL: *Clinically Oriented Anatomy*, 3rd ed. Baltimore: Williams and Wilkins 1992: 510-530
49. Nagano A, Ochiai N, Sugioka H, Hara T, Tsuyama N: Usefulness of myelography in brachial plexus injuries. *J Hand Surg* 14-B: 59-64, 1989
50. Narakas AO, Hentz VR: Neurotization in brachial plexus injuries. *Clin Orthop* 237: 43-56, 1988
51. Narakas AO: Surgical treatment of traction injuries of the brachial plexus. *Clin Orthop* 133: 71-90, 1978
52. Narakas AO: The treatment of the brachial plexus injuries. *Int Orthop* 9: 29-36, 1985
53. Ochiai N, Nagano A, Sugioka H, Hara T: Nerve grafting in brachial plexus injuries. *J Bone Joint Surg* 78-B: 754-758, 1996
54. Posniak HV, Olson MC, Dudiak CN, Wisniewski R, O'Malley C: MR imaging of the brachial plexus. *AJR* 161: 373-379, 1993
55. Rapoport S, Blair DN, McCarthy SM, Desser TS, Hammers LW, Sostman HD: Brachial plexus: Correlation of MR imaging with CT and pathologic findings. *Radiology* 167: 161-167, 1988
56. Samardzic MM, Dumica G, Antunovic V: Nerve transfer in brachial plexus traction injuries. *J Neurosurg* 76: 191-197, 1992
57. Samardzic MM, Grujicic DM, Antunovic V, Joksimovic M: Reinnervation of avulsed brachial plexus using the spinal accessory nerve. *Surg Neurol* 33: 7-11, 1990
58. Samardzic MM, Rasulic LG, Grujicic DM: Gunshot injuries to the brachial plexus. *J Trauma* 43: 645-649, 1997
59. Samii M, Carvalho GA, Nikkhah G, Penkert G: Surgical reconstruction of the musculocutaneous nerve in traumatic brachial plexus injuries. *J Neurosurg* 87: 881-886, 1997
60. Secer HI, Daneyemez M, Gonul E, Izci Y: Surgical repair of ulnar nerve lesions caused by gunshot and shrapnel: Results in 407 lesions. *J Neurosurg*. 107:776-783, 2007
61. Secer HI, Daneyemez M, Tehli O, Gonul E, Izci Y: The clinical, electrophysiologic, and surgical characteristics of peripheral nerve injuries caused by gunshot wounds in adults: A 40-year experience. *Surg Neurol* 69:143-152, 2008
62. Secer HI, Solmaz I, Anik I, Izci Y, Duz B, Daneyemez MK, Gonul E: Surgical outcomes of the brachial plexus lesions caused by gunshot wounds in adults. *J Brachial Plex Peripher Nerve Inj* 23,4:11, 2009
63. Shenaq SM, Tue AD: Replantation, revascularization, and obstetric brachial plexus palsy. *Clin Plastic Surg* 17: 77-83, 1990
64. Snell RS: *Clinical Anatomy for Medical Students*, 4th ed. Boston: Little Brown and Company 1992: 431-448
65. Stevens JH: Brachial plexus paralysis. *Clin Orthop* 237: 4-10, 1988
66. Tersiz J, Maragh H: Strategies in the microsurgical management of brachial plexus injuries. *Clin Plastic Surg* 16: 605-616, 1989
67. Thommeer RT: Recovery of brachial plexus injuries. *Clin Neurol Neurosurg* 93: 3-11, 1991
68. Thompson GE, Rorie DK: Functional anatomy of the brachial plexus sheaths. *Anesthesiology* 59: 117-122, 1983

69. Tonkin MA, Eckersley JRT, Gschwind CR: The surgical treatment of the brachial plexus injuries. *Aust N Z J Surg* 66: 29-39, 1996
70. Travols J, Goldberg I, Boome RS: Brachial plexus lesions associated with dislocated shoulders. *J Bone Joint Surg* 72-B: 68-71, 1990
71. Vahl CF, Carl I, Müller-Vahl H, Struck E: Brachial plexus injury after cardiac surgery. *J Thorac Cardiovasc Surg* 102: 724-729, 1991
72. Verdier HJ, Colletti PM, Terk MR: MRI of the brachial plexus: A review of 51 cases. *Comp Med Imag Graphics* 17: 45-50, 1993
73. Williams PL, Bannister LH, Berry MM, Collins P, Dyson M, Dussek JE, Ferguson MWJ: *Gray's Anatomy*, 38th ed. London: Churchill Livingstone 1995: 1258-1274
74. Yamada S, Lonsers RR, Iacano RP, Marenski JD, Bailey L: By pass coaptation procedures for cervical nerve root avulsion. *Neurosurgery* 38: 1145-1152, 1996
75. Yamada S, Peterson GW, Soloniuk DS, Will AD: Cooptation of the anterior rami of C3 and C4 to the upper trunk of the brachial plexus for cervical nerve root avulsion. *J Neurosurg* 74: 171-177, 1991
76. Yu-dong G, Min-ming W, Yi-lu Z, Jia-ao Z, Gao-meng Z, De-song C, Ji-qing Y, Xiao-ming C: Phrenic nerve transfer for treatment of root avulsion of the brachial plexus. *Chin Med J* 103: 267-270, 1990