



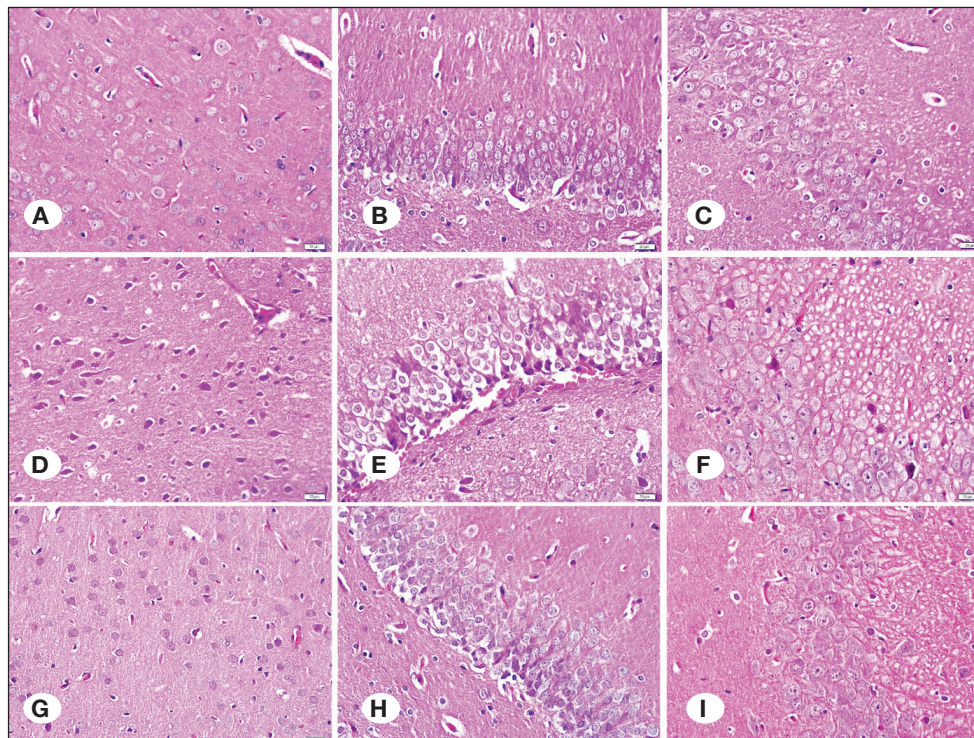
## Corrigendum to: Anti-Inflammatory, Antioxidant and Neuroprotective Effects of Niacin on Mild Traumatic Brain Injury in Rats

Turk Neurosurg 33(6):1028-1037, 2023

DOI: 10.5137/1019-5149.JTN.42563-22.3

Dear Editor and Readers,

As the authors of the manuscript entitled “Anti-Inflammatory, Antioxidant and Neuroprotective Effects of Niacin on Mild Traumatic Brain Injury in Rats” (1), we noticed an error after a retrospective review and want to apologize for the inconvenience in Figure 4. We would like to replace the figure with the correct one as follows:



**Figure 4:** A-C) Representative sections of the cortex, hippocampal dentate gyrus (DG), and CA3 regions, in the control group. D-F) Representative sections of the cortex, hippocampal DG, and CA3 regions in the TBI + placebo group. G-I) Representative sections of the cortex, hippocampal DG, and CA3 regions in the niacin group. H&E stain. Scale bar: 50 µm.

The error relating to Figure 4.A-I in the published version did not affect any statistical data or the study outcome.

We hereby correct the mistake and present them as they should be in order not to misinform our colleagues who will read our study.

### REFERENCES

1. Ozaydin D, Bektasoglu PK, Koyuncuoglu T, Ozkaya SC, Koroglu AK, Akakin D, Erzik C, Yuksel M, Yegen BC, Gurer B: Anti-inflammatory, antioxidant and neuroprotective effects of niacin on mild traumatic brain injury in rats. Turk Neurosurg 33:1028-1037, 2023. <https://doi.org/10.5137/1019-5149.JTN.42563-22.3>.